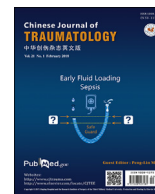



Contents lists available at ScienceDirect

Chinese Journal of Traumatology

journal homepage: <http://www.elsevier.com/locate/CJTEE>

Case Report

Use of tricortical iliac crest strut autograft in comminuted posterior wall acetabular fractures: A case series

Sandeep Gupta*, Naveen Mittal, Jagandeep Singh Virk

Department of Orthopaedics, Government Medical College Hospital, Chandigarh, India

ARTICLE INFO

Article history:

Received 16 August 2017

Received in revised form

20 August 2017

Accepted 27 August 2017

Available online 6 November 2017

Keywords:

Young patients

Comminuted posterior wall

Tricortical iliac crest

ABSTRACT

Purpose: The results for fixation of comminuted posterior wall acetabular fractures are not very promising with reported complications in terms of osteoarthritis, nonunion and malunion which subsequently require conversion to total hip arthroplasty. The conversion to total hip arthroplasty is possible in patients over 50 years of age but not in younger patients. So this requires new methods for salvage of the native hip in young patients.

Methods: There were six patients in our series with highly comminuted posterior wall acetabular fractures where the fragments were excised and the gap filled with tricortical anterior iliac-crest strut autograft, fixed with screws and plate.

Results: Good results were achieved in four out of six patients analyzed clinically using the Merle d'Aubigne score modified by Matta and radiologically by Matta scoring. These patients have returned to original work and are walking independently. The good result in one patient deteriorated from good to poor between one and two years. One patient developed infection and excision arthroplasty was done. The graft incorporated well in five out of six patients.

Conclusion: The use of iliac crest autograft is a better, advanced and promising technique as it provides a new wall to the weight bearing dome of the acetabulum for articulation with the femoral head. The rates of nonunion, malunion, post traumatic osteoarthritis are less as compared to the fixation of the comminuted fragments. The need for conversion to total hip arthroplasty is also less.

© 2017 Daping Hospital and the Research Institute of Surgery of the Third Military Medical University.

Production and hosting by Elsevier B.V. This is an open access article under the CC BY-NC-ND license (<http://creativecommons.org/licenses/by-nc-nd/4.0/>).

Posterior wall fracture-dislocations constitute the major bulk of acetabular fractures.^{1,2} The reported clinical outcomes of surgical management of these fractures in literature have not been very favorable with various authors reporting well to excellent result in only 35% of cases. Posterior wall comminution further compromises the ability to achieve good results in this subset of patients.³ Many strategies have been described in literature for fixation of these fractures including 2-tier fixation and spring plates.^{4,5} Despite adoption of these fixation strategies, some fractures have such severe comminution of posterior wall that it renders adequate fragment fixation impossible. Arthroplasty can be offered in such cases to elderly patients (>50 years) especially if associated with significant head damage.⁶ In similar fracture in young patients,

preservation of native joint is desirable despite fragments being unfixable. Strut cortical bone-grafting after comminuted fragment excision has been described in literature with acceptable results.^{7,8} We present our results of fragment excision and strut tricortical iliac-crest graft fixed with plate and screws to replace posterior wall in patients with unfixable comminuted posterior wall fractures.

Material and methods

We retrospectively analyzed our patient data from January 2011 to December 2013. Fifty four patients with posterior dislocation with posterior wall fractures were operated during this time. All patients were treated by the senior surgeon with intent to preserve the native hip using standard fixation techniques. Six patients were identified where comminution was so severe that fragments were deemed unfixable (Figs. 1–3). The comminuted fragments were excised and tricortical anterior iliac-crest strut autograft, fixed with screws and plate, was used to replace the posterior wall.

* Corresponding author.

E-mail address: sandy_tdh@yahoo.com (S. Gupta).

Peer review under responsibility of Daping Hospital and the Research Institute of Surgery of the Third Military Medical University.

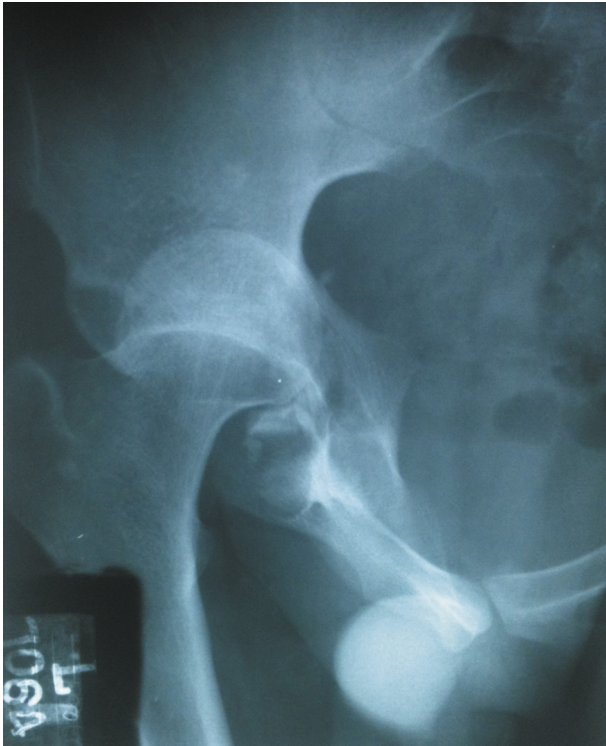

Fig. 1. The pre-operative X-ray with fracture dislocation of the hip.

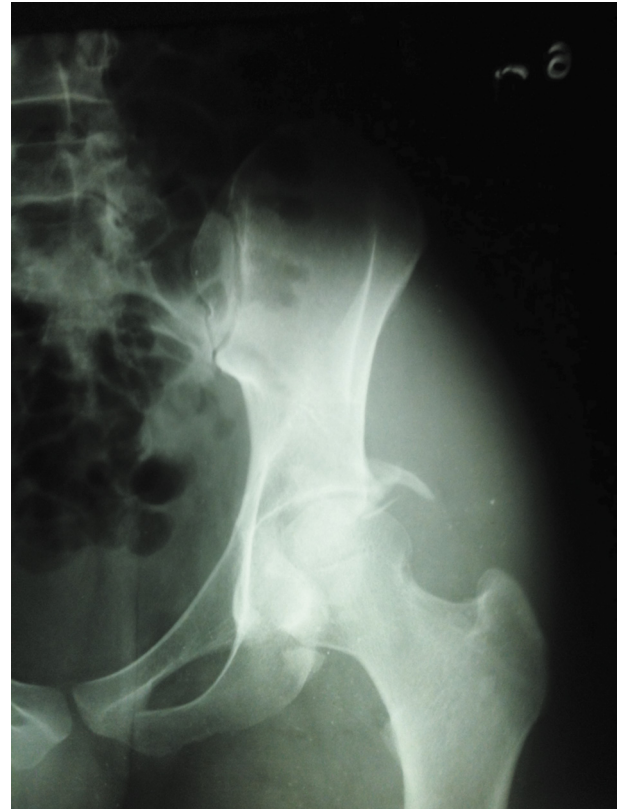

Fig. 2. X-ray after reduction of dislocation with comminuted posterior wall fracture.

Surgical technique

All patients were operated in lateral decubitus position using Kocher-Langenbeck approach. Additional trochanteric flip osteotomy was used in all cases to improve the dome exposure. Comminuted fragments were excised and posterior wall defect was measured using metallic caliper. Slightly oversized tri-cortical strut graft was harvested from anterior iliac-crest and shaped with bone nibblers to get a snug fit in the defect. Graft was secured with 2–3 K-wires (2 mm) and stability of the hip checked clinically and under c-arm for subtle instability. Definitive fixation was achieved using 2–3 inter fragmentary screws (3.5 mm cortical or 4.0 mm cancellous) and appropriately positioned reconstruction-plates. Flip osteotomy was fixed with 2–3 small-fragment screws and routine layered closure was done (Figs. 4–6).

Rehabilitation and follow-up

Patients were mobilized toe-touch with walker the next day. Stitch removal was done at two weeks and then followed up in six weeks, three months, six months, nine months, one year and two years post-operatively. CT scan was done at 2 years and patients were asked to follow up if any problem arose in the hip or yearly thereafter.

All patients were available for the follow up which were evaluated clinically using modified Merle de'Aubigne score⁹ were graded radiologically using Matta's score.¹⁰

Ethics

All procedures performed in studies involving human participants were in accordance with the ethical standards of the institutional and/or national research committee and with the 1975

Helsinki declaration and its later amendments or comparable ethical standards.

Statistics

The Pearson correlation coefficient was used for assessing the correlation between the clinical outcome and the radiological outcome.

Results

There were six patients in our study with five males and one female. The mean age was 30.5 years (18–49 years). The mean follow-up was 47.66 months (43–57 months). An associated injury was observed in three patients. One of the patients had sciatic nerve palsy pre-operatively which completely recovered by itself in two years. One patient developed infection at the surgical site. None of the patients reported complication in the form of heterotopic ossification. The demographic profile and clinical/radiological follow up is cited in Table 1.

The clinical score at one year follow up was good in 83.33% (5/6) patients and poor in one patient. However, the clinical score at two years follow up was good in four (66.67%) patients and poor in two (33.33%) thus deteriorating in one patient from good to poor. The radiological outcome at one year follow up was good in four (66.67%) patients, fair in one (16.66%) and poor in one (Figs. 7 and 8). At two years follow up, the radiological outcome was good in three (50%) patients, fair in one (16.67%) and poor in two (33.33%) thus deteriorating from good to poor in one patient (Figs. 9 and 10). The clinical and radiological score remained unaltered at last follow up as compared with that at two years. Four patients have returned

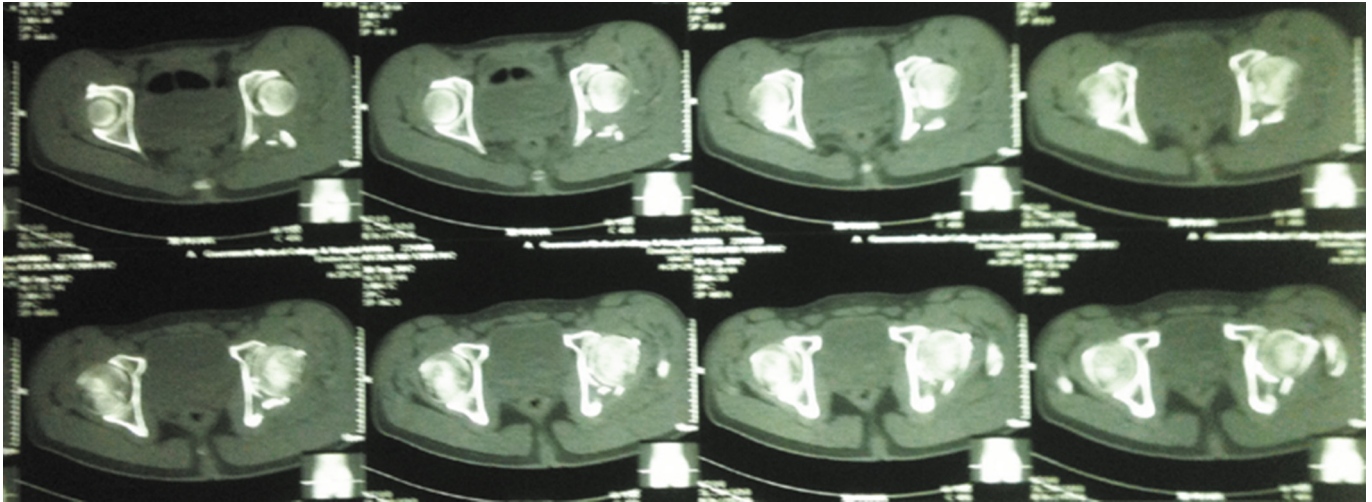


Fig. 3. Pre-operative CT scans show better delineation of comminution of the posterior wall.

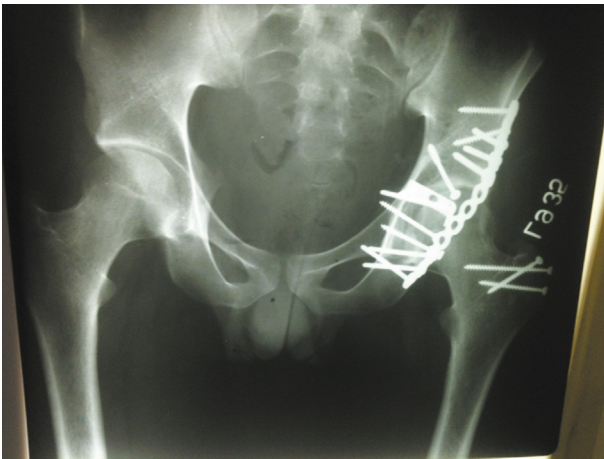

Fig. 4. Immediate post-operative AP X-ray shows the graft well fixed.

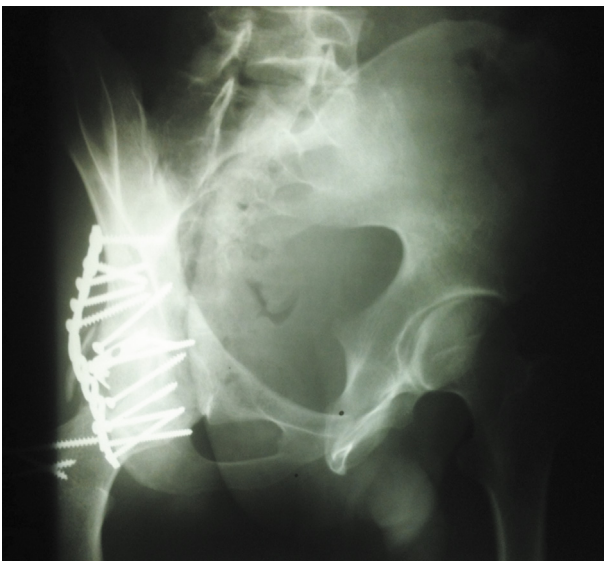

Fig. 5. Immediate post-operative obturator view with good reduction of the posterior wall.

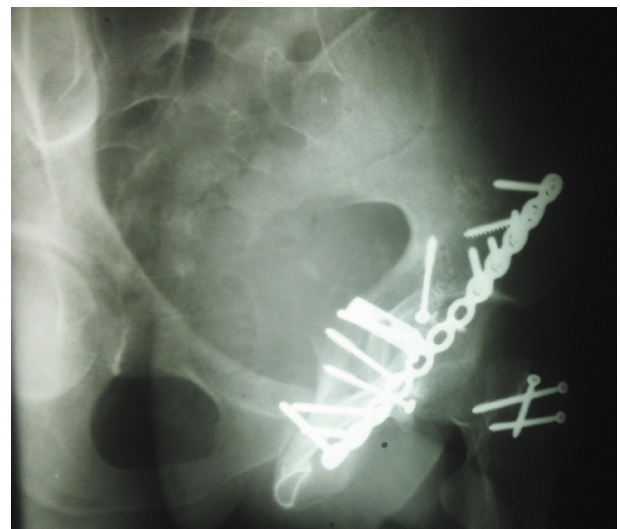


Fig. 6. Immediate post-operative iliac oblique view with good reduction of the posterior column.

to original work and are walking independently. Excision arthroplasty was performed in the patient who developed infection and was walking with frame-support. The other patient with poor result has been advised total hip replacement but is not willing for the same. Using the Pearson correlation coefficient, the clinical outcome correlated well with the radiological outcome.

None of the patients have reported any pain and disability at latest follow up in relation to graft-harvest site. Associated focal lesions of the femoral head in the form of posterior-superior scoring were seen in all the patients. Three patients were operated within one week of injury, two had good clinical and radiological outcome while one had poor outcome because of infection. Three patients were operated after two weeks, two had good clinical outcome whereas as radiological outcome was good in one patient, fair in one and poor in one.

Discussion

The review of literature clearly indicates that the results of reduction and fixation of comminuted posterior wall acetabular

Table 1
Demographic profile of patients.

No.	Age	Sex	Duration between injury and surgery (day)	Associated injuries	Post op. complication	At the first year		At the second year		At last follow-up	
						Radiological score	Clinical score	Radiological score	Clinical score	Radiological score	Clinical score
1	25	male	4	Opposite side # shaft femur with extensive soft-tissue degloving ipsilateral leg	infection	poor	poor	poor	poor	poor	poor
2	22	male	5	sciatic nerve palsy	none	good	good	good	good	good	good
3	42	male	8	None	none	fair	good	good	good	good	good
4	27	male	17	ipsilateral # bimal	none	good	good	good	good	good	good
5	18	female	59		none	good	good	poor	poor	poor	poor
6	49	male	41	liver injury	none	good	good	fair	good	fair	good

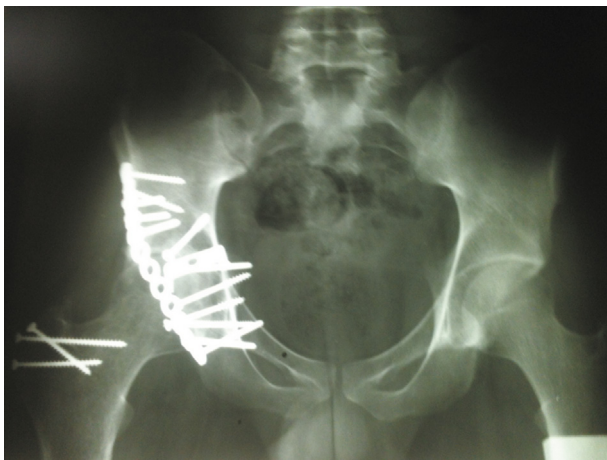

Fig. 7. Post-operative AP X-ray at 6 months follow up with the reduction well maintained.

fractures are not very promising. Letournel et al. reported good results in only 35% of the patients with comminuted posterior wall fractures.³ Saterbak et al. reported poor results in 11 patients who had comminuted fractures of the posterior wall with greater than three fragments and eight of these required reconstructive surgeries (72.7%).¹¹ Gupta et al.¹² in their study of 52 patients with poor outcomes of acetabular fractures, 13 had comminuted fractures with greater than three fragments. We agree with Matta that a malreduced posterior wall or non-union of the comminuted fragments can cause rapid wear of the femoral head that resembles AVN.¹⁰ So, this stems the need for developing better and advanced methods of fixation.

Daum et al. firstly described the use of iliac crest graft for comminuted posterior wall fractures in 1993 achieving satisfactory result in one case and poor in another case requiring total hip arthroplasty.⁷ Thus, this study was inconclusive. Sen et al. described reconstruction of the posterior wall using graft from the iliac crest achieving satisfactory clinical outcome in seven out of eight patients (87.5%).⁸ Zha et al. recommended the procedure for pediatric patients or adults without post traumatic arthritis for reconstruction of late acetabular deficits following unsuccessfully managed posterior wall fractures.¹³ Zhang et al. described case report of massive heterotopic ossification with late bone defects in the posterior wall of acetabulum after failed acetabular fracture operation. The posterior wall was reconstructed using the heterotopic bone followed by fixation with Ni–Ti shaped-memory alloy device named ATMFS for fixation instead of screws and plates achieving good result.¹⁴ We achieved good results in four out of six cases with the result in the 5th case deteriorating between one and two years which may be attributable to the late presentation of the patient.

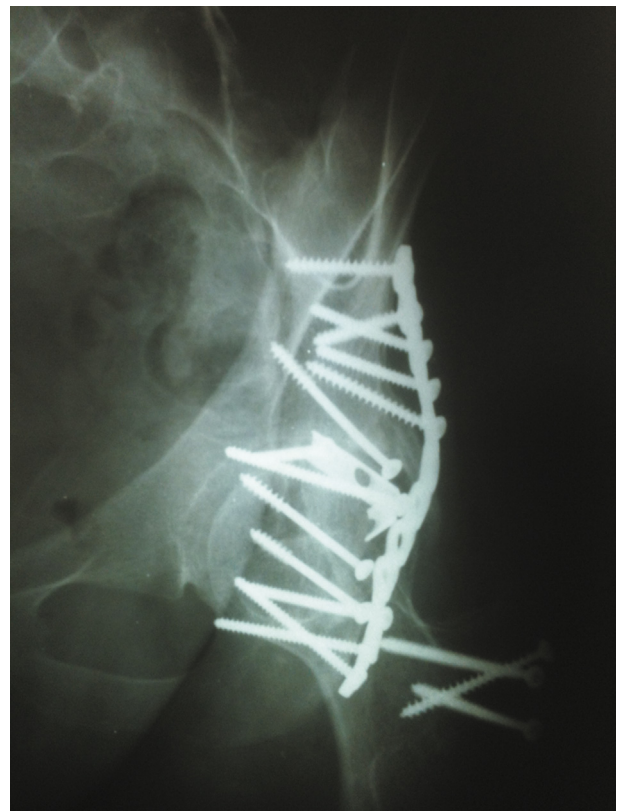

Fig. 8. Post-operative obturator view at one year follow up with the head vascularity retained.

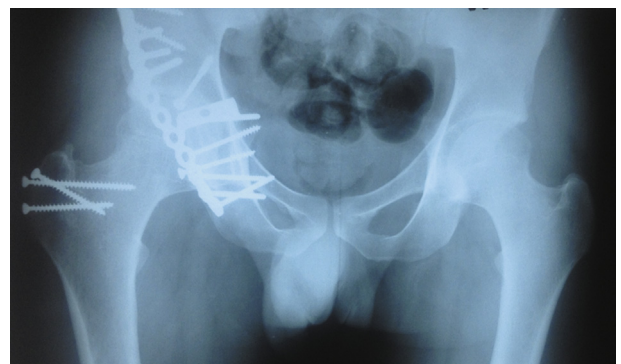


Fig. 9. Post-operative AP X-ray at two years with the fracture fully united and head completely vascular.

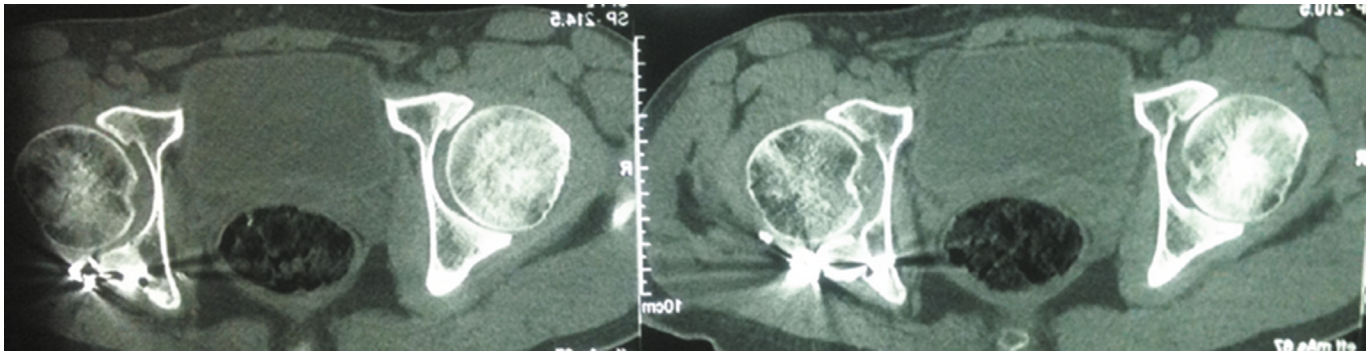


Fig. 10. Transverse cuts of CT scans at two years follow up with good reduction of the articular surface maintained.

The graft was well incorporated in five out of six patients with no incidence of nonunion or malunion. Thus, all of these studies have achieved good clinical and radiological outcomes better than the studies for fixation of comminuted fragments. The number of patients requiring conversion to total hip arthroplasty is also less with this method as compared to the results of fixation.

Thus, use of iliac crest autograft in comminuted posterior wall fractures is a better, advanced and promising technique as it provides a new wall to the weight bearing dome of the acetabulum for articulation with the femoral head. The rates of nonunion, malunion, post traumatic osteoarthritis are less as compared to the fixation of the comminuted fragments. The need of conversion to total hip arthroplasty is also less.

Patient declaration statement

The authors certify that they have obtained all appropriate patient consent forms in which the patient(s) has/have given his/her/their consent for his/her/their images and other clinical information to be reported in the journal. The patients understand that their names and initials will not be published and due efforts will be made to conceal their identity, but anonymity cannot be guaranteed.

Appendix A. Supplementary data

Supplementary data related to this article can be found at <https://doi.org/10.1016/j.cjtee.2017.08.005>.

References

- Mears DC, Velyvis JH, Chang CP. Displaced acetabular fractures managed operatively: indicators of outcome. *Clin Orthop Relat Res*. 2003;407:173–186.
- Giannoudis PV, Grotz MR, Papakostidis C, et al. Operative treatment of displaced fractures of the acetabulum. A meta-analysis. *J Bone Jt Surg Br*. 2005;87:2–9.
- Letournel E, Judet R. *Fractures of the Acetabulum*. New York: Springer; 1993:29–581.
- Giannoudis PV, Tzioupis C, Moed BR. Two-level reconstruction of comminuted posterior-wall fractures of the acetabulum. *J Bone Jt Surg Br*. 2007;89:503–509.
- Goulet JA, Rouleau JP, Mason DJ, et al. Comminuted fractures of the posterior wall of the acetabulum. A biomechanical evaluation of fixation methods. *J Bone Jt Surg Am*. 1994;76:1457–1463.
- Iotov A, Ivanov V, Tzachev N, et al. Primary total hip replacement after neglected acetabular fractures. *J Bone Jt Surg Br*. 2012;94:291.
- Daum WJ. Traumatic posterior acetabular defects reconstructed with iliac crest autograft. A report of two cases. *Clin Orthop Relat Res*. 1993;291:188–192.
- Sen RK, Tripathy SK, Aggarwal S, et al. Posterior wall reconstruction using iliac crest strut graft in severely comminuted posterior acetabular wall fracture. *Int Orthop*. 2011;35:1223–1228. <https://doi.org/10.1007/s00264-010-1177-3>. Epub 2010 Dec 7.
- D'Aubigne RM, Postel M. Functional results of hip arthroplasty with acrylic prosthesis. *J Bone Jt Surg Am*. 1954;36-A:451–475.
- Matta JM. Fractures of the acetabulum: accuracy of reduction and clinical results in patients managed operatively within three weeks after the injury. *J Bone Jt Surg Am*. 1996;78:1632–1645.
- Saterbak AM, Marsh JL, Nepola JV, et al. Clinical failure after posterior wall acetabular fractures: the influence of initial fracture patterns. *J Orthop Trauma*. 2000;14:230–237.
- Gupta RK, Jindal N, Pruthi M. Acetabular fractures labelled poor surgical choices: analysis of operative outcome. *J Clin Orthop Trauma*. 2015 Jun;6:94–100. <https://doi.org/10.1016/j.jcot.2015.03.003>. Epub 2015 Mar 21.
- Zha GC, Sun JY, Chen L, et al. Late reconstruction of posterior acetabular wall fractures using iliac crest. *J Trauma Acute Care Surg*. 2012;72:1386–1392. <https://doi.org/10.1097/TA.0b013e318248bdef>.
- Zhang Y, Xie Y, Xu S, et al. Massive heterotopic ossification associated with late deficits in posterior wall of acetabulum after failed acetabular fracture operation. *BMC Musculoskelet Disord*. 2013;26(14):368. <https://doi.org/10.1186/1471-2474-14-368>.