

Presumed congenital nictitating membrane dysplasia in a Japanese white rabbit

Miki Masatsugu  | Ikuyo Atsumi | Yoshinori Yamagiwa | Yu Haranosono | Masaaki Kurata

Central Research Laboratories, Senju Pharmaceutical Co., Ltd., Kobe, Hyogo, Japan

Correspondence

Miki Masatsugu, Central Research Laboratories, Senju Pharmaceutical Co., Ltd., 6-4-3, Minatojima-Minamimachi, Chuo-ku, Kobe, Hyogo 650-0047, Japan.
Email: m-masatsugu@senju.co.jp

Abstract

Objective: The present report characterises a spontaneous nictitating membrane abnormality in a Japanese white rabbit.

Animal studied: The animal was a male Japanese white rabbit (*Oryctolagus cuniculus*, Kbs:JW, 10 weeks old at the time of purchase) that had not received any treatment. A morphological abnormality of the nictitating membrane in the animal's right eye was detected.

Procedures: Ophthalmological examinations, including slit-lamp biomicroscopy, corneal and conjunctival staining with fluorescein and lissamine green, fundoscopy, blinking rate measurement, Schirmer's tear test, and tonometry were performed. The animal was euthanised at 15 weeks of age, and histopathological examinations of the abnormal nictitating membrane, palpebral conjunctiva, eyelid and eyeball were performed.

Results: The tip of the nictitating membrane adhered to the palpebral conjunctiva of the medial canthus. The eye and periocular tissues showed no abnormalities in the ophthalmological examinations, except for the structure of the nictitating membrane. Histopathological examination revealed that the adhered site of the nictitating membrane and the palpebral conjunctiva consisted of dense fibrous connective tissue that was consecutive to the conjunctiva adjacent to the eyelid margin and lamina propria of the nictitating membrane. The fibrous connective tissue was covered with stratified squamous epithelium.

Conclusion: Based on these results, we diagnosed this abnormal finding as congenital nictitating membrane dysplasia. This paper is the first case report describing a congenital structural abnormality of the nictitating membrane in a Japanese white rabbit.

KEYWORDS

congenital abnormalities, conjunctiva, nictitating membrane, rabbits

This is an open access article under the terms of the [Creative Commons Attribution-NonCommercial-NoDerivs](https://creativecommons.org/licenses/by-nc-nd/4.0/) License, which permits use and distribution in any medium, provided the original work is properly cited, the use is non-commercial and no modifications or adaptations are made.

© 2022 The Authors. *Veterinary Medicine and Science* published by John Wiley & Sons Ltd.

1 | INTRODUCTION

The nictitating membrane (also referred to as the third eyelid) is an ocular adnexa like thin sheet observed at the medial canthus in vertebrates, including some laboratory animals (e.g. rabbits and dogs). It is a fold of conjunctiva that contains a cartilaginous plate covered with exocrine glands that contribute to the production of tears (Schafer & Render, 2013). Rabbits are commonly used for non-clinical toxicity studies in ophthalmic drug development because of relatively high sensitivity against ocular irritants compared with other laboratory animals, and the characteristics and differences from other laboratory animals in ocular and periocular tissues are well known (Atsumi et al., 2013; Kurata et al., 2016; Kurata et al., 2017). To the best of our knowledge, however, there is no information about abnormal findings of nictitating membranes in rabbits (Langevin et al., 2018; Sorden et al., 2021). Here, we report a case of a structural abnormality of a nictitating membrane in an albino rabbit and the ophthalmological and histopathological findings.

2 | MATERIALS AND METHODS

2.1 | Animal

The animal was from a batch of untreated male Japanese white rabbits (*Oryctolagus cuniculus*, Kbs:JW) that were purchased from Kitayama Labes Co., Ltd. (Nagano, Japan) at 10 weeks of age for a toxicity study. An abnormality of the nictitating membrane in the animals' right eye was noted during ophthalmological examinations in the acclimation period.

Until euthanasia, the animal was maintained in a plastic cage for rabbits (R-SUITE, 784 × 820 × 1830 mm, Tecniplast S.p.A., Buguggiate, Italy) at a temperature range of 19°C to 25°C and a relative humidity of 40%–70% with a 12-h light/12-h dark cycle. The feed (Lab R stock; Nosan Corporation, Tokyo, Japan) was supplied once a day, and tap water was available ad libitum. A dumbbell (Bio-Serv, Flemington, NJ, USA) was placed in the cage for environmental enrichment. The animal was observed for clinical signs at least once a week.

2.2 | Ophthalmological examinations

The ocular and periocular tissues, that is, the nictitating membrane, palpebral and bulbar conjunctiva, cornea, anterior chamber and lens, were observed macroscopically and microscopically using a slit-lamp biomicroscope SL130 (Carl Zeiss Meditec Inc., Jena, Germany). In particular, corneal and conjunctival epithelial damage was also evaluated by staining with fluorescein (AYUMI Pharmaceutical Corporation, Tokyo, Japan) and lissamine green (Sigma-Aldrich Co., St. Louis, MO, USA). Fundoscopy was conducted using a binocular indirect ophthalmoscope IO- α (Neitz Instruments Co., Ltd., Tokyo, Japan) after instillation of a mydriatic agent of tropicamide/phenylephrine hydrochloride ophthalmic solution (Santen Pharmaceutical Co., Ltd., Osaka, Japan).

Lacrimal volume was measured by Schirmer's test 1 (the method without anaesthesia) with tear production measuring strips (AYUMI Pharmaceutical Corporation), and the blinking rate was counted for 1 min with a retention container for rabbits. Intraocular pressure (IOP) was measured using a pneumatonometer Model 30 (Reichert Inc., Depew, NY, USA) under local anaesthesia with oxybuprocaine hydrochloride (Santen Pharmaceutical Co., Ltd., Osaka, Japan).

2.3 | Histopathological examination

The animal was euthanised by intravenous injection of an overdose of sodium thiopental (Nipro ES Pharma Co., Ltd., Osaka, Japan) at 15 weeks of age (5 weeks after purchase). Following euthanasia, the nictitating membrane, including the adhered region with the palpebral conjunctiva and consecutive area of the eyelid on the right side, was collected and fixed in 10% formalin neutral buffer solution (FUJIFILM Wako Pure Chemical Corporation, Osaka, Japan). The right and left eyeballs were also collected and fixed in 0.1 M phosphate buffered 1% formaldehyde/2.5% glutaraldehyde fixative and post-fixed in 10% formalin neutral buffer solution. After fixation, the tissues were embedded in paraffin, sectioned, and stained with haematoxylin and eosin. Stained sections were observed microscopically.

3 | RESULTS

An abnormality in the nictitating membrane of the right eye was noted on macroscopy and slit-lamp biomicroscopy. The tip of the free edge of the nictitating membrane was bound to the palpebral conjunctiva of the medial canthus, and the bulbar surface of the nictitating membrane was exposed to the outside because the nictitating membrane was curled and overturned (Figure 1). In slit-lamp biomicroscopy and fundoscopy, the ocular and periocular tissues had no abnormal findings except for the structure of the nictitating membrane. No corneal or conjunctival epithelial damage was observed by fluorescein and lissamine green staining. No abnormal changes were detected from the following results: the blinking rate was 0 time/min, the lacrimal volume was 8.5 mm/min and the IOP was 22.3 mmHg. Ophthalmological examinations of the left eye revealed no abnormalities. Furthermore, the rabbit showed no abnormality in general condition or behaviour until euthanasia.

In the histopathological examination, the adhered site of the nictitating membrane and palpebral conjunctiva consisted of dense fibrous connective tissue that was consecutive to the conjunctiva in the vicinity of the eyelid epithelium and lamina propria of the nictitating membrane (Figure 2). The fibrous connective tissue was covered with the stratified squamous epithelium and the density of the adhered site was similar to that in the palpebral conjunctiva and nictitating membrane. The nictitating membrane contained a hyaline cartilaginous plate and glands, and none of the tissues had any morphological abnormalities. There were no abnormalities in the right eyelid or either eyeball.

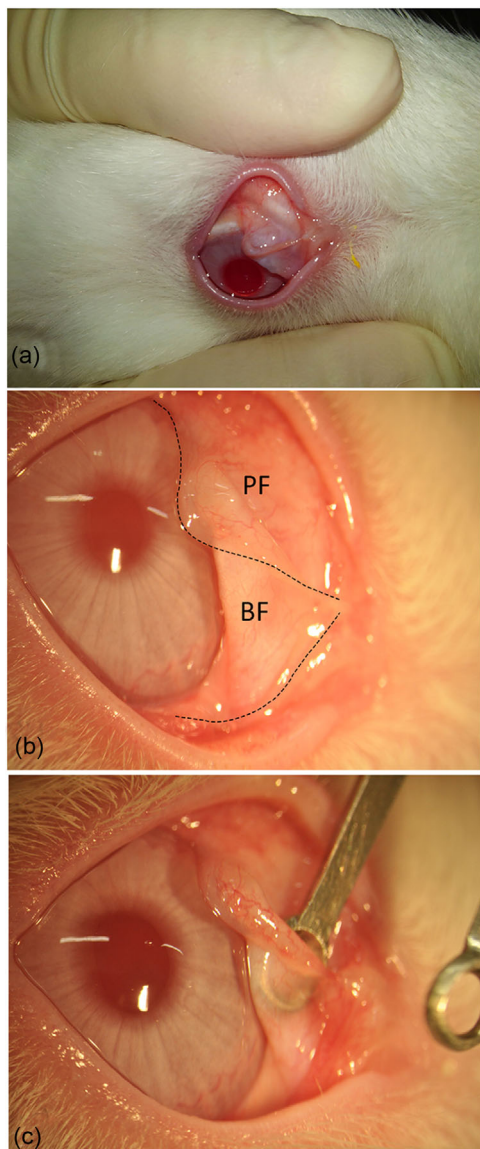


FIGURE 1 Gross (a) and slit-lamp biomicroscopic images (b and c) of the abnormal nictitating membrane of the right eye in the rabbit. (a) The bulbar surface of the nictitating membrane is overturned and exposed to the outside. (b) The free edge (dashed line) of the nictitating membrane is bound with the palpebral conjunctiva of medial canthus. (c) The adhered site is limited to the tip of the nictitating membrane because a tweezer can be inserted into the curled nictitating membrane from the free edge under local anaesthesia. PF, palpebral face; BF, bulbar face

4 | DISCUSSION

From the above results, the dense fibrous connective tissue covered with stratified squamous epithelium was consecutive from the palpebral conjunctiva to the conjunctival tissue of the nictitating membrane via the adhered site. Fibroblasts and conjunctival epithelial cells in the adhered site had no morphological abnormalities. In addition, there were no ophthalmological or histopathological findings suggestive of an inflammatory reaction in the eyeball and the ocular adnexa including

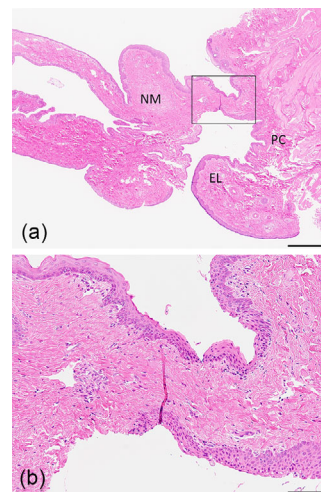


FIGURE 2 Haematoxylin and eosin-stained section of the adhered site of the free edge of the nictitating membrane and the palpebral conjunctiva of medial canthus. (a) The square indicates the adhered site. Scale bar: 500 μm . NM, nictitating membrane; PC, palpebral conjunctiva; EL, eyelid. (b) High magnification of the panel a. The adhered site between the nictitating membrane and eyelid consists of dense fibrous connective tissues covered with stratified squamous epithelium. Scale bar: 100 μm

the adhered site. Therefore, this abnormal finding was presumptively diagnosed as a congenital nictitating membrane dysplasia.

Symblepharon is a conjunctival adhesive lesion caused by inflammation of the bulbar or palpebral conjunctiva, cornea or third eyelid due to herpesvirus infection and is mainly reported in young cats (Maggs, 2018). In the present case, the lesion morphology, or the adhesion of the palpebral conjunctiva and nictitating membrane, was macroscopically similar to symblepharon; however, the adhered site in the conjunctiva predominantly consisted of consecutive fibrous connective tissue without infiltration of inflammatory cells. Therefore, in the diagnosis of this lesion, we excluded symblepharon and other acquired inflammatory diseases.

In dogs and cats, eversion of the nictitating membrane is well known as an abnormal appearance caused by the prolapse of the gland of nictitating membrane (called as cherry eye), or by the bending of the T-shaped cartilage. The former results from a combination of lymphoid hyperplasia and laxity of the retinaculum that normally attaches the third eyelid to the periorbita, and the latter results from the abnormal elongation of the vertical arm of the T-shaped cartilage (Peruccio, 2018). In the present case; however, the cartilage and the glands of the nictitating membrane had no histological abnormality. Additionally, it is not likely that abnormal elongation of the cartilage causes the nictitating membrane to overturn in rabbits because rabbits have a round-shaped nictitating cartilage in nature. Therefore, it is considered that the cause of eversion of the nictitating membrane in this case differs from that in dogs and cats. The nictitating membrane starts to develop from the maxillary process in a fetus at the age of 19-day or under, with the conjunctival surfaces derived from the surface ectoderm and neural crest-derived mesenchyme contributing to the internal structures

(Peruccio, 2018; Vézina, 2013). We considered that the abnormal nictitating membrane in the present case developed with incomplete separation from the maxillary process in the first half of the prenatal period of the rabbit.

The nictitating membrane has secretory glands and contributes to maintaining ocular surface health, for example, production of immunoglobulins in the tear film, spreading of the precorneal tear film and protection of the cornea (Peruccio, 2018; Schafer & Render, 2013). In the present case, ophthalmological results regarding ocular health were within normal ranges compared with the following data in normal rabbits; blinking rate was 1 time per 6 min (Vézina, 2013), IOP was 15–23 mmHg (Vareilles et al., 1977), and lacrimal volume was 0–11.2 mm/min (Abrams et al., 1990). Thus, the nictitating membrane abnormality did not affect its function.

5 | CONCLUSION

In summary, this paper is the first case report describing congenital nictitating membrane dysplasia in a Japanese white rabbit. The case report about the nictitating membrane of a rabbit will deepen the understanding of developmental abnormalities in the ocular adnexa and provide information on ocular background lesions in non-clinical studies in laboratory rabbits.

ACKNOWLEDGEMENTS

We would like to thank Mr. Yoshihiro Takei and the staff of Ina Research Inc. for their technical assistance in preparing the specimens for the histopathological experiments.

CONFLICT OF INTEREST

The authors declare no potential conflicts of interest with respect to the research, authorship and/or publication of this article.

FUNDING INFORMATION

This research did not receive any specific grant from funding agencies in the public, commercial or not-for-profit sectors.

ETHICS APPROVAL

The authors confirm that the ethical policies of the journal, as noted on the journal's author guidelines page, have been adhered to and the appropriate ethical review committee approval has been received. All experiments in this study were reviewed and approved by the Institutional Animal Care and Use Committee of Senju Pharmaceutical Co., Ltd (approval number: 20191025-01), and performed in accordance with the Act on Welfare and Management of Animals in Japan.

AUTHOR CONTRIBUTIONS

Miki Masatsugu: conceptualisation; investigation; writing – original draft; writing – review & editing. Ikuyo Atsumi: conceptualisation; investigation; writing – review & editing. Yoshinori Yamagiwa: conceptualisation; investigation; writing – review & editing. Yu Haranosono: writing – review & editing. Masaaki Kurata: writing – review & editing.

DATA AVAILABILITY STATEMENT

The data that support the findings of this study are available from the corresponding author upon reasonable request.

PEER REVIEW

The peer review history for this article is available at <https://publons.com/publon/10.1002/vms3.844>.

ORCID

Miki Masatsugu  <https://orcid.org/0000-0001-5980-8088>

REFERENCES

- Abrams, K. L., Brooks, D. E., & Theran, P. (1990). Evaluation of the Schirmer tear test in clinically normal rabbits. *American Journal of Veterinary Research*, 51(12), 1912–1913.
- Atsumi, I., Kurata, M., & Sakaki, H. (2013). Comparative study on ocular anatomical features among rabbits, beagle dogs and cynomolgus monkeys. *Animal Eye Research*, 32, 35–41. <https://doi.org/10.11254/jscvo.32.35>
- Kurata, M., Atsumi, I., Yamagiwa, Y., & Sakaki, H. (2016). Ocular instillation toxicity study: Current status and points to consider on study design and evaluation. *Fundamental Toxicological Sciences*, 3(5), 217–232. <https://doi.org/10.2131/fts.3.217>
- Kurata, M., Yamagiwa, Y., Haranosono, Y., & Sakaki, H. (2017). Repeated-dose ocular instillation toxicity study: A survey of its study design on the basis of common technical documents in Japan. *Fundamental Toxicological Sciences*, 4(2), 95–99. <https://doi.org/10.2131/fts.4.95>
- Langevin, N. E., Schafer, K. A., Turner, O. C., McPherson, B. J., & Rose, R. E. (2018). Historical data: Histopathology lesions observed in the eyes of control rabbits in topical ocular administration and contact lens studies. *Toxicologic Pathology*, 46(7), 799–820. <https://doi.org/10.1177/0192623318803854>
- Maggs, D. J. (2018). Diseases of the conjunctiva. In: D. J. Maggs, P. E. Miller, & R. Ofri (Eds.), *Slatter's fundamentals of veterinary ophthalmology* (6th edn., pp. 158–177). Missouri: Elsevier.
- Peruccio, C. (2018). Diseases of the third eyelid. In: D. J. Maggs, P. E. Miller, & R. Ofri (Eds.), *Slatter's fundamentals of veterinary ophthalmology* (6th edn., pp. 178–185). Missouri: Elsevier.
- Schafer, K. A., & Render, J. A. (2013). Toxicologic pathology of the eye: Histologic preparation and alterations of the anterior segment. In: A. B. Weir & M. Collins (Eds.), *Assessing ocular toxicology in laboratory animals* (pp. 159–217). New York: Springer.
- Sorden, S. D., Larsen, T., McPherson, L. E., Turner, O. C., Carroll, E. E., & Sharma, A. K. (2021). Spontaneous background and procedure-related microscopic findings and common artifacts in ocular tissues of laboratory animals in ocular studies. *Toxicologic Pathology*, 49(3), 569–580. <https://doi.org/10.1177/0192623320966244>
- Vézina, M. (2013). Comparative ocular anatomy in commonly used laboratory animals. In: A. B. Weir & M. Collins (Eds.), *Assessing ocular toxicology in laboratory animals* (pp. 1–21). New York: Springer.
- Vareilles, P., Conquet, P., & Douarec, J. C. L. (1977). A method for the routine intraocular pressure (IOP) measurement in the rabbit: Range of IOP variations in this species. *Experimental Eye Research*, 24(4), 369–375. [https://doi.org/10.1016/0014-4835\(77\)90149-X](https://doi.org/10.1016/0014-4835(77)90149-X)

How to cite this article: Masatsugu, M., Atsumi, I., Yamagiwa, Y., Haranosono, Y., & Kurata, M. (2022). Presumed congenital nictitating membrane dysplasia in a Japanese white rabbit. *Veterinary Medicine and Science*, 8, 1946–1949. <https://doi.org/10.1002/vms3.844>