



Original Article

Laser speckle imaging to evaluate scalp flap blood flow during closure in neurosurgical procedures

Andrew P. Carlson¹, Taryn Denezpi¹, Omar S. Akbik², Laila M. Mohammad³

¹Department of Neurosurgery, University of New Mexico Hospital, Albuquerque, New Mexico, ²Department of Neurosurgery, Creighton University Medical Center, Omaha, ³Department of Neurosurgery, Cook Children's Jane and John Justin Neurosciences Center, Fort Worth, Texas, United States.

E-mail: *Andrew P. Carlson - andrewcarlson@salud.unm.edu; Taryn Denezpi - TMDenezpi@salud.unm.edu; Omar S. Akbik - omarakbik@creighton.edu; Laila M. Mohammad - lmoham4@gmail.com



***Corresponding author:**

Andrew P. Carlson,
Department of Neurosurgery,
University of New Mexico
Hospital, New Mexico, United
States.

andrewcarlson@salud.unm.edu

Received : 11 February 2021
Accepted : 23 April 2021
Published : 30 December 2021

DOI

10.25259/SNI_143_2021

Videos Available on:

https://doi.org/10.25259/SNI_143_2021

Quick Response Code:



ABSTRACT

Background: To measure the degree of relative ischemia caused by skin closure, we explored the potential utility of intraoperative surface blood flow measurement with laser speckle imaging (LSI).

Methods: Prospective observational study of eight subjects that underwent intraoperative LSI during elective cranial neurosurgical procedures at the time of skin closure.

Results: Seven 1st time incisions, with closure techniques including sutures ($n = 3$), staples ($n = 3$), and one after galeal sutures. When compared to the control region, there was a mean 63.7% reduction in flow across all seven subjects (range 18.7–95.32%). Comparing by closure type, a higher flow reduction in the three subjects with suture closure (80.7% reduction) compared to staples (61.9% reduction, $P = 0.0379$). One subject had a complex wound where tightening and loosening of sutures were performed to ensure adequate perfusion. Suturing resulted in significantly more local decreased flow compared to staples ($P < 0.0001$).

Conclusion: These findings demonstrate the relative feasibility of using LSI for preoperative vascular flow assessment in planning complex incision closure. These data also provide preliminary support for the hypothesis that skin closure itself causes relative ischemia compared to deep approximation or cautery of the skin edge and that the relative ischemia from staples closure is generally less than from suture closure.

Keywords: Laser speckle imaging, Neurosurgical procedure, Scalp flap, Wound ischemia

INTRODUCTION

The scalp is one of the most highly vascularized skin surfaces on the body and so typically heals well after cranial incisions and trauma.^[5] Most closure techniques, however, carry the risk of creating a relatively ischemic zone in the region of the skin edges, which can lead to delayed healing or infection, with unfavorable cosmetic result such as scarring and alopecia.^[15,21,25] In recurrent cases or cases postradiation, the skin edges may be particularly vulnerable to wound breakdown.^[14]

“Standard” neurosurgical closure after craniotomy typically involves the placement of absorbable galeal sutures followed by suture or staple closure of the skin edge. Recent reports of alternative techniques including skin adhesives,^[3,23] absorbable skin sutures,^[13,17] or single layer closure^[1]

This is an open-access article distributed under the terms of the Creative Commons Attribution-Non Commercial-Share Alike 4.0 License, which allows others to remix, tweak, and build upon the work non-commercially, as long as the author is credited and the new creations are licensed under the identical terms.

©2021 Published by Scientific Scholar on behalf of Surgical Neurology International

have shown promising results. The closure must be balanced with strength to avoid breakdown or stretching of the scar versus local ischemia resulting in necrosis and related complications.^[6]

To measure the degree of relative ischemia caused by skin closure, we explored the potential utility of intraoperative surface blood flow measurement with laser speckle imaging (LSI). LSI uses the principle of light scatter from moving blood in tissue, which allows for semi-quantitative measurements of blood flow within an imaging field. To date, surface perfusion with LSI has been utilized in several different fields. These include skin perfusion during Raynaud's phenomenon,^[4] assessing the effects of revascularization on foot blood,^[10] and predicting wound outcomes after burn injury.^[12] In neurosurgery, LSI has been used for the assessment of the cortical surface in several applications; however, to the best of our knowledge, it has not been applied to assessing scalp closure techniques.^[7,9,11,16,18-20,22] We describe our preliminary experience with the use of LSI in neurosurgical scalp closure.

MATERIALS AND METHODS

Study design

We prospectively enrolled eight subjects into an observational study using intraoperative LSI during elective cranial neurosurgical procedures (UNM-HRPO-12-192). Within that study, LSI recordings were obtained at various stages of the surgery at the discretion of the attending surgeon (preincision, brain cortex, postclosure, etc.).

Participants

For this study, we identified subjects who had imaging performed of the skin closure. We did not collect any linked outcome data as this was a pilot, proof of concept study.

Interventions

A commercially available, clinical LSI system was used to acquire data (Moor FLPI [full-field laser perfusion imager]: Moor Instruments, Ltd., UK). The camera was draped with a clear sterile cover and positioned above the surgical field. Zoom and focus settings are then adjusted to obtain a clear image of the field. The lens polarizer can be adjusted to reduce glare. Measurements were obtained using the moorFLPI measurement v3.0 program.

Data collection and analysis

All recordings were made using a 4 ms exposure time with spatial resolution mode. Kernel size 5×5 , sample interval 40 ms with the default sample rate of 25 Hz. The acquisition program automatically restricts direct current (DC) so that

values >200 (caused by reflection or static objects like staples) are excluded from analysis. Similarly, any background data below the lower defined DC threshold are excluded from analysis. This approach ensures that inaccurate regions are excluded from analysis. Measurements were obtained for durations ranging 30 s to several minutes. When the response to an intervention was being examined (such as tightening sutures), the imaging was reviewed in real time to aid in decision-making regarding the degree of skin edge ischemia.

Analysis of the flux data was performed using the moorFLPI review v 4.0 program as anonymized files per our pilot protocol. For the seven subjects with LSI performed at the time of skin closure, we first identified a region of interest (ROI) around the entire closure line where there were valid flux data. We then made an adjacent, similarly sized ROI on the scalp just anterior to the closure line for internal comparison. These files were then exported to the Moor graphing program. Temporal regions were then identified that were relatively free of motion artifact and statistical analysis was performed for the spatial ROIs in these regions. These were exported as mean flux. Standard deviations were compared across subjects.

In one patient, LSI was used clinically to assess the scalp viability and closure methods due to several previous surgeries. In this patient, there were several comparative assessments made between sutures and staples in regions of the closure. To quantify these interventions, we made regions of interest along the suture/staple line. We then extracted time-based regions of interest with the mean and standard deviation of flux within that time and compared during different interventions.

Statistical methods

We extracted the mean flux, standard deviation of the flux, and duration of this "clean" recording. We exported these data to Prism (v9.0.0) and used these two ROIs to calculate the percent reduction/increase in flow (1-9ROI1/ROI2). We then calculated mean and standard deviation of these reductions between the three closure methods and compared sutures versus staples using an unpaired *t*-test. Other descriptive analysis was performed for the preincision and complex closure case. Ordinary one-way ANOVA was used to assess for differences in flux during different closure maneuvers (i.e., tightening versus loosening). In addition, multiple comparisons were made between each maneuver using Tukey's correction.

RESULTS

Demographics

Eight subjects were identified with scalp flow imaging for this pilot study [Table 1]. Three subjects had an aneurysm clipping,

two 1st time tumor resections, one multiple redo tumor resection, one STA-MCA bypass, and one temporal lobectomy.

Preincision flow

In one subject, we obtained a preincision flow study [Figure 1], which demonstrates the pulsatile flow within the branches of the superficial temporal artery (STA) [Video 1].

First-time incision

Seven of these were 1st time, supratentorial skin incisions and were used for comparison. Three underwent suture

closure, three underwent staple closure, and one had skin imaging after galeal sutures but before skin closure [Figure 2]. The mean flux within the suture ROIs was 72 (St. Dev., 93.5) (unlabeled flux units). When compared to the control region anterior to the closure line, there was a mean 63.7% reduction in flow across all seven subjects (range 18.7–95.32%). When comparing by closure type, we found a significantly higher flow reduction in the three subjects with suture closure (80.7% reduction) compared to staple closure (61.9% reduction, $P = 0.0379$) (difference of means=18.8, SEM ± 6.155). The one subject with a galeal closure only had the least reduction in flow (18.7% reduction).

Table 1: Subjects and measurements.

Subject	Procedure	Mean flux along incision (SD)	Mean flux anterior to incision (SD)	Reduction in flow along incision line	Duration of clean recording (sec)	Closure technique
1	Aneurysm clipping	14 (0.8)	70.4 (7)	-80.11%	31	Sutures
2	STA-MCA bypass	274.2 (6.4)	573.1 (8.7)	-52.15%	10	Staples
3*	Temporal lobectomy	98.9 (4.9)	121.7 (3.6)	-18.73%	26	Galea*
4	Tumor resection	36.6 (3.8)	80 (3.9)	-54.25%	27	Staples
5	Aneurysm clipping	46.2 (5.7)	141 (30.7)	-67.23%	21	Staples
6	Aneurysm clipping	23.6 (23.6)	108.9 (9.1)	-78.33%	22	Sutures
7	Tumor resection	15.1 (1)	322.5 (18.5)	-95.32%	26	Sutures
8	Multiple redo tumor resection	N/A	N/A	N/A	N/A	Complex

*In this subject, closure measurements were obtained after closure of galea and before any skin closure. SD=Standard deviation, STA-MCA=Superficial temporal artery to middle cerebral artery

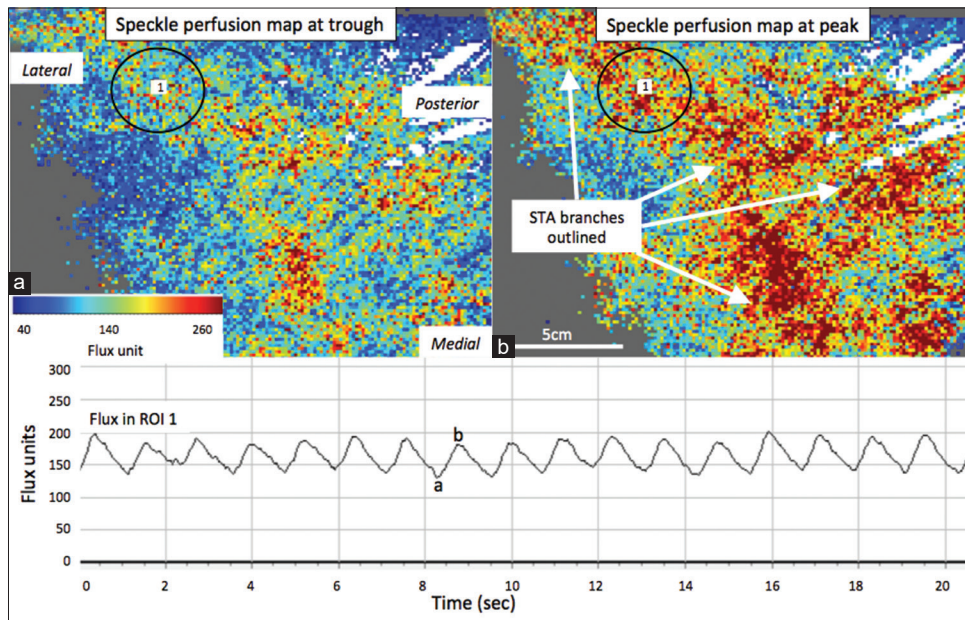


Figure 1: Preincision perfusion study demonstrating the pulsatile flow within the branches of the superficial temporal artery (STA). Black circle with the number 1 inside represents the region of interest (ROI) used for analysis. (a) STA regional surface flow at the trough (b) STA regional surface flow at peak. The graph demonstrates the flow measurements of the scalp at ROI 1, with each pulsation corresponding with the expected heart rate at 1/s. X-axis is the time in seconds and the Y is flux units.

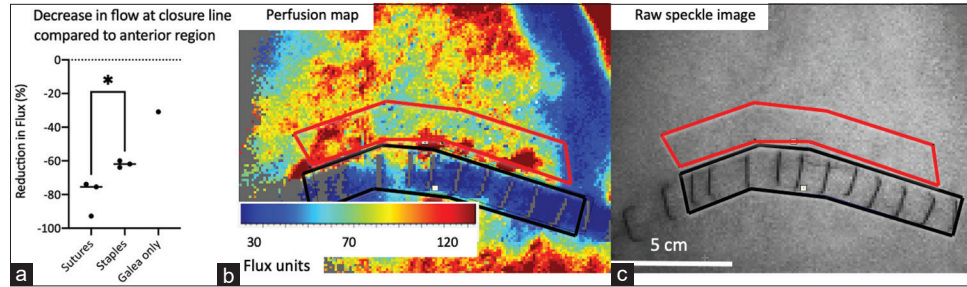


Figure 2: Mean decrease in perfusion along incision compared to scalp anterior to closure. (a) Graph demonstrating the decrease in blood flow along the incision compared to the scalp anterior to the closure in subjects receiving sutures ($n = 3$) versus staples ($n = 3$) versus galea ($n = 1$). The mean flux within the suture region of interest (ROI) was 72 (St. Dev., 93.5) (unlabeled flux units). When compared to the control region anterior to the closure line, there was a mean 63.7% reduction in flow across all seven subjects (range 18.7–95.32%). When comparing by closure type, we found a significantly higher flow reduction in the three subjects with suture closure (80.7% reduction) compared to staple closure (61.9% reduction, $P = 0.0379$) (difference of means = 18.8 ± 6.155). The one subject with galeal closure only had the least reduction in flow (18.7% reduction). (b) Flux/perfusion map and corresponding (c) raw speckle image that marks out the incision with a black box ROI and the comparative anterior region in a red box ROI.

Complex incision

One subject had a complex wound due to multiple previous tumor operations, creating an “H” like configuration near the center of the wound. LSI was used during the closure to assess for flap and skin edge integrity [Figure 3], [Table 2], [Video 2]. Since the closure was revised several times to attempt to create the least ischemic closure, we longitudinally analyzed several interventions. Measurements were obtained after suturing and after tightening the sutures. This created a concerning region of relative ischemia, so the sutures were completely released and replaced by staples [Video 2]. These internal comparisons demonstrated a statistically significant difference in mean flow between each of these interventions ($P < 0.0001$, one-way ANOVA); though, the ultimate staple placement was within 3% of the flow measured after initial suture placement but before tightening. Tightening sutures resulted in 23% reduction in flow, while complete release resulted in 60% increase in flow. Raw flux measurements are shown in [Figure 3] and [Table 2].

DISCUSSION

Preincision flow

We demonstrated how LSI can be used to demonstrate the pulsatile flow within the branches of the STA, which can be useful in terms of incision planning both for procedures involving the STA, such as bypass, but also for planning skin flap perfusion in large flaps or redo cases.

Scalp closure

We have demonstrated the use of LSI in the intraoperative period to assess cranial wound closure. The one subject with galeal closure only had the least reduction in flow (18.7% reduction), supporting the hypothesis that the skin

closure itself causes relative ischemia compared to deep approximation or cautery of the skin edge, and the relative ischemia from staples is generally less than from suturing. Most of our cases were 1st time incisions; and despite very small numbers, it appears that staples seem to show less variability and less relative ischemia compared to running sutures. We also demonstrate the use of LSI to assess flap and skin edge viability in a complex case of multiple redo surgery, where we replaced sutures with staples, due to the lower degree of relative ischemia at the vulnerable skin edge.

LSI

LSI has been used to assess wound healing in several other clinical settings. Perfusion has been related to healing outcomes, particularly after burn injuries.^[12] In addition, the utility of such imaging has been demonstrated in peripheral wound healing after revascularization^[10] and in regional free flap vascularization.^[8] Although not previously used in scalp wounds to our knowledge, the technique has significant potential utility for both immediate and longitudinal assessments of complex wound closures and flaps. In addition, regional perfusion may represent a physiological marker to assess newer closure techniques and adjuncts, such as negative pressure therapy, given that frank wound breakdown is fortunately uncommon and may be multifactorial.^[2,26]

LSI application to neurosurgical blood flow assessment has also been applied to the cortical surface, given that such measurement has significant potential applications in surgical decision-making.^[7,9,18,20] The accuracy of LSI had been validated with IMP-SPECT balloon test occlusion during carotid trapping and bypass surgery.^[16] The semi-quantitative, tissue level flow has some advantages over more widely used techniques, such as IC green angiography,

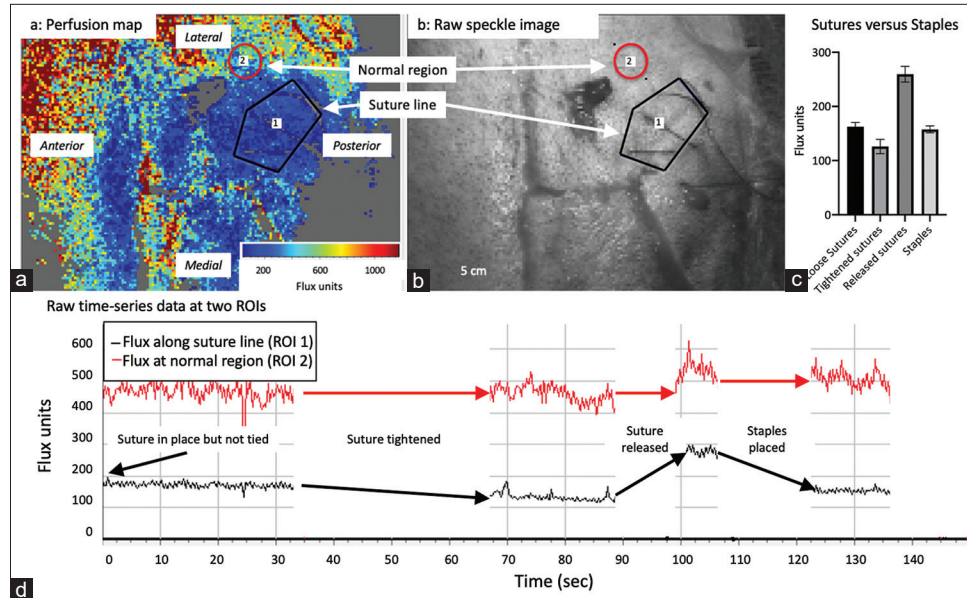


Figure 3: Perfusion study of a complex wound analyzed longitudinally over several interventions. (a) Perfusion map and corresponding (b) raw speckle image that marks the incision with a black box (ROI 1) and the comparative anterior region in a red circle (ROI 2). (c) Graph demonstrating difference in raw flux measurements between suture interventions (loose, tightened, and released) and staple blood flow. A statistically significant difference in mean flow between each of these interventions ($P < 0.0001$, one-way ANOVA) was found. The mean flux included tightened sutures (126), released sutures (259.7), and staples (157.7) (d) Raw time series data demonstrating the longitudinal flux data from both ROIs over multiple interventions in panel c. These data demonstrate the lack of changes in the control (red) region. Tightening sutures resulted in 23% reduction in flow while complete release resulted in 60% increase in flow. X-axis is the time in seconds and the Y is flux units.

Table 2: Comparison of sutures versus staples in complex revision round.

Tukey's multiple comparisons test	Mean Diff.	95.00% CI of diff.	Adjusted P Value
Loose Sutures vs. Tightened sutures	36.70	29.82 to 43.58	<0.0001
Loose Sutures vs. Released sutures	-97.00	-107.3 to -86.67	<0.0001
Loose Sutures vs. Staples	5.000	-2.774 to 12.77	0.3373
Tightened sutures vs. Released sutures	-133.7	-144.4 to -123.0	<0.0001
Tightened sutures vs. Staples	-31.70	-40.00 to -23.40	<0.0001
Released sutures vs. Staples	102.0	90.67 to 113.3	<0.0001

which is better suited for direct vascular imaging.^[19,22] Increases in flow have also been observed after motor excitation during awake mapping surgery.^[11] Other vascular applications include the ability to predict the infarct core after malignant hemispheric stroke^[7] and to observe the presence of spreading depolarization around such infarcts.^[24]

It is not currently known if LSI imaging would provide cost-effective feedback regarding scalp closure and clearly further studies are needed. The unit we use costs in the range of \$50–60,000, so to be a cost-effective solution, would have to demonstrate a significant benefit in reducing infection or return to the OR. The same machine, however, can be used for multiple clinical and research applications, described above, across departments.

Limitations

Our study has significant limitations and should be viewed primarily as a proof of concept study regarding the potential utility of LSI in cranial wound assessment and healing. There was not one standardized type of neurosurgical incision used for comparison between subjects. Furthermore, there was no comparison on the patients' baseline demographics, such as age, diabetes, or vasculopathies that could change vascular blood flow and healing in the participants. We did not record wound outcomes in these subjects, and the wound closure technique was performed at the discretion of the attending surgeon. Due to the semi-quantitative nature of the measurements, it is unknown if these relative reductions in blood flow reach truly ischemic levels. In addition, we only obtained these measurements at one intraoperative

time point, though longitudinal measurement will be very important to integrate into future studies.

CONCLUSION

These findings demonstrate the relative feasibility of using LSI for scalp vascular flow assessment in planning complex incision closure. It also supports the hypothesis that skin closure itself causes relative ischemia compared to deep approximation or cautery of the skin edge, and the relative ischemia from staples closure is generally less than from suture closure.

Declaration of patient consent

The authors certify that they have obtained all appropriate patient consent.

Financial support and sponsorship

Nil.

Conflicts of interest

There are no conflicts of interest.

REFERENCES

- Adeolu AA, Olabanji JK, Komolafe EO, Ademuyiwa AO, Awe AO, Oladele AO. A prospective study of two methods of closing surgical scalp wounds. *Br J Neurosurg* 2012;26:75-7.
- Bi H, Khan M, Li J, Pestana IA. Use of incisional negative pressure wound therapy in skin-containing free tissue transfer. *J Reconstr Microsurg* 2018;34:200-5.
- Chibbaro S, Tacconi L. Use of skin glue versus traditional wound closure methods in brain surgery: A prospective, randomized, controlled study. *J Clin Neurosci* 2009;16:535-9.
- Della Rossa A, Cazzato M, d'Ascanio A, Tavoni A, Bencivelli W, Pepe P, *et al.* Alteration of microcirculation is a hallmark of very early systemic sclerosis patients: A laser speckle contrast analysis. *Clin Exp Rheumatol* 2013;31 Suppl 76:109-14.
- Desai SC, Sand JP, Sharon JD, Branham G, Nussenbaum B. Scalp reconstruction: An algorithmic approach and systematic review. *JAMA Facial Plast Surg* 2015;17:56-66.
- Frechet P. Minimal scars for scalp surgery. *Dermatol Surg* 2007;33:45-55; discussion 55-6.
- Hecht N, Muller MM, Sandow N, Pinczolits A, Vajkoczy P, Woitzik J. Infarct prediction by intraoperative laser speckle imaging in patients with malignant hemispheric stroke. *J Cereb Blood Flow Metab* 2016;36:1022-32.
- Howdieshell TR, McGuire L, Maestas J, McGuire PG. Pattern recognition receptor gene expression in ischemia-induced flap revascularization. *Surgery* 2011;150:418-28.
- Ideguchi M, Kajiwara K, Yoshikawa K, Goto H, Sugimoto K, Inoue T, *et al.* Avoidance of ischemic complications after resection of a brain lesion based on intraoperative real-time recognition of the vasculature using laser speckle flow imaging. *J Neurosurg* 2017;126:274-80.
- Kikuchi S, Miyake K, Tada Y, Uchida D, Koya A, Saito Y, *et al.* Laser speckle flowgraphy can also be used to show dynamic changes in the blood flow of the skin of the foot after surgical revascularization. *Vascular* 2019;27:242-51.
- Klijn E, Hulscher HC, Balvers RK, Holland WP, Bakker J, Vincent AJ, *et al.* Laser speckle imaging identification of increases in cortical microcirculatory blood flow induced by motor activity during awake craniotomy. *J Neurosurg* 2013;118:280-6.
- Mirdell R, Farnebo S, Sjoberg F, Tesselaar E. Using blood flow pulsatility to improve the accuracy of laser speckle contrast imaging in the assessment of burns. *Burns* 2020;46:1398-406.
- Missori P, Polli FM, Fontana E, Delfini R. Closure of skin or scalp with absorbable sutures. *Plast Reconstr Surg* 2003;112:924-5.
- Nair S, Giannakopoulos G, Granick M, Solomon M, McCormack T, Black P. Surgical management of radiated scalp in patients with recurrent glioma. *Neurosurgery* 1994;34:103-6; discussion 106-7.
- Nitta N, Fukami T, Nozaki K. Electrocautery skin incision for neurosurgery procedures-technical note. *Neurol Med Chir (Tokyo)* 2011;51:88-91.
- Nomura S, Inoue T, Ishihara H, Koizumi H, Suehiro E, Oka F, *et al.* Reliability of laser speckle flow imaging for intraoperative monitoring of cerebral blood flow during cerebrovascular surgery: Comparison with cerebral blood flow measurement by single photon emission computed tomography. *World Neurosurg* 2014;82:e753-7.
- Paolini S, Morace R, Lanzino G, Missori P, Nano G, Cantore G, *et al.* Absorbable intradermal closure of elective craniotomy wounds. *Neurosurgery* 2008;62 Suppl 2:ONS490-2; discussion ONS492.
- Parthasarathy AB, Weber EL, Richards LM, Fox DJ, Dunn AK. Laser speckle contrast imaging of cerebral blood flow in humans during neurosurgery: A pilot clinical study. *J Biomed Opt* 2010;15:066030.
- Prinz V, Hecht N, Kato N, Vajkoczy P. FLOW 800 allows visualization of hemodynamic changes after extracranial-to-intracranial bypass surgery but not assessment of quantitative perfusion or flow. *Neurosurgery* 2014;10 Suppl 2:231-8; discussion 238-9.
- Richards LM, Kazmi SS, Olin KE, Waldron JS, Fox DJ Jr, Dunn AK. Intraoperative multi-exposure speckle imaging of cerebral blood flow. *J Cereb Blood Flow Metab* 2017;37:3097-109.
- Sittitavornwong S, Morlandt AB. Reconstruction of the scalp, calvarium, and frontal sinus. *Oral Maxillofac Surg Clin North Am* 2013;25:105-29.
- Valdes PA, Roberts DW, Lu FK, Golby A. Optical technologies for intraoperative neurosurgical guidance. *Neurosurg Focus* 2016;40:E8.
- Wang MY, Levy ML, Mittler MA, Liu CY, Johnston S, McComb JG. A prospective analysis of the use of octylcyanoacrylate tissue adhesive for wound closure in pediatric neurosurgery. *Pediatr Neurosurg* 1999;30:186-8.
- Woitzik J, Hecht N, Pinczolits A, Sandow N, Major S, Winkler MK, *et al.* Propagation of cortical spreading depolarization in the human cortex after malignant stroke.

- Neurology 2013;80:1095-102.
25. Yokoyama R, Mikami T, Ukai R, Komatsu K, Kimura Y, Suzuki H, *et al.* Interdisciplinary prevention and management of wound-related complications in extracranial-to-intracranial bypass surgery. *World Neurosurg* 2018;115:247-53.
26. Zhai Z, Yu L, Ren T, Jin X, Yang X, Qi Z. Use of vacuum-assisted wound closure and tissue expansion in revision cranioplasty for a large-sized composite defect in a child. *J Craniofac Surg* 2019;30:838-40.

How to cite this article: Carlson AP, Denezpi T, Akbik OS, Mohammad LM. Laser speckle imaging to evaluate scalp flap blood flow during closure in neurosurgical procedures. *Surg Neurol Int* 2021;12:632.