

Received: 2020.12.09


Accepted: 2021.02.18

Available online: 2021.04.30

Published: 2021.06.04

Diagnosis and Management of Left Ventricular Perforation During Mapping of Ventricular Tachycardia

Authors' Contribution:

Study Design A
Data Collection B
Statistical Analysis C
Data Interpretation D
Manuscript Preparation E
Literature Search F
Funds Collection GABCDEF 1,2 **Sorin Ștefan Popescu**
ABCDEF 1 **Christian-Hendrik Heeger**
ABCDEF 1 **Karl-Heinz Kuck**
ABCDEF 1 **Roland Richard Tilz**1 Department of Cardiology, Angiology and Intensive Care Medicine, University Heart Center Lübeck, Medical Clinic II, Lübeck, Germany
2 Faculty of Medicine, "Carol Davila" University of Medicine and Pharmacy, Bucharest, Romania**Corresponding Author:** Roland Richard Tilz, e-mail: tilz6@hotmail.com**Conflict of interest:** None declared**Patient:** Male, 70-year-old
Final Diagnosis: Ventricular perforation • ventricular tachycardia
Symptoms: Palpitation
Medication: —
Clinical Procedure: Left ventricular radiofrequency ablation
Specialty: Cardiac Surgery • Cardiology**Objective:** Unusual clinical course**Background:** Cardiac perforation leading to cardiac tamponade is one of the possible complications of endocardial mapping during catheter-based ablation procedures. The early diagnosis of catheter-induced perforation is critical for effective management of these patients. We hereby present the diagnosis and management of left ventricular perforation during mapping of ventricular tachycardia in a patient with left ventricular aneurysm.**Case Report:** A 70-year-old man with a history of ischemic heart disease, arterial hypertension, type 2 diabetes mellitus, and obesity was referred to our institution for the ablative treatment of recurrent, sustained monomorphic ventricular tachycardia that was resistant to medication. One particularity was the presence of a left ventricular aneurysm secondary to a non-ST segment elevation myocardial infarction, which was unusual and could increase the risk of cardiac perforation. During left ventricular mapping, several points were acquired in an apparently unusual position and the pericardial location of the mapping catheter was confirmed fluoroscopically. After setting a pericardial pigtail catheter, we successfully finished the ablation procedure using a second ablation catheter. The perforating catheter was thereafter removed by open surgery, and no significant bleeding occurred. The patient did not experience tachycardia during the follow-up period of 29 months.**Conclusions:** Left ventricular aneurysms might increase the cardiac perforation risk during endocardial mapping in ventricular tachycardia ablation procedures. In patients with this condition, a careful manipulation of the catheters could prevent such complications. The periodic fluoroscopic assessment of the catheter's position is essential for early recognition of the perforation.**Keywords:** Cardiac Tamponade • Catheter Ablation • Heart Ventricles • Pericardial Effusion • Tachycardia, VentricularFull-text PDF: <https://www.amjcaserep.com/abstract/index/idArt/930381> 1890 — 6 13

Background

Catheter ablation is a widely used technique for the treatment of ventricular tachycardia (VT) refractory to medical treatment in patients with structural and nonstructural heart disease. Its efficacy in reduction of appropriate implantable cardioverter defibrillator (ICD) shock incidence has been proven in randomized control trials, but the benefit on mortality has only been demonstrated in patients with VT storm [1]. Catheter-based ablation may be associated with complications including cardiac perforation in 1-2% of patients [2,3]. Most of the perforations are caused by a steam pop phenomenon, which refers to barotrauma due to excessive heating leading to production of gas during catheter ablation, or by complications related to transseptal punctures. However, a case of left ventricular (LV) perforation during endocardial mapping has been reported using a NOGA® XP needle-tipped catheter [4]. We describe the diagnosis and management of ventricular perforation without significant pericardial effusion during mapping of VT, in a patient with LV aneurysm due to anterior myocardial infarction 4 months previously.

Case Report

A 70-year-old man was referred to our institution for the treatment of recurrent, hemodynamically stable sustained

monomorphic VT (SMVT) resistant to medical treatment. The patient had a history of a non-ST segment elevation myocardial infarction 4 months prior to presentation, treated with placement of a drug-eluting stent in the left anterior descending coronary artery, hypertension, type 2 diabetes mellitus, and obesity. Despite revascularization, the patient was documented to have an ischemic cardiomyopathy with a LV ejection fraction of 38% and an antero-apical aneurysm, which is unusual after non-ST segment elevation myocardial infarction.

During hospitalization, the patient was documented to have an episode of self-terminating SMVT. An electrocardiogram during VT was recorded, showing a right bundle branch block morphology, with superior axis and negative QRS complexes from V2 to V6 (Figure 1), suggesting an LV apical origin.

After written informed consent of the patient was obtained, an electrophysiological study was conducted. The procedure was performed under deep sedation utilizing midazolam, fentanyl, and a continuous infusion of propofol. An arterial access was utilized for continuous invasive arterial blood pressure monitoring. A standard catheter was positioned in the right ventricle (RV) apex by a right femoral venous approach. The LV access was obtained via a single transseptal approach via the right femoral vein under fluoroscopic guidance, using a modified Brockenbrough technique and an 8.5F transseptal sheath (SL1). Heparin was administered after transseptal puncture to

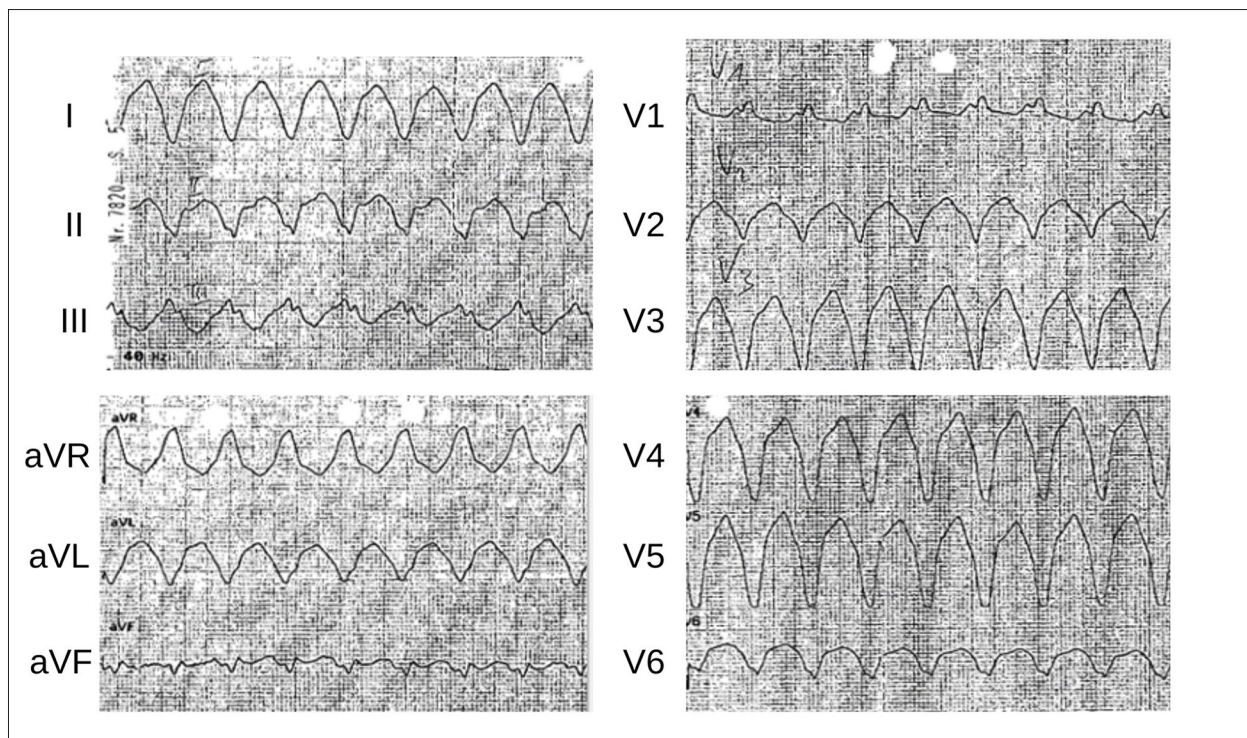


Figure 1. The 12-lead surface electrocardiogram showing monomorphic ventricular tachycardia, with right bundle branch block morphology, superior axis, negative QRS complexes from V2 to V6, and a cycle length of 290 ms.

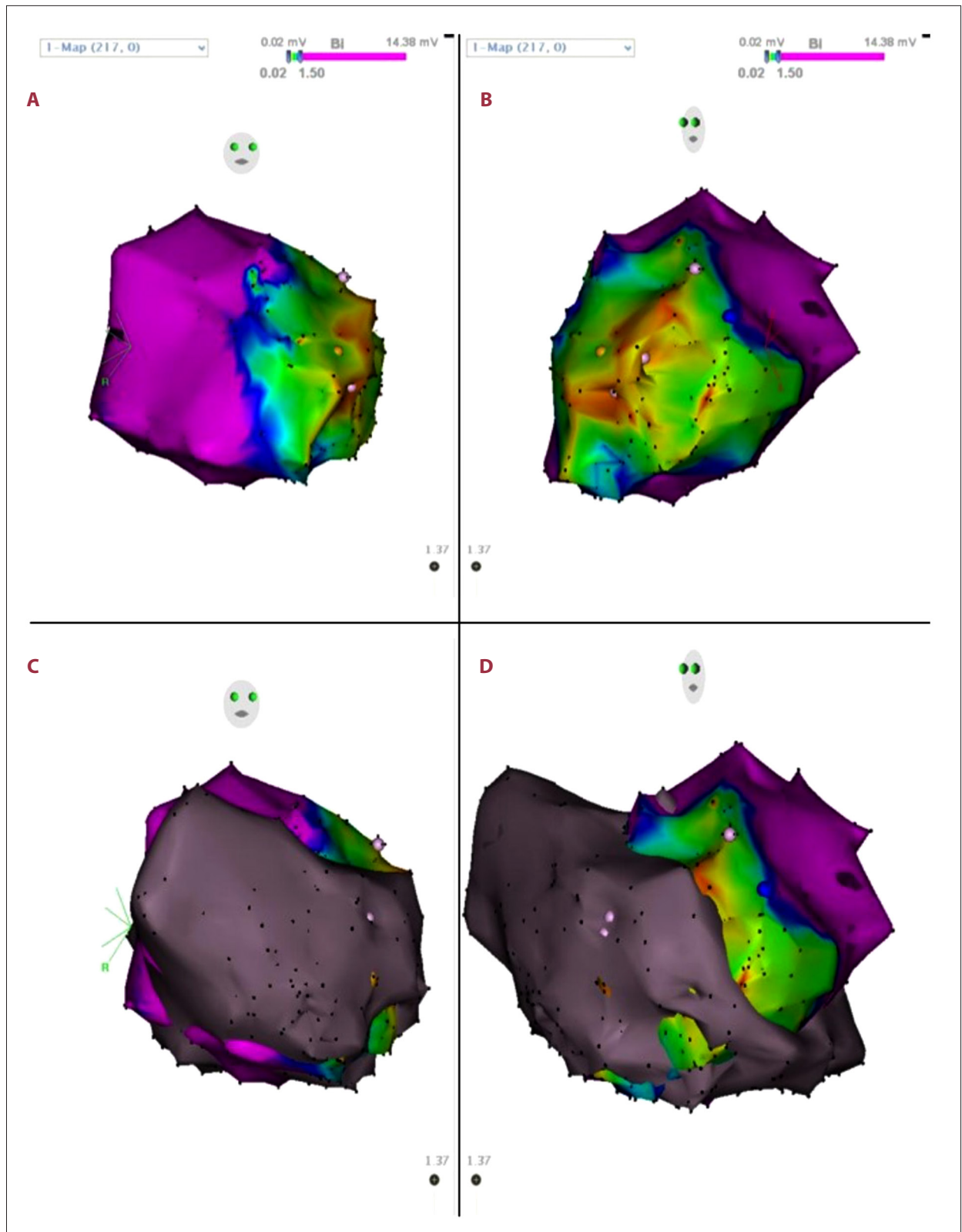


Figure 2. Voltage mapping of the left ventricle in right anterior oblique (RAO) view (A) and left anterior oblique (LAO) view (B), showing the low-voltage areas located at the anterior aspect. (C) RAO view and (D) LAO view of the left ventricular voltage map and the anatomical map of the pericardial space acquired after left ventricular perforation (gray area).

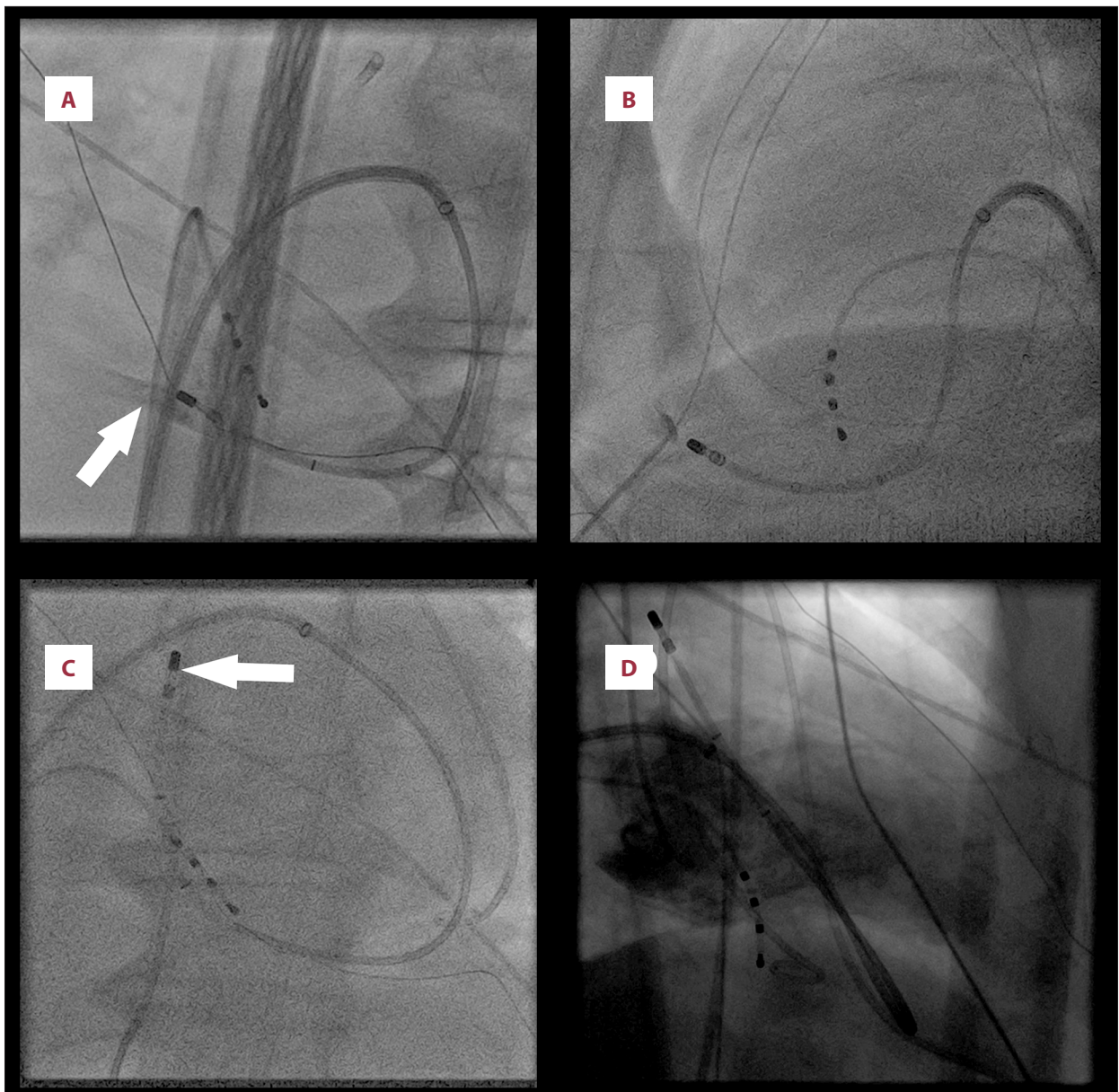


Figure 3. (A) Fluoroscopic left anterior oblique 40° view showing the abnormal position of the ablation catheter outside the cardiac silhouette. The white arrow indicates the contrast in the pericardial space after injection through the irrigation port of the ablation catheter. (B) Guidewire in the pericardial space during dry epicardial puncture procedure. (C) Ablation catheter advanced in the pericardial space to maintain occlusion of the aperture in the left ventricular wall. (D) Left ventricular angiography confirming the absence of ventricular leak.

maintain an activated clotting time of ≥ 300 s. The transseptal sheath was continuously irrigated with heparinized saline [5,6].

In a first step, a diagnostic electrophysiological study was conducted and VT identical to the patient's presenting arrhythmia was induced by RV programmed stimulation and terminated by overdrive pacing.

Point by point 3-dimensional electroanatomical mapping of the LV was performed using the CARTO system (Biosense Webster, Diamond Bar, CA, USA). Mapping and ablation were achieved using a 3.5-mm irrigated-tip, contact force-sensing catheter (ThermoCool SmartTouch, Biosense Webster). Bipolar endocardial voltage of ≥ 1.5 mV was considered normal. Late potentials were predefined as any low voltage electrogram (< 1.5 mV) with a single component or with multiple continuous delayed components separated from the higher amplitude component

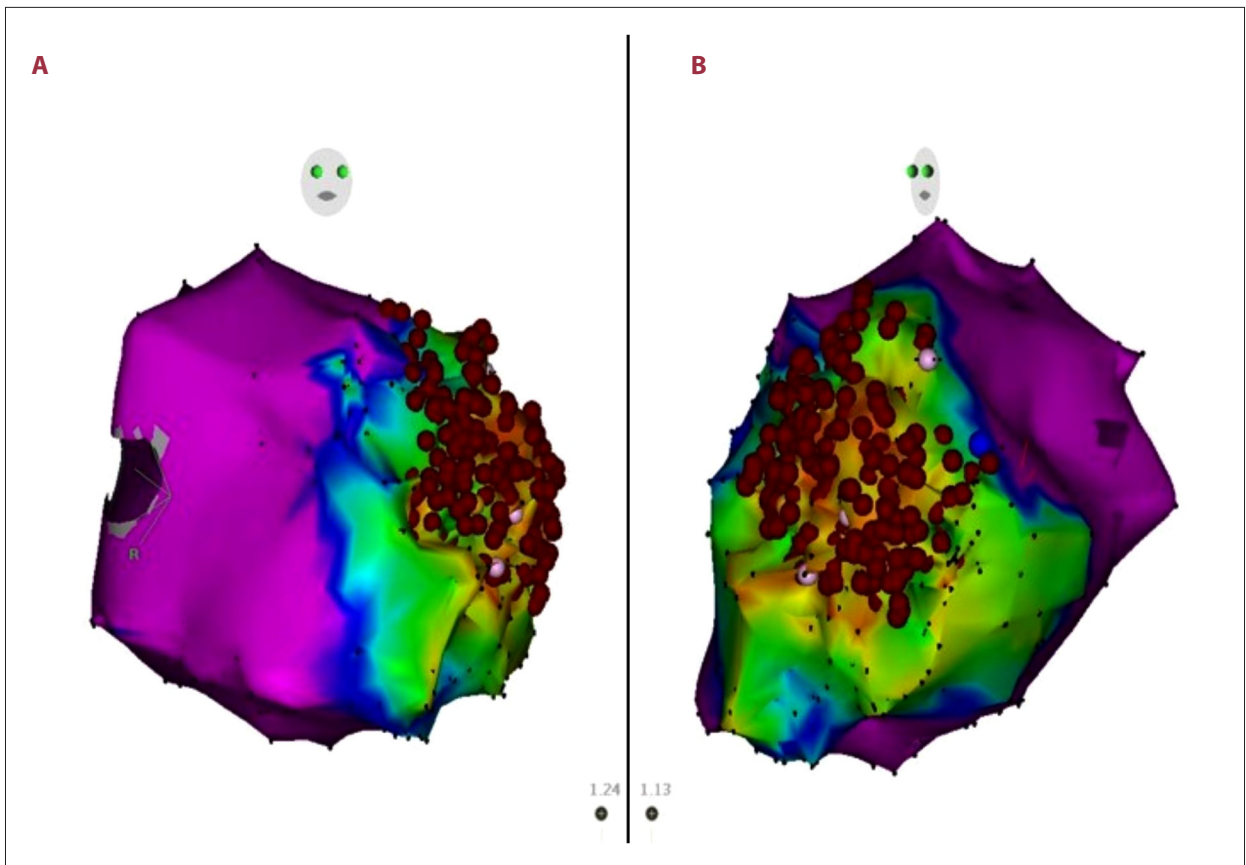


Figure 4. (A) Right anterior oblique view and (B) left anterior oblique view of the first left ventricular voltage map showing the superimposed ablation points at the end of the procedure.

of the local ventricular electrogram by ≥ 20 ms and recorded after the end of the surface QRS [7,8]. The resultant voltage map showed the arrhythmogenic substrate at the antero-apical aspect of the LV (Figure 2A, 2B). Moreover, a concordant pacemap (12/12) was obtained in the same region.

During LV mapping, several mapping points were acquired in unusual locations (Figure 2C, 2D). While checking the catheter position using fluoroscopy in a left anterior oblique 40° view, an abnormal location of the ablation catheter was observed (Figure 3A), suggesting that the catheter was situated outside the cardiac silhouette. In order to confirm this position, 5 mL of contrast was injected through the irrigation port demonstrating evidence of catheter perforation and pericardial cavity staining (Figure 3A). Immediately, a transthoracic echocardiogram was performed, which did not document an effusion in the pericardial space. The LV systolic function was unchanged.

After dry epicardial puncture was achieved under fluoroscopic guidance as a back-up maneuver in case of bleeding complications (Figure 3B), the mapping catheter was advanced to maintain the myocardial puncture site occluded (Figure 3C). Aspiration attempt through the drainage catheter confirmed

the absence of pericardial effusion, and the patient remained hemodynamically stable. LV angiography was performed and did not demonstrate a residual ventricular leak (Figure 3D). The total volume of blood suctioned from the pericardial space by multiple aspirations throughout the procedure was about 200 mL.

Given the frequent recurrences of the VT episodes and the presence of ischemic heart disease, it was decided to continue the procedure with cardiothoracic surgical backup. LV access was then obtained, this time using a retrograde, femoral artery approach. Another 3.5-mm irrigated-tip, contact force-sensing ablation catheter (ThermoCool SmartTouch, Biosense Webster) was placed into the LV, while the first catheter was left in place in order to maintain hemostasis. The ablation procedure was completed successfully at the anterior aspect of the LV, within the area displaying late potentials, utilizing the former voltage map (Figure 4A, 4B). The ablation was performed using contact force guidance, a power limited to 30-50 W. No steam pops or sudden changes of impedance were noted, and the hemodynamic parameters remained normal throughout the procedure. After completion of LV ablation, noninducibility of VT was confirmed by programmed and burst electrical

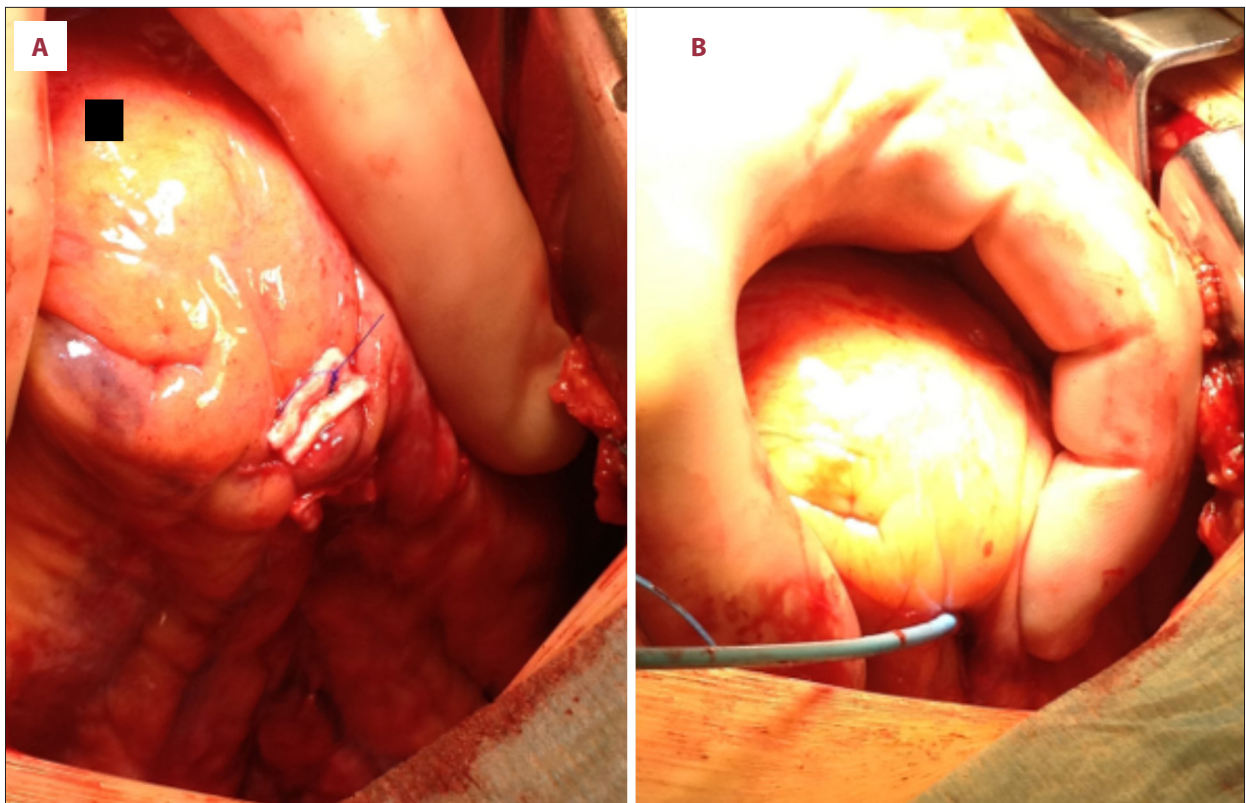


Figure 5. Intraoperative images. (A) Wall breach closed with mattress sutures over pledgets. (B) Ablation catheter perforation site at the apex of the left ventricle and no signs of pericardial bleeding.

stimulation from both the RV and the LV, with and without isoproterenol infusion. All the vascular catheters, other than the perforating one, were removed and the patient was transferred to the operating room.

The patient underwent open removal of the first catheter that resulted in LV perforation using an open thoracotomy approach. The puncture site was closed using mattress sutures with pledgets (Figure 5A). The catheter perforation site was found at the apical aspect of the LV. There was no evidence of significant residual bleeding into the pericardial cavity (Figure 5B). A pericardial drainage catheter was left in place for 2 more days and no further pericardial bleeding was documented.

Beta-blocker treatment was initiated, and an ICD was implanted 6 days after surgery. In a follow-up period of 29 months, the patient has remained free of ICD events, with beta-blocker therapy only.

Discussion

The incidence of pericardial effusion and cardiac tamponade after VT or premature ventricular contractions (PVC) ablation is 1-2% [2,3]. It is generally perceived that the perforation risk

in atrial ablation is higher than in ventricular procedures, due to differences in wall thickness, although many studies reported similar risks in both types of procedures [3,9]. Moreover, the risk of RV perforation is significantly higher than that of LV perforation [9]. In most cases, the ventricular perforation occurs during radiofrequency application and is often associated with the steam pop phenomenon [9]. In our case, the perforation occurred during LV mapping before any ablation attempt. There are several reports of cardiac perforation with catheter positioning or mapping [4,9,10]. Wu and Dong [10] described a LV apical incomplete perforation during mapping. In their report an abnormal catheter position was recognized before entering the pericardial space. While no pericardial bleeding was documented, the procedure was aborted after finding the abnormal catheter position. Sharma et al [4] described a case of LV perforation during endocardial mapping using the NOGA® XP Cardiac Navigation System. This system has been used to create electromechanical mapping and to identify chronically ischemic or viable myocardium in patients with coronary artery disease. The catheter used for this type of procedures is different from that used for RF ablation, being equipped with a small needle in its tip. The ThermoCool SmartTouch catheter utilized during our procedure has an 8F outer diameter and a blunt electrode tip of 3.5 mm (Figure 6). However, the authors did not provide information regarding the management of this complication [4].




Figure 6. The ThermoCool SmartTouch catheter with a 3.5-mm blunt tip and an outer diameter of 8F.

Tokuda et al [9], comparing their series of patients undergoing VT or PVC catheter ablation with other reports of cardiac tamponade after atrial catheter ablation, suggested that patients with ventricular perforation are at higher risk of requiring surgical repair than those with atrial perforation. Another particularity of our case is that even if the perforation was located in the LV, the pericardial effusion was minimal and self-limited. As LV perforation was not associated with hemodynamic compromise, the fluoroscopic assessment of the catheter's position was the cornerstone of promptly detecting its abnormal location. After the absence of ventricular leak was demonstrated, the first mapping catheter was left in place until surgical closure could be performed because removal of this catheter could have resulted in uncontrolled intrapericardial bleeding. However, after the ablation catheter was extracted under direct observation of the surgical team, the aperture remained closed and no sign of hemorrhage appeared. In this case, the surgical closure of the perforation site was performed as a precaution instead of a mandatory step.

One more important aspect in our patient was the fact that even if the complete perforation had been confirmed, the procedure would have been continued with the back-up measure of setting a pigtail pericardial drainage, in order to prevent an eventual cardiac tamponade in case of massive hemorrhage. Furthermore, the patient remained free of ICD events for the 29 months follow-up period, suggesting the success of the intervention.

In the current case, the absence of excessive tip-tissue contact shown by the contact force-sensing catheter as well as the preserved homodynamic stability after perforation led to a protracted period prior to intrapericardial passage identification, as demonstrated by the multiple mapping points acquired in the pericardial cavity (**Figure 2C, 2D**).

Of note, the presence of ventricular aneurysms secondary to NSTEMI is unusual because the common cause of aneurysm formation is represented by the transmural myocardial infarction [11]. However, our patient did not have a history of ST-segment elevation myocardial infarction. In this case, we concluded that the ventricular aneurysm was secondary to NSTEMI. This theory is also sustained by the antero-apical location of the aneurysm, corresponding to the infarcted area.

Careful manipulation of the catheter is essential to prevent cardiac perforation. This prerequisite was even more important in the present case because LV aneurysms are prone to rupture, especially in the early phase of their evolution [11]. Six to 8 weeks after an infarction, during the late remodeling phase of the aneurysm formation, the infarcted area is replaced by fibrous tissue, but this region is still susceptible to rupture, even if less frequent than during the early expansion phase [11].

Another possible explanation for the ventricular perforation during electroanatomical mapping might be provided by the LV apical thin point theory. Bradfield et al [12] demonstrated the presence of a thin point located at the apex of the LV, with 97% of the dissected hearts from their study having a thickness of less than 2 mm at this site [12]. These results were further confirmed by imaging methods [13].

Conclusions

Physicians should be aware of the increased risk of LV perforation during endocardial mapping and ablation in patients with ventricular aneurysms. For this population, a careful manipulation of the ablation catheter is essential to avoid such complications. In those patients remaining hemodynamically stable after cardiac perforation, the fluoroscopic assessment of the catheter's position is crucial for the early recognition of the complication. In case of cardiac perforation, the insertion of a pigtail catheter, as well as good collaboration with the surgical team, is a key aspect of successful management.

References:

1. Sapp JL, Wells GA, Parkash R, et al. Ventricular tachycardia ablation versus escalation of antiarrhythmic drugs. *N Engl J Med*. 2016;375(2):111-21
2. Cheung JW, Yeo I, Ip JE, et al. Outcomes, costs, and 30-day readmissions after catheter ablation of myocardial infarct-associated ventricular tachycardia in the real world: Nationwide Readmissions Database 2010 to 2015. *Circ Arrhythm Electrophysiol*. 2018;11(11):e006754
3. Katsume Y, Ueda A, Mohri T, et al. Assessing the perforation site of cardiac tamponade during radiofrequency catheter ablation using gas analysis of pericardial effusion. *Heart Rhythm*. 2020;1(4):268-74
4. Sharma GK, Poulin MF, Schaer GL. Left ventricular perforation in a patient with a left ventricular aneurysm during NOGA® catheter mapping. *Cardiovasc Revasc Med*. 2018;19(8S):50-52
5. Heeger CH, Metzner A, Schlüter M, et al. Cerebral protection during catheter ablation of ventricular tachycardia in patients with ischemic heart disease. *J Am Heart Assoc*. 2018;7(13):e009005
6. Heeger CH, Hayashi K, Kuck KH, Ouyang F. Catheter ablation of idiopathic ventricular arrhythmias arising from the cardiac outflow tracts – recent insights and techniques for the successful treatment of common and challenging cases. *Circ J*. 2016;80(5):1073-86
7. Nakahara S, Tung R, Ramirez RJ, et al. Characterization of the arrhythmogenic substrate in ischemic and nonischemic cardiomyopathy implications for catheter ablation of hemodynamically unstable ventricular tachycardia. *J Am Coll Cardiol*. 2010;55(21):2355-65
8. Vergara P, Trevisi N, Ricco A, et al. Late potentials abolition as an additional technique for reduction of arrhythmia recurrence in scar related ventricular tachycardia ablation. *J Cardiovasc Electrophysiol*. 2012;23(6):621-27
9. Tokuda M, Kojodjojo P, Epstein LM, et al. Outcomes of cardiac perforation complicating catheter ablation of ventricular arrhythmias. *Circ Arrhythm Electrophysiol*. 2011;4(5):660-66
10. Wu JT, Dong JZ. Unusual perforation of the left ventricle during radiofrequency catheter ablation for ventricular tachycardia. *Cardiovasc J Afr*. 2014;25(2):e1-4
11. Sattar Y, Alraies MC. Ventricular aneurysm. 2020 Nov 26. In: StatPearls [Internet]. Treasure Island (FL): StatPearls Publishing; 2020 Jan
12. Bradfield JW, Beck G, Vecht RJ. Left ventricular apical thin point. *Br Heart J*. 1977;39(7):806-9
13. Ferencik M, Abbara S, Hoffmann U, et al. Left ventricular thin-point detection using multidetector spiral computed tomography. *Am J Cardiol*. 2004;93(7):949-51