



Special requirements for TNM-staging in esophageal cancer

Magnus Sundbom[^], Gustav Linder[^]

Department of Surgical Sciences, Uppsala University, University Hospital, Uppsala, Sweden

Correspondence to: Magnus Sundbom, MD, PhD. Adjunct Professor of Surgery and Head of Gastroesophageal Surgery, Department of Surgical Sciences, Uppsala University, University Hospital, Entrance 70, SE-751 85 Uppsala, Sweden. Email: magnus.sundbom@surgsci.uu.se.

Comment on: Leng X, Kurita D, Zhu Y, *et al.* Collaborative multidisciplinary management and expertise of cT2-3 locally advanced operable esophageal squamous cell carcinoma: a report of two cases. *J Thorac Dis* 2023;15:6362-72.

Keywords: Esophagus; cancer; staging

Submitted Dec 13, 2023. Accepted for publication Apr 26, 2024. Published online May 30, 2024.

doi: 10.21037/jtd-23-1898

View this article at: <https://dx.doi.org/10.21037/jtd-23-1898>

In the present paper (1), Leng *et al.* have evaluated the multidisciplinary management of operable clinical T2–3 esophageal squamous cell carcinomas (ESCCs) by presenting two case reports to several experts, within different professions, on three continents: East-Asia (China, Japan, and Korea), America (the United States) and Europe (the Netherlands). The authors conclude that further research is needed to address the challenges in clinical staging, as it is found to be very difficult to differentiate between T2 and T3 tumors. The authors also recommend that the use of multidisciplinary teams (MDTs) should be encouraged to ensure comprehensive evaluation and treatment planning of these, and other, esophageal cancer patients.

Esophageal cancer is the 8th most common cancer worldwide. According to World Cancer Research Fund International there were more than 600,000 new cases of esophageal cancer worldwide in 2020 (2). This corresponds to an age-standardized rate of 6.3/100,000, and approximately 10–15/100,000 inhabitants in several high incidence countries in Africa and East-Asia. Unfortunately, many cases are diagnosed late due to the lack of early pathognomonic symptoms and the progressive nature of the disease. Typical symptoms include dysphagia, heartburn or acid reflux, retrosternal discomfort, loss of appetite, all leading to weight loss and fatigue. Hoarse voice can also be present, especially in individuals with paralysis of

the recurrent laryngeal nerve due to tumor growth. In combination with the lack of sufficient treatment in some countries, the overall disease-related mortality is very high, 5.6/100,000 (2). Thus, esophageal cancer is a truly lethal disease.

Esophageal cancer is most often diagnosed by an upper endoscopy with visually confirmed biopsies, while the spread, or extent, of the disease is most often determined by computed tomography (CT), endoscopic ultrasonography with fine needle aspiration (EUS + FNA) and/or positron emissions tomography (PET). Treatment algorithms depend on the stage of the disease, in most centers/countries defined by the Tumor-Node-Metastasis (TNM) Classification of Malignant Tumors. TNM was developed by the Union for International Cancer Control (UICC) in collaboration with the American Joint Committee on Cancer (AJCC) (3). Although there are some smaller differences between the UICC/AJCC and the Japanese Esophageal Society (JES) translation of the TNM classification, the use of TNM has become a globally recognized standard.

TNM describes the stage of a cancer using alphanumeric codes: T for tumor size and/or invasion of nearby tissue, N for tumor involvement of regional lymph nodes, and M for distant metastasis. The classification system also includes prefix modifiers: c, stage based on clinical information; p, stage given by histopathologic examination; y, stage assessed after chemotherapy and/or radiation therapy; and

[^] ORCID: Magnus Sundbom, 0000-0002-6243-2859; Gustav Linder, 0000-0003-2933-0815.

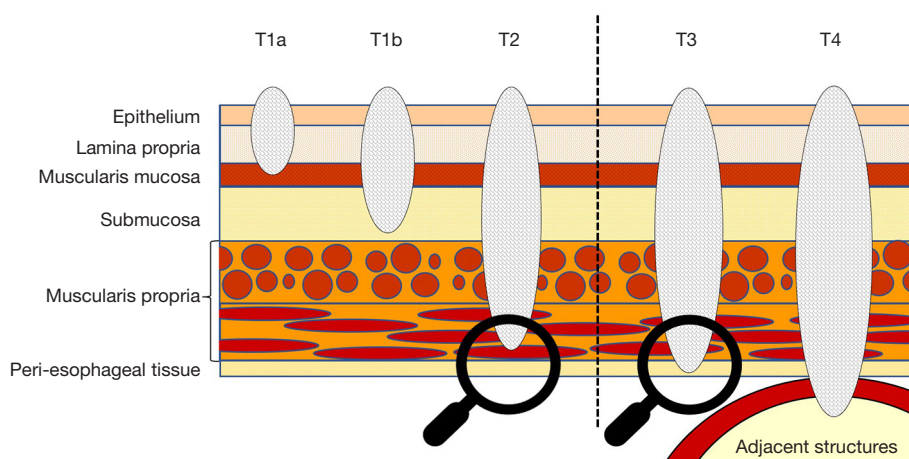


Figure 1 Schematic diagram of local tumor invasion in esophageal cancer (T-stage). Note the minute difference in tumor depth between a T2 and a T3 tumor, i.e., if the tumor invades the entire muscularis propria but not through to the peri-esophageal tissue.

r, stage for a recurrent tumor. Postoperatively, additional parameters are included, e.g., cancer cells at resection-boundaries (R 0–2), invasion into adjunct nerves, lymphatic vessels, or veins, (Pn 0–1), (L 0–1), and (V 0–2), respectively.

In esophageal cancer, the T-stage can be difficult to determine, despite several diagnostic methods such as EUS, CT and PET. Firstly, the T-stage is not based on tumor size but depth of invasion into the esophageal wall (4).

T-stage in esophageal cancer:

- ❖ T1: tumor invades the lamina propria, muscularis mucosae, or submucosa;
 - ◆ T1a: invasion into the lamina propria or muscularis mucosae;
 - ◆ T1b: invasion into the submucosa;
- ❖ T2: tumor invades the muscularis propria;
- ❖ T3: tumor invades the peri-esophageal tissue;
- ❖ T4: tumor invades adjacent structures;
 - ◆ T4a: invasion of pleura, pericardium, diaphragm, or peritoneum;
 - ◆ T4b: invasion of other adjacent structures, such as aorta, or trachea.

Secondly, the present diagnostic methods lack the resolution needed to determine whether the tumor has penetrated adjacent wall layers of the esophagus or the surrounding tissue. The distinction point between a T2 and a T3 tumor, i.e., if the tumor invades the muscularis propria but not the peri-esophageal tissue, is most problematic (Figure 1). The muscularis propria is only a few millimeters thick and esophageal EUS measurements, although fairly accurate in discriminating a T1 or a T4 tumor (5), are

often compromised by a local tumor stricture preventing adequate evaluation. Additionally, the peri-esophageal connective tissue layer of the esophagus is less defined than its counterpart in the small or large intestine.

At most larger centers, a MDT approach is used to decide on the best treatment for each patient. In esophageal cancer, the range of potential treatments is unusually wide—from local endoscopic resections to thoraco-abdominal esophagectomy on the surgical side, and the possibility to give curative or perioperative chemo(radio)therapy as well as various combinations of oncologic palliative treatment. At present, esophageal cancer treatment is entering a new era with targeted immunotherapy. The list of potential biologic agents is growing but anti-human epidermal growth factor receptor-2 (HER-2) antibodies and immune checkpoint inhibitors, e.g., nivolumab and pembrolizumab, have been integrated in clinical practice (6,7). Multimodal therapy with perioperative oncologic treatment is the most effective (8,9). However, as individuals with esophageal cancer often have impaired physical ability due to increasing age, malnourishment, frailty or concomitant disease, care must be taken to avoid overly demanding treatments. This reinforces the need for accurate staging.

In ESCC, radiotherapy with or without the addition of chemotherapy is arguably a more tolerated treatment than resectional surgery, especially in the elderly, and therefore has a special place. In practical terms, definitive chemoradiotherapy and surgical treatment are very different treatment strategies. While the first consists of multiple outpatient visits with administration of chemotherapy

and short sessions of radiotherapy for 5–6 weeks, the second comprises a large thoracoabdominal resection with considerable time spent in hospital. The fitness of the patient and the location of the tumor will often determine the preferred choice of treatment and is one important topic for the MDT to discuss. Definitive chemoradiotherapy, especially of high ESCC, is well tolerated and has demonstrated low mortality and even equipoise with CRT and surgery in terms of 2-year survival but seems to increase the risk of post treatment strictures requiring interventions (10). Surgery on the other hand increases the chances of local tumor control but poses challenges such as complex or maiming procedures in resection of ESCC of the upper esophagus where laryngectomy might be required.

In the age of neoadjuvant treatment, the N-stage has become associated with some important controversy. In ESCC, the risk of lymphatic spread is very low to nonexistent for T1a cancer ranging up to substantial for T3 or T4 tumors (11). The classic distinction between possible curative endoscopic resection resides at the T1b/T2 tumor level. In the T1a category, lymph node involvement is very rare but in the T1b category lymph nodes have been proposed to be positive in up to 40% of patients (12) mandating the need to consider additional treatment to endoscopic resection. However, the high prevalence of positive lymph nodes in T1b disease has been recently challenged as found to be much lower than 40% (13). Instead, a recent study has proposed histopathological worrisome features such as lymphovascular invasion, perineural growth or poor differentiation to be associated with the risk of lymphatic spread and prognosis, thus suggesting the need for adjunct treatment only in endoscopically treated patients having T1b tumors with worrisome features (14). T2 or T3 tumors are not amenable for endoscopic resection but instead need to be treated with either upfront surgery or multimodal treatment.

As stated by many experts in the present study, and as exemplified above, the N-stage may affect treatment allocation more than the clinical distinction between T2 and T3. Patients with locoregional lymphatic spread demonstrate a more aggressive tumor biology and therefore could benefit from added systemic treatment. The increased likelihood of lymphatic involvement in T3 tumors over T2 tumors (11) merits efforts to improve the staging process, as explored in the present study, to ensure optimal treatment for each patient. In this context, it is also important to remember that many of the patients with esophageal cancer are frail because of their rather advanced age and significant

weight loss due to progressive dysphagia. Furthermore, both fatigue and weight loss are known to increase during oncological and surgical treatment (15).

The inclusion of comments from several professions and countries, created the true clinical depth of the paper. Interestingly, most experts, irrespective of profession, agreed on the current problem with T-staging. To exemplify, Dr. Zhang, China, stated that “... *current diagnostic methods do not provide high level of accuracy in distinguishing between clinical T2 and T3 stage*”. Other authors, such as Dr. Park, Korea, went further and suggested that “*Differentiation between cT2 and cT3 is not meaningful when patients present with clinically suspected metastatic lymph nodes*”. It is mainly in the N0 patients that many of the authors propose the distinction between cT2 and cT3 to be of clinical importance since comprehensive guidelines recommend neoadjuvant therapy for cT3N0 patients but not for cT2N0.

The proposed treatment regimes, however, were rather similar among responding centers. Most experts proposed the mainstay of treatment, for both cT2 and cT3 ESCC, to be surgery with the addition of neoadjuvant treatment. Nodal status, as discussed above, was interpreted by most experts to be the true clinical divider. Both upfront surgery and neoadjuvant treatment followed by surgery was described as viable treatment options for true T2N0 patients and only one author, in East-Asia, argued for definitive chemoradiotherapy in these patients. From a clinical standpoint it is important to remember that upstaging of T2N0 patients is common, ranging from 25% to 55% (16–18). Upstaging is associated with increasing tumor size, poor differentiation, and lymphovascular invasion (19,20).

Multiple experts commented on the lack of feedback on clinical staging from the postoperative histology in the era of neoadjuvant treatment. This notion is important since it is no longer possible to ascertain quality control by comparing the clinical staging to postoperative histological findings due to the downstaging effect of chemoradiation.

Many endoscopists advocated the benefits of EUS as the most accurate method to differentiate between T2 or T3 heeding the fact that in up to 30% of patients EUS is not possible to perform due to intraluminal stenosis. It is noted by the authors that EUS before and after neoadjuvant treatment can aid in predicting the patient's future prognosis based on response to oncologic treatment. Additional proposed modalities to improve staging was PET/magnetic resonance imaging (MRI) or MRI with diffusion weighted imaging which could aid both in staging but also response evaluation

of neoadjuvant treatment. However, in a study conducted at our own institution, comparing the staging accuracy of PET/CT to PET/MRI, agreement on T-stage between these two modalities was seen in only 56% of the patients, with PET/CT more often overstaging the tumors (21). Additionally, in a recent Swedish validation of the outcomes of the MDT in selected reevaluated anonymized patients with esophageal cancer, a rather large variability was discovered, especially in deciding on the clinical T-stage. Even when we are given the best available diagnostic tools the distinction of clinical T-stage is difficult at best.

In conclusion, the authors have creatively used two well-defined cases to compare the opinions and workflows of multinational MDTs, regarding the diagnostic problems of assigning the correct clinical T-stage (T2 or T3) and the clinical implications thereof. The highlighted problems need to be studied further in our pursuit of improved and individualized care for this group of frail patients.

Acknowledgments

Funding: None.

Footnote

Provenance and Peer Review: This article was commissioned by the editorial office, *Journal of Thoracic Disease*. The article has undergone external peer review.

Peer Review File: Available at <https://jtd.amegroups.com/article/view/10.21037/jtd-23-1898/prf>

Conflicts of Interest: Both authors have completed the ICMJE uniform disclosure form (available at <https://jtd.amegroups.com/article/view/10.21037/jtd-23-1898/coif>). The authors have no conflicts of interest to declare.

Ethical Statement: The authors are accountable for all aspects of the work in ensuring that questions related to the accuracy or integrity of any part of the work are appropriately investigated and resolved.

Open Access Statement: This is an Open Access article distributed in accordance with the Creative Commons Attribution-NonCommercial-NoDerivs 4.0 International License (CC BY-NC-ND 4.0), which permits the non-commercial replication and distribution of the article with the strict proviso that no changes or edits are made and the

original work is properly cited (including links to both the formal publication through the relevant DOI and the license). See: <https://creativecommons.org/licenses/by-nc-nd/4.0/>.

References

- Leng X, Kurita D, Zhu Y, et al. Collaborative multidisciplinary management and expertise of cT2-3 locally advanced operable esophageal squamous cell carcinoma: a report of two cases. *J Thorac Dis* 2023;15:6362-72.
- World Cancer Research Fund International. Oesophageal cancer statistics. Available online: <https://www.wcrf.org/cancer-trends/oesophageal-cancer-statistics/2023>
- Brierley JD. TNM classification of malignant tumours. 8th ed. Chichester: Wiley Blackwell; 2017.
- Rice TW, Patil DT, Blackstone EH. 8th edition AJCC/UICC staging of cancers of the esophagus and esophagogastric junction: application to clinical practice. *Ann Cardiothorac Surg* 2017;6:119-30.
- Puli SR, Reddy JB, Bechtold ML, et al. Staging accuracy of esophageal cancer by endoscopic ultrasound: a meta-analysis and systematic review. *World J Gastroenterol* 2008;14:1479-90.
- Teixeira Farinha H, Digkila A, Schizas D, et al. Immunotherapy for Esophageal Cancer: State-of-the Art in 2021. *Cancers (Basel)* 2022;14:554.
- Kelly RJ, Ajani JA, Kuzdzal J, et al. Adjuvant Nivolumab in Resected Esophageal or Gastroesophageal Junction Cancer. *N Engl J Med* 2021;384:1191-203.
- Al-Batran SE, Homann N, Pauligk C, et al. Perioperative chemotherapy with fluorouracil plus leucovorin, oxaliplatin, and docetaxel versus fluorouracil or capecitabine plus cisplatin and epirubicin for locally advanced, resectable gastric or gastro-oesophageal junction adenocarcinoma (FLOT4): a randomised, phase 2/3 trial. *Lancet* 2019;393:1948-57.
- Shapiro J, van Lanschot JJB, Hulshof MCCM, et al. Neoadjuvant chemoradiotherapy plus surgery versus surgery alone for oesophageal or junctional cancer (CROSS): long-term results of a randomised controlled trial. *Lancet Oncol* 2015;16:1090-8.
- Bedenne L, Michel P, Bouché O, et al. Chemoradiation followed by surgery compared with chemoradiation alone in squamous cancer of the esophagus: FFCD 9102. *J Clin Oncol* 2007;25:1160-8.
- Rice TW, Ishwaran H, Hofstetter WL, et al. Esophageal Cancer: Associations With (pN+) Lymph Node Metastases.

- Ann Surg 2017;265:122-9.
12. Nigro JJ, Hagen JA, DeMeester TR, et al. Prevalence and location of nodal metastases in distal esophageal adenocarcinoma confined to the wall: implications for therapy. *J Thorac Cardiovasc Surg* 1999;117:16-23; discussion 23-5.
 13. Manner H, Pech O, Heldmann Y, et al. The frequency of lymph node metastasis in early-stage adenocarcinoma of the esophagus with incipient submucosal invasion (pT1b sm1) depending on histological risk patterns. *Surg Endosc* 2015;29:1888-96.
 14. Schölvinc D, Künzli H, Meijer S, et al. Management of patients with T1b esophageal adenocarcinoma: a retrospective cohort study on patient management and risk of metastatic disease. *Surg Endosc* 2016;30:4102-13.
 15. Sundbom M, Ekfjord L, Willman M, et al. Patient-reported experience and outcome measures during treatment for gastroesophageal cancer. *Eur J Cancer Care (Engl)* 2020;29:e13200.
 16. Markar SR, Gronnier C, Pasquer A, et al. Role of neoadjuvant treatment in clinical T2N0M0 oesophageal cancer: results from a retrospective multi-center European study. *Eur J Cancer* 2016;56:59-68.
 17. Barbeta A, Schlottmann F, Nobel T, et al. Predictors of Nodal Metastases for Clinical T2N0 Esophageal Adenocarcinoma. *Ann Thorac Surg* 2018;106:172-7.
 18. Vining P, Birdas TJ. Management of clinical T2N0 esophageal cancer: a review. *J Thorac Dis* 2019;11:S1629-32.
 19. Semenkovich TR, Panni RZ, Hudson JL, et al. Comparative effectiveness of upfront esophagectomy versus induction chemoradiation in clinical stage T2N0 esophageal cancer: A decision analysis. *J Thorac Cardiovasc Surg* 2018;155:2221-2230.e1.
 20. Kidane B, Korst RJ, Weksler B, et al. Neoadjuvant Therapy Vs Upfront Surgery for Clinical T2N0 Esophageal Cancer: A Systematic Review. *Ann Thorac Surg* 2019;108:935-44.
 21. Linder G, Korsavidou-Hult N, Bjerner T, et al. (18) F-FDG-PET/MRI in preoperative staging of oesophageal and gastroesophageal junctional cancer. *Clin Radiol* 2019;74:718-25.

Cite this article as: Sundbom M, Linder G. Special requirements for TNM-staging in esophageal cancer. *J Thorac Dis* 2024;16(6):3535-3539. doi: 10.21037/jtd-23-1898