



Contents lists available at ScienceDirect

International Journal of Surgery Case Reports

journal homepage: www.casereports.com

The role of surgical excision for the Krukenberg tumour: A case report

David Lam^{a,*}, Eugene Ong^{a,b}^a Department of Colorectal Surgery, St Vincent's Hospital Melbourne, 41 Victoria Street, Fitzroy, VIC 3065, Australia^b General Surgery and Gastroenterology Clinical Institute, Epworth Freemasons, 166 Clarendon Street, East Melbourne, VIC 3002, Australia

ARTICLE INFO

Article history:

Received 28 April 2017

Received in revised form 15 July 2017

Accepted 21 July 2017

Available online 25 July 2017

Keywords:

Krukenberg tumour

Colorectal cancer

Cytoreductive surgery

Case report

Carcinomatosis peritonei

ABSTRACT

INTRODUCTION: Krukenberg tumour (KT), which represents carcinoma in the ovary, is an uncommon manifestation of metastatic colorectal cancer. It is associated with poor prognosis and a high incidence of peritoneal metastatic disease.

PRESENTATION OF CASE: The authors present a case of a 51-year-old female who had a symptomatic, metachronous right ovarian KT diagnosed 12 months after her initial resection. Surgery was performed to excise the 23 cm tumour as well as the contralateral ovary and isolated peritoneal disease, with an R0 resection achieved.

DISCUSSION: KT from colorectal origin behave differently to non-ovarian colorectal metastases, with features suggestive of transcoelomic dissemination. Surgical removal of isolated ovarian metastasis without peritoneal involvement is associated with improved outcomes. Treatment with cytoreductive surgery and heated intraperitoneal chemotherapy offers promise for patients with KT and concomitant peritoneal involvement.

CONCLUSION: This case is illustrative of the clinical features of KT including its chemo-resistance and concomitant carcinomatosis peritonei. Cytoreductive surgery for KT provides symptom control and confers survival benefit in selected patients.

© 2017 The Author(s). Published by Elsevier Ltd on behalf of IJS Publishing Group Ltd. This is an open access article under the CC BY-NC-ND license (<http://creativecommons.org/licenses/by-nc-nd/4.0/>).

1. Introduction

Krukenberg tumours (KTs) are histologically defined as carcinoma within the ovary containing mucin-filled signet ring cells and represent metastasis to the ovary. Up to 30 per cent of ovarian metastases arise from a colorectal origin, with gastric adenocarcinoma being the most common primary malignancy [1]. Colorectal KT's are an uncommon entity, comprising less than 10 per cent of all colorectal metastases. Here we present the management of a patient with symptomatic, metachronous KT. This case report has been reported in line with the SCARE criteria [2].

2. Presentation of case

A 51-year-old female underwent an open right hemicolectomy in December 2014 in China for a Stage IIA caecal cancer. Twelve months later, she presented with abdominal pain and a rising carcinoembryonic antigen level of 228. Subsequent CT scan demonstrated a ten centimetre pelvic mass. This was managed with

chemotherapy (FOLFOX for five cycles) upon which the patient travelled to Melbourne, Australia to seek alternative therapy. MRI and Whole Body FDG PET performed six months following diagnosis of recurrence demonstrated disease progression. MRI findings were of a 23 cm multiloculated mucinous appearing mass with enhancing internal septations, nodularity and diffusion restriction, as well as peritoneal nodularity in the right paracolic gutter and upper abdomen. On PET, there was patchy increase in FDG activity around the margins of the mass, as well as a separate 27 mm intensely FDG-avid mass between the mass and the right abdominal wall. Ultrasound-guided core biopsy of the mass confirmed metastatic mucinous adenocarcinoma with immunohistochemistry favouring a colonic primary (Figs. 1 and 2).

Clinically, the patient was symptomatic with abdominal discomfort from her pelvic mass but no symptoms of bowel obstruction. The patient was discussed at a multidisciplinary meeting and the decision was made to undertake surgical excision. At laparotomy, the large tumour was dissected free from the small bowel and omentum and resected en bloc with the right fallopian tubes. There was also macroscopic right anterior abdominal wall and paracolic gutter recurrence which was excised, and a prophylactic left salpingo-oophorectomy performed. The patient recovered well with no post-operative complications. Histopathology confirmed moderately differentiated adenocarcinoma within the right ovary weighing 2630g and measuring 230 × 210 × 200mm in size, with immunostains confirming col-

Abbreviations: FOLFOX, folinic acid, fluorouracil, oxaliplatin; MRI, magnetic resonance imaging; FDG PET, fludeoxyglucose positron emission topography; HIPEC, hyperthermic intraperitoneal chemotherapy.

* Corresponding author at: 3/352 Whitehorse Road, Balwyn, VIC 3103, Australia. E-mail address: dlams@hotmail.com (D. Lam).

<http://dx.doi.org/10.1016/j.ijscr.2017.07.046>

2210-2612/© 2017 The Author(s). Published by Elsevier Ltd on behalf of IJS Publishing Group Ltd. This is an open access article under the CC BY-NC-ND license (<http://creativecommons.org/licenses/by-nc-nd/4.0/>).

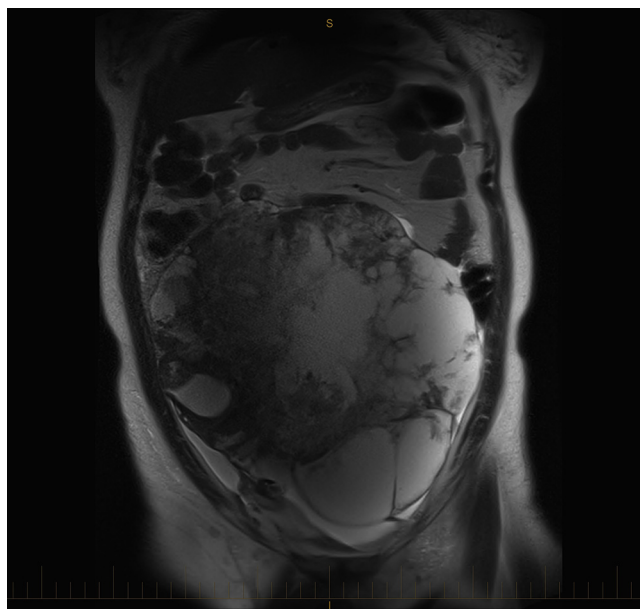


Fig. 1. Coronal image of MRI scan demonstrating internal septations and nodularity of the KT.

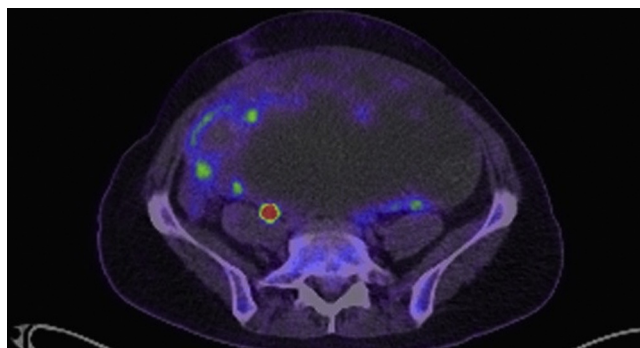


Fig. 2. Axial image of FDG PET scan demonstrating patchy uptake at the periphery of the KT and the small FDG-avid mass between the KT and abdominal wall.

orectal origin. There was no evidence of malignancy in the left ovary and fallopian tube. The peritoneal nodules on the anterior abdominal wall and right paracolic gutter specimens had similar appearance to the ovarian tumour microscopically with clear resection margins. At six month follow-up her pre-operative symptoms had resolved, with no evidence of local or systemic recurrence (Fig. 3).

3. Discussion

The name 'Krukenberg tumour' originates from Friedrich Ernst Krukenberg, a German physician who described five cases in 1896. The exact route of spread from the primary site to the ovary is unknown, with proposed theories describing haematogenous, lymphatic or trans-coloemic routes. Evidence for trans-coloemic spread is the high incidence of bilateral involvement as well as concomitant carcinomatosis peritoneii in KT; in one case series 18 out of 24 patients had documented peritoneal disease at the time of diagnosis [3]. Furthermore, the ovary has been suggested to be a sanctuary organ for systemic chemotherapy owing to the poor response of KTs to 5-FU based chemotherapy and even oxaliplatin- or irinotecan-containing chemotherapy compared to extra-ovarian metastases, in part due to their voluminous, cystic and mucin-rich features [4,5].

KTs from colorectal origin are an overall indicator of poor prognosis, with median survival times reported between 19 to 29 months [1,3,6] and 5-year survival rates of 9% for synchronous KT and 20% for metachronous KT [7]. The data regarding long-term outcomes for KT from colorectal primaries lies mainly in small case series due to the limited incidence of this disease. Isolated metastatic disease to the ovaries has been shown to confer a significant overall survival advantage, with one series reporting mean overall survival time of 61 months with isolated ovarian disease treated with cytoreductive surgery. Other favourable prognostic indicators include postmenopausal status and unilateral ovarian involvement [6].

Cytoreductive surgery (CRS) for KTs carries a significant locoregional or metastatic recurrence rate despite achieving an initial R0 resection. KTs in particular have been linked to retroperitoneal lymph node recurrence [8]. It has been suggested that should KT be discovered incidentally upon resection of a colorectal primary, systematic second-look surgery should be performed to exclude peritoneal metastasis [9]. Although prospective studies to directly investigate the role of CRS are lacking, there is evidence that maximal cytoreduction still does confer a survival benefit in selected patients. In one study of colorectal KTs, patients undergoing optimal cytoreduction (residual <1 cm) had a significantly longer median progression-free survival compared to those undergoing suboptimal cytoreduction (11 vs 2.5 months) and overall

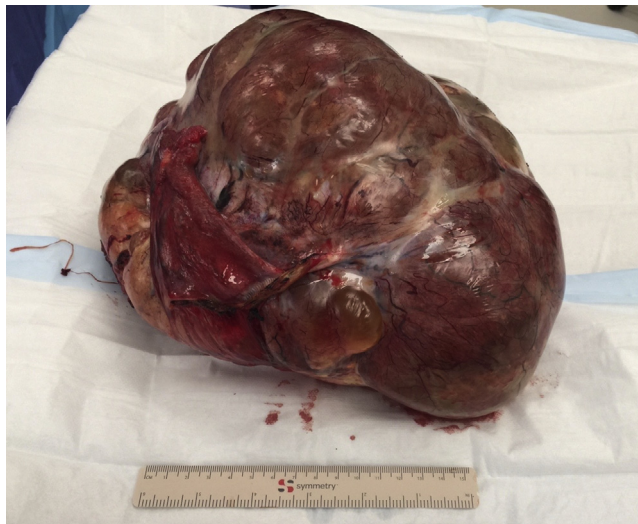

Fig. 3. Intra-operative photograph of the en-bloc resection specimen.

survival (35 vs 7 months), albeit with a high peri-operative mortality rate of 5% [10]. In another retrospective series, ovary-specific survival (date from KT diagnosis to death) in the oophorectomy group was favourable compared with the historical control group who did not undergo oophorectomy (20.8 vs 10.9 months) [4].

Currently, the landscape for management of peritoneal disease in colorectal cancer is evolving. CRS and concomitant HIPEC (CRS-HIPEC) for KT from gastric origin has been shown to confer a survival advantage compared to CRS alone; however, this benefit was not seen in the subgroup with ovarian metastasis in the absence of peritoneal disease [11]. For ovarian metastases from colorectal origin, a recent series of 75 patients underwent CRS-HIPEC with a median overall survival of 40 months [12]. However, 19% in this group had KT alone without peritoneal disease and this group had a significantly higher three-year survival compared to those with peritoneal disease (77% versus 48%). There is at present insufficient evidence for routine HIPEC for KT, especially where there is minimal or no overt peritoneal disease, and any potential oncologic benefit must be weighed against the additional morbidity of CRS-HIPEC.

4. Conclusion

KTs from colorectal origin can often be rapidly progressive despite systemic chemotherapy and present with concomitant peritoneal metastatic disease, as this case demonstrates. Surgery for KTs aims to alleviate symptoms but also can result in survival benefit. The emerging utility of combined cytoreductive surgery and intraperitoneal chemotherapy for KTs suggests that KTs may be a surrogate marker for occult or future peritoneal metastasis.

Conflicts of interest

No conflicts of interest to disclose.

Funding source

No sources of funding to declare.

Ethical approval

Ethics approval has been granted by the St Vincent's Hospital Melbourne Research Governance Unit.

Consent

Written informed consent was obtained from the patient for publication of this case report and accompanying images. A copy of the written consent is available for review by the Editor-in-Chief of this journal on request.

Author contribution

David Lam was responsible for writing of the manuscript.

Eugene Ong was the surgeon responsible for the clinical management of the patient in the case report and contributed the clinical information and figures for the manuscript. He was also responsible for editing of the manuscript.

Guarantor

Mr Eugene Ong is the guarantor of the study.

References

- [1] J. Ojo, S. De Silva, E. Han, P. Lin, M. Wakabayashi, R. Nelson, et al., Krukenberg tumors from colorectal cancer: presentation, treatment and outcomes, *Am. Surg.* 77 (2011) 1381–1385.
- [2] R.A. Agha, A.J. Fowler, A. Saeta, I. Barai, S. Rajmohan, D.P. Orgill, et al., The SCARE Statement: consensus-based surgical case report guidelines, *Int. J. Surg.* 34 (2016) 180–186.
- [3] K.L. Tan, W.S. Tan, J.F. Lim, K.W. Eu, Krukenberg tumors of colorectal origin: a dismal outcome-experience of a tertiary center, *Int. J. Colorectal Dis.* 25 (2010) 233–238.
- [4] S.J. Lee, J. Lee, H.Y. Lim, W.K. Kang, C.H. Choi, J.W. Lee, et al., Survival benefit from ovarian metastectomy in colorectal cancer patients with ovarian metastasis: a retrospective analysis, *Cancer Chemother. Pharmacol.* 66 (2010) 229–235.
- [5] D. Goere, C. Daveau, D. Elias, V. Boige, G. Tomasic, S. Bonnet, et al., The differential response to chemotherapy of ovarian metastases from colorectal carcinoma, *Eur. J. Surg. Oncol.* 34 (2008) 1335–1339.
- [6] Y.J. Jeung, H.J. Ok, W.G. Kim, S.H. Kim, T.H. Lee, Krukenberg tumors of gastric origin versus colorectal origin, *Obstet. Gynecol. Sci.* 58 (2015) 32–39.
- [7] P.P. Huang, T.K. Weber, C. Mendoza, M.A. Rodriguez-Bigas, N.J. Petrelli, Long-term survival in patients with ovarian metastases from colorectal carcinoma, *Ann. Surg. Oncol.* 5 (1998) 695–698.
- [8] C. Eveno, D. Goere, P. Dartigues, C. Honore, F. Dumont, D. Tzanis, et al., Ovarian metastasis is associated with retroperitoneal lymph node relapses in women treated for colorectal peritoneal carcinomatosis, *Ann. Surg. Oncol.* 20 (2013) 491–496.
- [9] C. Honore, D. Goere, A. Souadka, F. Dumont, D. Elias, Definition of patients presenting a high risk of developing peritoneal carcinomatosis after curative surgery for colorectal cancer: a systematic review, *Ann. Surg. Oncol.* 20 (2013) 183–192.

- [10] C.C. McCormick, R.L. Giuntoli, G.J. 2nd Gardner, R.D. Schulick, K. Judson, B.M. Ronnett, et al., The role of cytoreductive surgery for colon cancer metastatic to the ovary, *Gynecol. Oncol.* 105 (2007) 791–795.
- [11] X.J. Wu, P. Yuan, Z.Y. Li, Z.D. Bu, L.H. Zhang, A.W. Wu, et al., Cytoreductive surgery and hyperthermic intraperitoneal chemotherapy improves the survival of gastric cancer patients with ovarian metastasis and peritoneal dissemination, *Tumour Biol.* 34 (2013) 463–469.
- [12] A.M. Kuijpers, A.M. Mehta, A.G. Aalbers, W.J. van Driel, H. Boot, V.J. Verwaal, Treatment of ovarian metastases of colorectal and appendiceal carcinoma in the era of cytoreductive surgery and hyperthermic intraperitoneal chemotherapy, *Eur. J. Surg. Oncol.* 40 (2014) 937–942.

Open Access

This article is published Open Access at scimedirect.com. It is distributed under the [IJSCR Supplemental terms and conditions](#), which permits unrestricted non commercial use, distribution, and reproduction in any medium, provided the original authors and source are credited.