



Robotic cross-folded U-configuration intracorporeal ileal neobladder for muscle-invasive bladder cancer: Initial experience and functional outcomes

Takuya Koie | Chikara Ohyama  | Takahiro Yoneyama | Hirotaka Nagasaka | Hayato Yamamoto | Atsushi Imai | Shingo Hatakeyama | Yasuhiro Hashimoto

Department of Urology, Hirosaki University
Graduate School of Medicine, Hirosaki, Japan

Correspondence

Chikara Ohyama, Department of Urology,
Hirosaki University Graduate School of
Medicine, Zaifucho 5, Hirosaki 036-8562,
Japan.

Email: coyama@hirosaki-u.ac.jp

Abstract

Background: This study compared the surgical and urinary functional outcomes in patients with muscle-invasive bladder cancer (MIBC) who underwent robot-assisted radical cystectomy (RARC) followed by intracorporeal ileal neobladder reconstruction (ICNB) to those in patients who underwent minimum incision endoscopic radical cystectomy (MIE-RC) followed by extracorporeal ileal neobladder reconstruction (ECNB).

Materials and Methods: This study reviewed the clinical records of 153 consecutive MIBC patients who underwent neoadjuvant chemotherapy followed by radical cystectomy and ileal neobladder reconstruction.

Results: The operative time in the ICNB group was significantly longer than that in the ECNB group. The median estimated blood loss was significantly less in the ICNB group than in the ECNB group. The neobladder capacity gradually increased in both groups. The maximum neobladder pressure and urethral closure pressure gradually improved in both groups.

Conclusion: Our initial experience with ICNB was favourable, with acceptable surgical and urinary functional outcomes.

KEYWORDS

ileal neobladder, intracorporeal urinary diversion, muscle-invasive bladder cancer, radical cystectomy, robot-assisted surgery

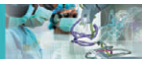1 | INTRODUCTION

Radical cystectomy (RC) remains the gold standard treatment for muscle-invasive bladder cancer (MIBC). Minimally invasive RC, especially robot-assisted RC (RARC), has been able to reduce estimated blood loss (EBL), blood transfusion rates, and the need for postoperative

analgesia and has enabled earlier recovery of bowel function.^{1,2} The largest multi-institutional cohort study from the International Robotic Cystectomy Consortium (IRCC) reported that long-term oncological outcomes were similar to those for open RC.³ As a result, the proportion of RARC cases had dramatically increased from 0.6% to 12.8% by 2010.^{4,5}

This is an open access article under the terms of the Creative Commons Attribution-NonCommercial-NoDerivs License, which permits use and distribution in any medium, provided the original work is properly cited, the use is non-commercial and no modifications or adaptations are made.

© 2018 The Authors. The International Journal of Medical Robotics and Computer Assisted Surgery Published by John Wiley & Sons Ltd.



Although robotic surgery has advanced, experience with totally intracorporeal orthotopic ileal neobladder reconstruction (ICNB) remains limited. Most surgeons have performed a hybrid approach, with RARC and extracorporeal reconstruction of urinary diversion, because ICNB remains technically challenging.⁶⁻⁸ To date, the adoption of ICNB has been confined to high-volume academic institutions worldwide. However, several techniques for ICNB have been reported with promising functional outcomes.⁹⁻¹¹

The ideal continent reservoir should have adequate capacity and low pressure in the storage phase and high compliance to help with continence, and it should allow voluntary emptying without residual urine.¹² We previously reported the surgical procedure and functional outcomes of our original cross-folded U-configuration extracorporeal ileal neobladder reconstruction (ECNB).^{13,14} We applied the open surgery technique to ICNB formation. Herein, we report our initial experience with 22 MIBC patients who underwent RARC with U-shaped ICNB, which replicates the open technique. In addition, we compared urinary functional outcomes of ICNB with those of ECNB.

2 | MATERIALS AND METHODS

2.1 | Study population

In this retrospective study, we reviewed the clinical and pathological records of 445 consecutive MIBC patients who underwent RC and pelvic lymphadenectomy (PLND) between May 1994 and December 2017 at Hirosaki University. Our study focused on MIBC patients who underwent neoadjuvant chemotherapy (NAC) followed by RC and ileal neobladder reconstruction.

The study protocol and informed consent documents were reviewed and approved by the Hirosaki University institutional review board (authorization number: 2013-271).

2.2 | Treatment schedule

All treatments were performed at our institution. All patients received two cycles of gemcitabine and cisplatin or carboplatin (CBDCA) (800 mg/m² of gemcitabine on days 1, 8, and 15, and 70 mg/m² of CDDP or CBDCA at an area under the curve of 4 based on Calvert formula¹⁵ on day 2) as NAC. Each cycle lasted for 21 days. The two courses of NAC were followed by RC and PLND at a 1-month interval.^{16,17} A patient was identified as cisplatin ineligible if they met at least one of the following criteria: European Cooperative Oncology Group (ECOG) performance status of 2, creatinine clearance of <60 mL/min, hearing loss grade of ≥ 2 , neuropathy grade of ≥ 2 , and/or New York Heart Association Class III heart failure.¹⁸

2.3 | Surgical procedure

Robot-assisted radical cystectomy with ICNB was performed by two experienced robotic surgeons. Our surgical technique for RARC has been described in detail previously.¹⁹ In all, seven trocars were used. The patients were placed in the Trendelenburg position (25°). The peritoneum was incised, and the anterior cavity of the bladder was sufficiently exposed. The endopelvic fascia was incised, and the dorsal

vein complex was ligated. The posterior layer of Denonvilliers' fascia was then incised in the midline between the rectum or vagina and the bladder. The ureters were divided close to the bladder. The lateral vascular bundles were incised close to the bladder. The plane of urethral dissection was directed under the dorsal vein complex and through the anterior prostatic fibromuscular stroma. Pelvic lymphadenectomy, including the hypogastric, external iliac, and obturator nodes, was routinely performed in both procedures. Our surgical technique for minimum incision endoscopic RC (MIE-RC) has also been previously described in detail.²⁰

Our U-shaped ICNB technique replicates the ECNB technique at our institution.^{13,14} The first step is to identify the most mobile ileum that reaches the urethra without tension. A 40-cm bowel segment is chosen for the neobladder, using a fenestrated forceps and a Cadere grasper. A monopolar scissors is used to create a small opening in the centre of the bowel segment. An 18-F urethral catheter is inserted through the urethra to irrigate the future neobladder and to minimize spillage of ileal contents (Figure 1A).

The second step is to divide approximately 5 cm of the peritoneum with the bowel mesentery. Two mesenteric windows are created, using a monopolar scissors. After ensuring that the bowel segment has maintained good vascularity, a 60-mm Endo-GIA stapler is passed through the 15-mm assistant port to divide the bowel lumen both proximally and distally, using the Covidien iDrive Ultra Powered Stapling System. Anastomosis is performed with a 60-mm Endo-GIA stapler for the side-to-side part and 60-mm loads for the horizontal part, using the iDrive.

The third step is to fix the ileal segment at the pelvic floor (Figure 1B). Two stay sutures are placed 5 cm laterally from the centre of the ileal segment. The ileal segment is fixed to the pelvic floor using a 3-0 V-Loc suture to facilitate ease of handling and the neobladder-urethral anastomosis. The ileal segment is detubularized at the antimesenteric border using a monopolar scissors, while exerting traction with a fenestrated forceps and counter-traction using a suction device.

The fourth step is to make the urethro-ileal anastomosis (Figure 1C). The urethro-ileal anastomosis begins with suturing of the ileal edge to the posterior aspect of the urethral stump starting at the 6 o'clock position, using a 15-cm 3-0 V-Loc suture. The anastomosis continues anteriorly in a running fashion, up to the 12 o'clock position. After the anastomosis is complete, the ileal loop is arranged in an inverted U-shape and the inner opposite borders are oversewn with a single-layer seromuscular running suture using 15-cm 3-0 V-Loc sutures (Figure 1D).

The fifth step is to make the uretero-ileal anastomosis. Two small enterotomies are created in the U-flap, and the ureters are introduced into the future neobladder. A 4-0 braided polyglactin suture (7-cm long) is used to make an anastomosis with interrupted sutures. After transection of the ureter using a monopolar scissors, an anchoring suture is placed using a 4-0 braided polyglactin suture. A 6-F single-J ureteric stent is placed over a guidewire that is inserted through the urethra. An 18-F urethral catheter with 10-mL balloon is subsequently inserted through the urethra. After ureteral anastomosis, the U-flap is cross-folded to make a pouch (Figure 1E). The remaining anterior neobladder wall is closed using 15-cm 3-0 V-Loc sutures (Figure 1F).

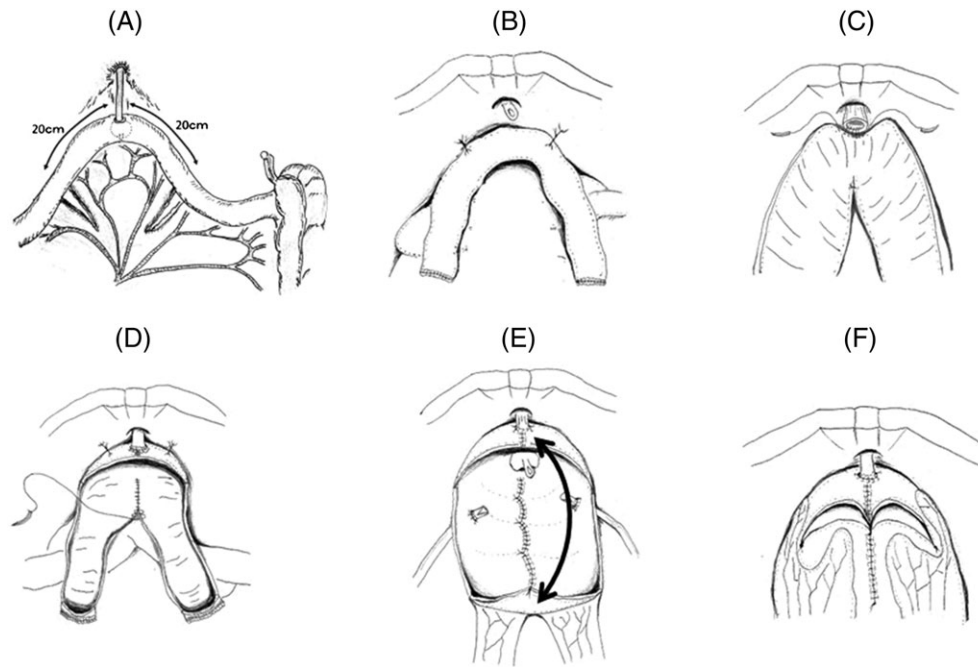


FIGURE 1 Schema of surgical procedure for U-shaped intracorporeal ileal neobladder. (A) Selection of the appropriate portion of ileum that reaches the urethra without tension. A 40-cm bowel segment is chosen for the neobladder. A 14-F urethral catheter is inserted through the urethra to irrigate the ileum. (B) The ileal loop is fixed to the pelvic floor to facilitate ease of handling and the neobladder-urethral anastomosis. (C) Detubularization of the ileal loop and urethro-ileal anastomosis. The urethro-ileal anastomosis is started by suturing the ileal edge to the posterior aspect of the urethral stump at the 6 o'clock position. The anastomosis continues anteriorly in a running fashion, up to the 12 o'clock position. (D) The detubularized ileal loop is arranged in an inverted U-shape and the inner opposite borders are oversewn with a single-layer seromuscular running suture. (E) After the ureteral anastomosis, the U-flap is cross-folded to make a pouch. (F) Closure of ileal pouch

Finally, the peritoneal window is closed to place the neobladder in the extraperitoneal position (the pelvis).

2.4 | Patient evaluation

The following baseline information was obtained: complete history and physical examination, Eastern Cooperative Oncology Group performance status, abdominal and pelvic computed tomography (CT) or magnetic resonance imaging (MRI), and chest radiography or CT.

Tumours were measured at baseline and before RC. The diagnosis of MIBC was confirmed by a single pathologist at Hirosaki University after reviewing the results of the transurethral resection and MRI at baseline. We extensively examined the specimens obtained during cystoprostatectomy to identify the presence of MIBC. Pathological examination of complete transmural sections of the bladder wall was performed to accurately determine the pathological stage. All tumours were staged according to the eighth edition of the American Joint Committee on Cancer Staging Manual.²¹ All lymph nodes from each designated site were submitted for examination, and representative sections of the surrounding fibroadipose tissue were also examined.

All perioperative complications were classified according to the Clavien-Dindo classification (I: complications needing only oral medications or bedside intervention; II: complications needing only intravenous medications, total parenteral nutrition, enteral nutrition, or blood transfusion; III: complications needing interventional radiology, therapeutic endoscopy, intubation, angiography, or operation; IV: complications causing residual and lasting disability requiring major rehabilitation or organ resection; V: complications causing death).²²

2.5 | Training for voiding

Patients with the neobladder were advised to void every 2 hours for the first 3 months. Subsequently, the voiding records were checked, and the patients were allowed to void according to their preference.

2.6 | Follow-up

Each patient was evaluated every 3 months using ultrasonography to check for hydronephrosis and to monitor renal and liver function. Computed tomography was performed every 6 months for early detection of recurrence. Cystourethroscopic examination was performed at 3-month intervals during the first and second years and at 6-month intervals thereafter.

2.7 | Urinary function

The patients were asked about their voiding behaviour, presence or absence of incontinence, and pad requirements. Continence status was evaluated by the number of pads the patient required during 24 hours. Continence was defined as good if a patient used 0-1 pad daily. Urodynamic studies, including cystometry, urethral pressure profilometry, and uroflowmetry, were also performed at 3, 6, 9, and 12 months after surgery.

2.8 | Statistical analysis

The endpoints in this study were surgical outcomes, including operative time, EBL, perioperative complications, and urinary function. Data

were analysed using IBM SPSS version 24 (IBM Corp., Armonk, New York). The Mann-Whitney *U* test was used to assess chronological changes in the neobladder, including urethral pressure, neobladder capacity, residual urine, and maximum urinary flow rate (Qmax). All *P* values were 2-sided, and the significance level was set at *P* < 0.05.

3 | RESULTS

3.1 | Patient characteristics

A total of 22 patients who underwent RARC and ICNB (ICNB group) and 131 who underwent MIE-RC and ECNB (ECNB group) were enrolled in this study. The pretreatment characteristics of the patients are listed in Table 1. All patients were diagnosed with muscle-invasive urothelial carcinoma on the basis of histological examination of the specimens obtained from transurethral resection. The median age was 67 years, and 77.1% of the enrolled patients were men. A total of 78 patients (51.0%) had clinical T2, and seven patients (4.6%) had lymph node involvement. Significantly more patients received neoadjuvant gemcitabine and cisplatin in the ICNB group than in the ECNB group (*P* < 0.001). All patients with MIBC who received NAC underwent MIE-RC with ECNB before August 2013. If the patients with MIBC who received NAC achieved complete or partial response with tumour stage T2 or lower, they underwent RARC and ICNB from September 2013.

TABLE 1 Patients' characteristics

	RARC + ICNB (N = 22)	MIE-RC + ECNB (N = 131)	<i>P</i>
Age (year, median, IQR)	67 (59-69)	67 (60-72)	0.716
Gender, N (%)			0.046
Male	21 (95.5)	97 (74.0)	
Female	1 (4.55)	34 (26.0)	
Clinical T, N (%)			0.345
T2	13 (59.1)	65 (49.6)	
T3	7 (31.8)	64 (48.9)	
T4a	2 (9.1)	2 (1.5)	
Clinical N, N (%)			0.251
Negative	21 (95.5)	125 (95.4)	
Positive	1 (4.5)	6 (4.6)	
Grade, N (%)			0.912
2	5 (22.7)	38 (29.0)	
3	17 (77.3)	93 (71.0)	
Regimen of neoadjuvant chemotherapy			<0.001
Gem + CDDP	18 (81.8)	23 (17.6)	
Gem + CBDCA	4 (18.2)	108 (82.4)	
The interval from the diagnosis of MIBC to RARC (day, median, IQR)	78 (70-81)	64 (57-73)	0.038
Follow-up period (months, median, IQR)	33.4 (27.2-44.5)	71 (39.9-116.4)	<0.001

Abbreviations: CBDCA, carboplatin; CDDP, cisplatin; ECNB, extracorporeal ileal neobladder; Gem, gemcitabine; ICNB, intracorporeal ileal neobladder; IQR, interquartile range; MIBC, muscle-invasive bladder cancer; MIE-RC, minimum incision endoscopic radical cystectomy; RARC, robot-assisted radical cystectomy.

3.2 | Surgical outcomes

Surgical outcomes and perioperative complications are shown in Table 2. Robot-assisted radical cystectomy with ICNB was successfully completed in all patients without open conversion. The operative time in the ICNB group was significantly longer than in the ECNB group. The median estimated blood loss was less, and the transfusion rate was significantly lower in the ICNB group than in the ECNB group (*P* < 0.001).

3.3 | Pathological outcomes

All patients were evaluated for pathological outcomes. Table 3 lists the histopathological details. Overall, the surgical specimens of 45 (29.4%) patients showed stage pT0 disease. One patient had a positive surgical margin in the ECNB group. Nine patients (5.9%) had lymph node involvement that was not evident on preoperative evaluation in both groups.

3.4 | Complications

No intraoperative complications were associated with this procedure. Table 4 lists the perioperative complications. No patients died or were readmitted within 90 days of surgery in either group. The most frequent perioperative complications were ileus in three patients (13.6%) in the ICNB group and surgical site infections in 18 patients (13.7%) in the ECNB group. Patients who had ileourethral anastomotic strictures underwent high-pressure balloon dilation. In the ECNB group, two patients had grade 4 complications because of ileus or ileal anastomosis leak.

3.5 | Aspects of surgery influencing the perioperative outcomes after RARC

Table 5 lists the effects of specific surgical aspects on perioperative outcomes. Median operation time in the last eight cases was significantly lower than that in the first seven cases (*P* < 0.001). Median EBL and rates of perioperative complications were not significantly different among the three groups.

3.6 | Oncological outcomes

At the end of the follow-up period, two patients (9.1%) in the ICNB group and 11 (8.4%) in the ECNB group died of bladder cancer. Nine patients (5.9%), including two in the ICNBC group and seven in the ECNB group, developed clinical recurrence.

3.7 | Urinary function

Figure 2 shows the chronological changes in median capacity and residual urine in the cross-folded U-configuration ileal neobladder. The median neobladder capacity at 6 and 12 months after surgery was 276 and 285 mL in the ICNB group and 274 and 309 mL in the ECNB group, respectively. There were no statistically significant differences between the groups. The median residual volume at 6 and 12 months after surgery was 40 and 29 mL in the ICNB group and 0 and 0 mL in the ECNB group. At 9 months after surgery, the residual



TABLE 2 Surgical outcomes and perioperative complications

	RARC + ICNB (N = 22)	MIE-RC + ECNB (N = 131)	P
Operative time for all procedures (minutes, median, IQR)	430 (349-476)	287 (263-335)	0.033
Estimated blood loss for all procedures (mL, median, IQR)	300 (119-450)	1150 (720-1788)	<0.001
Operative time for RC and PLND (minutes, median, IQR)	117 (97-130)	94 (81-116)	0.033
Operative time for neobladder reconstruction (minutes, median, IQR)	156 (142-198)	95 (90-120)	0.032
Intraoperative transfusion rate (number, %)	0 (0)	12 (9.2)	<0.001

Abbreviations: ECIN, extracorporeal ileal neobladder; ICNB, intracorporeal ileal neobladder; IQR, interquartile range; MIE-RC, minimum incision endoscopic radical cystectomy; RC, radical cystectomy; PLND, pelvic lymph node dissection; RARC, robot-assisted radial cystectomy.

TABLE 3 Pathological outcomes

	RARC + ICNB (N = 22)	MIE-RC + ECNB (N = 131)	P
Pathological stage, number (%)			0.782
T0	8 (36.4)	37 (28.2)	
T1	6 (27.3)	37 (28.2)	
T2	2 (9.0)	37 (28.2)	
T3	6 (27.3)	19 (14.5)	
T4	0	1 (0.9)	
Lymph node involvement, number (%)	3 (13.6)	6 (4.6)	0.064
Positive surgical margins	0	1 (0.5)	>0.999
Lymph node yield (median, number, IQR)	15 (12-18)	18 (12-28)	0.747

Abbreviations: ECNB, extracorporeal ileal neobladder; ICNB, intracorporeal ileal neobladder; IQR, interquartile range; MIE-RC, minimum incision endoscopic radical cystectomy; RARC, robot-assisted radial cystectomy.

urine in the ICNB group was significantly greater than in the ECNB group ($P = 0.002$). Figure 3 shows the chronological changes in maximum neobladder pressure (Pdet) and maximum urethral closure pressure (MUCP) in the cross-folded U-configuration ileal neobladder. The median Pdet at 6 and 12 months after surgery was 19.0 and 26.5 cmH₂O in the ICNB group and 28 and 16 cmH₂O in the ECNB group. At 12 months after surgery, the Pdet in the ICNB group was significantly greater than in the ECNB group ($P = 0.027$). The median MUCP at 6 and 12 months after surgery was 30.2 and 46.8 cmH₂O in the ICNB group and 42 and 48 cmH₂O in the ECNB group. There were no significant differences between the groups. The Qmax at 3 months after surgery was 12.7 mL/s in the ICNB group and 14.8 mL/s in the ECNB group, and was maintained throughout the

TABLE 4 Perioperative complications

Type of Complication (number, %)	RARC + ICNB (N = 22)		MIE-RC + ECNB (N = 131)	
	Any grade	≥Grade 3	Any grade	≥Grade 3
Surgical site infection	2 (9.1)	0	18 (13.7)	0
Urinary leak	2 (9.1)	0	11 (8.4)	0
Ileourethral anastomotic stricture	1 (4.5)	1 (4.5)	5 (3.8)	5 (3.8)
Ileus	3 (13.6)	0	4 (3.1)	1 (0.8)
Ileal anastomosis leak	0	0	1 (0.8)	1 (0.8)
Readmission for complications	0		0	

Abbreviations: ECNB, extracorporeal ileal neobladder; ICNB, intracorporeal ileal neobladder; MIE-RC, minimum incision endoscopic radical cystectomy; RARC, robot-assisted radial cystectomy.

TABLE 5 Impact of surgical factors on perioperative outcomes in robot-assisted radical prostatectomy

Cases	Cases 1-7	Cases 8-14	Cases 15-22
Median operation time (min)			
Total console	445	428	330
Cystectomy	100	85	82
Lymph node dissection	22	30	25
Neobladder reconstruction	301	298	213
Median estimated blood loss (mL)	300	330	200
Complication (number)			
Any grade	4	3	1
Grade 3 or higher	0	0	1

follow-up period (data not shown). There were no significant differences between the groups.

Figure 4 shows the continence status. Daytime and night-time continence gradually improved in both groups. There were no significant differences in continence rate between the groups during the follow-up period. Two patients (9.1%) in the RARC group and three (2.3%) in the ECNB group required transient clean intermittent catheterization (CIC) because of greater than 150-mL residual urine.

4 | DISCUSSION

In previous studies, we reported on the open surgical technique and functional outcomes with use of a U-shaped ileal neobladder.^{13,14} Our procedure is simpler, and the operative time is relatively short.^{13,14} In this study, we reported on our robot-assisted ICNB

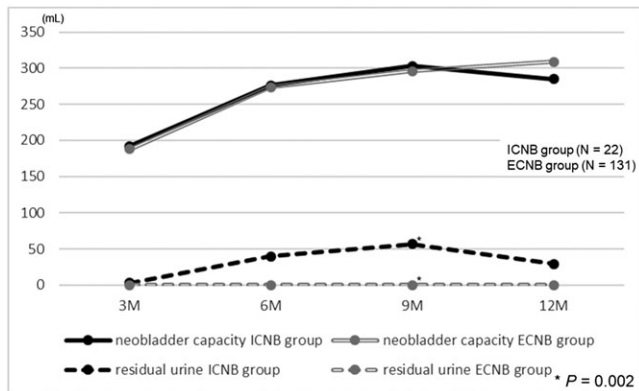


FIGURE 2 Chronologic changes in neobladder capacity and residual urine volume. The neobladder capacity gradually increased in both groups. There were no statistically significant differences between the groups. The residual urine volume remained relatively low throughout the follow-up period in both groups. At 9 months after surgery, the residual urine in the ICNB group was significantly greater than that in the ECNB group ($P = 0.002$)

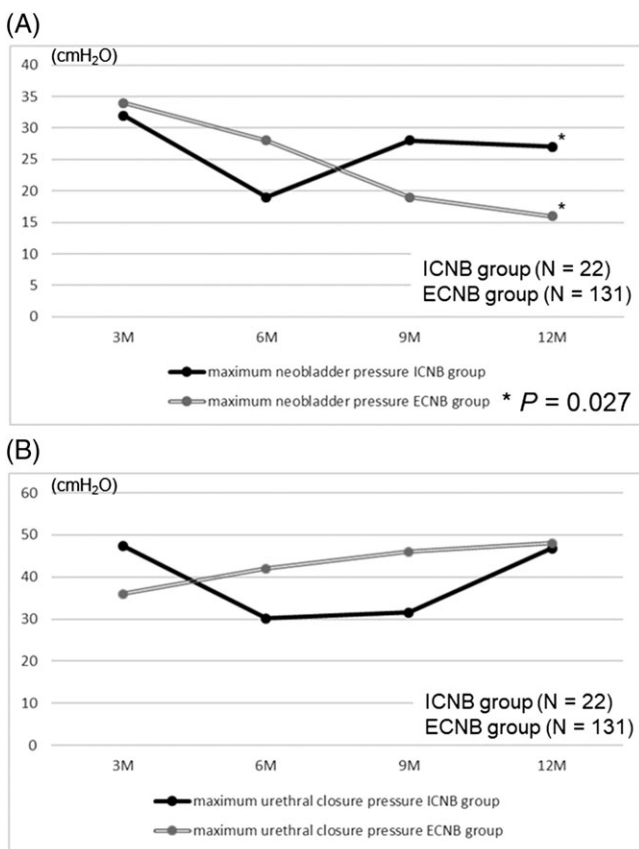


FIGURE 3 Chronologic changes in the maximum neobladder pressure (Pdet) and maximum urethral closure pressure (MUCP). (A) Chronological changes in Pdet with cross-folded U-configuration ileal neobladder. The median Pdet gradually decreased in both groups. At 12 months after surgery, the Pdet in the ICNB group was significantly greater than in the ECNB group ($P = 0.027$). (B) Chronological changes in MUCP with the cross-folded U-configuration ileal neobladder. The MUCP gradually improved in both groups. There were no significant differences between the groups

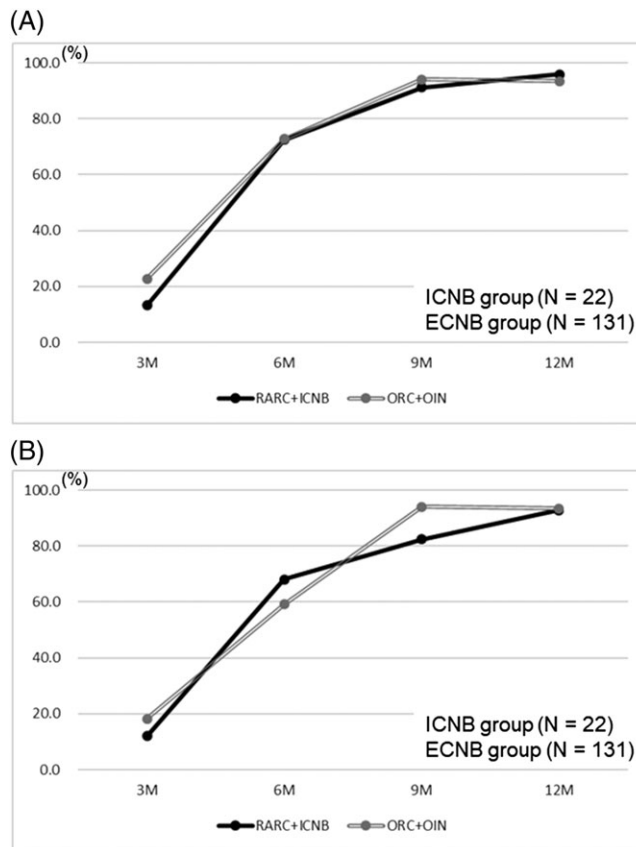


FIGURE 4 Chronological changes in daytime (A) and night-time (B) continence status with cross-folded U-configuration ileal neobladder. The daytime and night-time continence status gradually improved in both groups. There were no statistically significant differences between the groups throughout the follow-up period

technique for replicating the open procedure.^{13,14} The operative time in the ICNB group was significantly longer than that in the ECNB group. However, in five recent cases, the median operative time for all procedures, RARC, and ICNB was 324, 83, and 212 minutes, respectively. We think that the use of our standardized ICNB technique and increasing expertise may contribute to improved surgical outcomes.

The entire intracorporeal procedure, including RARC and reconstruction of the urinary tract, may potentially lead to decreased bowel manipulation/exposure, reduced fluid loss, and a shorter time to oral intake.²³ In fact, ICNB is challenging for the urologist compared with ECNB owing to technical difficulties with the reconfiguration of the ileum and prolonged operative time. Therefore, the adoption of ICNB has been slow and is confined to high-volume academic institutions worldwide.^{9,24,25} An analysis of 18 centers contributing to the IRCC registry showed that 935 patients underwent RARC between 2003 and 2011. Ileal neobladder reconstruction was performed in 198 patients (27.7%), and of these, only 61 (6.5%) received an ICNB.²⁶

Early complications after RC and urinary diversion may occur as a consequence of lymphadenectomy, RC, resection of the ileal segment, and urinary diversion reconstruction. Hautmann et al reported that the majority of all complications after RC and urinary diversion were related to urinary diversion reconstruction.²⁷ Grade 3 complications occurred in 21.8% of 1013 patients who underwent ileal neobladder



reconstruction, with the most common surgery-related complication being infection (24.4%).²⁷ In addition, 23 patients (2.3%) died within 90 days after surgery.²⁷ In an analysis based on the IRCC database, the major complication rate was 20% in RARC patients with intracorporeal urinary diversion, whereas 32% was reported for extracorporeal urinary diversion.⁹ In this study, grade 3 Clavien-Dindo complications occurred in the ICNB group,²² and none of the patients died within 90 days after surgery. However, the complication rates were similar to those reported in large open or RARC series.^{9,27}

It is important to provide patients who undergo ICNB with the best possible urinary continence to maintain their quality of life. Tyrztis et al reported a daytime continence rate of 88% in men and 67% in women at 12 months and night-time continence rates of 76%.²⁸ Simone et al reported 1-year daytime and night-time continence rates of 73.3% and 55.5%, respectively.²⁹ In the ICNB group, daytime and night-time continence rates at 12 months were 93.4% and 93.4%, respectively. In addition, 10% of the patients required CIC. These results were similar in the ECNB group. Studer and Turner proposed that an ideal neobladder should have a large capacity for storage and low pressure and high compliance for continence and should permit voluntary emptying without residual urine.¹² Our surgical technique with ICNB may provide acceptable urinary function. In addition, voiding education may play an important role in achieving a reduced amount of residual urine.

The current study has several limitations. First, this was a retrospective study, with an inherent potential for bias. Second, a relatively small number of patients were enrolled in this study, and the follow-up period was relatively short. A longer period of careful observation for oncological and functional consequences is necessary.

5 | CONCLUSIONS

Our initial experience with cross-folded U-configuration ICNB was favourable, with acceptable surgical outcomes and voiding function after surgery.

ACKNOWLEDGEMENTS

This work was supported by grants-in-aid for Scientific Research from the Japan Society for the Promotion of Science (15H02563 to C.O.), (15K15579 to C.O.), and (17K11118 to T.K.).

CONFLICT OF INTEREST

The authors have stated explicitly that there are no conflicts of interest in connection with this article.

AUTHOR CONTRIBUTIONS

Study concept and design: C.O. and T.K.; acquisition of data, T.K., H.Y. and A.I.; drafting of the manuscript: T.K. and H.N.; critical revision of the manuscript: C.O.; statistical analysis: S.H.; technical and material support: Y.H., T.Y., and S.H.

FUNDING

No specific funding.

FIGURE COPYRIGHT

All authors assure that the manuscript's figures are not copied from other sources.

ORCID

Chikara Ohyama  <http://orcid.org/0000-0003-1550-8379>

REFERENCES

- Novara G, Catto JW, Wilson T, et al. Systematic review and cumulative analysis of perioperative outcomes and complications after robot-assisted radical cystectomy. *Eur Urol*. 2015;67(3):376-401.
- Nix J, Smith A, Kurpad R, Nielsen ME, Wallen EM, Pruthi RS. Prospective randomized controlled trial of robotic versus open radical cystectomy for bladder cancer: perioperative and pathologic results. *Eur Urol*. 2010;57(2):196-201.
- Raza SJ, Wilson T, Peabody JO, et al. Long-term oncologic outcomes following robot-assisted radical cystectomy: results from the International Robotic Cystectomy Consortium. *Eur Urol*. 2015;68(4):721-728.
- Leow JJ, Reese SW, Jiang W, et al. Propensity-matched comparison of morbidity and costs of open and robot-assisted radical cystectomies: a contemporary population-based analysis in the United States. *Eur Urol*. 2014;66(3):569-576.
- Yu HY, Hevelone ND, Lipsitz SR, et al. Comparative analysis of outcomes and costs following open radical cystectomy versus robot-assisted laparoscopic radical cystectomy: results from the US Nationwide Inpatient Sample. *Eur Urol*. 2012;61(6):1239-1244.
- Iwamoto H, Yumioka T, Yamaguchi N, et al. Robot-assisted radical cystectomy is a promising alternative to open surgery in the Japanese population with a high rate of octogenarians. *Int J Clin Oncol*. 2016;21(4):756-763.
- Menon M, Hemal AK, Tewari A, et al. Nerve-sparing robot-assisted radical cystoprostatectomy and urinary diversion. *BJU Int*. 2003;92(3):232-236.
- Menon M, Hemal AK, Tewari A, et al. Robot-assisted radical cystectomy and urinary diversion in female patients: technique with preservation of the uterus and vagina. *J Am Coll Surg*. 2004;198(3):386-393.
- Hussein AA, Ahmed YE, Kozlowski JD, et al. Robot-assisted approach to 'W'-configuration urinary diversion: a step-by-step technique. *BJU Int*. 2017;120(1):152-157.
- Dal Moro F, Zattoni F. Ves.Pa.—Designing a novel robotic intracorporeal orthotopic ileal neobladder. *Urology*. 2016;91:99-103.
- Tan WS, Sridhar A, Goldstraw M, et al. Robot-assisted intracorporeal pyramid neobladder. *BJU Int*. 2015;116(5):771-779.
- Studer UE, Turner WH. The ileal orthotopic bladder. *Urology*. 1995;45(2):185-189.
- Koie T, Hatakeyama S, Yoneyama T, Hashimoto Y, Kamimura N, Ohyama C. Uterus-, fallopian tube-, ovary-, and vagina-sparing cystectomy followed by U-shaped ileal neobladder construction for female bladder cancer patients: oncological and functional outcomes. *Urology*. 2010;75(6):1499-1503.
- Koie T, Hatakeyama S, Yoneyama T, et al. Experience and functional outcome of modified ileal neobladder in 95 patients. *Int J Urol*. 2006;13(9):1175-1179.
- Calvert AH, Newell DR, Gumbrell LA, et al. Carboplatin dosage: prospective evaluation of a simple formula based on renal function. *J Clin Oncol*. 1989;7(11):1748-1756.
- Koie T, Ohyama C, Yamamoto H, et al. Neoadjuvant gemcitabine and carboplatin followed by immediate cystectomy may be associated with a survival benefit in patients with clinical T2 bladder cancer. *Med Oncol*. 2014;31(5):949.
- Koie T, Ohyama C, Hashimoto Y, et al. Efficacies and safety of neoadjuvant gemcitabine plus carboplatin followed by immediate



- cystectomy in patients with muscle-invasive bladder cancer, including those unfit for cisplatin: a prospective single-arm study. *Int J Clin Oncol*. 2013;18(4):724-730.
18. Galsky MD, Hahn NM, Rosenberg J, et al. Treatment of patients with metastatic urothelial cancer "unfit" for cisplatin-based chemotherapy. *J Clin Oncol*. 2011;29(17):2432-2438.
 19. Koie T, Ohyama C, Yamamoto H, et al. The feasibility and effectiveness of robot-assisted radical cystectomy after neoadjuvant chemotherapy in patients with muscle-invasive bladder cancer. *Jpn J Clin Oncol*. 2017;47(3):252-256.
 20. Koie T, Ohyama C, Yamamoto H, et al. Minimum incision endoscopic radical cystectomy in patients with malignant tumors of the urinary bladder: clinical and oncological outcomes at a single institution. *Eur J Surg Oncol*. 2012;38(11):1101-1105.
 21. Paner GP, Stadler WM, Hansel DE, Montironi R, Lin DW, Amin MB. Updates in the eighth edition of the Tumor-Node-Metastasis staging classification for urologic cancers. *Eur Urol*. 2018;73(4):560-569.
 22. Clavien PA, Barkun J, de Oliveira ML, et al. The Clavien-Dindo classification of surgical complications. *Ann Surg*. 2009;250(2):187-196.
 23. Goh AC, Gill IS, Lee DJ, et al. Robotic intracorporeal orthotopic ileal neobladder: replicating open surgical principles. *Eur Urol*. 2012;62(5):891-901.
 24. Desai MM, Gill IS, de Castro Abreu AL, et al. Robotic intracorporeal orthotopic neobladder during radical cystectomy in 132 patients. *J Urol*. 2014;192(6):1734-1740.
 25. Collins JW, Wiklund NP. Totally intracorporeal robot-assisted radical cystectomy: optimizing total outcomes. *BJU Int*. 2014;114(3):326-333.
 26. Ahmed K, Khan SA, Hayn MH, et al. Analysis of intracorporeal compared with extracorporeal urinary diversion after robot-assisted radical cystectomy: results from the International Robotic Cystectomy Consortium. *Eur Urol*. 2014;65(2):340-347.
 27. Hautmann RE, de Petriconi RC, Volkmer BG. Lessons learned from 1,000 neobladders: the 90-day complication rate. *J Urol*. 2010;184(3):990-994.
 28. Tyritzis SI, Hosseini A, Collins J, et al. Oncologic, functional, and complications outcomes of robot-assisted radical cystectomy with totally intracorporeal neobladder diversion. *Eur Urol*. 2013;64(5):734-741.
 29. Simone G, Papalia R, Misuraca L, et al. Robotic intracorporeal Padua ileal bladder: surgical technique, perioperative, oncologic and functional outcomes. *Eur Urol*. 2018;73(6):934-940.

How to cite this article: Koie T, Ohyama C, Yoneyama T, et al. Robotic cross-folded U-configuration intracorporeal ileal neobladder for muscle-invasive bladder cancer: Initial experience and functional outcomes. *Int J Med Robotics Comput Assist Surg*. 2018;14:e1955. <https://doi.org/10.1002/rcs.1955>