

Acute Pneumococcal Myelitis in an Adult Patient

Klaudija Višković, Matej Mustapić¹, Marko Kutleša^{2,3}, Dragan Lepur^{3,4}

Department of Radiology, ³Department of Intensive Care Medicine and Neuroinfectology, University Hospital for Infectious Diseases “Dr. Fran Mihaljević”, ¹Department of Diagnostic and Interventional Radiology, University Hospital Centre “Sestre milosrdnice”, ²School of Medicine, ⁴School of Dental Medicine, University of Zagreb, Zagreb, Croatia

ABSTRACT

Pneumococcal meningitis represents the most severe community-acquired bacterial meningitis. The disease is frequently associated with various complications. We present a case of pneumococcal meningitis in an immunocompetent adult patient treated with hypothermia. The disease course was complicated with severe myelitis and consequent paraplegia which is an extremely rare complication of pneumococcal disease.

Key words: Adult, Bacterial Meningitis, Myelitis, *Streptococcus pneumoniae*

INTRODUCTION

Despite recent advances in antibiotic therapy and critical care, bacterial meningitis continues to have high rates of morbidity and mortality.^[1-3] Pneumococcal meningitis represents the most severe community-acquired bacterial meningitis. The disease is frequently accompanied by various neurological complications.^[4] However, spinal cord involvement is an extremely rare complication.^[5] Possible causes of acute spinal cord dysfunction in those patients are spinal abscess, epidural hemorrhage, ischemia due to vasculitis and finally, myelitis.

We present a case of pneumococcal meningitis in an immunocompetent adult patient treated with hypothermia. The disease course was complicated with acute severe myelitis and consequent paraplegia and loss of bladder control.

CASE REPORT

In February 2009, a previously healthy 63-year-old male was admitted to hospital for an abrupt onset of fever

and progressive mental obtundation. At admission the Glasgow Coma Scale score (GCS) was 4. On examination, right-sided otitis media and purulent discharge were found. The patient's temperature was 36,8° C, pulse 124 and respiration 20. The blood pressure was 137/79 mmHg. The chest and cardiac examination was unremarkable. Neurological examination revealed mild divergent strabismus and eye deviation to the left. Deep tendon reflexes were symmetric and enhanced. Babinski's sign was negative.

Laboratory tests revealed a leukocyte count of $18.5 \times 10^9/L$ (neutrophils 91%, monocytes 7% and lymphocytes 3%). The red blood cell count was $4.7 \times 10^{12}/L$, hemoglobin was 143 g/L and platelets were $172 \times 10^9/L$. Erythrocyte sedimentation rate was 80 per h. C-reactive protein was 75.5 mg/L and fibrinogen was 4.13 g/L. Prothrombin and partial-thromboplastin times were normal. Serum concentration of lactate was 6.0 mmol/L, magnesium 0.5 mmol/L and phosphorus 0.43 mmol/L. Total bilirubin, aminotransferases, lactate dehydrogenase, glucose and alkaline phosphatase were normal. There were no abnormalities on serum protein electrophoresis. The blood level of sodium was 134 mmol/L, potassium 3.0 mmol/L, chloride 97 mmol/L, urea nitrogen 5.0 mmol/L and creatinine 88 $\mu\text{mol}/L$.

Cerebrospinal fluid (CSF) examination revealed 200,000 white cells per cubic millimeter with 95% polymorphonuclear cells. CSF glucose was 0.0 mmol/L, the

Access this article online

Quick Response Code:



Website:
www.jgid.org

DOI:
10.4103/0974-777X.132048

Address for correspondence:

Dr.sc. Klaudija Višković, E-mail: viskovic@gmail.com

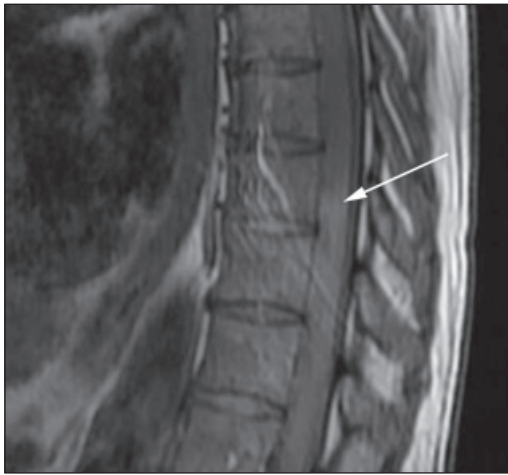

Figure 1: Sagittal T1-weighted image shows scattered multiple intramedullary hyperintensities in the thoracic lumbar cord (arrow)

total protein concentration was 12.1 g/L and lactate 15.9 mmol/L. Treatment consisted of intravenous ceftriaxone (4 g per day) and dexamethasone (48 mg/day) for the first four days. Penicillin-resistant (PRSP) and ceftriaxone-sensitive *Streptococcus pneumoniae* was cultured from CSF.

A native and contrast-enhanced brain CT scans were normal. Transcranial Doppler ultrasonography (TCD) revealed absent diastolic blood flow velocities (BFV) in both the middle cerebral arteries (MCA). BFV in systole were 25 cm/s in the left MCA and 23 cm/s in the right MCA. Pulsatility index (PI) was accordingly increased (4.3 and 3.4, respectively). Mean arterial pressure (MAP) was 72 mmHg. Carbon-dioxide reactivity (CO₂ R) using the breath holding method was significantly impaired [breath holding index (BHI) was 0.80 – normal values 1.03 – 1.65].

A bilateral increase in optic nerve sheath diameter (ONSD) was found at admission (6.6 mm). Mild therapeutic hypothermia (32-34°C) for the next 72 h, accompanied with low doses of norepinephrine support was started immediately after TCD finding was obtained. Hypothermia was induced by intravenous infusion of cold (+4°C - +8°C) isotonic saline and maintained with continuous venovenous hemofiltration (CVVHF) by using a Prismaflex (Gambro Dasco S.p.A., Medolla, Italy) machine. A marked reduction in ONSD during hypothermia was noted as well as significant improvement of mean BFV in both the MCA.

In the week following hypothermia, the patient's condition improved. On day 5, the patient became alert and followed simple commands in spite of mild diffuse brain edema observed on follow-up brain CT scan. However, flaccid paraplegia with areflexia, a sensory level at T8 and loss of

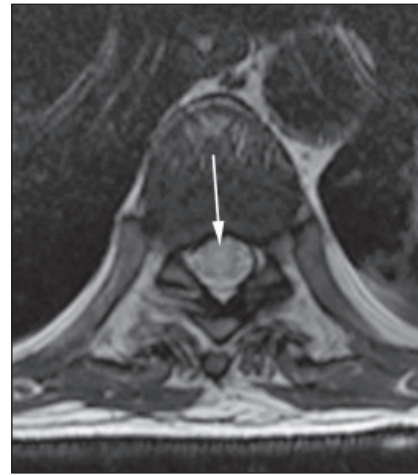


Figure 2: Axial T2-weight image at the level of Th 8 shows central intramedullary hyperintensities that predominantly involve the gray matter (arrow)

bladder control were noted. Repeated lumbar puncture yielded only few drops of bloody-brown fluid shown to be inappropriate for analysis. Magnetic Resonance Imaging (MRI) of the spine revealed scattered multiple hyperintensive lesions of the thoracic medulla in T2-weighted image (T2WI) consistent with myelitis [Figures 1 and 2]. High-dose methylprednisolone (1 g/day IV for five days) followed with total plasma exchange (TPE) (seven exchanges, administered every other day, volume 50 ml/kg each) were without any effect on the neurological deficit.

The patient was transferred to a rehabilitation center two months after the disease onset. At discharge from the hospital his GCS was 15, Glasgow Outcome Scale score (GOS) 3 and Karnofsky performance score 60%. Four months rehabilitation treatment was unsuccessful and the patient remained paraplegic with urinary incontinence.

DISCUSSION

Acute spinal cord dysfunction is a very rare complication of community-acquired bacterial meningitis. Thirty-two cases have been reported in the last 40 years and the great majority was in children (25/32, 78.1%).^[5-8] Characteristic MRI findings were demonstrated in only three adult patients with myelitis so far.^[5] Most patients had permanent neurological deficit manifested by spasticity and weakness, walking difficulties and diverse sensory losses.

A well defined truncal sensory level in our patient was recognized and therefore the possibility of cerebral lesions or peripheral inflammatory polyneuropathy was discarded. MRI of the entire spine was made to rule out the presence of structural lesions or extradural cord compression. Among other possible causes of early spinal dysfunction were

vascular compromises (including cerebral septic venous thrombosis with compromised venous drainage of the spinal cord) or disseminated encephalomyelitis (ADEM). However, there was no evidence of concomitant multifocal cerebral involvement and the finding of spinal MRI dissolved our first concern - epidural or spinal hemorrhage during hypothermia. In a view of MRI finding and absence of hypotension, we were also able to exclude the ischemic infarction. The extensive central intramedullary hyperintensities on T1 and T2WI MRI and the clinical course of the disease were primarily compatible with myelitis [Figures 1 and 2]. Unfortunately, a postcontrast T1 weighted image, the best field-wide imaging tool, was not done by mistake.^[9]

We have not completely discarded the possibility of immune-mediated pathogenic mechanism of such neurological disorder despite prior dexamethasone and hypothermia treatment. Therefore, we have commenced an additional immunosuppressive treatment with methylprednisolone and plasmapheresis. Based on immunosuppressive treatment failure and timing of neurological deficit onset, it seems that the spinal cord damage in our patient was most probably caused by direct bacterial cytotoxic action.

REFERENCES

1. van de Beek D, de Gans J, Tunkel AR, Wijdicks EF. Community-acquired bacterial meningitis in adults. *N Engl J Med* 2006;354:44-53.
2. Durand ML, Calderwood SB, Weber DJ, Miller SI, Southwick FS, Caviness VS, *et al.* Acute bacterial meningitis in adults. A review of 493 episodes. *N Engl J Med* 1993;328:21-8.
3. Lepur D, Barsic B. Community-acquired bacterial meningitis in adults: Antibiotic timing in disease course and outcome. *Infection* 2007;35:225-31.
4. Kastenbauer S, Pfister HW. Pneumococcal meningitis in adults: Spectrum of complications and prognostic factors in a series of 87 cases. *Brain* 2003;126:1015-25.
5. Kastenbauer S, Winkler F, Fesl G, Schiel X, Ostermann H, Yousry TA, *et al.* Acute severe spinal cord dysfunction in bacterial meningitis in adults: MRI findings suggest extensive myelitis. *Arch Neurol* 2001;58:806-10.
6. Moffett KS, Berkowitz FE. Quadriplegia complicating *Escherichia coli* meningitis in a newborn infant: Case report and review of 22 cases of spinal cord dysfunction in patients with acute bacterial meningitis. *Clin Infect Dis* 1997;25:211-4.
7. Kikuchi M, Nagao K, Muraosa Y, Ohnuma S, Hoshino H. Cauda equina syndrome complicating pneumococcal meningitis. *Pediatr Neurol* 1999;20:152-4.
8. Puvabanditsin S, Wojdylo EW, Garrow E, Kalavantavanich K. Group B streptococcal meningitis: A case of transverse myelitis with spinal cord and posterior fossa cysts. *Pediatr Radiol* 1997;27:317-8.
9. Transverse Myelitis Consortium Working Group. Proposed diagnostic criteria and nosology of acute transverse myelitis. *Neurology* 2002;59:499-505.

How to cite this article: Višković K, Mustapić M, Kutleša M, Lepur D. Acute pneumococcal myelitis in an adult patient. *J Global Infect Dis* 2014;6:73-5.
Source of Support: Nil. **Conflict of Interest:** None declared.