

Relationship Between Diabetic Chorea and Timing of MRI Findings: A Systematic Review with Case Reports

Yumi Otaka ¹, Yukinori Harada ¹, Norio Sugawara ², Taro Shimizu¹, Norio Yasui-Furukori ²

¹Department of Diagnostic and Generalist Medicine, Dokkyo Medical University, School of Medicine, Tochigi, Japan; ²Department of Psychiatry, Dokkyo Medical University, School of Medicine, Tochigi, Japan

Correspondence: Norio Yasui-Furukori, Department of Psychiatry, Dokkyo Medical University, School of Medicine, Mibu, Shimotsuga, Tochigi, 321-0293, Japan, Tel +81-282-86-1111, Fax +81-282-86-5187, Email furukori@dokkyomed.ac.jp

Background: Diabetic chorea is a rare complication of diabetes mellitus for which head MRI is the most common diagnostic imaging modality. Cases have been reported where CT and/or MRI findings are inconsistent or clinical symptoms and imaging findings do not appear simultaneously. We aimed to compile the cases in which imaging findings appeared on MRI retests and to examine in a systematic review whether temporal differences in the appearance of imaging findings correlate with clinical characteristics.

Case Presentation: An 80-year-old man with type 2 diabetes mellitus came to a hospital with abnormal movements of the left upper and lower extremities. Two days after the first visit, his symptoms flared up, and his head MRI showed an old cerebral infarction and no new lesion. On day 14, he retested T1-weighted imaging and showed a high signal in the right putamen, which was considered diabetic chorea. Blood glucose was controlled with insulin, and the involuntary movements disappeared.

Methods: PubMed and ICHUSHI were searched to identify patients with diabetic chorea who had undergone MRI retests. Patients grouped by the temporal change in the presence/absence of imaging findings were compared on age, sex, duration of diabetes mellitus, blood glucose level, HbA1c level, side of involuntary movement, time to first MRI, and follow-up MRI.

Results: Of the 64 cases analyzed, 43 (67.2%) were female. The mean age was 69.0 years. 16 (25.0%) had worsening findings upon MRI retesting, 37 (57.8%) had improvement, and 10 (15.6%) had unchanged findings. There were no significant differences in age, sex, mean blood glucose level or HbA1c at onset among the groups.

Conclusion: There was no association between the pattern of appearance of imaging findings over time and clinical characteristics, including glucose levels. If initial MRI findings are negative, MRI retesting after a certain time may help diagnose diabetic chorea.

Keywords: hyperglycemia, hemichorea, hemiballismus, diabetes, movement disorders

Background

Nonketotic hyperglycemia-induced chorea was first described in the 1960s,¹ and diabetic chorea is a disease that causes chorea and ballism associated with hyperglycemia. Although a rare complication of diabetes, nonketotic hyperglycemia is the most common metabolic cause of hemichorea-hemiballismus.^{2,3} It is characterized by acute-onset chorea and hyperintense changes in the striatum on T1-weighted MRI. Its prevalence is 1 in 100,000,³ and it occurs more frequently in older women with type 2 diabetes mellitus. CT and MRI are the most common imaging modalities for detecting striatal abnormalities in diabetic chorea. Chua et al⁴ reported the sensitivity of CT and MRI to be 78.86% and 95.33%, respectively, with MRI being the more reliable test than CT. Furthermore, the discrepancy between CT and MRI findings was reported in 1/6 of cases, and in 1/10 of cases, clinical symptoms and imaging findings of diabetic chorea did not appear simultaneously.⁵ To our knowledge, few reports of MRI being repeated within a short time after negative MRI findings, with the retest showing typical findings. In addition, the characteristics of cases in which MRI is repeated and new imaging findings appear or the imaging findings worsen (increased brightness) are unknown.

Here, we report our experience with a case of worsening imaging findings, and we examine through a systematic review whether changes in the presence/absence of imaging findings over time are correlated with clinical characteristics.

Case Presentation

An 80-year-old man with independent activities of daily living, cerebral infarction, and type 2 diabetes mellitus came to a hospital with a chief complaint of abnormal movements of the left upper and lower extremities. Two days after the first visit, his symptoms flared up, and his head MRI showed only an old cerebral infarction and no new lesion (Figure 1a). On day 7, his movements, including jerking of the left upper and lower extremities, worsened, and on day 11, he started saying things that did not make sense. On day 14, he visited a hospital again and was hospitalized. Physical examination revealed ballism of the left upper and lower extremities, and blood tests showed a blood glucose level of 243 mg/dl, which fluctuated little, an HbA1c of 14.1%, and no evidence of acidosis. On the same day, we suspected stroke, encephalitis or chorea, and head MRI was repeated, in which T1-weighted imaging showed a high signal in the right putamen, which was considered diabetic chorea (Figure 1b). Blood glucose was controlled with insulin, and on the 5th day in the hospital, the blood glucose level dropped below 200 mg/dl at all times, and the involuntary movements disappeared.

Methods

Literature Search Strategy and Selection Criteria

A systematic review was conducted based on PRISMA 2020 (Figure 2). Inclusion criteria were cases of diabetes mellitus combined with chorea and MRI, and exclusion criteria were those without MRI. A literature search on PubMed on 18 June 2022 was conducted by two authors (YO and NYF). The search formula was as follows: (hyperglycemia [TIAB] OR hyperglycemic [TIAB] OR glycemia [TIAB] OR diabetic [TIAB] OR diabetes [TIAB]) AND (chorea [TIAB] OR ballismus [TIAB] OR hemichorea [TIAB] OR hemiballismus [TIAB]). Since the handsearch resulted in many reports from Japan, a literature search was also conducted using ICHUCHI, a Japanese literature search engine that will be available until June 18, 2022. Because the above search formula was used, only abstracts written in English were retrieved.

A total of 392 articles were returned, and the number of cases in the articles was 602. After screening by title and abstract, we first excluded 46 articles written in languages other than English, 55 articles not about diabetic chorea, and one article that was an update of a previous article by the same author. Then, we excluded 44 papers that did not describe the cases in detail, such as reviews and letters to editors. Reviewing all 456 remaining cases, 86 cases without any MRI and 291 cases without repeat MRI were excluded. Of the 79 cases now left, 9 had no T1-weighted MRI, which is needed

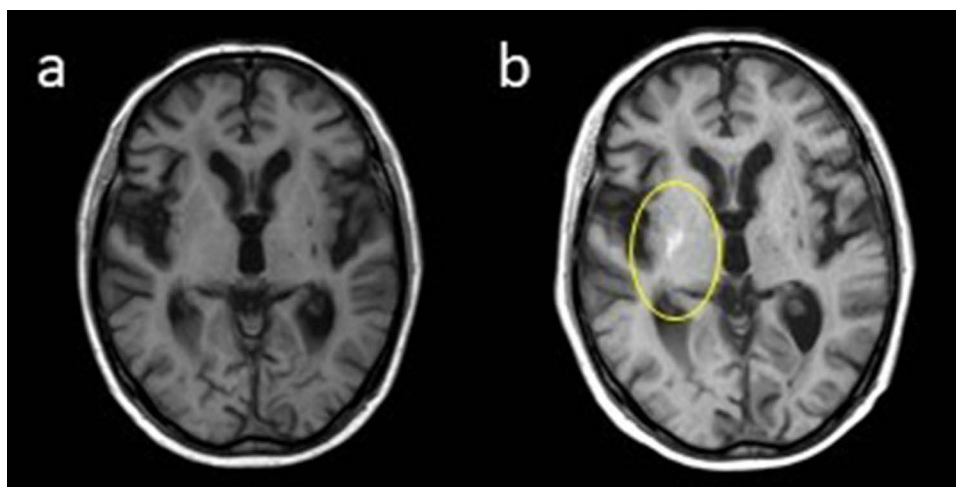


Figure 1 Magnetic resonance imaging (MRI) on the day of examination (a) and 14 days later (b).




Figure 2 Study screening and selection flow chart.

to characterize diabetic chorea; 4 cases had unclear MRIs or findings other than diabetic chorea; and 2 cases had diabetic chorea but no findings on the initial MRI or the repeat MRI, leaving 64 cases in 56 papers (Table 1).^{6–60} We selected age, sex, duration of diabetes mellitus, blood glucose level, HbA1c level, side of involuntary movement, time to first MRI, time to follow-up MRI, plasma osmolality, hyperintense lesion of MRI (T1 weighted image), and course.

Statistical analysis was performed using ANOVA and the χ^2 test with SPSS28 software, with $p < 0.05$ being considered significant.

Results

Of the 64 patients finally analyzed, 20 were male, 43 were female, and 1 was unspecified. The mean age was 69.0 years. First, we divided the 64 patients into 6 groups: (1) 1 case with no initial MRI findings but with retest MRI findings, (2) 15 cases with initial MRI findings and clearer findings on retest MRI (“clearer” means that the high intensity of T1-weighted imaging is more distinct), (3) 24 cases with initial MRI findings and weaker findings on retest MRI, (4) 10 cases with initial MRI findings and unchanged findings on retest MRI, (5) 13 cases with initial MRI findings and no findings on retest MRI and (6) 1 case with initial MRI findings and weaker findings on the left and clearer findings on the right on retest MRI. Afterward, the patients were consolidated into three groups: original groups (1) and (2), 16 patients made up a worsened group; original groups (3) and (5), 37 patients made up an improved group; and original group (4), 10 patients made up an unchanged group (Table 2). One case with a mismatch finding (6) was excluded from the analysis.

There were no differences in age or sex among the three groups. The mean age of the patients in the worsened group was 67 years, and the male-to-female ratio was 4:12. In the improved group, the mean age was 71 years, and the male-to-female ratio was 11:25; in the unchanged group, the mean age was 64 years, and the male-to-female ratio was 5:5. The mean blood glucose at onset was 453 mg/dL in the worsened group, 426 mg/dL in the improved group, and 443 mg/dL in the unchanged group. The mean HbA1c at onset in the worsened group was 14.5%, 12.9% in the improved group, and 12.7% in the unchanged group, all statistically similar (Table 2).

Table 1 Basic Information of All Patients

Case No	Sex	Age (Year)	Duration of Diabetes Mellitus	Glucose (mg/dL)	HbA1c	Plasma Osmolality (mOsm/L)	Side of Involuntary Movement (L,R,Bi)	Time to First MRI (After Onset or Consultation)	First MRI Lesion (TI Hyperintense) (R/L,P,C,G,B)	Time to Follow-Up MRI	F/U MRI Lesion (TI Hyperintense) (R/L,P,C,G,B)	Course	Study
1	F	77	0	NA	NA	NA	R	3 months	Bi,P	11 months	Resolution	Improved	Nagai et al (1995) ⁶
2	M	69	Unknown	597	NA	NA	L	4 days	R,C	3 weeks	R,P,C,G, more clear	Worse	Broderick et al (1995) ⁷
3	M	66	2 years	300	NA	310	R	6 days	L,C	6 months	Diminished	Improved	Lai et al (1996) ⁸
4	M	78	3 years	245	NA	296	Bi	7 days	Bi,P,C,G	6 months	Diminished	Improved	
5	M	67	NA	337	NA	302	R	NA	L,P	6 months	Diminished	Improved	
6	NA	62	NA	688	NA	NA	L→Bi	1 month	R,P,C,G, Cerebral peduncle, internal capsule	26 months	Diminished	Improved	Shan et al (1998) ⁹
7	M	64	1 year	567	17.3%	301	L	11 days	R,P,C	58 days	More clear	Worse	Iwata et al (1999) ¹⁰
8	M	90	20 years	144	8.3%	NA	L	NA	R,B	5 months	Diminished	Improved	Free et al (1999) ¹¹
9	F	22	NA	527	11.1%	299	L	4 days	R,P,C	4 months	More clear	Worse	Oerlemans et al (1999) ¹²
10	M	92	Unknown	320	17.4%	NA	L	24 days	R,P,G	71 days	Diminished	Improved	Ohara et al (2001) ¹³
11	F	60	Unknown	365	NA	NA	R	NA	L,P	6 months	Normal	Improved	Lin et al (2001) ¹⁴
12	F	69	7 years	348	9.5%	NA	L	4 days	R,P,C,G	17 days	Unchanged	Unchanged	Chu et al (2002) ¹⁵
13	F	74	15 years	264	9.7%	NA	L	NA	R,P	2 months	Diminished	Improved	Lee et al (2002) ¹⁶
14	F	63	10 years	1080	NA	375	Bi	NA	Bi,P	4 months	Diminished	Improved	Higa et al (2004) ¹⁷

15	F	28	6 years	481	12.2%	NA	L	NA	Bi,P,C	3 months	Unchanged	Unchanged	Kang et al (2005) ¹⁸
16	M	65	3 years	96	10.9%	NA	R	NA	L,P,C	3 months	Diminished	Improved	Nakano et al (2005) ¹⁹
17	F	81	0	505	13.3%	334.3	Bi	NA	Normal	5 months	Normal	Unchanged	Branca et al (2005) ²⁰
18	M	81	Unknown	NA	NA	NA	L	4 weeks	R,P	6 months	Resolution	Improved	Pisani et al (2005) ²¹
19	F	72	Unknown	507	NA	NA	R→Bi	NA	Bi(R>L),P	6 months	Diminished	Improved	
20	F	78	8 years	473	18%	NA	L	12 days	Bi,B	25 days	More clear	Worse	Chung et al (2005) ²²
21	F	85	30 years	324	14.8%	NA	L→Bi	6 days	R,P	1.5 months	Diminished	Improved	Ohmori et al (2005) ²³
22	M	70	0	560	6.6%	332	L	NA	R,P	9 months	Resolution	Improved	Felicio et al (2008) ²⁴
23	F	78	0	463	10%	NA	L	3 days	R,P	1 year	Resolution	Improved	Battisti et al (2009) ²⁵
24	F	80	0	121	8%	NA	L	33 days	R,P,G	4 months	Diminished	Improved	
25	F	82	0	445	NA	NA	L	14 days	R,G	1 month	R,P,G	Worse	Wang et al (2009) ²⁶
26	F	77	0	459	NA	NA	R	2 days	L,P	13 months	Resolution	Improved	
27	M	37	Unknown	NA	NA	NA	R	NA	L,P	3 months	Unchanged	Unchanged	Duker et al (2010) ²⁷
28	F	63	10 years	1067	14.5	388	Bi	1 year	Bi,G	4 months	R more clear, L diminished	Improved	Higa et al (2010) ²⁸
29	F	98	3 years	589	11.4	314	L	NA	R,G	3 months	Unchanged	Improved	
30	F	82	0	220	14.5%	320	Bi	NA	Bi,P,G	2 weeks	Resolution	Improved	Massaro et al (2012) ²⁹
31	F	77	NA	632	19%	NA	L	4 days	R,P,C	19 days	More clear	Worse	Hashimoto et al (2012) ³⁰
32	F	78	NA	455	14.4%	NA	L	3 days	Bi, P,C,G	35 days	More clear	Worse	

(Continued)

Table I (Continued).

Case No	Sex	Age (Year)	Duration of Diabetes Mellitus	Glucose (mg/dL)	HbA1c	Plasma Osmolality (mOsm/L)	Side of Involuntary Movement (L,R,Bi)	Time to First MRI (After Onset or Consultation)	First MRI Lesion (T1 Hyperintense) (R/L,P,C,G,B)	Time to Follow-Up MRI	F/U MRI Lesion (T1 Hyperintense) (R/L,P,C,G,B)	Course	Study
33	F	76	0	439.6	17.3%	NA	R	NA	L,P,C,G	2 months	More clear	Worse	Padmanabhan et al (2013) ³¹
34	F	78	NA	567	13.90%	NA	L	5 days	R,B	3 months	More clear	Worse	Kaseda et al (2013) ³²
35	F	74	20 years	180	10.7%	299	L	NA	R,P	1 year	Diminished	Improved	Guo et al (2014) ³³
36	F	82	0	239	9.5%	313	R	NA	L,P,C	18 months	diminished	Improved	
37	F	85	Unknown	500	16.2%	NA	Bi	NA	Bi,P	4 months	Resolution	Improved	Lin et al (2014) ³⁴
38	M	82	NA	374	11.5%	NA	L	NA	R,P,C	1 month	Diminished	Improved	Nagai et al (2015) ³⁵
39	F	14	0	349	NA	313.2	L	1 month	R,P,C	4 years	Diminished	Improved	Aquino et al (2015) ³⁶
40	F	55	Unknown	540	NA	NA	L	NA	R,B	NA	Diminished	Improved	Patel et al (2015) ³⁷
41	M	61	0	527	10.3%	NA	L→Bi	NA	R,P	2 months	Unchanged	Unchanged	Ray et al (2015) ³⁸
42	F	68	Unknown	500	15.8%	NA	Bi(L>R)	9 days	R,P,C,G	13 months	Diminished	Improved	Teodoro et al (2015) ³⁹
43	M	86	Unknown	306	11.9%	303.3	L	NA	R,P,C	9 months	Unchanged	Unchanged	Lancellotti et al (2015) ⁴⁰

44	F	57	NA	NA	15.9%	NA	L	2 days	R,B	1 month	More clear	Worse	Suárez-Vega et al (2016) ⁴¹
45	M	52	0	356	16.2%	291	L	NA	R,P,C	6 months	Resolution	Improved	Roy et al (2016) ⁴²
46	F	71	Unknown	822	16.0%	343	Bi	NA	Bi,P,G	1 month	Resolution	Improved	Yu et al (2017) ⁴³
47	M	85	9 years	102	8.1%	NA	R	1 month	L,P,G	2 months	More clear	Worse	Kitagawa et al (2017) ⁴⁴
48	M	58	0	549	16.1%	311	No involuntary movement	7 days	L,P,C	24 days	Unchanged	Unchanged	Sato et al (2017) ⁴⁵
49	F	46	11 years	536	15.7%	335	L	NA	R,P,G	16 months	Diminished	Improved	Son et al (2017) ⁴⁶
50	F	57	NA	NA	14%	NA	L	1 month	R,C,B	5 years	Resolution	Improved	Lucassen et al (2017) ⁴⁷
51	F	76	20 years	558.6	10.5%	NA	R	NA	Bi,P	5 months	Diminished	Improved	Fong et al (2019) ⁴⁸
52	F	69	15 years	NA	NA	NA	R	40 days	L,B	3.5 months	Diminished	Improved	Lin et al (2019) ⁴⁹
53	M	83	NA	505	15.7%	NA	L	7 days	Bi,P,C	3 weeks	Diminished	Improved	Marinelli et al (2019) ⁵⁰
54	F	58	>20 years	219	14.5%	NA	R	2 months	L,P,G	14 days	More clear	Worse	Zheng et al (2020) ⁵¹
55	F	65	10 years	270	16.8%	NA	L	3 months	R,B	6 months	Unchanged	Unchanged	Wang et al (2020) ⁵²

(Continued)

Table I (Continued).

Case No	Sex	Age (Year)	Duration of Diabetes Mellitus	Glucose (mg/dL)	HbA1c	Plasma Osmolality (mOsm/L)	Side of Involuntary Movement (L,R,Bi)	Time to First MRI (After Onset or Consultation)	First MRI Lesion (T1 Hyperintense) (R/L,P,C,G,B)	Time to Follow-Up MRI	F/U MRI Lesion (T1 Hyperintense) (R/L,P,C,G,B)	Course	Study
56	M	61	15 years	414	NA	NA	R	NA	L,P,C	3 weeks	Unchanged	Unchanged	Kammeyer et al (2020) ⁵³
57	M	78	Unknown	167	11.1%	NA	L	NA	R,B	NA	More clear	Worse	Chakales et al (2020) ⁵⁴
58	F	70	0	428	15.2%	NA	L	4 months	R,P,C	6 months	Diminished	Improved	Currò et al (2021) ⁵⁵
59	F	54	Recent	416	9%	NA	R→Bi	NA	L,B	4 months	More clear	Worse	Zhao et al (2021) ⁵⁶
60	F	56	Recent	167	14%	NA	L	NA	R,P,C	4 months	Diminished	Improved	Scamarcia et al (2021) ⁵⁷
61	F	85	6 weeks	1035	14.60%	311 (6 weeks before onset)	NA	NA	R,P	6 months	Normal	Improved	Kataja Knight et al (2021) ⁵⁸
62	F	62	3 years	776	15.8%	NA	L	4 days	Normal	1 month	R,P,C,G	Worse	Rupp et al (2021) ⁵⁹
63	F	54	Unknown	416	18%	NA	L	1 month	R,B	1 month later during current hospitalization	More clear	Worse	Nelson et al (2021) ⁶⁰
64	F	91	Unknown	460	14%	NA	L	NA	R,P,G	6 months	Resolution	Improved	Maia et al (2021) ⁶¹

Abbreviations: M, male; F, female; NA, not available; L, left; R, right; Bi, bilateral; P, putamen; C, caudate; G, globus pallidus; B, basal ganglia.

Table 2 Characteristics of Patients Between Unchanged, Worsened and Improved Groups

	Unchanged n=10	Worsened n=16	Improved n=37	Significance
Age (years)	64.4 (21.2)	67.0 (15.9)	71.2 (14.9)	0.425
Sex	M 5, F 5	M 4, F 12	M 11, F 25	0.392*
Duration of diabetes mellitus (years)	5.2 (5.4)	7.5 (7.2)	6.6 (9.0)	0.852
Glucose	443 (114)	453 (180)	426 (232)	0.904
HbA1c (%)	12.7 (2.6)	14.5 (3.5)	12.9 (3.1)	0.263
Side of involuntary movement (n)	Bi 2, L 5, R 2	Bi 1, L 12, R 3	Bi 9, L 18, R 9	0.490*
Time to first MRI (days)	33.7 (48.8)	14.1 (16.8)	29.1 (32.7)	0.323
Time to follow-up MRI (months)	3.3 (2.7)	1.8 (1.2)	9.4 (12.3)	0.023

Note: *Statistical analyses were performed using Chi square test and others were using ANOVA.

Abbreviations: Bi, bilateral; L, left; R, right.

Discussion

In reviewing the 64 patients with original and repeat MR images, there were no significant differences in age, sex, blood glucose at onset, or HbA1c at onset between the groups with improved, unchanged, or worsened MRI findings. We found only one case reported in which the patient underwent another MRI after the initial negative MRI finding and the MRI finding was positive,⁵⁹ as was the case with our patient. Thus, the case we encountered is the second such case reported. In that case, the MRI findings were negative 4 days after onset, and the patient underwent another MRI approximately 1 month later, which showed a high signal in the right basal ganglia on T1-weighted imaging. The difference is that in the current case, the time until the MRI retest was approximately 1 month, and the symptoms of the initial chorea improved from constant to intermittent, but the symptoms worsened again 1 month later, so another MRI was performed.

The review of case reports revealed that while there are cases in which MRI findings are positive even on the day of onset of involuntary movements, there are also cases in which later MRI findings are positive after initial MRI findings are negative, although such reports are rare even with our case added. These results suggest that imaging findings may not always correlate with the timing of disease, intensity of symptoms, blood glucose level, or HbA1c. In addition, 41 of the 602 patients with negative initial MRI findings were not followed up with a retest MRI. It could be that some of these patients would have had positive MRI findings if the MRI had been repeated after a certain time. Therefore, it is possible that true “MRI-negative” diabetic chorea is less common than reported. When “MRI-negative” cases are difficult to distinguish from other diseases that cause involuntary movements, MRI may aid in the diagnosis of diabetic chorea if it is repeated after a certain time.

The pathophysiology of striatal abnormalities in patients with diabetic chorea and the exact mechanism of chorea onset are not fully understood. Metabolic changes secondary to disruption of the blood–brain barrier may be involved. Hyperglycemia induces an anaerobic metabolic pathway that uses inhibitory neurotransmitters such as acetylcholinesterase and gamma-aminobutyric acid (GABA) as alternative energy sources. As a result, GABA is depleted and acetylcholine synthesis is reduced, leading to dysfunction of the basal ganglia, which is thought to clinically manifest as involuntary movements.^{62,63}

There are several limitations to this study. First, it is a compilation of case reports and not a prospective study, which may lead to publication bias. Second, some of the case reports did not have all the information we wanted, leading to the exclusion of many cases. Third, we searched only two databases (PubMed and ICHUCHI). Since multiple search engines are usually used, the possibility that we missed something cannot be ruled out. Finally, the clinical significance of this study is limited because the topic of the study is not predictive of outcomes. Because patients with diabetic chorea are extremely rare, a national registry project would need to be developed to clarify the details.

Conclusions

This study was a case-reported systematic review of the characteristics of diabetic chorea and the pattern of MRI findings. We attempted to find associations between these patterns and some demographic and clinical characteristics but were unable to do so with the information we collected. We also tried to find associations between the characteristics of imaging findings and the time from the onset of diabetic chorea to MR imaging and the duration of diabetic chorea, but we were unable to perform a sufficient analysis because few case reports clearly described the time to MR imaging or the duration of diabetic chorea.

Data Sharing Statement

All data generated or analyzed during this study are included in this published article.

Ethics Approval and Consent to Participate

We obtained signed consent from the patient for personal use. The ethics committee of the School of Medicine at Dokkyo Medical University judged that there was no need to review this case.

Consent for Publication

We obtained signed consent from the patient for the personal or clinical details to be published in this study.

Author Contributions

All authors made substantial contributions to conception and design, acquisition of data, or analysis and interpretation of data; took part in drafting the article or revising it critically for important intellectual content; agreed to submit to the current journal; gave final approval of the version to be published; and agree to be accountable for all aspects of the work.

Funding

There is no funding to report.

Disclosure

Dr Yukinori Harada reports personal fees from PRECISION, Inc., outside the submitted work. The authors declare that they have no other competing interests in this work.

References

1. Ifergane G, Masalha R, Herishanu YO. Transient hemichorea/hemiballismus associated with new onset hyperglycemia. *Can J Neurol Sci.* 2001;28(4):365–368. doi:10.1017/S0317167100001608
2. Wang W, Tang X, Feng H, et al. Clinical manifestation of nonketotic hyperglycemia chorea: a case report and literature review. *Medicine.* 2020;99(22):e19801. doi:10.1097/MD.00000000000019801
3. Bendi VS, Matta A, Torres-Russotto D, Shou J. Bilateral chorea/ballismus: detection and management of a rare complication of nonketotic hyperglycemia. *BMJ Case Rep.* 2018;2018:bcr2018224856. doi:10.1136/bcr-2018-224856
4. Ondo WG. Hyperglycemic nonketotic states and other metabolic imbalances. *Handb Clin Neurol.* 2011;100:287–291.
5. Chua CB, Sun CK, Hsu CW, Tai YC, Liang CY, Tsai IT. "Diabetic striatopathy": clinical presentations, controversy, pathogenesis, treatments, and outcomes. *Sci Rep.* 2020;10(1):1594. doi:10.1038/s41598-020-58555-w
6. Nagai C, Kato T, Katagiri T, Sasaki H. Hyperintense putamen on T1-weighted MR images in a case of chorea with hyperglycemia. *AJNR Am J Neuroradiol.* 1995;16(6):1243–1246.
7. Broderick JP, Hagen T, Brott T, Tomsick T. Hyperglycemia and hemorrhagic transformation of cerebral infarcts. *Stroke.* 1995;26(3):484–487. doi:10.1161/01.STR.26.3.484
8. Lai PH, Tien RD, Chang MH, et al. Choreo-ballismus with nonketotic hyperglycemia in primary diabetes mellitus. *AJNR Am J Neuroradiol.* 1996;17(6):1057–1064.
9. Shan DE, Ho DM, Chang C, Pan HC, Teng MM. Hemichorea-hemiballismus: an explanation for MR signal changes. *AJNR Am J Neuroradiol.* 1998;19(5):863–870.
10. Iwata A, Koike F, Arasaki K, Tamaki M. Blood brain barrier destruction in hyperglycemic chorea in a patient with poorly controlled diabetes. *J Neurol Sci.* 1999;163(1):90–93. doi:10.1016/S0022-510X(98)00325-6
11. Free T, VanderPol A, Freeman JW. Case report: hemiballismus with unusual MRI findings. *S D J Med.* 1999;52(4):125–126.
12. Oerlemans WG, Moll LC. Nonketotic hyperglycemia in a young woman, presenting as hemiballismus-hemichorea. *Acta Neurol Scand.* 1999;100(6):411–414. doi:10.1111/j.1600-0404.1999.tb01062.x

13. Ohara S, Nakagawa S, Tabata K, Hashimoto T. Hemiballism with hyperglycemia and striatal T1-MRI hyperintensity: an autopsy report. *Mov Disord.* 2001;16(3):521–525. doi:10.1002/mds.1110
14. Lin JJ, Lin GY, Shih C, Shen WC. Presentation of striatal hyperintensity on T1-weighted MRI in patients with hemiballism-hemichorea caused by nonketotic hyperglycemia: report of seven new cases and a review of literature. *J Neurol.* 2001;248(9):750–755. doi:10.1007/s004150170089
15. Chu K, Kang DW, Kim DE, Park SH, Roh JK. Diffusion-weighted and gradient echo magnetic resonance findings of hemichorea-hemiballismus associated with diabetic hyperglycemia: a hyperviscosity syndrome? *Arch Neurol.* 2002;59(3):448–452. doi:10.1001/archneur.59.3.448
16. Lee EJ, Choi JY, Lee SH, Song SY, Lee YS. Hemichorea-hemiballismus in primary diabetic patients: MR correlation. *J Comput Assist Tomogr.* 2002;26(6):905–911. doi:10.1097/00004728-200211000-00009
17. Higa M, Kaneko Y, Inokuchi T. Two cases of hyperglycemic chorea in diabetic patients. *Diabet Med.* 2004;21(2):196–198. doi:10.1111/j.1464-5491.2004.01096.x
18. Kang JH, Kang SY, Choi JC, Lee SS, Kim JS. Chorea triggered by hyperglycemia in a maternally inherited diabetes and deafness (MIDD) patient with the A3243G mutation of mitochondrial DNA and basal ganglia calcification. *J Neurol.* 2005;252(1):103–105. doi:10.1007/s00415-005-0600-y
19. Nakano N, Uchiyama T, Okuda T, Kitano M, Taneda M. Successful long-term deep brain stimulation for hemichorea-hemiballismus in a patient with diabetes. Case report. *J Neurosurg.* 2005;102(6):1137–1141. doi:10.3171/jns.2005.102.6.1137
20. Branca D, Gervasio O, Le Piane E, Russo C, Aguglia U. Chorea induced by nonketotic hyperglycemia: a case report. *Neurol Sci.* 2005;26(4):275–277. doi:10.1007/s10072-005-0471-0
21. Pisani A, Diomedes M, Rum A, et al. Acanthocytosis as a predisposing factor for nonketotic hyperglycemia induced chorea-ballismus. *J Neurol Neurosurg Psychiatry.* 2005;76(12):1717–1719. doi:10.1136/jnnp.2005.067033
22. Chung SJ, Lee JH, Lee SA, No YJ, Im JH, Lee MC. Co-occurrence of seizure and chorea in a patient with nonketotic hyperglycemia. *Eur Neurol.* 2005;54(4):230–232. doi:10.1159/000090717
23. Ohmori H, Hirashima K, Ishihara D, et al. Two cases of hemiballism-hemichorea with T1-weighted MR image hyperintensities. *Intern Med.* 2005;44(12):1280–1285. doi:10.2169/internalmedicine.44.1280
24. Felicio AC, Chang CV, Godeiro-Junior C, Okoshi MP, Ferraz HB. Hemichorea-hemiballismus as the first presentation of type 2 diabetes mellitus. *Arq Neuropsiquiatr.* 2008;66(2A):249–250. doi:10.1590/S0004-282X2008000200022
25. Battisti C, Forte F, Rubenni E, et al. Two cases of hemichorea-hemiballismus with nonketotic hyperglycemia: a new point of view. *Neurol Sci.* 2009;30(3):179–183. doi:10.1007/s10072-009-0039-5
26. Wang JH, Wu T, Deng BQ, Zhang YW, Zhang P, Wang ZK. Hemichorea-hemiballismus associated with nonketotic hyperglycemia: a possible role of inflammation. *J Neurol Sci.* 2009;284(1–2):198–202. doi:10.1016/j.jns.2009.04.005
27. Duker AP, Espay AJ. Images in clinical medicine. Hemichorea-hemiballismus after diabetic ketoacidosis. *N Engl J Med.* 2010;363(17):e27. doi:10.1056/NEJMcic0909769
28. Higa M, Yoshida E, Yamashita K, et al. Clinical features of the four cases of hyperglycemic chorea with poorly controlled diabetes. *Jpn J Med Pharm Sci.* 2010;64(2):259–266.
29. Massaro F, Palumbo P, Falcini M, Zanfranceschi G, Pratesi A. Generalized chorea-ballismus in acute non ketotic hyperglycemia: findings from diffusion-weighted magnetic resonance imaging. *Parkinsonism Relat Disord.* 2012;18(8):998–999. doi:10.1016/j.parkreldis.2012.04.008
30. Hashimoto T, Oguchi K, Takeuchi R. Change in striatal metabolism in diabetic haemichorea-haemiballismus. *BMJ Case Rep.* 2012;2012:bcr2012006405. doi:10.1136/bcr-2012-006405
31. Padmanabhan S, Zagami AS, Poynten AM. A case of hemichorea-hemiballismus due to nonketotic hyperglycemia. *Diabetes Care.* 2013;36(4):e55–6. doi:10.2337/dc12-2048
32. Kaseda Y, Yamawaki T, Ikeda J, et al. Amelioration of persistent, nonketotic hyperglycemia-induced hemichorea by repetitive transcranial magnetic stimulation. *Case Rep Neurol.* 2013;5(1):68–73. doi:10.1159/000350434
33. Guo Y, Miao YW, Ji XF, Li M, Liu X, Sun XP. Hemichorea associated with nonketotic hyperglycemia: clinical and neuroimaging features in 12 patients. *Eur Neurol.* 2014;71(5–6):299–304. doi:10.1159/000357210
34. Lin CM, Liu CK. Bilateral hemiballismus-hemi-chorea presenting in a diabetes Taiwanese woman. *Neurol Int.* 2014;6(3):5519. doi:10.4081/ni.2014.5519
35. Nagai J, Yamada T, Cao X, et al. Cranial magnetic resonance imaging and angiography findings in a patient with hyperglycemic hemichorea-hemiballismus. *J Clin Endocrinol Metab.* 2015;100(1):11–12. doi:10.1210/jc.2014-2576
36. Aquino JH, Spitz M, Pereira JS. Hemichorea-hemiballismus as the first sign of type 1b diabetes during adolescence and its recurrence in the setting of infection. *J Child Neurol.* 2015;30(10):1362–1365. doi:10.1177/0883073814553972
37. Patel B, Ladva ZR, Khan U. Hemichorea-hemiballismus: a case report. *Pract Neurol.* 2015;15(3):222–223. doi:10.1136/practneurol-2014-001063
38. Ray S, Howlader S, Chakraborty S, Chakraborty PP, Ghosh S. Hemichorea-hemiballismus as the first presentation of type 2 diabetes. *Clin Diabetes.* 2015;33(2):87–89. doi:10.2337/diaclin.33.2.87
39. Teodoro T, Lobo PP, Ferreira J, et al. Delayed Parkinsonism after acute chorea due to nonketotic hyperglycemia. *J Neurol Sci.* 2015;354(1–2):116–117. doi:10.1016/j.jns.2015.04.039
40. Lancellotti G, Sagot C, Forest A, Greffard S, Bertrand A, Verny M. An unusual case of hemiballismus-hemichorea associated with nonketotic hyperglycemia in association with a centrum semiovale stroke. *J Am Geriatr Soc.* 2015;63(8):1720–1721. doi:10.1111/jgs.13577
41. Suárez-Vega VM, Sánchez Almaraz C, Bernardo AI, Rodríguez-Díaz R, Díez Barrio A, Martín Gil L. CT and MR unilateral brain features secondary to nonketotic hyperglycemia presenting as hemichorea-hemiballismus. *Case Rep Radiol.* 2016;2016:5727138. doi:10.1155/2016/5727138
42. Roy U, Das SK, Mukherjee A, et al. Irreversible hemichorea-hemiballismus in a case of nonketotic hyperglycemia presenting as the initial manifestation of diabetes mellitus. *Tremor Other Hyperkinet Mov.* 2016;6:393. doi:10.5334/tohm.301
43. Yu F, Steven A, Birnbaum L, Altmeyer W. T2*-based MR imaging of hyperglycemia-induced hemichorea-hemiballismus. *J Neuroradiol.* 2017;44(1):24–30. doi:10.1016/j.neurad.2016.09.005
44. Kitagawa M, Yamanaka Y, Adachi T, et al. Diabetic hemichorea-hemiballismus after prompt improvement in hyperglycemia. *Intern Med.* 2017;56(22):3073–3076. doi:10.2169/internalmedicine.8615-16
45. Sato H, Hamano M, Fushimi E, Takahashi T, Horikawa Y, Horiguchi S. Diabetic striatopathy manifesting as severe consciousness disturbance with no involuntary movements. *Diabet Med.* 2017;34(12):1795–1799. doi:10.1111/dme.13526
46. Son BC, Choi JG, Ko HC. Globus pallidus internus deep brain stimulation for disabling diabetic hemiballismus/hemichorea. *Case Rep Neurol Med.* 2017;2017:2165905. doi:10.1155/2017/2165905

47. Lucassen EB, Delfyett WT, Stahl MC. Persistent hemichorea and caudate atrophy in untreated diabetic striatopathy: a case report. *Case Rep Neurol.* 2017;9(3):299–303. doi:10.1159/000484201
48. Fong SL, Tan AH, Lau KF, Ramli N, Lim SY. hyperglycemia-associated hemichorea-hemiballismus with predominant ipsilateral putaminal abnormality on neuroimaging. *J Mov Disord.* 2019;12(3):187–189. doi:10.14802/jmd.19014
49. Lin YT, Chen SC, Yip PK, Wang V. Magnetic resonance imaging volumetric analysis for diabetic striatopathy with two episodes of hemichorea-hemiballismus syndrome: a case report. *Medicine.* 2019;98(38):e17249. doi:10.1097/MD.00000000000017249
50. Marinelli L, Maggi D, Trompetto C, Renzetti P. Neuroradiological evolution of glyceic hemichorea-hemiballismus and the possible role of brain hypoperfusion. *Eur J Case Rep Intern Med.* 2019;6(11):001257. doi:10.12890/2019_001257
51. Zheng W, Chen L, Chen JH, et al. Hemichorea associated with nonketotic hyperglycemia: a case report and literature review. *Front Neurol.* 2020;11:96. doi:10.3389/fneur.2020.00096
52. Wang DM, Su S, Lin ZZ, Lai LY, Wu YM, Wang SN. Recurrent hemichorea in a patient with diabetes and anti-phospholipid syndrome: a case report. *Chin Med J.* 2020;133(6):753–755. doi:10.1097/CM9.0000000000000698
53. Kammeyer RM, Orjuela KD. Rapidly progressive dementia and temporal lobe atrophy in a case of nonketotic hyperglycemic hemichorea. *Neurohospitalist.* 2020;10(3):229–233. doi:10.1177/1941874420902875
54. Chakales P, Park A, Amos A, Baldinger E, Sirotkin I, Frontera A. Hemiballismus in patients with poorly controlled type 2 diabetes mellitus. *Fed Pract.* 2020;37(6):282–287. doi:10.1016/j.parkreldis.2011.08.015
55. Currò CT, Nicocia G, Ziccone V, et al. Pimozide and pancreatic cancer in diabetic chorea: a case report. *Int J Neurosci.* 2021;3:1–4.
56. Zhao S, Wu S, Feng L, et al. Hemichorea induced by nonketotic hyperglycemia evaluated with 18F-FDG and 11C-CFT PET/CT. *Eur J Nucl Med Mol Imaging.* 2021;48(9):3001–3002. doi:10.1007/s00259-021-05240-3
57. Scamarcia PG, Agosta F, Anzalone N, Volontè MA, Filippi M. Striatal atrophy and hypometabolism in drug-resistant non-ketotic hyperglycemic chorea-ballismus. *Mov Disord Clin Pract.* 2021;8(3):486–488. doi:10.1002/mdc3.13155
58. Kataja Knight A, Magnusson P, Sjöholm Å. Hemiballismus in hyperglycemia. *Clin Case Rep.* 2021;9(5):e04343. doi:10.1002/ccr3.4343
59. Rupp J, Gillespie A. A case of diabetic hemichorea hemiballismus exacerbated by hypoglycemia. *AACE Clin Case Rep.* 2021;7(5):327–329. doi:10.1016/j.aace.2021.04.004
60. Nelson CC, Ohnoutka C, Ulen M. Non-ketotic hyperglycemic hemichorea-hemiballismus in the setting of antipsychotics and methamphetamine. *Cureus.* 2021;13(10):e19094. doi:10.7759/cureus.19094
61. Maia M, Moreira AP, Gonçalves AI, Espírito Santo J, Araújo J. Hemichorea-hemiballismus as a manifestation of hyperglycemia. *Cureus.* 2021;13. doi:10.7759/cureus.19330
62. Aggarwal A, Bansal N, Aggarwal R. Nonketotic hyperglycemia presenting as monoballismus. *J Emerg Med.* 2016;50(3):e133–4. doi:10.1016/j.jemermed.2015.11.016
63. Shafait S, Alamgir W, Shafique M. Hyperglycemia presenting with hemichorea-hemiballismus and T-1 hyperintensity on MRI brain. *J Coll Physicians Surg Pak.* 2021;31(10):1228–1230.

International Journal of General Medicine

Dovepress

Publish your work in this journal

The International Journal of General Medicine is an international, peer-reviewed open-access journal that focuses on general and internal medicine, pathogenesis, epidemiology, diagnosis, monitoring and treatment protocols. The journal is characterized by the rapid reporting of reviews, original research and clinical studies across all disease areas. The manuscript management system is completely online and includes a very quick and fair peer-review system, which is all easy to use. Visit <http://www.dovepress.com/testimonials.php> to read real quotes from published authors.

Submit your manuscript here: <https://www.dovepress.com/international-journal-of-general-medicine-journal>