

Adrenal Collision Tumor Composed of Pheochromocytoma and Diffuse Large B-Cell Lymphoma: A Case Report

Atieh Khorsand¹, Fatemeh Khatami², Salma Sefidbakht¹, Hiva Saffar¹, Alireza Sadeghipour³, Seyed Mohammad Tavangar¹

¹Department of Pathology, Shariati Hospital, Tehran University of Medical Sciences, Tehran, Iran

²Chronic Diseases Research Center, Endocrinology and Metabolism Population Sciences Institute, Tehran University of Medical Sciences, Tehran, Iran

³Department of Pathology, Rasool-e-Akram Hospital, Iran University of Medical Sciences, Tehran, Iran

Corresponding Author: Seyed Mohammad Tavangar, Department of Pathology, Shariati Hospital, Tehran University of Medical Sciences, Tehran, Iran

Tel.: +98 21 84902187

Fax: +98 21 88633078

E-mail: Tavangar@ams.ac.ir

Received: 7, Jan, 2018
Accepted: 16, Jun, 2018

ABSTRACT

Adrenal involvement in the course of malignant lymphoma occurs in about 4% of patients, but primary adrenal lymphoma (PAL) is extremely rare. To the best of our knowledge, only one case study reported the combination of PAL with pheochromocytoma. In the current study, we present the second case who was a 63-year-old man admitted to our hospital with hematuria and abdominal discomfort. Ultrasound imaging indicated the presence of a lesion, 5×4×3 cm in size, in the upper pole of his right kidney. Histopathologic study confirmed a collision tumor composed of pheochromocytoma and diffuse large B-cell lymphoma (DLBCL).

Keywords: Collision tumor, Diffuse large B-cell lymphoma, Pheochromocytoma

INTRODUCTION

Primary lymphomas of endocrine glands are extremely rare and usually involve thyroid gland and less commonly adrenal glands¹. Pheochromocytomas as the neoplastic transformation of chromaffin cells of sympatoadrenal system are also rare and usually pure neoplasms²⁻⁴. Coexistence of PAL and pheochromocytoma is very rare and we describe a unique presentation of this association⁵.

Case presentation

A 63-year-old man with three different episodes of renal colic and painful hematuria was referred to our hospital. He had no specific medical history or hormonal symptoms. Physical examination was unremarkable and he had normal vital signs. In paraclinical investigations, ultrasound imaging revealed a mass in upper pole of right kidney. Pheochromocytoma workup was negative. The patient underwent right adrenalectomy. The submitted sample for pathologic study consisted of multiple fragmented irregular tumoral tissues, weighting 95 gram measuring totally 5×4×3 cm.

Microscopic examinations showed two separated areas, one component was composed of nests and sheets of neoplastic large polyhedral cells in a vascularized stroma. The cells had round to oval moderately pleomorphic nuclei, distinct nucleoli and basophilic cytoplasm.

In many areas, tumoral cells were invaded and trapped by the second population of small round tumoral cells with high N/C ratio, vesicular mildly pleomorphic nuclei and thick irregular nuclear membrane. A lot of mitotic figures were identified. Immunohistochemical (IHC) staining signified these cells as positive cells for CD20 and BCL2, and negative for CK, CD3, BCL-6, MUM-1 and CD10 (Figure 2). Ki67 staining showed proliferative activity in about 60% of tumor cells. Histologically, the tumor approximately consisted of 80% typical pheochromocytomas and 20% diffuse large B-cell lymphoma (DLBCL) (Figure 1). IHC studies in the pheochromocytoma component showed positivity of tumor cells for synaptophysin and chromogranin (Figure 3).

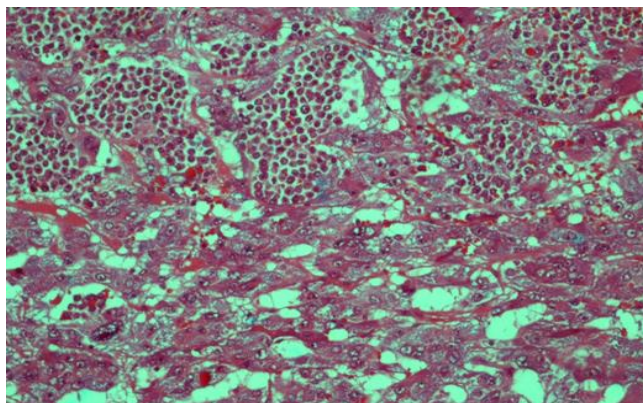


Figure 1: (H&E, times 250) Boundary between pheochromocytoma and Lymphoma

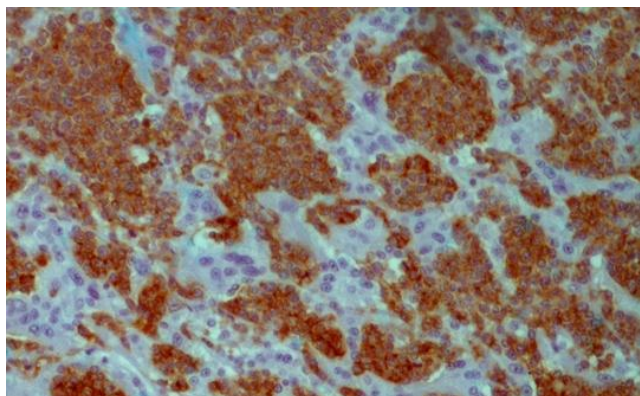


Figure 2: IHC (x400), Lymphoma cells show positive reaction for CD20 antigen

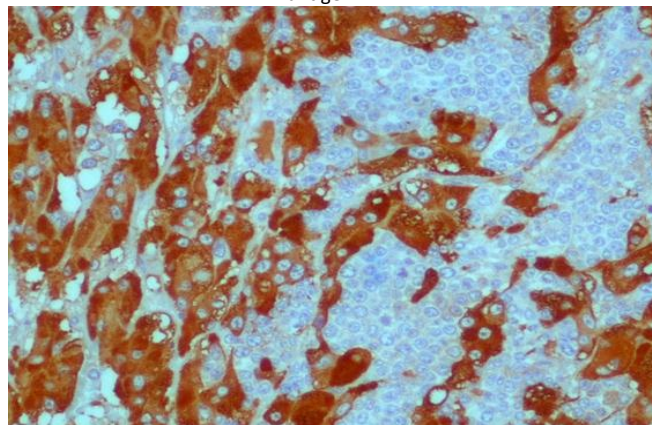


Figure 3: IHC (x400), The pheochromocytoma component shows strong immune reactive for chromogranin antibody

DISCUSSION

Adrenal collision tumors (ACTs) by definition show the presence of two independent tumors in one adrenal gland. Co-occurrence of pheochromocytoma with neuroblastoma, ganglioneuroblastoma, ganglioneuroma or malignant peripheral nerve sheath tumor (MPNST) has been reported several times during the past 70 years⁶⁻⁹.

In one review, Brian R Untch et al. showed that all ACLs had one component of primary adrenal tumors and the second component in most cases was metastasis¹⁰. The latter tumoral component can be lymphoma¹¹.

PAL is usually represented with bilateral large masses, sometimes accompanied by adrenal insufficiency, most frequently affecting older men¹². The lymphoma part of our case was DLBCL which can arise in almost any part of the body and the first manifestation of this cancer is typically a rapidly growing mass, sometimes associated with B symptoms—fever, weight loss, and night sweats¹³. Our case showed none of the above-mentioned symptoms.

On the other hand, one of primary adrenal tumors that can be seen in ACLs is pheochromocytoma which secretes catecholamines, and therefore headache, sweating palpitations and hypertension are the most common symptoms. Our case had none of these symptoms and biochemically was negative for pheochromocytoma markers. Pheochromocytomas with negative urine and serum markers are not uncommon^{14,15}. Heavner et al.

showed some differences between marker-negative and marker positive patients, including different mean BMI and presentation signs (more vertigo/dizziness in marker-negative patients)¹⁴.

The majority of pheochromocytomas are benign and curable by resection. However, differentiation between benign and malignant pheochromocytoma is one of the most challenging areas in endocrine pathology. Application of pheochromocytoma of the Adrenal Gland Scaled Score (PASS) is one the recent attempts for distinguishing pheochromocytomas with malignant potential, which showed great inter-and intra-observer variation¹⁶. Immunohistochemical study is a great method in detection of different aspects of diagnosis and treatment¹⁷⁻²³. In one study, Saffar et al. examined 55 cases of pheochromocytoma and determined the expression of galectin-3, COX-2, and nm-23 among them²⁴. They showed that the presence of these markers along with tumor size and tumor necrosis can be a reasonable predictor of this disease outcome.

In another study, Haji Amousha, et al. used the pituitary tumor-transforming gene (PTTG1) to predict malignant behavior of pheochromocytomas²⁵. They showed that this IHC marker had 100% specificity and 100% PPV for malignant behavior prediction. Ki67, c-erbB-2 and c-kit antigens were also used as predictor markers of tumor behavior in another study by Tavangar et al¹⁹. Their study demonstrated that these markers could be used to determine the behavior of tumors. The pheochromocytoma part of our case had no metastasis and showed benign behavior.

CONCLUSION

The results of the study highlight the need to increase awareness of rare entities such as ACLs for proper diagnosis of adrenal masses in paraclinical investigations which is critical for staging and treatment.

ACKNOWLEDGMENT

The authors would like to express their appreciation to Department of Pathology, Shariati Hospital, Tehran University of Medical Sciences, Tehran, Iran.

CONFLICT OF INTERESTS

The authors declare no conflict of interest.

REFERENCES

1. Hatjiharissi E, Diamantidis M, Papaioannou M, et al. Long-term outcome of primary endocrine non-Hodgkin lymphomas: does the site make the difference? *QJM*. 2013;106(7):623-30.
2. Juarez D, Brown RW, Ostrowski M, et al. Pheochromocytoma associated with neuroendocrine carcinoma: a new type of composite pheochromocytoma. *Arch Pathol Lab Med*. 1999;123(12):1274-9.
3. Haghpanah V, Soliemanpour B, Heshmat R, et al. Endocrine cancer in Iran: based on cancer registry system. *Indian J Cancer*. 2006;43(2):80-5.
4. Larijani B, Shirzad M, Mohagheghi MA, et al. Epidemiologic feature of thyroid cancer based on cancer registry data system. *Iranian J Publ Health*. 2005; 34(4): 1-7.
5. Babinska A, Peksa R, Sworczak K. Primary malignant lymphoma combined with clinically "silent" pheochromocytoma in the same adrenal gland. *World J Surg Oncol*. 2015; 13: 289.
6. Brady S, Lechan RM, Schwaitzberg S, et al. Composite pheochromocytoma/ganglioneuroma of the adrenal gland associated with multiple endocrine neoplasia 2A: case report with immunohistochemical analysis. *Am J Surg Pathol*. 1997;21(1):102-8.
7. Tatekawa Y, Muraji T, Nishijima E, et al. Composite pheochromocytoma associated with adrenal neuroblastoma in an infant: a case report. *J Pediatr Surg*. 2006;41(2):443-5.
8. Ch'ng E, Hoshida Y, Iizuka N, et al. Composite malignant pheochromocytoma with malignant peripheral nerve sheath tumour: a case with 28 years of tumour-bearing history. *Histopathology*. 2007;51(3):420-2.
9. Khan AN, Solomon SS, Childress RD. Composite pheochromocytoma-ganglioneuroma: a rare experiment of nature. *Endocr Pract*. 2010;16(2):291-9.
10. Untch BR, Shia J, Downey RJ, et al. Imaging and management of a small cell lung cancer metastasis/adrenal adenoma collision tumor: a case report and review of the literature. *World J Surg Oncol*. 2014;12:45.
11. Hagspiel KD. Manifestation of Hodgkin's lymphoma in an adrenal myelolipoma. *Eur Radiol*. 2005;15(8):1757-9.
12. Ezer A, Parlakgümüş A, Kocer NE, et al. Primary adrenal non-Hodgkin's lymphoma: report of two cases. *Turk J Gastroenterol*. 2011;22(6):643-7.
13. Smith A, Roman E, Howell D, et al. The Haematological Malignancy Research Network (HMRN): a new information strategy for population based epidemiology and health service research. *Br J Haematol*. 2010;148(5):739-53.
14. Heavner MG, Krane LS, Winters SM, et al. Pheochromocytoma diagnosed pathologically with

- previous negative serum markers. *J Surg Oncol*. 2015;112(5):492-5.
15. Softysiak M, Gołofit P, Łokaj M, et al. Biochemically silent pheochromocytoma—rare, but not uncommon. Case study. *Arterial Hypertens*. 2015;19(4):200-202.
16. Wu D, Tischler AS, Lloyd RV, et al. Observer variation in the application of the Pheochromocytoma of the Adrenal Gland Scaled Score. *Am J Surg Pathol*. 2009;33(4):599-608.
17. Sarmadi S, Izadi-Mood N, Sotoudeh K, et al. Altered PTEN expression; a diagnostic marker for differentiating normal, hyperplastic and neoplastic endometrium. *Diagn Pathol*. 2009;4:41.
18. Kajbafzadeh A-M, Payabvash S, Salmasi AH, et al. Smooth muscle cell apoptosis and defective neural development in congenital ureteropelvic junction obstruction. *J Urol*. 2006;176(2):718-23.
19. Tavangar SM, Shojaee A, Moradi Tabriz H, et al. Immunohistochemical expression of Ki67, c-erbB-2, and c-kit antigens in benign and malignant pheochromocytoma. *Pathol Res Pract*. 2010;206(5):305-9.
20. Haghpanah V, Shooshtarizadeh P, Heshmat R, et al. Immunohistochemical analysis of survivin expression in thyroid follicular adenoma and carcinoma. *Appl Immunohistochem Mol Morphol*. 2006;14(4):422-5.
21. Mohammadi-asl J, Larijani B, Khorgami Z, et al. Qualitative and quantitative promoter hypermethylation patterns of the P16, TSHR, RASSF1A and RARβ2 genes in papillary thyroid carcinoma. *Med Oncol*. 2011;28(4):1123-8.
22. Sabetkish S, Kajbafzadeh AM, Sabetkish N, et al. Whole-organ tissue engineering: Decellularization and recellularization of three-dimensional matrix liver scaffolds. *J Biomed Mater Res A*. 2015;103(4):1498-508.
23. Omidfar K, Moinfar Z, Sohi AN, et al. Expression of EGFRvIII in thyroid carcinoma: immunohistochemical study by camel antibodies. *Immunol Invest*. 2009;38(2):165-80.
24. Saffar H, Sanii S, Heshmat R, et al. Expression of galectin-3, nm-23, and cyclooxygenase-2 could potentially discriminate between benign and malignant pheochromocytoma. *Am J Clin Pathol*. 2011;135(3):454-60.
25. Haji Amousha MR, Sabetkish N, Heshmat R, et al. Expression of the pituitary tumor transforming gene (PTTG1) in pheochromocytoma as a potential marker for distinguishing benign versus malignant tumors. *Acta Med Iran*. 2015;53(4):236-41.