

Greater Omental Lymph Node Flap for Upper Limb Lymphedema with Lymph Nodes–depleted Patient

Yu-Ying Chu, MD*

Robert J. Allen, Jr, MD*

Ting-Jung Wu, MD†

Ming-Huei Cheng, MD, MBA*‡

Background: The greater omentum is supplied by the right, middle, and left omental arteries, which arise from the right and left gastroepiploic arteries. All or part of the greater omentum can be harvested based on this blood supply for free tissue transfer. It has stimulated new interest in its use as the donor site in the treatment of lymphedema. For patients who have failed other management options or have limited peripheral lymph node donor sites, the greater omental lymph node flap may offer the best chance for lymphedema treatment.

Methods: We report a 59-year-old woman with a history of left breast cancer who was treated with left modified radical mastectomy and axillary lymph node dissection and developed left upper extremity Grade IV lymphedema. She received vascularized groin lymph node transfer and lymphaticovenous anastomosis, but the result was not satisfactory. She also had nasopharyngeal cancer that was treated with radiotherapy to the head and neck, making use of the submental lymph nodes flap impossible. Due to a lack of other options of lymph node donor sites, the split greater omental lymph node flap (GOLF) was used.

Results: After surgery, it showed an arm circumference reduction of 42.9% above the elbow and 36.4% below the elbow at an 8-month follow-up. There was no intraabdominal complication.

Conclusions: The split GOLF has shown good results in a peripheral lymph node–depleted lymphedema patient. Using a laparoscopic technique for flap harvest has less risk of donor site morbidity and hides scarring. (*Plast Reconstr Surg Glob Open* 2017;5:e1288; doi: 10.1097/GOX.0000000000001288; Published online 25 April 2017.)

The greater omentum is an apron-like fold of peritoneum suspended from the greater curvature of the stomach and transverse colon.¹ The omentum functions in the protection of the underlying viscera and immunoregulation of the peritoneal cavity. As a highly vascularized tissue, the greater omentum is supplied by the right, middle, and left omental arteries, which arise from the right and left gastroepiploic arteries. All or part of the greater omentum can be harvested based on this blood supply, with ample pedicle length as needed for a free tissue transfer.² Given its

large size, extensive blood supply and pliability, the greater omental flap has been used for reconstruction throughout the body, including the head, neck, and trunk, as well as the extremities.² Recently, the presence of lymphatic tissues within the greater omentum has also stimulated interest in its use in the treatment of lymphedema.

Worldwide, it is estimated that up to 250 million people suffer from lymphedema.³ In developing countries, the most common causative factor of lymphedema is filariasis, whereas in the developed world, chronic lymphedema of the extremities most commonly results from cancer treatment. Approximately 5%–20% of patients undergoing lymph node dissection suffer from this unfortunate condition.⁴ Lymphedema is a debilitating disease that is difficult to treat and poses a significant economic burden to health care. Thus, many surgical methods to treat lymphedema have been proposed. These include lymphaticove-

From the *Division of Reconstructive Microsurgery, Department of Plastic and Reconstructive Surgery, Chang Gung Memorial Hospital, Chang Gung University, College of Medicine, Taoyuan, Taiwan, and †Department of General Surgery and ‡Center for Tissue Engineering, Chang Gung Memorial Hospital, Linkou, Taiwan.

Received for publication July 19, 2016; accepted February 15, 2017.

Copyright © 2017 The Authors. Published by Wolters Kluwer Health, Inc. on behalf of The American Society of Plastic Surgeons. This is an open-access article distributed under the terms of the Creative Commons Attribution-Non Commercial-No Derivatives License 4.0 (CCBY-NC-ND), where it is permissible to download and share the work provided it is properly cited. The work cannot be changed in any way or used commercially without permission from the journal.

DOI: 10.1097/GOX.0000000000001288

Disclosure: The authors have no financial interest to declare in relation to the content of this article. The Article Processing Charge was paid for by Ming-Huei Cheng at Chang Gung Memorial Hospital.

Supplemental digital content is available for this article. Clickable URL citations appear in the text.

nous anastomosis,^{5–10} lymphatico-lymphatic anastomosis,¹¹ vascularized lymph node transfer,^{12–19} and liposuction^{20–22}; however, the outcomes of these methods have been variable. Perhaps the most recent and promising of these therapies is the transplantation of vascularized lymph nodes from one area of the body to an affected region using microsurgical techniques. The groin and submental areas are reported as the most commonly used vascularized lymph node transfer donor sites,^{12,13,15} whereas the peritoneal cavity is rarely utilized. For patients who have failed other treatment options or have limited peripheral lymph node donor sites, the greater omental lymph node flap (GOLF) may offer the best approach for lymphedema treatment.

The GOLF can be transferred as a pedicled flap or free flap.^{23–31} The first animal study using omental tissue for the treatment of lymphedema was described in 1966 when Goldsmith et al.²³ transposed omental tissue via a subcutaneous tunnel to the leg in a canine model. Subsequently, Nakajima et al.³² were the first to report omental flap transposition to the axilla to treat upper extremity lymphedema. Since these initial reports, laparoscopy has become widely used in abdominal surgery as a minimally invasive technique. Saltz et al.³³ described this approach using laparoscopic harvesting omental flap for large defect coverage in a canine model in 1993. Kamei et al.³⁴ further modified laparoscopic omentum harvesting with their work in human subjects in 1998. The advances in both laparoscopic and microsurgical techniques combined with an increased understanding of lymphedema over the past decades have emerging interest in the greater omentum for its use as a vascularized lymph node donor site. For patients who have failed previous lymph node transfers, have refractory lymphedema, or have limited lymph

node donor sites, the GOLF may provide the last option for surgical treatment of this disease. In this article, we present a novel case using a laparoscopically harvested split GOLF for vascularized lymph node transfer in a peripheral lymph node–depleted patient.

CASE PRESENTATION

A 59-year-old woman with a history of left breast cancer was treated with left breast lumpectomy and radiation in 2001. Subsequently, she developed recurrent breast cancer and underwent a left modified radical mastectomy with axillary lymph node dissection in 2006. In this context, the patient then developed left upper extremity Grade IV lymphedema (Cheng's Grading System)^{16,35} that resulted in recurrent episodes of cellulitis (Fig. 1). After failure of conservative therapy, she underwent several surgeries for the treatment of the left upper extremity lymphedema. These included left breast reconstruction with a combined deep inferior epigastric artery perforator and left vascularized groin lymph node (VGLN) flap transfer to the left breast and axilla in 2006; right VGLN transfer to the left elbow in 2012; multiple wedge resections of the left upper limb between 2006 and 2012; and left arm side-to-end lymphaticovenous anastomosis in 2013. Her other past medical history was significant for nasopharyngeal cancer that was treated with radiotherapy to the head and neck in 2011. In the aftermath of her lymphedema management, her upper limb became softer; however, the patient continued to suffer from recurrent episodes of cellulitis every 2–3 months in 2013. Lymphoscintigraphy was then performed and revealed total lymphatic obstruction

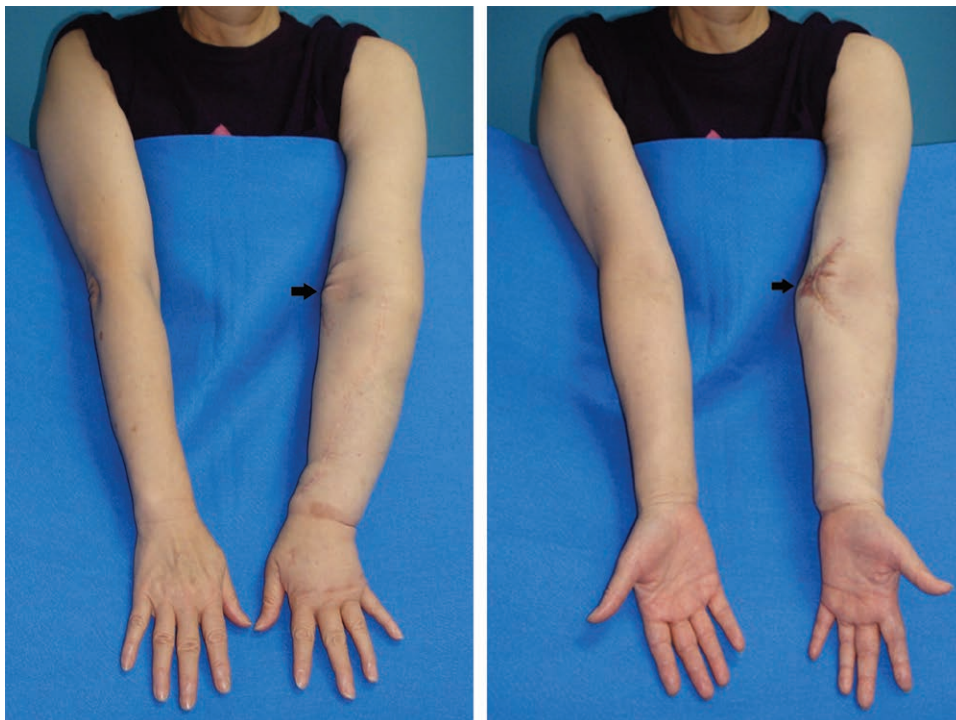


Fig. 1. Preoperative view. The scar of previous vascularized groin lymph node on left medial elbow, and previous lymphovenous anastomosis on the dorsal wrist (black arrow).

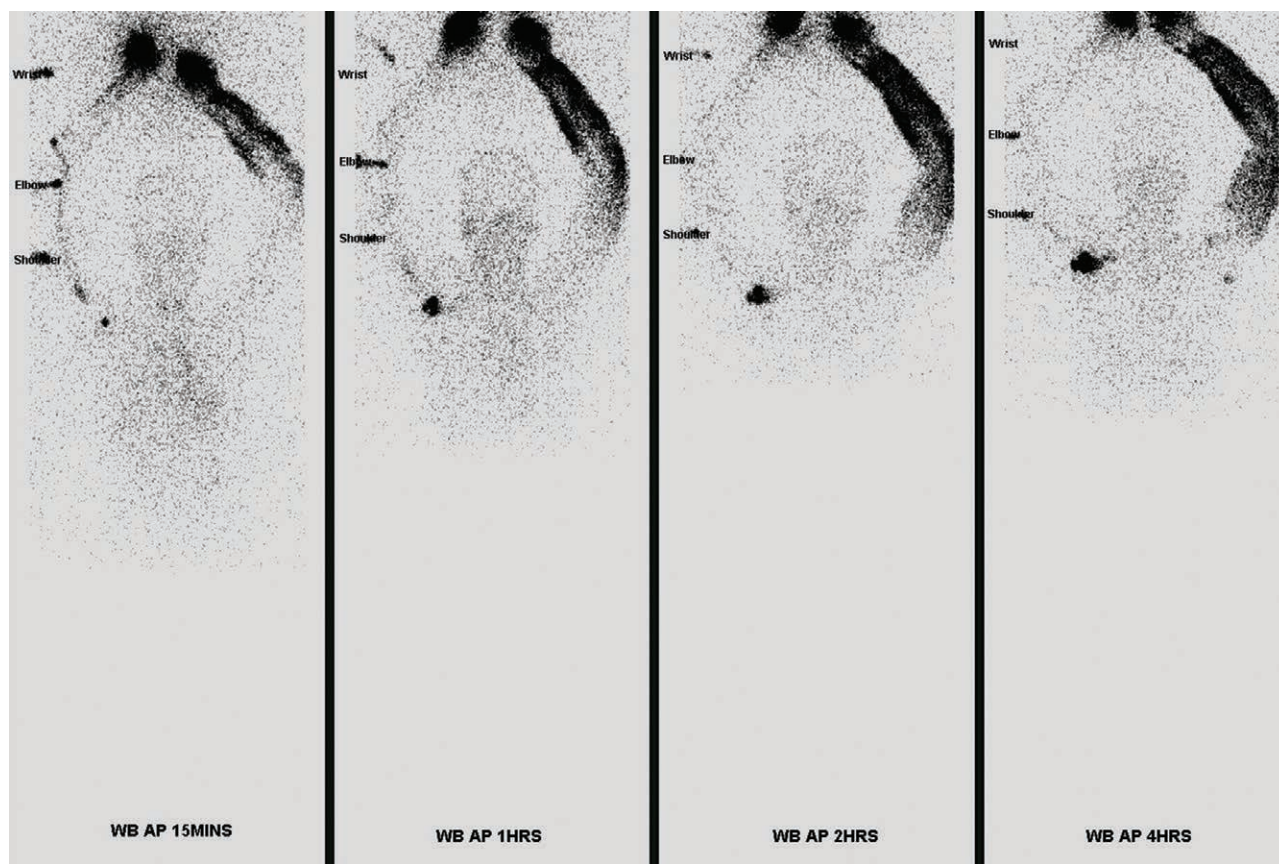


Fig. 2. Preoperative lymphoscintigraphy. WB (whole body), AP (anteroposterior) view of upper limbs, 15 minutes, 1 hour, 2 hours, and 4 hours after injection, respectively.

of the left upper limb despite all the aforementioned procedures (Fig. 2).

The patient's quality of life was compromised by this disease process, and she was motivated to pursue any further treatment necessary. Thus, we planned to perform another vascularized lymph node transfer to the left upper extremity. As for the donor site selection, the patient was now severely limited. Both groins had been previously used, and the radiation she endured for her nasopharyngeal cancer precluded the use of vascularized submental lymph node (VSLN) or supraclavicular lymph node flaps. In our experienced opinion, the next best option for her was a right thoracic lymph node flap. On the morning of the planned right thoracic lymph node transfer, a reverse mapping of the right thoracic lymph nodes was performed with Tc-99 injected at the second web space of the hand and patent blue dye injection into the thoracic region. Unfortunately, reverse mapping was unable to locate available lymph nodes for transfer in this region. With no other options remaining, the decision was made to proceed with a GOLF transfer to the left upper extremity for management of refractory lymphedema.

Operative Technique

Laparoscopic harvest of the greater omental flap was performed by a general surgeon (T.-J.W.). The patient was placed on supine position and slight reverse Tren-

delenburg to assist the dissection. The greater omentum was identified and then freed from its attachments to the transverse colon and the greater curvature of stomach. The left gastroepiploic vessels were divided, and the right gastroepiploic vein and artery were dissected to provide adequate pedicle length for anastomosis. (Video Graphic 1, **See video, Supplemental Digital Content 1**, which displays laparoscopic greater omental lymph node flap (GOLF) harvest. This video is available in the "Related Videos" section of the Full-Text article on PRSGlobalOpen.com or available at <http://links.lww.com/PRSGO/A411>.)

Before dividing the pedicle, indocyanine green was injected into the periphery of the flap. The flap was then viewed under infrared light to confirm the presence of lymphatic tissue and lymph nodes within the flap. The pedicle was divided and the GOLF was transferred to the left distal forearm (Fig. 3).

The proximal radial artery and one comitant vein were used as recipient vessels. Fluorescence from the previously injected ICG was found throughout the entire flap and was also visualized draining into the radial comitant vein after anastomosis. (Video Graphic 1, **See video, Supplemental Digital Content 1**, which displays laparoscopic greater omental lymph node flap (GOLF) harvest. This video is available in the "Related Videos" section of the Full-Text article on PRSGlobalOpen.com or available at <http://links.lww.com/PRSGO/A411>.) To prevent compression and folding of the flap, the

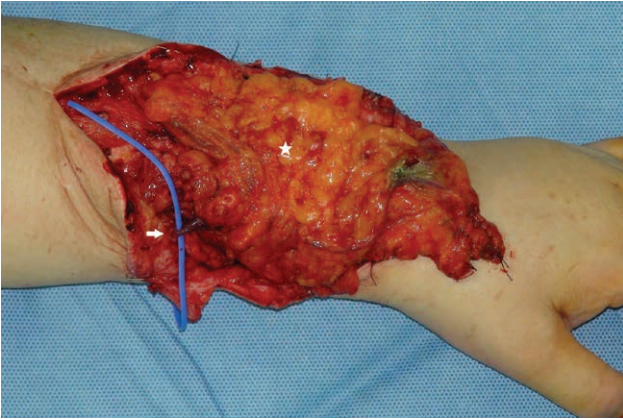
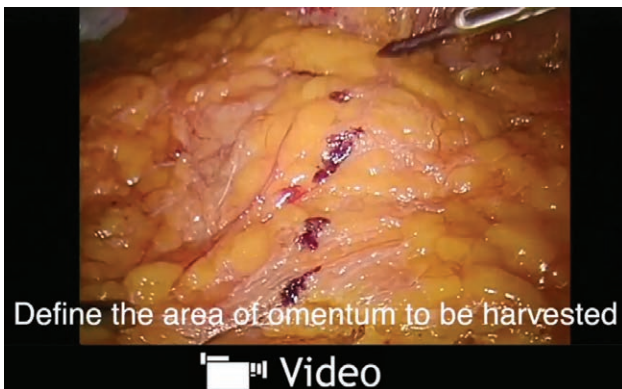

Fig. 3. Transfer GOLF (white star) to left distal forearm. Pedicle vein was anastomosed to radial comitant vein (white arrow).



Video Graphic 1. See video, Supplemental Digital Content 1, which displays laparoscopic greater omental lymph node flap (GOLF) harvest. This video is available in the "Related Videos" section of the Full-Text article on PRSGlobalOpen.com or available at <http://links.lww.com/PRSGO/A411>.

recipient site was not closed primarily. Instead, the exposed partial omentum was covered by Mepitel (Mölnlycke, Göteborg, Sweden) film. This transparent film allowed for flap monitoring postoperatively while maintaining a healthy bed for subsequent skin grafting if needed. The patient was sent to the intensive care unit for microsurgery for flap and monitoring after an uncomplicated operative course.

RESULTS

Postoperatively, the patient and flap were monitored in the intensive care unit for 3 days. The arm was kept in a neutral position for 1 week after the procedure. All compressive therapies were discontinued, and the patient was asked to resume activities as tolerated after complete healing of the skin graft that replaced the Mepitel at 2 weeks. The left arm became soft and decreased in its circumference. She has had no further episodes of cellulitis and reports a lighter feel to her arm. There were no complications with the flap or donor site. At 2-month and 8-month follow-ups, the reduction of the arm circumference was 42.9% at both times above the elbow and 27.3% and 36.4%, respectively, below the elbow (Figs. 4, 5). The

patient was satisfied with the functional outcome and minimal donor site morbidity (Fig. 6).

DISCUSSION

The greater omentum contains groups of lymph nodes (level 4ab along the left gastroepiploic vessels and level 4d along the right gastroepiploic vessels) and lymphatic ducts for adequate drainage, which makes GOLF a good alternative choice for donor lymph node transfer. Our patient was an ideal candidate for GOLF transfer because she had very limited superficial extremity lymph nodes available.

The advantages of GOLF are an abundance of lymph nodes, moderate pedicle diameter, minimal donor site lymphedema, and minimal incision wounds, which are in unobtrusive areas and should leave little scarring.

On the other hand, the disadvantages are long operation time, incapability of primary closure, less aesthetic results at the recipient site, the possibility of intraperitoneal organ injury and conversion to an open method,³⁴ and postoperative abdomen and chest discomfort caused by pneumoperitoneum. In our patient, we spent 4 hours for flap dissection and harvest, which is typical as described in the literature.³⁴ The long operation time may be decreased by repetitive practices. The organ injury is more likely to occur when harvesting the omentum with left gastroepiploic vessels. It is likely to injure the spleen due to vessels that are difficult to identify. Moreover, extraction of the flap pedicle during dissection of the gastroepiploic vessels was also suggested. Surgeons who perform the flap harvest should be aware of these details or seek the assistance of a reconstructive microsurgeon.²⁸

Kamei et al.³⁴ suggested that when a large volume of omental flap is required, the laparotomy method would be the best first choice. For Grade II–III lymphedema patients, just a small amount of omental tissue could provide an adequate number of lymph nodes. It is safer to harvest only the right-side omentum with the right gastroepiploic artery as the pedicle.

Furthermore, 2-team approach with general surgeons allows plastic surgeon to prepare recipient site simultaneously, and save at least 1–2 hours of operation time. If there is emergent intra-abdominal complication happened such as massive bleeding or injury of pancreas, the general surgeons could react faster and change into open method immediately to avoid further damage or delay of rescue.

Our standard strategy for treating Grade 0–I post-mastectomy upper limb lymphedema without cancer recurrence or metastasis is to do complete decongestive treatment or lymphovenous anastomosis; Grade II–IV is indicated to transfer a VGLN or VSLN flap to dorsal wrist concerning better functional recovery and then do further scar tissue release or skin paddle revision in combination with partial excision and liposuction.^{16,19,35}

According to previous studies, the VGLN flap could improve the circumference of the arm from 31.6% to 50.5% above the elbow, 9.6% to 42.2% below the elbow, 17.3% to 56.6% at the wrist, and 15.7% to 54.5% at the palm.^{13,15,18,19,36–38} The volume reduction achieved by VSLN flap transposition was more than 60% in the

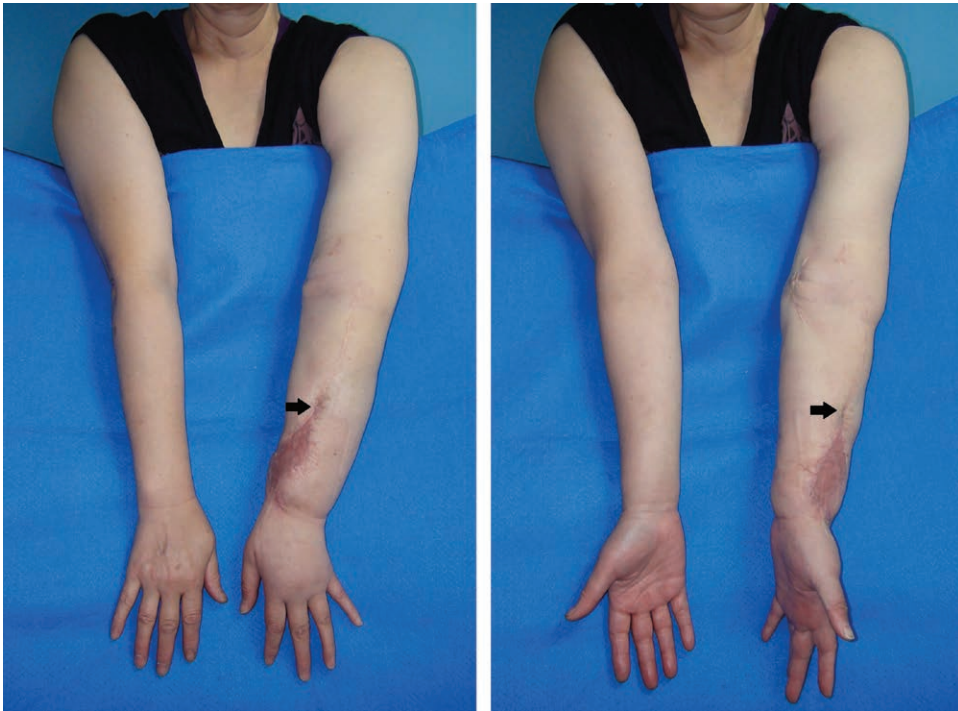


Fig. 4. Two months postoperative follow-up. The arm circumference reduction was 42.9% above the elbow and 27.3% below the elbow. Recipient vessels were the radial artery and one comitant vein (black arrow).

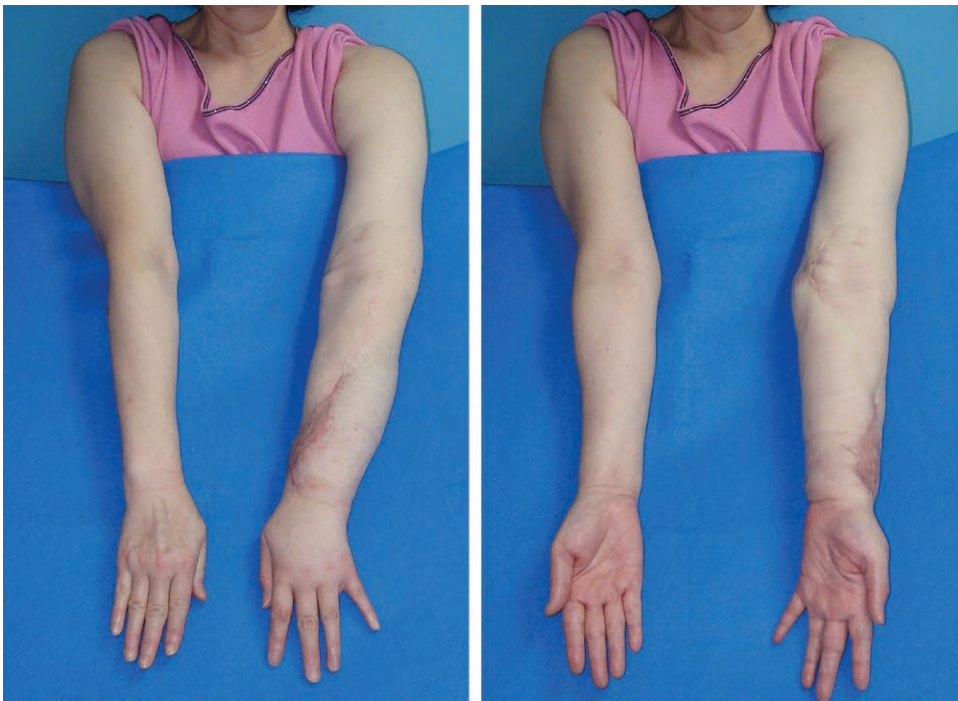

Fig. 5. Eight months postoperative follow-up. The arm circumference reduction was 42.9% above the elbow and 36.4% below the elbow.

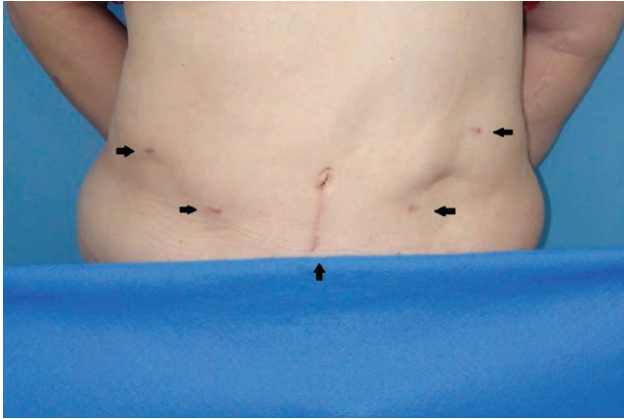


Fig. 6. Scars of the donor site (black arrow).

lower extremities.¹⁵ Nevertheless, the omental flap has been reported to have a reduction in circumference from 9% to 22.2% of the upper extremities,^{28,29} 50% to 75% of the lower extremities,³⁹ and 2% to 29% differential improvement in volumetric measurements.²⁹ Nguyen et al. also reported a latest long-term outcome study in 42 patients who underwent a free omental lymphatic flap transfer with a mean follow-up of 14 months. The mean volumetric improvement was 22% and the subjective improvements were noted in 83% of patients in their study.⁴⁰ At 8 months' follow-up the arm circumference of the patient was reduced by 42.9% above the elbow and 36.4% below the elbow. This was a better result than the patient had achieved after previous treatment using other modalities.

The possible reasons of ineffectiveness of the patient's former groin lymph node flaps may be due to vascular occlusion and inadequate inclusion of lymph nodes in the donor groin area, which still showed lymph nodes remained by CT scan and sonography. The GOLF has been proven to have patent recipient vessels and adequate transferred lymph nodes amounts detected by sonography.

The iatrogenic donor site morbidity of lymph node transfer was a major concern. Although the vascularized lymph nodes from the groin or the axilla have the advantage of a well-hidden scar, abundant surrounding soft tissue and lymph node, the possibility of causing donor site lymphedema after harvesting lymph nodes was a concern. The submental flap and supraclavicular flap have a relatively low risk for donor site morbidity, but have possible visible scar and damage to the marginal mandibular nerve.³⁶ For the laparoscopic harvest of the omental flap, none of the cases reported major complications related to the donor site, and only slight abdominal pain, which resolved rapidly, was noted.^{2,28,29,33,40}

SUMMARY

The split GOLF has shown good results in a peripheral lymph node-depleted lymphedema patient. It is one of the alternative choices for a lymph node transfer donor site. Using laparoscopic technique for GOLF harvest has a minimal donor site morbidity.

Ming-Huei Cheng, MD, MBA, FACS

Division of Reconstructive Microsurgery
Department of Plastic and Reconstructive Surgery
Chang Gung Memorial Hospital
College of Medicine, Chang Gung University
5 Fu-Hsing Street, Kueishan
Taoyuan 333, Taiwan
E-mail: minghueicheng@gmail.com, minghuei@cgmh.org.tw

REFERENCES

- Hansen, J. *Netter's Clinical Anatomy*. 2nd ed. Philadelphia: Saunders/Elsevier; 2010.
- Nishimura T, Kanehira E, Tsukatani T, et al. Laparoscopically harvested omental flap for head and neck reconstruction. *Laryngoscope*. 2002;112:930–932.
- Slavin SA, Greene AK, Borud LJ. Lymphedema. In: Weinzeig J, ed. *Plastic Surgery Secrets Plus*. 2nd ed. Philadelphia, PA: Mosby; 2009:631–635.
- Lawenda BD, Mondry TE, Johnstone PA. Lymphedema: a primer on the identification and management of a chronic condition in oncologic treatment. *CA Cancer J Clin*. 2009;59:8–24.
- Cheng MH, Huang JJ, Wu CW, et al. The mechanism of vascularized lymph node transfer for lymphedema: natural lymphaticovenous drainage. *Plast Reconstr Surg*. 2014;133:192e–198e.
- Martorell F. [Lymphaticovenous anastomosis as a treatment of lymphedema]. *Angiologia*. 1969;21:61–63.
- Gilbert A, O'Brien BM, Vorrath JW, et al. Lymphaticovenous anastomosis by microvascular technique. *Br J Plast Surg*. 1976;29:355–360.
- Ohara I, Taneichi N. Lymphaticovenous anastomosis in a case with primary lymphedema tarda. *Angiology*. 1973;24:668–674.
- Fox U, Montorsi M, Romagnoli G. [Treatment of lymphedema of the extremities with lymphaticovenous anastomosis]. *Minerva Chir*. 1980;35:1455–1460.
- Yamamoto Y, Sugihara T. Microsurgical lymphaticovenous implantation for the treatment of chronic lymphedema. *Plast Reconstr Surg*. 1998;101:157–161.
- Shafiroff BB, Nightingale G, Baxter TJ, et al. Lymphaticolymphatic anastomosis. *Ann Plast Surg*. 1979;3:199–210.
- Cheng MH, Chen SC, Henry SL, et al. Reply: Vascularized groin lymph node flap transfer for postmastectomy upper limb lymphedema: the flap anatomy, recipient sites, and outcomes. *Plast Reconstr Surg*. 2014;133:428e–429e.
- Lin CH, Ali R, Chen SC, et al. Vascularized groin lymph node transfer using the wrist as a recipient site for management of postmastectomy upper extremity lymphedema. *Plast Reconstr Surg*. 2009;123:1265–1275.
- Chen HC, O'Brien BM, Rogers IW, et al. Lymph node transfer for the treatment of obstructive lymphoedema in the canine model. *Br J Plast Surg*. 1990;43:578–586.
- Cheng MH, Huang JJ, Huang JJ, et al. A novel approach to the treatment of lower extremity lymphedema by transferring a vascularized submental lymph node flap to the ankle. *Gynecol Oncol*. 2012;126:93–98.
- Nguyen DH, Chou PY, Hsieh YH, et al. Quantity of lymph nodes correlates with improvement in lymphatic drainage in treatment of hind limb lymphedema with lymph node flap transfer in rats. *Microsurgery*. 2016;36:239–245.
- Chipp E, Ferguson L, Rayatt S. Vascularized groin lymph node transfer using the wrist as a recipient site for management of postmastectomy upper extremity lymphedema. *Plast Reconstr Surg*. 2010;125:751–2; author reply 752.
- Gharb BB, Rampazzo A, Spanio di Spilimbergo S, et al. Vascularized lymph node transfer based on the hilar perforators improves the outcome in upper limb lymphedema. *Ann Plast Surg*. 2011;67:589–593.

19. Cheng MH, Chen SC, Henry SL, et al. Vascularized groin lymph node flap transfer for postmastectomy upper limb lymphedema: flap anatomy, recipient sites, and outcomes. *Plast Reconstr Surg*. 2013;131:1286–1298.
20. Nava VM, Lawrence WT. Liposuction on a lymphedematous arm. *Ann Plast Surg*. 1988;21:366–368.
21. O'Brien BM, Khazanchi RK, Kumar PA, et al. Liposuction in the treatment of lymphoedema; a preliminary report. *Br J Plast Surg*. 1989;42:530–533.
22. Brorson H, Svensson H, Norrgren K, et al. Liposuction reduces arm lymphedema without significantly altering the already impaired lymph transport. *Lymphology*. 1998;31:156–172.
23. Goldsmith HS, De los Santos R. Omental transposition for the treatment of chronic lymphedema. *Rev Surg*. 1966;23:303–304.
24. Goldsmith HS, De los Santos R, Beattie EJ Jr. Relief of chronic lymphedema by omental transposition. *Ann Surg*. 1967;166:573–585.
25. Goldsmith HS, de los Santos R, Beattie EJ Jr. Omental transposition in the control of chronic lymphedema. *JAMA*. 1968;203:1119–1121.
26. O'Brien BM, Hickey MJ, Hurley JV, et al. Microsurgical transfer of the greater omentum in the treatment of canine obstructive lymphoedema. *Br J Plast Surg*. 1990;43:440–446.
27. Micheau P. [The greater omentum. Its role in reconstructive plastic surgery]. *Ann Chir Plast Esthet*. 1995;40:192–207.
28. Lasso JM, Pinilla C, Castellano M. New refinements in greater omentum free flap transfer for severe secondary lymphedema surgical treatment. *Plast Reconstr Surg Glob Open*. 2015;3:e387.
29. Nguyen AT, Suami H. Laparoscopic free omental lymphatic flap for the treatment of lymphedema. *Plast Reconstr Surg*. 2015;136:114–118.
30. Benoit L, Boichot C, Cheynel N, et al. Preventing lymphedema and morbidity with an omentum flap after ilioinguinal lymph node dissection. *Ann Surg Oncol*. 2005;12:793–799.
31. Logmans A, Kruyt RH, de Bruin HG, et al. Lymphedema and lymphocysts following lymphadenectomy may be prevented by omentoplasty: A pilot study. *Gynecol Oncol*. 1999;75:323–327.
32. Nakajima E, Nakajima R, Tsukamoto S, et al. Omental transposition for lymphedema after a breast cancer resection: report of a case. *Surg Today*. 2006;36:175–179.
33. Saltz R, Stowers R, Smith M, et al. Laparoscopically harvested omental free flap to cover a large soft tissue defect. *Ann Surg*. 1993;217:542–6; discussion 546.
34. Kamei Y, Torii S, Hasegawa T, et al. Endoscopic omental harvest. *Plast Reconstr Surg*. 1998;102:2450–2453.
35. Cheng M-H, Chang DW, Patel KM. *Principles and Practice of Lymphedema Surgery*. Edinburgh: Elsevier Health Sciences; 2015.
36. Raju A, Chang DW. Vascularized lymph node transfer for treatment of lymphedema: a comprehensive literature review. *Ann Surg*. 2015;261:1013–1023.
37. Becker C, Vasile JV, Levine JL, et al. Microlymphatic surgery for the treatment of iatrogenic lymphedema. *Clin Plast Surg*. 2012;39:385–398.
38. Hartiala P, Saaristo AM. Growth factor therapy and autologous lymph node transfer in lymphedema. *Trends Cardiovasc Med*. 2010;20:249–253.
39. Attash, S. M., Al-Sheikh, M. Y. Omental flap for treatment of long standing lymphoedema of the lower limb: can it end the suffering? Report of four cases with review of literatures. *BMJ Case Reports* 2013. doi: 10.1136/bcr-2012-008463.
40. Nguyen AT, Suami H, Hanasono MM, et al. Long-term outcomes of the minimally invasive free vascularized omental lymphatic flap for the treatment of lymphedema. *J Surg Oncol*. 2017;115:84–89.