

Myoferlin expression in non-small cell lung cancer: Prognostic role and correlation with VEGFR-2 expression

DAE HYUN SONG^{1,2}, GYUNG HYUCK KO¹⁻³, JEONG HEE LEE¹⁻³, JONG SIL LEE¹⁻³,
GYEONG-WON LEE³⁻⁵, HYEON CHEOL KIM², JUNG WOOK YANG¹, ROK WON HEO^{3,6},
GU SEOB ROH^{3,6}, SUN-YOUNG HAN⁷ and DONG CHUL KIM¹⁻³

¹Department of Pathology, Gyeongsang National University School of Medicine;

²Department of Pathology, Gyeongsang National University Hospital;

³Gyeongsang Institute of Health Sciences, Gyeongsang National University; ⁴Department of Internal Medicine, Gyeongsang National University School of Medicine, ⁵Department of Internal Medicine, Gyeongsang National University Hospital;

⁶Department of Anatomy, Gyeongsang National University School of Medicine; ⁷Department of Pharmacology, College of Pharmacy, Gyeongsang National University, Jinju, Gyeongsang 660-751, Republic of Korea

Received November 12, 2014; Accepted September 17, 2015

DOI: 10.3892/ol.2015.3988

Abstract. Myoferlin is a protein that is associated with cellular repair following injury. The expression of myoferlin in breast cancer and pancreatic adenocarcinoma has been reported to correlate with tumor invasiveness, epithelial to mesenchymal transition and an adverse prognosis. In the present study, myoferlin expression was investigated in non-small cell lung carcinoma (NSCLC), along with its association with patient prognosis and the expression of a number of other proteins. A total of 148 patients exhibiting NSCLC were enrolled in the present study. The survival data of all patients was examined, and myoferlin, vascular endothelial growth factor receptor-2 (VEGFR-2), epidermal growth factor receptor, E-cadherin, β -catenin, thyroid transcription factor-1 and tumor protein p63 expression was investigated via immunohistochemical staining of tissue microarrays. Myoferlin expression was detected in the cytoplasm of 75/148 (50.7%) of the NSCLC cases. In the adenocarcinoma cases, myoferlin-positive patients possessed a poorer prognosis (odds ratio, 2.94; $P=0.339$). In the squamous cell carcinoma cases, myoferlin expression was significantly associated with VEGFR-2 expression ($P=0.001$). Immunohistochemical staining for VEGFR-2 and myoferlin expression indicated similar features and cytoplasmic staining in tumor cells. As VEGFR-2 is a significant target for novel anticancer

therapies, it is anticipated that myoferlin may also possess the potential to become a novel clinical target for the treatment of NSCLC.

Introduction

Myoferlin protein is associated with cell membrane repair (1). Cancer cells demonstrate an increased proliferative rate compared with normal cells. As the cell membrane is a vital organelle, there is an increased occurrence of membrane repair events in cancer cells compared with normal cells (1). Therefore, myoferlin may possess a significant role in tumorigenesis.

The ferlin family of proteins, which contains myoferlin, is a mammalian protein family named due to its members' homology with the Fer-1 protein of *Caenorhabditis elegans* (2). A defective *Fer-1* gene results in infertility, due to abnormal membrane fusion processes during the development of sperm (3). The ferlin family of proteins possesses multiple C2 domains, and is able to anchor to the cell membrane using a carboxyl terminal. C2 domains participate in protein-protein or protein-membrane interactions (4); they are calcium sensing, and mediate membrane fusion, repair and vesicle trafficking in skeletal muscles. The ferlin family contains six members: Dysferlin, myoferlin, otoferlin, Fer-1-like 4, Fer-1-like 5 and Fer-1-like 6 (1,4).

Myoferlin has been well-studied in muscle cells due to its correlation with musculopathy. During the normal embryonic development of muscle or the regeneration of mature muscle cells following injury, myoblasts possessing a single nucleus fuse and form large syncytial myofibers. Myoferlin is highly expressed during myoblast fusion, although the specific function of myoferlin in this process remains to be elucidated (5). In endothelial cells, myoferlin regulates angiogenesis, which is associated with vascular endothelial growth factor receptor-2 (VEGFR-2) expression (6,7).

Myoferlin expression by cancer cells has received attention in a number of studies. The MDA-MB-231 breast cancer

Correspondence to: Professor Dong Chul Kim, Department of Pathology, Gyeongsang National University School of Medicine, 15 Jinju-daero 816 Beon-gil, Jinju, Gyeongsang 660-751, Republic of Korea
E-mail: kdcjes@gmail.com

Key words: myoferlin protein, vascular endothelial growth factor receptor-2, non-small cell lung cancer, prognosis, tissue array analysis

cell line exhibits high myoferlin expression and is frequently used in studies of myoferlin in cancer. *In vitro*, depletion of myoferlin induces a mesenchymal to epithelial transition and reduces cancer cell invasiveness (8,9). Although the mechanism via which myoferlin impacts breast cancer cell invasiveness remains to be elucidated, a number of studies have suggested that matrix metalloproteinases may possess a significant role in the myoferlin-mediated regulation of invasion (10). *In vivo*, myoferlin-depleted breast cancer cells demonstrate reduced cellular proliferation, are smaller and form less invasive tumors (1,9). Furthermore, myoferlin is hypothesized to be a significant modulator of epidermal growth factor receptor (EGFR) expression in breast cancer cells (11). In pancreatic cancer, patients exhibiting myoferlin-expressing tumors possess relatively poor clinical outcomes (12).

To the best of our knowledge, the expression of myoferlin in lung cancer surgical specimens has not been previously investigated. A recent study concerning myoferlin expression in normal lung parenchyma and bronchial epithelium stimulated the present study to investigate whether myoferlin is expressed in non-small cell lung cancer (NSCLC) (13).

The aim of the present study was to elucidate the clinicopathological characteristics of myoferlin expression in NSCLC.

Materials and methods

Case selection. Data from primary NSCLC patients treated at Gyeongsang National University Hospital (Jinju, South Korea) was collected between January 2002 and December 2009. A total of 148 patients were enrolled in the present study. The clinical data and survival period of all patients were obtained by reviewing clinical charts and National Statistical Office of Korea (Seoul, South Korea) records. Current smokers and ex-smokers were included in the positive-smoking history group. All of the included patients were clinically operable; pneumonectomies, lobectomies or sleeve lobectomies were performed. The tumor-node-metastasis (TNM) stage of each patient was assessed using the American Joint Committee on Cancer Staging Manual, 7th edition (14).

Gross images and hematoxylin and eosin (HE)-stained sections of surgical specimens were reviewed, and the tumor pathological characteristics were described by two pathologists. The degree of differentiation in squamous cell carcinoma was classified, using a three-tiered system, as either well-, moderately- or poorly-differentiated. Well-differentiated squamous cell carcinomas maintained the characteristic morphology of squamous cells, including keratinization, a plump cytoplasm and distinct cellular borders with intercellular bridges. Poorly-differentiated squamous cell carcinomas did not exhibit these histological features (Fig. 1). The histological characteristics of adenocarcinoma were described using the classification system of the International Association for the Study of Lung Cancer/American Thoracic Society/European Respiratory Society (15,16). The nuclear grade of adenocarcinomas was defined, using a two-tiered system, as either high- or low-grade. High-grade adenocarcinomas demonstrated atypical nuclei, macronucleoli and a coarse chromatin pattern in >10% of the tumor cells on the whole slide. Low-grade adenocarcinomas demonstrated relatively regular-sized and -shaped nuclei, and evenly distributed

chromatin in almost all tumor cells. The Institutional Review Board of Gyeongsang National University Hospital (Jinju, Korea) approved the present study.

Tissue microarray (TMA). Resected tumor samples were fixed overnight in 20% buffered neutral formalin. The samples were grossly examined, dissected and embedded in paraffin blocks. Representative blocks were selected following microscopic examination of HE-stained sections from each tumor (BX-51, light microscope, Olympus Corporation, Tokyo, Japan). A 3-mm representative core of tissue was obtained from each paraffin block and arranged in new recipient TMA paraffin blocks. A representative area of the donor blocks was selected based on its major differentiation and location near the invasive front.

Immunohistochemical (IHC) analysis. Immunohistochemistry was performed on the TMA block sections for 7 distinct proteins. Primary antibodies for myoferlin, VEGFR-2, EGFR, E-cadherin, β -catenin, tumor protein p63 and thyroid transcription factor-1 (TTF-1) were used to investigate protein expression, and the association between the expression of certain proteins was examined. VEGFR-2 is a well-known drug target for the prevention of angiogenesis, and its expression has been demonstrated to correlate with myoferlin expression in endothelial cells (6). The expression of EGFR, E-cadherin and β -catenin in cancer cells is known to be associated with patient prognosis (17,18). TTF-1 and p63 are generally known as specific markers for pulmonary adenocarcinoma and squamous cell carcinoma (19).

IHC staining was performed on 4- μ m sections from the TMA blocks. Once attached to glass slides, the sections were deparaffinized, rehydrated and incubated in 3% hydrogen peroxide for 10 min in order to block endogenous peroxidase activity, which may cause non-specific background staining. Sections were subsequently heated for 20 min in 10 mM citrate buffer (pH 6.0) in a microwave oven (700 W). Following incubation with Ultra V Block (Lab Vision; Thermo Fisher Scientific, Inc., Waltham, MA, USA) for 7 min at room temperature in order to block background staining, slides were incubated with a mouse monoclonal primary antibody specific to myoferlin (1:100 dilution; 7D2; ab76746; Abcam, Cambridge, UK) according to the manufacturer's protocols. The compound 3,3'-diaminobenzidine was utilized in order to detect the proteins, and the sections were counterstained using hematoxylin. IHC staining was additionally performed using the same protocol with primary antibodies for VEGFR-2 (1:200 dilution; rabbit polyclonal; PA5-16487; Thermo Fisher Scientific, Waltham, MA, USA), EGFR (1:100 dilution; mouse monoclonal; 3C6; 790-2988; Ventana Medical Systems, Inc., Tuscon, AZ, USA), E-cadherin (1:200 dilution; rabbit monoclonal; EP700Y; MA5-14458; Thermo Fisher Scientific, Inc.), β -catenin (1:400 dilution; mouse monoclonal; E-5; sc-7963; Santa Cruz Biotechnology, Inc., Dallas, TX, USA), p63 (1:50 dilution; mouse monoclonal; 4A4; Ventana Medical Systems, Inc.), and TTF-1 (1:1,500 dilution; rabbit monoclonal; SP141; 790-4756; Ventana Medical Systems, Inc.). The positive control used for myoferlin comparison was normal bronchiolar epithelium; tissues with equal to or more intense staining compared with normal bronchiolar epithelium were regarded as positive. For EGFR, tissue with equivocal expression was

classified as negative, and focal or diffuse membrane staining was classified as positive for myoferlin expression. Almost all EGFR-positive specimens demonstrated cytoplasmic staining. In addition, VEGFR-2 was expressed in the cytoplasm. Tissues demonstrating β -catenin or E-cadherin expression in the cellular membrane were regarded as demonstrating positive expression.

Western blot analysis. Fresh tumor samples were obtained from the central portion of the mass, in an area that appeared to be homogeneous and was neither necrotic nor fibrotic. The western blot analysis method was used as previously described to determine myoferlin and VEGFR-2 expression (20).

Statistical analysis. The overall survival of patients with NSCLC was compared using univariate and multivariate Cox proportional hazard model analyses. The analysis of correlations was performed using χ^2 tests. $P < 0.05$ was considered to indicate a statistically significant difference. All statistical analyses were performed using SPSS version 18.0 (SPSS, Inc., Chicago, IL, USA).

Results

Clinicopathological features of 148 NSCLC patients. The clinicopathological features of the 148 NSCLC patients are summarized in Table I. Of these patients, 125 were male and 95 possessed a history of smoking (current or ex-smoker). The mean patient age was 64.85 years. The majority of the patients (83/148; 56.1%) were evaluated as TNM stage I following surgery, while 51 (34.5%), 12 (8.1%), and 2 (1.4%) patients were evaluated as TNM stages II, III and IV, respectively. A lobectomy was performed in 130 (87.8%) patients. A bilobectomy or sleeve lobectomy was performed in 3 (2.0%) patients, and a pneumonectomy was performed in 15 (10.1%) patients. Squamous cell carcinoma accounted for 96 (64.9%) of the total NSCLC cases, 59 of which demonstrated moderate differentiation (Fig. 1A-C). A total of 15 and 22 patients exhibited well- and poorly-differentiated squamous cell carcinomas, respectively. Adenocarcinomas accounted for 37 (25.0%) of the total NSCLC cases. Acinar, solid, papillary, micropapillary, lepidic and mucinous growth patterns were observed in 15, 6, 8, 3, 3 and 2 patients, respectively (Fig. 2A-G). Large cell neuroendocrine carcinomas were observed in 8 of the NSCLC patients. Pleomorphic and mucoepidermoid carcinomas were observed in 6 and 1 patient(s), respectively. The median survival time was 37 months and the 5-year survival rate was 22.3%.

Myoferlin is expressed in NSCLC. The expression of myoferlin in each pathological subtype is summarized in Table I. Myoferlin expression in the cytoplasm of cancer cells was observed in 75/148 NSCLC cases. Myoferlin expression in the cytoplasm of cancer cells was observed in 37/96 (38.5%) squamous cell carcinoma cases (Fig. 1D). Normal bronchial epithelium, lung parenchyma and a number of capillary endothelial cells surrounding the cancer cells additionally expressed cytoplasmic myoferlin. Myoferlin protein expression was observed in the cytoplasm in 31/37 (83.8%) adenocarcinomas cases (Fig. 2H). Myoferlin expression was additionally

Table I. Clinicopathological features of 148 non-small cell lung cancer patients.

Clinicopathological feature	Value
Male gender, n (%)	125 (84.5)
Smoking history, n (%)	97 (65.5)
Mean age, years	64.85
Tumor-node-metastasis stage, n (%)	
I	83 (56.1)
II	51 (34.5)
III	12 (8.1)
IV	2 (1.4)
Surgical procedure, n (%)	
Lobectomy	130 (87.8)
Bilobectomy or sleeve lobectomy	3 (2.0)
Pneumonectomy	15 (10.1)
Histological type, n (%)	
Squamous cell carcinoma	96 (64.9)
Well-differentiated	15
Moderately-differentiated	59
Poorly-differentiated	22
Adenocarcinoma	37 (25.0)
Acinar	15
Solid	6
Papillary	8
Micropapillary	3
Lepidic	3
Mucinous	2
Large cell neuroendocrine carcinoma	8 (5.4)
Other	7 (4.7)
Median survival, months	37
Five-year survival rate, n (%)	33 (22.3)
Myoferlin expression, n/total n (%)	
Squamous cell carcinoma	37/96 (38.5)
Adenocarcinoma	31/37 (83.8)
Large cell neuroendocrine carcinoma	3/8 (37.5)
Pleomorphic carcinoma	3/6 (50.0)
Mucoepidermoid carcinoma	1/1 (100.0)
Total	75/148 (50.7)

observed in 3/8 large cell neuroendocrine carcinoma, 3 pleomorphic carcinoma and 1 mucoepidermoid carcinoma case(s).

Differential expression of 7 distinct proteins in NSCLC cells. The expression of myoferlin, VEGFR-2, E-cadherin, β -catenin, EGFR, TTF-1 and p63 in the cancer cells was examined and is summarized in Table II (Fig. 1 and 2). Initially, the expression of each protein in association with TNM stage was investigated; however, no statistically significant

Table II. Clinicopathological features of 148 non-small cell lung carcinoma patients.

Factor	Myoferlin		VEGFR-2		E-cadherin		β-catenin		EGFR		TTF-1		p63								
	+	-	+	-	+	-	+	-	+	-	+	-	+	-							
Stage																					
I	44	39	0.632	39	44	0.558	64	19	0.391	70	13	0.424	29	54	0.721	25	58	0.643	51	32	0.876
II	25	26		18	33		37	14		39	12		19	32		6	45		31	20	
III	4	8		4	8		7	5		9	3		4	8		3	9		10	2	
IV	2	0		2	0		2	0		2	0		0	2		2	0		0	2	
Path type																					
Sqcc	37	59	<0.0001	28	68	<0.0001	67	29	0.002	74	22	0.001	39	57	0.040	4	92	<0.0001	86	10	<0.0001
Adc	31	6		28	9		35	2		37	0		8	29		28	9		3	34	

Sqcc, squamous cell carcinoma; Adc, adenocarcinoma; path, pathological; VEGFR-2, vascular endothelial growth factor-2; EGFR, epidermal growth factor receptor; TTF-1, thyroid transcription factor-1.

correlations were observed. Myoferlin-positive cancer cells were more abundant in adenocarcinoma cases compared with squamous cell carcinoma cases (P<0.001). A larger proportion of VEGFR-2-positive cancers were adenocarcinoma cases (P<0.001). E-cadherin and β-catenin were more frequently expressed in adenocarcinoma compared with squamous cell carcinoma (P=0.002 and P=0.001, respectively). EGFR demonstrated increased expression in squamous cell carcinoma compared with adenocarcinoma (P=0.040). VEGFR-2 expression was predominantly cytoplasmic; however, capillary endothelial cells demonstrated only weak VEGFR-2 cytoplasmic staining. EGFR, β-catenin and E-cadherin were predominantly expressed in the cellular membrane, although focal cytoplasmic expression was additionally observed. There was a significant correlation between p63 expression and squamous cell carcinoma differentiation (P=0.009). A total of 69/73 patients with well- or moderately-differentiated squamous cell carcinoma exhibited p63 expression in IHC. A total of 16/22 patients with poorly-differentiated squamous cell carcinoma demonstrated p63 expression. The nuclear grade of the adenocarcinoma did not exhibit a significant correlation with any of the proteins investigated in the present study.

Correlations exist between the expression of specific proteins in 2 major histological subtypes: Squamous cell carcinoma and adenocarcinoma. Squamous cell carcinoma and adenocarcinoma accounted for 89.9% of the NSCLC cases in the present study. There were 133 patients with squamous cell carcinoma or adenocarcinoma, and correlations between protein expression and tumor stage or pathological type were investigated (Table III). VEGFR-2, TTF-1 and p63 expression were significantly correlated with myoferlin expression (P<0.001, P<0.001 and P=0.006, respectively). Although the expression of all 7 investigated proteins was significantly correlated with the histological subtypes of squamous cell carcinoma and adenocarcinoma (Table III), E-cadherin, β-catenin and EGFR expression was only weakly correlated with myoferlin expression. (P=0.114, P=0.726 and P=0.461, respectively). VEGFR-2, TTF-1 and p63 expression was strongly correlated with myoferlin expression in low-stage tumors. In squamous cell carcinomas, a highly significant correlation between myoferlin and VEGFR-2 expression was identified (P=0.001).

Western blot analysis shows myoferlin and VEGFR-2 expression. Specimens from 6 patients with squamous cell carcinoma and 4 patients with adenocarcinoma were analyzed using western blotting. All specimens demonstrated myoferlin expression via immunohistochemical staining. Upon western blotting, myoferlin protein was detected in all cases. In addition, VEGFR-2 protein was identified in several cases (Fig. 3).

Survival analysis of squamous cell carcinoma. As revealed in Table IV, univariate analysis of squamous cell carcinoma patients indicated that p63 expression and pathological differentiation possessed relatively high odds ratios of 1.908 [95% confidence interval (CI), 0.804-4.528; P=0.143] and 2.010 (95% CI, .074-3.762; P=0.029), respectively. Myoferlin and VEGFR-2 possessed odds ratios of 1.221 (95% CI, 0.672-2.221; P=0.512) and 1.219 (95% CI, 0.644-2.306; P=0.542), respectively. Using multivariate analysis, the parameter of stage demonstrated an

Table III. Correlation between expression of myoferlin and other proteins in 133 squamous cell carcinoma and adenocarcinoma patients.

Factor	Myoferlin	VEGFR-2			E-cadherin			β-catenin			EGFR			TTF-1			p63		
		+	-	P-value	+	-	P-value	+	-	P-value	+	-	P-value	+	-	P-value	+	-	P-value
Sqcc+Adc	+	43	25	0.000	56	46	0.114	56	12	0.726	22	46	0.461	25	43	0.000	38	30	0.006
	-	13	52		12	19		55	10		25	40		7	58		51	14	
Stage of Sqcc+Adc	+	28	13	0.000	35	6	0.057	36	5	0.525	13	28	0.882	18	23	0.008	22	19	0.024
I	-	6	27		22	11		27	6		11	22		5	28		26	7	
II	+	11	10	0.220	16	5	1.000	16	5	0.439	6	15	0.108	5	16	0.015	12	9	0.174
	-	5	20		20	5		22	3		13	12		0	25		19	6	
III	+	2	2	0.576	3	1	1.000	2	2	0.491	3	1	0.088	0	4	0.491	4	0	1.000
	-	2	5		4	3		6	1		1	3		2	5		6	1	
Path type	+	18	19	0.001	27	10	0.591	25	12	0.079	16	21	0.679	2	35	0.638	35	2	0.308
Sqcc	-	10	49		40	19		49	10		23	36		2	57		51	8	
Adc	+	25	6	0.140	29	2	1.000	31	0	N/I	6	25	0.591	23	8	1.000	3	28	1.000
	-	3	3		6	0		6	0		2	4		5	1		0	6	

Sqcc, squamous cell carcinoma; Adc, adenocarcinoma; N/I, statistically not informative since all 37 adenocarcinomas showed positivity for beta-catenin; path, pathological; VEGFR-2, vascular endothelial growth factor 2; EGFR, epidermal growth factor receptor; TTF-1, thyroid transcription factor 1.

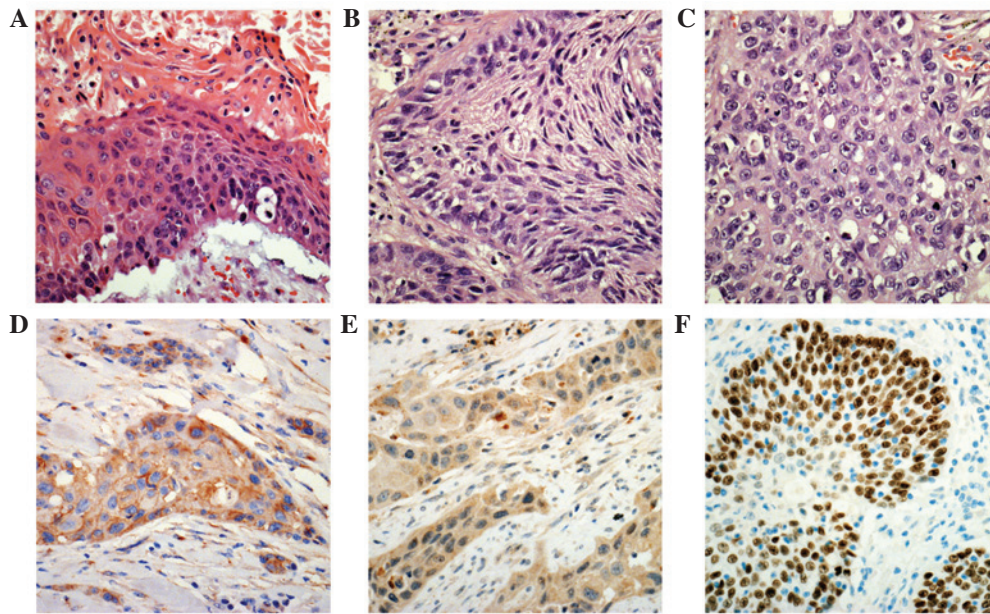


Figure 1. Microscopic features of squamous cell carcinoma following hematoxylin and eosin staining. (A) Well-differentiated squamous cell carcinoma demonstrated keratinization with parakeratosis and a relatively distinct cell border. (B) Moderately-differentiated squamous cell carcinoma demonstrated a distinct cell border, however, no keratinization was observed. (C) Poorly-differentiated squamous cell carcinoma exhibited a vague cellular border. This tumor was positive for p63 immunostaining and negative for thyroid transcription factor-1 immunostaining, indicating a differential diagnosis from solid pattern adenocarcinoma. (D) Myoferlin protein was expressed in the cytoplasm of the tumor cells. Capillary endothelial cells in the stroma additionally demonstrated myoferlin expression. (E) Vascular endothelial growth factor receptor-2 expression was observed in the cytoplasm of the tumor cells. (F) Poorly-differentiated squamous cell carcinoma demonstrated p63 expression in the nucleus. Magnification, x400.

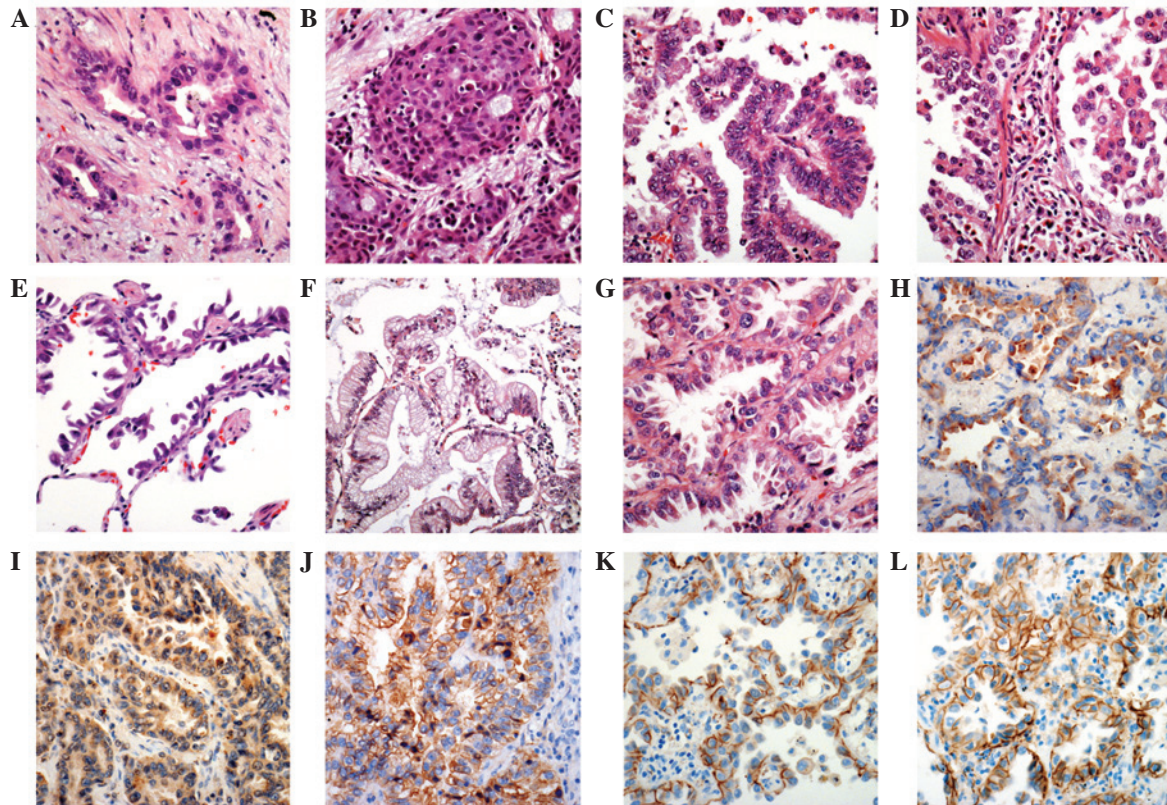


Figure 2. Microscopic features of adenocarcinoma following hematoxylin and eosin staining. (A) Acinar pattern of adenocarcinoma revealed glands with central lumina. (B) Solid pattern adenocarcinoma revealed highly packed cells with no specific pattern. (C) Papillary pattern adenocarcinoma exhibited tumor cell proliferation with a central vascular core. (D) Micropapillary pattern adenocarcinoma revealed projective cell proliferation with no fibrovascular core. (E) Lepidic pattern adenocarcinoma revealed a preserved alveolar structure. (F) Proliferation of mucin-containing tumor cells was observed in mucinous adenocarcinoma. (G) Adenocarcinoma without thyroid transcription factor-1 staining and nuclear pleomorphism with occasionally prominent nucleoli. This tumor was classified as low nuclear grade. (H) Cytoplasmic myoferlin expression. (I) Vascular endothelial growth factor receptor-2 was additionally expressed in the cytoplasm. (J) E-cadherin protein was located in the cell membrane with focal expression in the cytoplasm. (K) β -catenin was expressed in the cell membrane. (L) Epidermal growth factor receptor protein was additionally expressed in the cell membrane. Magnification, x400.

Table IV. Cox proportional hazard model analysis of squamous cell carcinoma and adenocarcinoma patients.

Analysis	Sqcc		Adc	
	OR	P-value	OR	P-value
Univariate				
Myoferlin, negative vs. positive	1.221	0.512	1.556	0.677
VEGFR2, negative vs. positive	1.219	0.542	0.682	0.589
β -catenin, positive vs. negative	0.919	0.821	N/A	N/A
E-cadherin, positive vs. negative	1.139	0.695	N/A	N/A
EGFR, negative vs. positive	0.871	0.656	0.347	0.320
p63, positive vs. negative	1.908	0.143	N/A	N/A
TTF-1, positive vs. negative	N/A	N/A	1.560	0.530
Differentiation of Sqcc, M/D and W/D vs. P/D	2.010	0.029	N/A	N/A
Pattern of Adc, others vs. solid and micropapillary	N/A	N/A	3.111	0.092
Nuclear grade of Adc, low vs. high	N/A	N/A	0.771	0.714
Median age, <67 vs. \geq 67 in Sqcc; <65 vs. \geq 65 in Adc	1.080	0.842	2.912	0.286
Smoking history, non-smoker vs. ex- or current	0.579	0.114	3.155	0.188
Stage, <IIa vs. \geq IIb	1.765	0.094	6.721	0.057
Procedure, L vs. P, bi and sleeve	1.487	0.316	N/A ^a	N/A ^a
Differentiation of Sqcc, M/D and W/D vs. P/D	1.561	0.250	N/A	N/A
Multivariate				
Pattern of Adc, others vs. solid and micropapillary	N/A	N/A	1.639	0.570
Myoferlin, negative vs. positive	1.028	0.938	2.942	0.339
EGFR, negative vs. positive	0.990	0.978	0.248	0.298
VEGFR2, negative vs. positive	1.101	0.833	0.145	0.055
E-cadherin, positive vs. negative	1.252	0.541	N/A	N/A
p63, positive vs. negative	1.680	0.370	N/A	N/A
TTF-1, positive vs. negative	N/A	N/A	0.642	0.608

^aAll adenocarcinoma patients were treated by lobectomy. N/A, statistically not informative as all 37 adenocarcinomas showed positivity for beta-catenin; Sqcc, squamous cell carcinoma; Adc, adenocarcinoma; W/D, well-differentiated; M/D, moderately-differentiated; P/D, poorly-differentiated; CI, confidence interval; OR, odds ratio; VEGFR2, vascular endothelial growth factor 2; EGFR, epidermal growth factor receptor; TTF-1, thyroid transcription factor 1; L, lobectomy; P, pneumonectomy; bi, bilobectomy; sleeve, sleeve lobectomy.

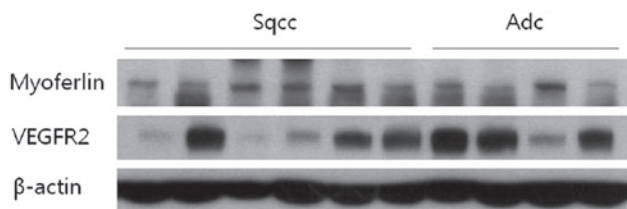


Figure 3. Western blot analysis of non-small cell carcinoma samples from 6 patients with squamous cell carcinoma and four patients with adenocarcinoma. Immunohistochemically, all patients demonstrated positive expression for myoferlin protein. Upon western blotting, there were also positive signals for myoferlin. Several specimens additionally demonstrated VEGFR-2 expression. β -actin served as a control for equivalent protein loading. Sqcc, squamous cell carcinoma; Adc, adenocarcinoma; VEGFR-2, vascular endothelial growth factor receptor-2.

odds ratio of 1.765 (95% CI, 0.908-3.429; P=0.094), procedure had an odds ratio of 1.487 (95% CI, 0.684-3.232; P=0.316),

pathologic differentiation had an odds ratio of 1.561 (95% CI, 0.730-3.337; P=0.250) and loss of p63 expression demonstrated an odds ratio of 1.680 (95% CI, 0.541-5.219; P=0.370).

Survival analysis of adenocarcinoma. As shown in Table IV, univariate analysis of adenocarcinoma patients indicated that a pathological group of solid and micropapillary growth patterns possessed relatively high odds ratios of 3.111 (95% CI, 0.832-11.633; P=0.092). The parameter of EGFR expression had an odds ratio of 0.347 (95% CI, 0.043-2.793; P=0.320). Myoferlin, VEGFR-2 and TTF-1 expression possessed odds ratios of 1.556 (95% CI, 0.194-12.472; P=0.677), 0.682 (95% CI, 0.170-2.735; P=0.589) and 1.560 (95% CI, 0.390-6.251; P=0.530), respectively. Upon multivariate analysis, VEGFR-2 expression demonstrated an odds ratio of 0.145 (95% CI, 0.020-1.046; P=0.055). EGFR expression, myoferlin expression and pathological pattern possessed odds

ratios of 0.248 (95% CI, 0.018-3.429; $P=0.298$), 2.942 (95% CI, 0.321-26.930; $P=0.339$) and 1.639 (95% CI, 0.298-9.006; $P=0.570$), respectively.

Discussion

Myoferlin expression was identified in 75/148 NSCLC patients. All NSCLC pathological subtypes contained myoferlin-positive tumors. Adenocarcinomas possessed the largest proportion of myoferlin-expressing tumors. Immunohistochemistry indicated that myoferlin protein was localized to the cytoplasm of the tumor cells. Leung *et al* (1,13) previously described cytoplasmic expression of myoferlin in human airway epithelium and mouse Lewis lung carcinoma (LCC) cells. In airway epithelial cells, myoferlin expression was detected in the cytoplasm, cell membrane and Golgi membrane using confocal microscopy, immunofluorescent staining and immunohistochemical staining. In LCC cells, cytoplasmic expression of myoferlin was detected by studying immunofluorescence. In the present study, normal bronchial epithelial cells and NSCLC cells demonstrated similar localization of expressed protein. Dislocation of myoferlin protein, from the cell membrane to the cytoplasm, requires further investigation in order to specify the pathophysiological function of myoferlin.

The present study identified that adenocarcinoma patients with myoferlin protein expression possess poorer prognoses (odds ratio, 2.942; $P=0.339$) upon multivariate analysis. However, the P -value was not <0.05 , therefore this was not a statistically significant difference. However, there was a higher odds ratio in the myoferlin-expressing group compared with the group comprising solid and micropapillary pattern tumors upon multivariate analysis. Pulmonary adenocarcinoma with a micropapillary and solid pattern is a well-known indicator of a poor prognosis, therefore, further evaluation of these factors may be required in a larger study (21).

In a previous study, Sun *et al* (22) reported clinically relevant mutations associated with pulmonary adenocarcinoma in 10 genes, *EGFR*, tumor protein p53, *KRAS*, ribosomal protein S6 kinase β -2, *Ataxin-2*, *DHX9*, tyrosine-protein phosphatase non-receptor type 13, specificity protein 1*, spectrin α non-erythrocytic 1 and myoferlin (*MYOF*) using sequencing analysis. Mutation of the *MYOF* gene in lung adenocarcinoma was detected upon exome and messenger RNA sequencing analysis. As the list of genes identified by Sun *et al* (22) included *EGFR* and *KRAS*, which are clinicopathologically significant mutations in pulmonary adenocarcinomas, further molecular study of the *MYOF* gene may be required.

Another notable result of the present study is the statistically significant correlation identified between myoferlin and VEGFR-2 expression in adenocarcinoma and squamous cell carcinoma ($P<0.001$). This correlation was more pronounced in stage I patients ($P<0.001$) compared with stage II ($P=0.220$) or stage III ($P=0.576$) patients; as stage increased, the correlation became less significant. The correlation between myoferlin and VEGFR-2 expression demonstrated increased significance in squamous cell carcinoma ($P=0.001$) compared with adenocarcinoma ($P=0.140$). Yu *et al* (6) and Bernatchez *et al* (7) have previously reported

that the physiological function of myoferlin is to regulate VEGFR-2 stability and activity; loss of myoferlin reduces the expression and autophosphorylation of VEGFR-2 in endothelial cells. These functions additionally require the endothelial cell-specific tyrosine kinase receptors, dynamin-2 and tyrosine kinase with immunoglobulin and epidermal growth factor homology domains-2. However, to the best of our knowledge, only two studies have discussed the physiological functions of myoferlin with respect to VEGFR-2 (6,7). Although myoferlin is relatively well studied in skeletal muscle due to its role in musculopathy, its precise physiological functions remain to be fully elucidated. The function of myoferlin in tumor cells is also unclear. To the best of our knowledge, the present study is the first to reveal a marked correlation between myoferlin and VEGFR-2 expression *in vivo* in tumor cells.

Angiogenic factors of cancer, VEGF and VEGFR, are well-established drug targets. Bevacizumab is a monoclonal antibody of VEGF (19). It was the first angiogenic inhibitor to be identified. In patients exhibiting squamous cell carcinoma, bevacizumab induced the side effect of hemoptysis (23). However, more recent clinical trials investigating VEGFR-2-targeted therapy demonstrated a relatively positive performance, without induction of hemoptysis, in patients exhibiting NSCLC containing squamous cell carcinoma (24). In addition, small molecule inhibitors of receptor tyrosine kinases, which work with VEGFR-2, nintedanib, sunitinib, sorafenib, vandetanib and vatalanib, have been tested as potential anticancer therapies (25,26). Due to the association between myoferlin and VEGFR-2 observed in the current study, the efficacy of myoferlin as a therapeutic agent may require further investigation.

In conclusion, to the best of our knowledge, the present study is the first to describe myoferlin expression in NSCLC. In adenocarcinoma cases, myoferlin-positive patients possessed a poor prognosis (odds ratio, 2.94; $P=0.339$). In squamous cell carcinoma cases, myoferlin expression was significantly associated with VEGFR-2 expression ($P=0.001$). As VEGFR-2 is a significant therapeutic target, myoferlin expression in NSCLC may require further investigation in future studies.

References

1. Leung C, Yu C, Lin MI, Tognon C and Bernatchez P: Expression of myoferlin in human and murine carcinoma tumors: Role in membrane repair, cell proliferation and tumorigenesis. *Am J Pathol* 182: 1900-1909, 2013.
2. Achanzar WE and Ward S: A nematode gene required for sperm vesicle fusion. *J Cell Sci* 110: 1073-1081, 1997.
3. Ward S, Argon Y and Nelson GA: Sperm morphogenesis in wild-type and fertilization-defective mutants of *Caenorhabditis elegans*. *J Cell Biol* 91: 26-44, 1981.
4. Posey AD Jr, Pytel P, Gardikiotes K, *et al*: Endocytic recycling proteins EHD1 and EHD2 interact with fer-1-like-5 (Fer1L5) and mediate myoblast fusion. *J Biol Chem* 286: 7379-7388, 2011.
5. Doherty KR, Cave A, Davis DB, Delmonte AJ, Posey A, Earley JU, Hadhazy M and McNally EM: Normal myoblast fusion requires myoferlin. *Development* 132: 5565-5575, 2005.
6. Yu C, Sharma A, Trane A, Utokaparch S, Leung C and Bernatchez P: Myoferlin gene silencing decreases Tie-2 expression *in vitro* and angiogenesis *in vivo*. *Vascul Pharmacol* 55: 26-33, 2011.
7. Bernatchez PN, Acevedo L, Fernandez-Hernando C, Murata T, Chalouni C, Kim J, Erdjument-Bromage H, Shah V, Gratton JP, McNally EM, *et al*: Myoferlin regulates vascular endothelial growth factor receptor-2 stability and function. *J Biol Chem* 282: 30745-30753, 2007.

8. Li R, Ackerman WE 4th, Mihai C, Volakis LI, Ghadiali S and Kniss DA: Myoferlin depletion in breast cancer cells promotes mesenchymal to epithelial shape change and stalls invasion. *PLoS One* 7: e39766, 2012.
9. Volakis LI, Li R, Ackerman WE 4th, Mihai C, Bechel M, Summerfield TL, Ahn CS, Powell HM, Zielinski R, Rosol TJ, *et al*: Loss of myoferlin redirects breast cancer cell motility towards collective migration. *PLoS One* 9: e86110, 2014.
10. Eisenberg MC, Kim Y, Li R, Ackerman WE, Kniss DA and Friedman A: Mechanistic modeling of the effects of myoferlin on tumor cell invasion. *Proc Natl Acad Sci USA* 108: 20078-20083, 2011.
11. Turtoi A, Blomme A, Bellahcène A, Gilles C, Hennequière V, Peixoto P, Bianchi E, Noel A, De Pauw E, Lifrange E, *et al*: Myoferlin is a key regulator of EGFR activity in breast cancer. *Cancer Res* 73: 5438-5448, 2013.
12. Wang WS, Liu XH, Liu LX, Lou WH, Jin DY, Yang PY and Wang XL: iTRAQ-based quantitative proteomics reveals myoferlin as a novel prognostic predictor in pancreatic adenocarcinoma. *J Proteomics* 91: 453-465, 2013.
13. Leung C, Shaheen F, Bernatchez P and Hackett TL: Expression of myoferlin in human airway epithelium and its role in cell adhesion and zonula occludens-1 expression. *PLoS One* 7: e40478, 2012.
14. Chheang S and Brown K: Lung cancer staging: Clinical and radiologic perspectives. *Semin Intervent Radiol* 30: 99-113, 2013.
15. Travis WD, Brambilla E, Noguchi M, Nicholson AG, Geisinger KR, Yatabe Y, Beer DG, Powell CA, Riely GJ, Van Schil PE, *et al*: International association for the study of lung cancer/american thoracic society/european respiratory society international multidisciplinary classification of lung adenocarcinoma. *J Thorac Oncol* 6: 244-285, 2011.
16. Ha SY and Roh MS: The new 2011 international association for the study of lung cancer/american thoracic society/european respiratory society classification of lung adenocarcinoma in resected specimens: Clinicopathologic relevance and emerging issues. *Korean J Pathol* 47: 316-325, 2013.
17. Suzuki S, Dobashi Y, Sakurai H, Nishikawa K, Hanawa M and Ooi A: Protein overexpression and gene amplification of epidermal growth factor receptor in nonsmall cell lung carcinomas. An immunohistochemical and fluorescence in situ hybridization study. *Cancer* 103: 1265-1273, 2005.
18. Kim H, Yoo SB, Sun P, Jin Y, Jheon S, Lee CT and Chung JH: Alteration of the E-Cadherin/beta-Catenin Complex is an independent poor prognostic factor in lung adenocarcinoma. *Korean J Pathol* 47: 44-51, 2013.
19. Rekhtman N, Ang DC, Sima CS, Travis WD and Moreira AL: Immunohistochemical algorithm for differentiation of lung adenocarcinoma and squamous cell carcinoma based on large series of whole-tissue sections with validation in small specimens. *Mod Pathol* 24: 1348-1359, 2011.
20. Jang I, Jeon BT, Jeong EA, Kim EJ, Kang D, Lee JS, Jeong BG, Kim JH, Choi BH, Lee JE, *et al*: Pak1/LIMK1/cofilin pathway contributes to tumor migration and invasion in human non-small cell lung carcinomas and cell lines. *Korean J Physiol Pharmacol* 16: 159-165, 2012.
21. Morales-Oyarvide V and Mino-Kenudson M: High-grade lung adenocarcinomas with micropapillary and/or solid patterns: A review. *Curr Opin Pulm Med* 20: 317-323, 2014.
22. Sun Z, Wang L, Eckloff BW, Deng B, Wang Y, Wampfler JA, Jang J, Wieben ED, Jen J, You M and Yang P: Conserved recurrent gene mutations correlate with pathway deregulation and clinical outcomes of lung adenocarcinoma in never-smokers. *BMC Med Genomics* 7: 32, 2014.
23. Lauro S, Onesti CE, Righini R and Marchetti P: The use of bevacizumab in non-small cell lung cancer: An update. *Anticancer Res* 34: 1537-1545, 2014.
24. Garon EB, Ciuleanu TE, Arrieta O, Prabhaskar K, Syrigos KN, Goksel T, Park K, Gorbunova V, Kowalyszyn RD, Pikiel J, *et al*: Ramucirumab plus docetaxel versus placebo plus docetaxel for second-line treatment of stage IV non-small-cell lung cancer after disease progression on platinum-based therapy (REVEL): A multicentre, double-blind, randomised phase 3 trial. *Lancet* 384: 665-673, 2014.
25. Rashdan S and Hanna N: Nintedanib for the treatment of non-small-cell lung cancer. *Expert Opin Pharmacother* 15: 729-739, 2014.
26. Majeti BK, Lee JH, Simmons BH and Shojaei F: VEGF is an important mediator of tumor angiogenesis in malignant lesions in a genetically engineered mouse model of lung adenocarcinoma. *BMC Cancer* 13: 213, 2013.