



# Spinal Subdural Hematoma following Epidural Anesthesia

Rajesh Bhosle<sup>1</sup> Dimble Raju<sup>1</sup> Shamshuddin Senior Patel<sup>1</sup> Grandhi Aditya<sup>1</sup> Jagriti Shukla<sup>1</sup>  
Nabanita Ghosh<sup>1</sup> Prasad Krishnan<sup>1</sup>

<sup>1</sup>Department of Neurosurgery, National Neurosciences Centre, Kolkata, West Bengal, India

Address for correspondence Prasad Krishnan, MS, MCh, Department of Neurosurgery, National Neurosciences Centre, 2nd Floor, Peerless Hospital Campus, 360, Panchasayar, Garia, 700094, Kolkata, West Bengal, India (e-mail: prasad.krishnan@rediffmail.com).

AJNS 2023;18:347–351.

## Abstract

The spinal subdural space is an avascular, potential space and is a rare location for intraspinal hematomas. Compared to spinal epidural hematomas, spinal subdural hematomas are uncommonly described complications of lumbar puncture for spinal or epidural anesthesia, particularly in patients who have no pre-existing bleeding disorders or history of antiplatelet or anticoagulant intake. We describe a 19-year-old girl who had a large thoracolumbar spinal subdural hematoma following epidural anesthesia for elective cholecystectomy with no pre-existing bleeding diathesis that caused rapidly developing paraplegia that evolved over the next 2 days following surgery. Nine days after the initial surgery she underwent multilevel laminectomy and surgical evacuation with eventual satisfactory recovery. Even epidural anesthesia without thecal sac violation can result in bleeding in the spinal subdural space. The possible sources of bleed in this space may be from injury to an interdural vein or extravasation of subarachnoid bleed into the subdural space. When neurological deficits occur, prompt imaging is mandatory and early evacuation yields gratifying results.

## Keywords

- ▶ lumbar puncture
- ▶ epidural anesthesia
- ▶ spinal subdural hematoma
- ▶ laminectomy
- ▶ complications

## Introduction

Neurological deterioration after lumbar puncture (LP) can be a result of nerve root injury, inadvertent damage to a low-lying cord, iatrogenic spinal hematomas, drug- and dosage-related complications, or coning in the presence of an undetected intracranial or spinal tumor.<sup>1</sup>

Analyzing the literature between 1974 and 2016 Brown et al<sup>2</sup> found only 35 cases of post-LP spinal hematomas of which 9 were spinal subdural hematomas (SSDHs). Nine others were epidural, 14 were subarachnoid, in 1 case the location was not specified, while in a further two cases, the hematoma was multicompartamental. However, it is unusual

for a patient to develop a SSDH after epidural anesthesia without thecal sac violation as happened in this case.

## Case Report

A 19-year-old patient underwent elective cholecystectomy under epidural anesthesia. Her preoperative coagulation profile (prothrombin time and activated partial thromboplastin time) as well as her platelet counts were normal. She was not on any antiplatelet or anticoagulant medication and had no history of any pre-existing bleeding disorder. The epidural catheter was inserted through the L3-L4 interspace

article published online  
June 7, 2023

DOI <https://doi.org/10.1055/s-0043-1768576>.  
ISSN 2248-9614.

© 2023. Asian Congress of Neurological Surgeons. All rights reserved.

This is an open access article published by Thieme under the terms of the Creative Commons Attribution-NonDerivative-NonCommercial-License, permitting copying and reproduction so long as the original work is given appropriate credit. Contents may not be used for commercial purposes, or adapted, remixed, transformed or built upon. (<https://creativecommons.org/licenses/by-nc-nd/4.0/>)

Thieme Medical and Scientific Publishers Pvt. Ltd., A-12, 2nd Floor, Sector 2, Noida-201301 UP, India

and the level of epidural anesthesia was D4 dermatome. Immediately following surgery, the epidural catheter was removed. On the evening of surgery, she complained of intense diffuse back pain and over the next 2 days rapidly lost power in both lower limbs with complete sensory loss below D10 dermatome with inability to pass urine or stool with loss of perianal sensations as well. During anesthesia, there was no history of thecal sac breach and no cerebrospinal fluid had egressed. A magnetic resonance imaging (MRI) study done more than 72 hours after the operation showed a T1 hyperintense and T2 mixed intensity intradural extra-medullary hematoma with cord compression and effacement of spinal subarachnoid space extending from D8 to L5 vertebral levels (►Fig. 1).

She presented to us 9 days after the initial surgery and bleeding parameters were rechecked and found to be normal and a spinal angiogram was done that ruled out any arteriovenous malformation. She then underwent D9 to L4 laminectomy. The dura was bluish and tense. Durotomy revealed all the lumbar roots to be clumped together in the midline with the cord and each other and an anteriorly located organized thick clot was seen in the subdural space that was removed piecemeal from both sides of the roots and cords till the anterior dura was seen (►Fig. 2). No abnormal vessels or bleeding point were encountered. Postoperatively, she gradually regained power and sensations in the legs and after 6 weeks became independently ambulant and continent.

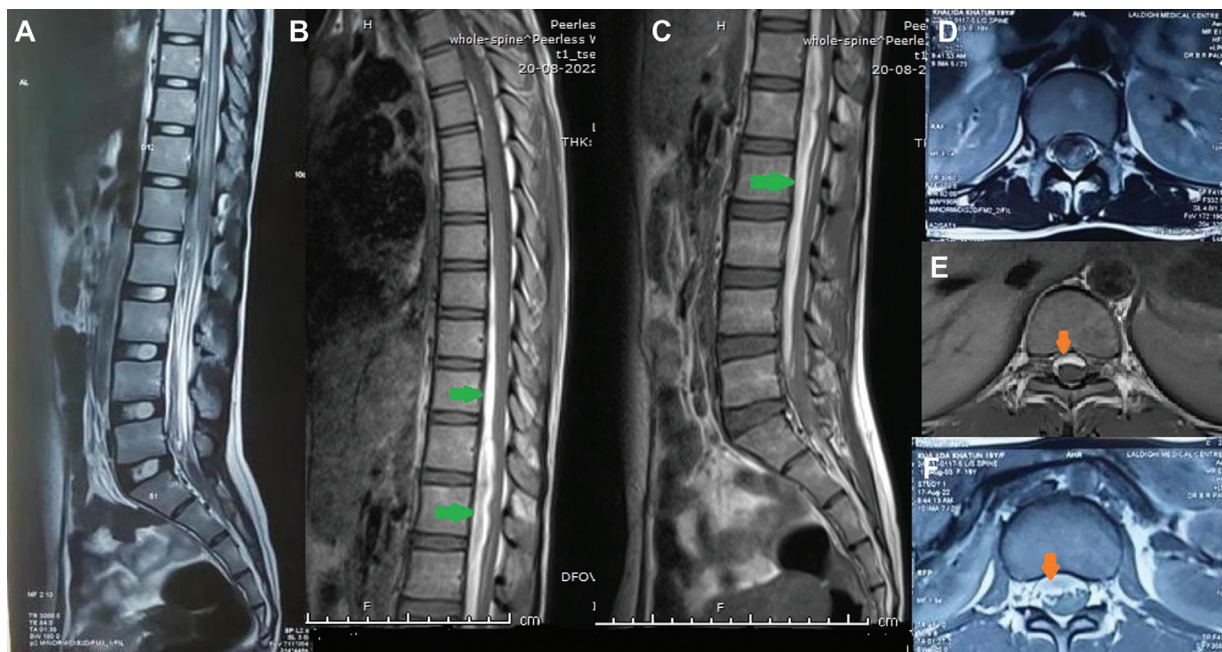
Postoperative MRI showed no residual clot in the subdural space with reformation of the spinal subarachnoid space (►Fig. 3).

## Discussion

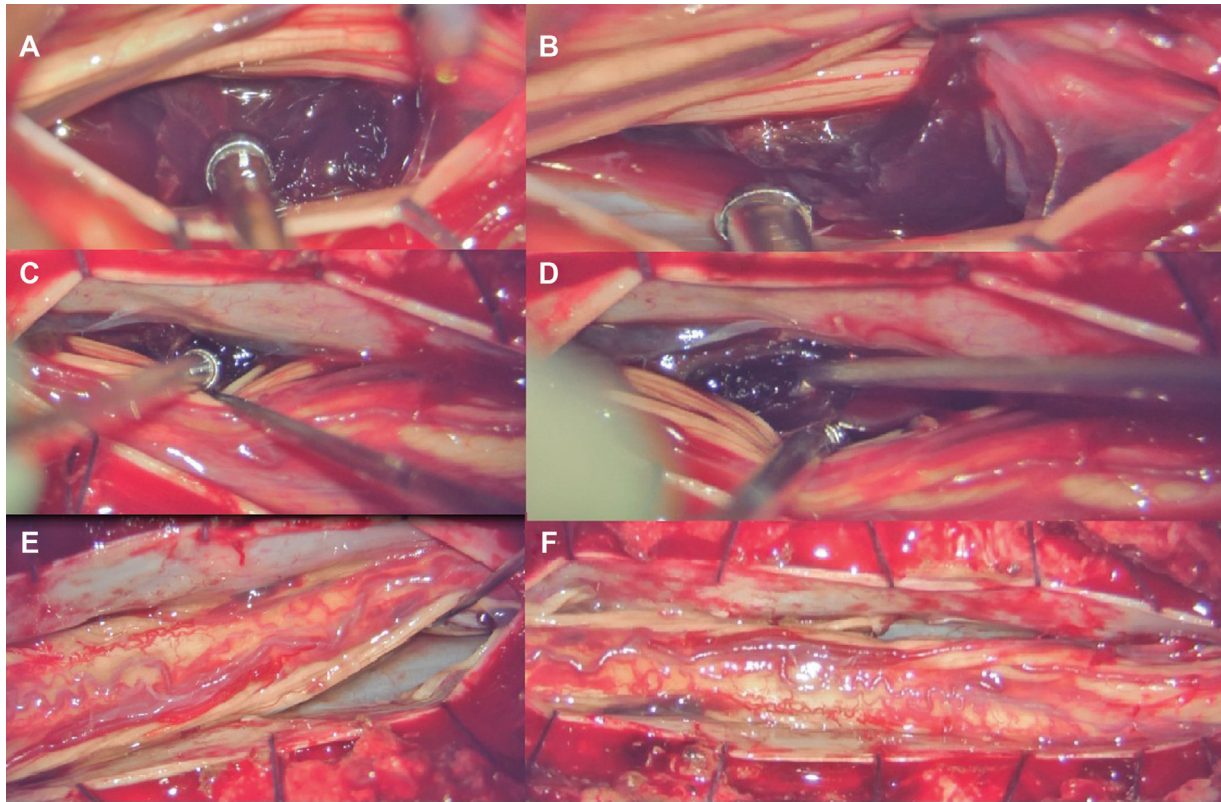
The first clinically diagnosed SSDH was described by Robert Jackson in 1869<sup>3</sup> who called it “spinal apoplexy” in the cervical spine and was confirmed later by postmortem examination in a 14 years old girl who died following rapidly progressive quadriplegia and respiratory failure. While SSDHs can be a result of LP, spinal tumors, spinal vascular malformations, spinal surgery, anticoagulation therapy, and bleeding diathesis, Ji et al<sup>4</sup> state that LP is the rarest cause of any spinal hematoma, with an incidence of less than 1%. They also state that among all spinal hematomas caused by LPs epidural hematoma is the commonest (75%), while sub-arachnoid hematoma and SSDH account for 15.7 and 4.1%, respectively.<sup>4</sup> Kreppel et al<sup>5</sup> too reported only 25 cases (4%) of SSDHs in a meta-analysis of 613 patients of spinal hematomas with varying etiologies.

In SSDHs caused following LP, concomitant bleeding diathesis is an important etiology and of the nine cases reported by Brown et al,<sup>2</sup> four had thrombocytopenia, one was on anticoagulants, and one was in a premature infant. In only three cases (33%), as in ours, there were no deranged bleeding parameters.

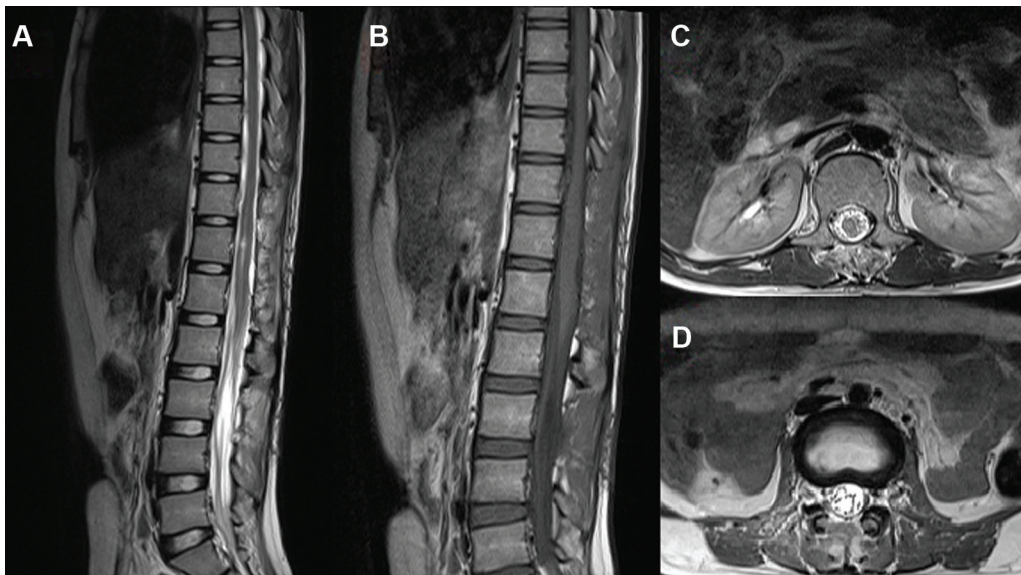
While damage to the venous plexus in the epidural fat and injury to radicular arteries and veins coursing along the lumbar roots during LP for epidural and spinal anesthesia have been implicated as the cause of bleeding in spinal epidural and spinal subarachnoid hemorrhages<sup>6</sup> respectively, the source of hemorrhage in a SSDH is unclear.<sup>7</sup> In fact, various authors<sup>6,7</sup> note that blood vessels are not apparent on the inner aspect of the spinal dura and also that there are no bridging veins



**Fig. 1** T2 sagittal magnetic resonance imaging (A) showing a heterogeneous intensity mass situated anterior to the spinal cords and roots with signal change in the cord at D10-D12 levels. The mass is predominantly hyperintense and anteriorly located on T1 imaging both at dorsal (B) and lumbar (C) levels (green arrows). Axial T2 image at D12-L1 level (D) shows a hypointense lesion compressing cord and roots with obliteration of the cerebrospinal fluid (CSF) space, axial T1 image (E) shows the “cap” sign with cord pushed dorsally (orange arrow), and axial T1 image at the lumbar spine (F) too shows hyperintense lesion (orange arrow) with effacement of CSF space and root compression.



**Fig. 2** Intraoperative microscopic images showing (A) organized thick clot anterior to the roots in the lumbar region, (B) piecemeal removal of clots with exposure of anterior dura, in the dorsal region the clots are drawn into the limited operative field by gentle suction (C) and then removed with forceps (D), clean anterior dura (E) is seen and finally (F) cord with normal vasculature after clot removal. All images show neither the cord nor the roots to be stained with blood showing it is not subarachnoid in location.



**Fig. 3** Postoperative T2 sagittal magnetic resonance imaging (A) showing no residual clot and reformation of the cerebrospinal fluid (CSF) space around the cord and roots, sagittal T1 image (B) showing no residual hyperintense lesion, and T2 axial images at dorsal (C) and lumbar (D) levels showing cord and roots surrounded by CSF.

traversing the spinal subdural space unlike what is seen in the intracranial subdural compartment which might be the source of bleed. Moreover, Pierce et al<sup>6</sup> stress that the “presence of a true spinal subdural space is controversial,” while others<sup>5</sup> have described this space as “merely a capillary slit.”

Hence, Post et al<sup>8</sup> have offered two hypotheses for the development of hematomas in this space—(a) opening up of the potential space between the spinal dura and arachnoid by subarachnoid blood that comes out of the arachnoidal rent into the subdural space—a proposition that has also been put

forward by Rettenmaier et al<sup>9</sup> or (b) “cleaving open” of the dura itself with separation of the outer thicker and inner tenuous layer of the dura with subsequent bleeding accumulating between the dura and the arachnoid that can happen during drug delivery without violation of the arachnoid. The second theory is supported by Spanu et al<sup>10</sup> who found an encysted collection in the subdural space in a patient who had undergone serial LP, and hypothesized that the source of bleed was from a damaged interdural vein.

Whatever be the source of bleed most cases of SSDHs following LP have been reported following entry into the spinal arachnoidal space during procedure. We could find only two cases<sup>11,12</sup> prior to ours where SSDH was the result of an epidural anesthesia, while in one more case<sup>13</sup> it was after a combined epidural–spinal anesthesia was given.

The common presenting symptoms in patients with SSDHs are motor deficits, back pain, radicular pain, and parasthesias.<sup>14</sup> With increasing compression, sphincter involvement and complete paraplegia and quadriplegia too may occur<sup>9</sup> as happened in our case. These symptoms may be discovered immediately after the effects of the anesthetic drug wear off but may also develop and progress over time<sup>11,14</sup> as occurred in this patient. This may be due to slow accumulation of blood and Domenicucci et al<sup>14</sup> have mentioned that symptoms can develop between 3 and 86 hours after a LP. It also may occur if the tamponading effect of the epidural catheter on a damaged vessel is removed, and Chan and Lindsay<sup>11</sup> state that removal of the epidural catheter may be an important event in the onset of symptoms.

MRI is the investigation of choice to identify the pathology<sup>6,9</sup> as it delineates both the spinal compartment where the bleed occurred (epidural, subdural or subarachnoid) as well as the longitudinal extent of the bleed, cord signal changes or injury, and any associated pathology.<sup>6</sup>

Following spinal or epidural anesthesia, MRI must be done as soon as deficits are detected as early surgery has better results than delayed evacuation.<sup>2,15</sup> The classical findings of SSDHs in MRI include the “Mercedes-Benz” and “cap” signs.<sup>16</sup> The intensity pattern on T1 and T2 sequences on MRI depend on the age of the hematoma<sup>9</sup> that is again dependent on how long after the bleed the MRI was performed. In our case, a mixed intensity signal on T2 imaging and a hyperintense signal on T1 imaging were seen as the MRI was done more than 72 hours after the event and was consistent with the signal patterns seen in a bleed in the early subacute phase.<sup>6</sup>

The treatment of SSDHs can be both conservative and surgical depending on the extent of neurological deficits.<sup>9</sup> Brown et al<sup>2</sup> did not find any statistical difference between outcomes in surgically and conservatively treated cases of all types of spinal hematomas caused by LP in their series. However, Rettenmaier et al<sup>9</sup> argue that superior results with conservative management in SSDHs reflect a selection bias as only patients who have severe deficits are offered surgery, while those who are preserved neurologically are usually managed with medications. Conversely, Ji et al<sup>4</sup> state that there is a 63.6% chance of developing permanent deficits

and sphincter loss in those who have neurological symptoms but do not undergo surgery as opposed to such poor outcomes in only 17.9% in cases with symptoms who undergo surgery and advocate intervention as soon as possible as was done in this instance.

Finally, paraplegia following spinal or epidural anesthesia can be a subject matter for litigation and the person performing the procedure should be aware of the potential complications it entails and observe the patient in the postoperative period for immediate and delayed neurological deficits. Though not widely available, ultrasound-guided central neuraxial blocks have increasingly become the norm and must be utilized<sup>17</sup> if facilities are available to decrease chances of iatrogenic injury to intraspinal neural or vascular structures.

## Conclusion

SSDHs are rare in comparison to spinal epidural hematomas. They have been reported after LP for spinal anesthesia (particularly in the setting of bleeding disorders) but less frequently after epidural anesthesia in those with normal coagulation profile as happened in our patient. While the origin of bleed is still a matter of debate, the presentation depends on the extent of neural compression and can range from back and radicular pain to paraplegia with sphincter involvement. They may not come to light immediately after the effects of anesthesia wear off as they may evolve slowly over the next few days as happened in this case. MRI must be done at the earliest to delineate the horizontal location and the vertical extent of bleed in the spinal canal. Finally, our patient had complete recovery even though she underwent delayed evacuation of the SSDH. Hence, though early evacuation is desirable, we feel surgery must not be denied even if the patient presents late with complete motor, sensory, and sphincteric deficits.

### Informed Consent

Informed consent was received from the patient for this study.

### Conflict of Interest

None declared.

## References

- 1 Krishnan P, Roychowdhury S. Spinal coning after lumbar puncture in a patient with undiagnosed giant cervical neurofibroma. *Ann Indian Acad Neurol* 2013;16(03):440–442
- 2 Brown MW, Yilmaz TS, Kasper EM. Iatrogenic spinal hematoma as a complication of lumbar puncture: what is the risk and best management plan? *Surg Neurol Int* 2016;7(Suppl 22):S581–S589
- 3 Jackson R. Case of spinal apoplexy. *Lancet* 1869;2:5–6
- 4 Ji JY, Ahn JM, Chung JH, et al. Spinal intradural hematoma after spinal anesthesia in a young male patient: case report and review of the literature. *Int J Environ Res Public Health* 2022; 19(08):4845
- 5 Kreppel D, Antoniadis G, Seeling W. Spinal hematoma: a literature survey with meta-analysis of 613 patients. *Neurosurg Rev* 2003; 26(01):1–49

- 6 Pierce JL, Donahue JH, Nacey NC, et al. Spinal hematomas: what a radiologist needs to know. *Radiographics* 2018;38(05): 1516–1535
- 7 Edelson RN, Chernik NL, Posner JB. Spinal subdural hematomas complicating lumbar puncture. *Arch Neurol* 1974;31(02): 134–137
- 8 Post MJ, Becerra JL, Madsen PW, et al. Acute spinal subdural hematoma: MR and CT findings with pathologic correlates. *AJNR Am J Neuroradiol* 1994;15(10):1895–1905
- 9 Rettenmaier LA, Holland MT, Abel TJ. Acute, nontraumatic spontaneous spinal subdural hematoma: a case report and systematic review of the literature. *Case Rep Neurol Med* 2017; 2017:2431041
- 10 Spanu G, Berlanda P, Rodriguez y Baena R. Spinal subdural haematoma: a rare complication of lumbar puncture. Case report and review of the literature. *Neurochirurgia (Stuttg)* 1988;31(05): 157–159
- 11 Chan MYL, Lindsay DA. Subdural spinal haematoma after epidural anaesthesia in a patient with spinal canal stenosis. *Anaesth Intensive Care* 2006;34(02):269–275
- 12 Maddali P, Walker B, Fisahn C, et al. Subdural thoracolumbar spine hematoma after spinal anesthesia: a rare occurrence and literature review of spinal hematomas after spinal anesthesia. *Cureus* 2017;9(02):e1032
- 13 Singhal N, Sethi P, Jain JK, Agarwal S. Spinal subdural hematoma with cauda equina syndrome: a complication of combined spinal epidural anesthesia. *J Anaesthesiol Clin Pharmacol* 2015;31(02): 244–245
- 14 Domenicucci M, Ramieri A, Ciappetta P, Delfini R. Nontraumatic acute spinal subdural hematoma: report of five cases and review of the literature. *J Neurosurg* 1999;91(01):65–73
- 15 Dezawa T, Hasegawa K, Tsuge S, Wada A, Takahashi H. A case of idiopathic thoracic spinal subdural hematoma with bilateral lower limb paralysis. *Cureus* 2021;13(07):e16585
- 16 Krishnan P, Banerjee TK. Classical imaging findings in spinal subdural hematoma - “Mercedes-Benz” and “Cap” signs. *Br J Neurosurg* 2016;30(01):99–100
- 17 Kalagara H, Nair H, Kolli S, Thota G, Uppal V. Ultrasound imaging of the spine for central neuraxial blockade: a technical description and evidence update. *Curr Anesthesiol Rep* 2021;11:326–339