

Case report



Postoperative myocardial injury in a patient with left ureteric stone and asymptomatic COVID-19 disease

Nadeem Kassam, Omar Aziz, Ally Zain Ismail, Rodgers Swai, Samina Somji, Robert Mvungi, Mustafafa Bapumia, Aliakber Zehri, Salim Surani

Corresponding author: Salim Surani, Department of Internal Medicine, Texas A&M Health Science Center, Bryan, USA. srsurani@hotmail.com

Received: 31 May 2020 - **Accepted:** 02 Jul 2020 - **Published:** 10 Jul 2020

Keywords: Coronavirus disease 2019 (COVID-19), severe acute respiratory syndrome coronavirus 2, myocardial infarction, ureteric calculi

Copyright: Nadeem Kassam et al. Pan African Medical Journal (ISSN: 1937-8688). This is an Open Access article distributed under the terms of the Creative Commons Attribution International 4.0 License (<https://creativecommons.org/licenses/by/4.0/>), which permits unrestricted use, distribution, and reproduction in any medium, provided the original work is properly cited.

Cite this article: Nadeem Kassam et al. Postoperative myocardial injury in a patient with left ureteric stone and asymptomatic COVID-19 disease. Pan African Medical Journal. 2020;36(170). 10.11604/pamj.2020.36.170.23882

Available online at: <https://www.panafrican-med-journal.com//content/article/36/170/full>

Postoperative myocardial injury in a patient with left ureteric stone and asymptomatic COVID-19 disease

Nadeem Kassam¹, Omar Aziz², Ally Zain Ismail³, Rodgers Swai⁴, Samina Somji¹, Robert Mvungi⁵, Mustafafa Bapumia⁵, Aliakber Zehri³, Salim Surani^{6,&}

¹Department of Internal medicine, Aga Khan University, Medical college, East Africa,

²Department of Internal medicine, Aga Khan Hospital, Dar-es-salaam, Tanzania ³Department of Surgery, Aga Khan University, Medical college, East Africa,

⁴Department of Intensive care, Aga Khan Hospital, Dar-es-salaam, Tanzania, ⁵Department of Cardiology, Aga Khan Hospital, Dar-es-salaam, Tanzania, ⁶Department of Internal Medicine, Texas A&M Health Science Center, Bryan, USA

Hospital, Dar-es-salaam, Tanzania, ⁵Department of Cardiology, Aga Khan Hospital, Dar-es-salaam, Tanzania, ⁶Department of Internal Medicine, Texas A&M Health Science Center, Bryan, USA

&Corresponding author

Salim Surani, Department of Internal Medicine, Texas A&M Health Science Center, Bryan, USA

Abstract

Coronavirus disease 2019 (COVID-19) is an infectious disease caused by severe acute respiratory syndrome coronavirus 2 (SARS-CoV-2). It was first identified on 8th December 2019 in Wuhan, Hubei, China, and has since spread globally to become an emergency of international concern. Patients infected with SARS-CoV-2 may be asymptomatic or present with symptoms ranging from mild clinical manifestations: such as fever, cough, and sore throat to moderate and severe form of the disease such as pneumonia and acute respiratory distress syndrome (ARDS). In some patients, SARS-CoV-2 can affect the heart and cause myocardial injury which is evidenced either by electrocardiographic (ECG) changes or by a rise in serum troponin level. Patients with myocardial involvement are generally at risk of developing severe illness and tend to have a poor outcome. We hereby present a case of a hypertensive male patient with undiagnosed, asymptomatic COVID-19, who underwent an emergency urologic procedure for ureteric calculi. He eventually sustained a postoperative myocardial injury resulting in his demise. This case highlights the importance of detailed preoperative assessment and anticipation of complications during this global pandemic.

Introduction

SARS-CoV-2 has spread across the world in a very short period, posing an extraordinary challenge. According to the situation report published by the World Health Organization, as of April 30th, 2020, it has affected more than 3 million people worldwide with more than 200,000 deaths. Patients with COVID-19 who have underlying cardiovascular disease and diabetes are at added risk of poor outcomes. Myocardial injury has been considered as an essential pathogenic feature of COVID-19 however the precise mechanism is not completely clear. It has been hypothesized that it generally results either from direct damage of myocytes or systemic inflammation resulting in an interferon-

mediated immune response. Additionally, the cytokine storm has also been considered to trigger stable coronary artery plaque which subsequently results in myocardial injury [1]. Therefore, it is expected that elderly patients with cardiovascular risk factors are predisposed to adverse consequences of the disease compared to younger individuals.

Patient and observation

A 60-year-old male with a history of hypertension presented with an acute, severe, left lumbar pain, radiating to the groin, associated with nausea and dull pain on micturition. He denied any history of fever or hematuria. He reported upper respiratory tract symptoms, including cough and chest pain for 10 days before admission which had slowly resolved. The patient denied having been in close contact with a COVID-19 patient. On examination, he was alert and oriented with stable vital signs. An abdominal examination revealed a tender left lumbar region. The rest of the physical examination was unremarkable. Computed tomography of the kidneys, ureters, and bladder revealed an obstructive left ureteric calculus at the vesicoureteric junction (VUJ) measuring 4.7mm (Figure 1). Blood workup revealed an elevated creatinine at 134 $\mu\text{mol/L}$ (59-104 $\mu\text{mol/L}$) and potassium of 6.26 mmol/L (3.3-5.1 mmol/L) suggestive of obstructive uropathy with acute kidney injury. Given the findings, the patient underwent emergency cystoscopy, left ureteroscopy, stone fragmentation, and Double J (DJ) ureteric stent insertion. The pre-operative assessment involved medication review and ECG, which was considered normal (Figure 2). Intraoperatively he was found to have significant distal left ureteric narrowing at the VUJ with a calculus proximal to the narrowing. The stone was fragmented, DJ stent was deployed, and a Foley catheter was placed to facilitate urinary drainage. In the recovery room, he was found to be desaturating at saturation of 80-85% on room air and required 8 L/min of oxygen supplementation via a face mask to maintain his oxygen saturation

above 94%. He was then transferred to the ward for post-operative management and close observation. 12 hours post-transfer to the ward he was found to be tachycardic at 130 beats per minute with normal sinus rhythm (Figure 2) and blood pressure ranging from 80/50 mmHg to 90/60 mmHg. On examination, he was alert, not diaphoretic but had cool and clammy extremities. Respiratory examination revealed bilateral basal crepitations. The patient denied having lightheadedness, chest pain, difficulty in breathing, or shortness of breath.

On workup, it was found that the patient had an abnormal ECG with ST-segment depressions and T wave inversion on the anterior (V1- V4) and inferior leads (III & aVF) (Figure 3), when compared to the preoperative ECG with markedly elevated troponin-T of 174.1 pg/ml (0-14 pg/ml). Other laboratory parameters were: Lactate dehydrogenase 494 IU/L (135-225 IU/L), Pro-BNP 375 pg/ml (0-125 pg/ml), Procalcitonin 1.67 ng/ml (0-2 ng/ml), C-Reactive Protein 312 mg/L (0.5-5 mg/L), INR 1.15, ferritin 1531 µg/l (22-322 µg/l), D-dimer 0.63 µg/ml (0-0.5 µg/ml). A portable chest x-ray revealed bilateral patchy pulmonary infiltrates with some coalescence observed in the periphery of lungs, a pattern consistent with a CO-RADS 5 classification, highly suggestive of COVID-19 (Figure 4), and was later confirmed by a nasopharyngeal swab using real-time reverse transcription-polymerase chain reaction (RT-PCR). He was transferred to an isolation intensive care unit and started on Non-ST Elevation Myocardial Infarction (NSTEMI) protocol where he received anticoagulant therapy with subcutaneous Enoxaparin 80 mg, 300 mg Clopidogrel, 600 mg Aspirin, and 80 mg Atorvastatin. Within a few hours of the patient's transfer to critical care, his clinical condition deteriorated rapidly necessitating intravenous inotropic support. He was subsequently intubated and put on mechanical ventilation. A repeat Troponin level at 6 hours was increased to 194 pg/ml while there was further documented worsening of renal function with BUN 16.70 mmol/l and creatinine 254 µmol/L. Unfortunately, a transthoracic echocardiogram was unavailable at

the time. His condition continued to deteriorate rapidly, and he went into shock and sustained a cardiac arrest. Cardiopulmonary resuscitation (CPR) was carried out according to American Cardiac Life Support (ACLS) protocol but was unsuccessful. The patient was pronounced dead after 30 minutes of CPR.

Discussion

The COVID-19 pandemic is one of the greatest international health care challenges we face in this modern time causing global turmoil with both health and economic challenges. So far, the focus of COVID-19 has primarily been the respiratory system. Extrapulmonary manifestation is still somewhat unfamiliar and variable, nevertheless, recent studies have recognized the role of cardiovascular disease as a risk factor of the severity of the infection [2]. Cardiovascular manifestations are not unique to this particular pandemic, SARS-CoV-2 appears to have similar pathophysiology of myocardial injury to the coronaviruses responsible for previous Severe Acute Respiratory Syndrome coronavirus (SARS) and the Middle East Respiratory Syndrome coronavirus (MERS-CoV) outbreak [3]. Myocarditis is a reflection of myocardial damage, out of the several mechanisms; direct myocardial injury due to fulminant viral myocarditis has been considered the most common [3]. This phenomenon results in circulatory and respiratory collapse, as observed in our patient and carries a very high in-hospital mortality of above 50% [4].

Diagnosis of myocarditis is a diagnostic dilemma it is practically a clinical concept and very few cases have been confirmed radiologically. In a case published by Inciardi *et al.*[5] the diagnosis of myocarditis was established with cardiac MRI which revealed biventricular oedema and gadolinium enhancement, a diagnostic tool currently not available in our setting. It is unclear what the precise precipitating event of our patient's sudden cardiac arrest was, though malignant arrhythmias have also been well noted in patients with COVID-19 who are admitted to

intensive care units (ICU). It has been assumed that the arrhythmias are likely to be attributable to hypoxia, metabolic disarray, or neurohormonal stress in the background of COVID-19 infection [6]. In terms of disease outcome, a cross-sectional study by Chen *et al.*[7] revealed: elevated N-terminal pro brain natriuretic peptide (NT-proBNP), cardiac troponin I (cTnI), and C- Reactive protein (CRP) was collectively suggestive of myocardial injury and inflammation that correlated with critical illness and poor outcomes. In the same study, it was also noted elderly patients with a history of hypertension and elevated serum creatinine were prone to poor prognosis as witnessed in our patient.

Conclusion

This case also highlights the need for detailed and standardized pre-operative assessment during the current COVID-19 pandemic, especially for asymptomatic patients. Comprehensive assessments will not only help to control disease transmission amongst staff but also prepare medics better for possible anticipation of complications. Since patients affected by SARS-CoV-2 can present with no or varying symptoms, it is logical to label or manage everyone as COVID-19 suspect until results are confirmed. It is becoming more obvious that many cases are pre-symptomatic or asymptomatic and the prevalence of myocardial injury in various populations is not yet known, as Troponin and ECGs are generally reserved for hospitalized patients.

Competing interests

The authors declare no competing interests.

Authors' contributions

All authors have significantly contributed to the case report, all authors have reviewed the case report prior to submission.

Figures

Figure 1: computed tomography of kidneys, ureters, and bladder revealed an obstructive left ureteric calculus at the vesicoureteric junction (VUJ) measuring 4.7 mm with no obvious fat stranding

Figure 2: ECG showing normal sinus rhythm with sinus tachycardia

Figure 3: ECG showing nonspecific ST changes and T wave inversion with no ST elevation

Figure 4: X-ray Chest showing bilateral patchy infiltrates, cardiomegaly, and unfolded aorta are seen

References

1. Libby P, Loscalzo J, Ridker PM, Farkouh ME, Hsue PY, Fuster V *et al.* Inflammation, Immunity, and Infection in Atherothrombosis: JACC Review Topic of the Week. *J Am Coll Cardiol.* 2018; 72(17): 2071-2081. [PubMed](#) | [Google Scholar](#)
2. Yang J, Zheng Y, Gou X, Pu K, Chen Z, Guo Q, Ji R *et al.* Prevalence of comorbidities and its effects in patients infected with SARS-CoV-2: a systematic review and meta-analysis. *Int J Infect Dis.* 2020;94: 91-95. [PubMed](#) | [Google Scholar](#)
3. Oudit GY, Kassiri Z, Jiang C, Liu PP, Poutanen SM, Penninger JM *et al.* SARS-coronavirus modulation of myocardial ACE2 expression and inflammation in patients with SARS. *Eur J Clin Invest.* 2009;39(7): 618-25. [PubMed](#) | [Google Scholar](#)
4. Mehta P, McAuley DF, Brown M, Sanchez E, Tattersall RS, Manson JJ *et al.* COVID-19: consider cytokine storm syndromes and immunosuppression. *Lancet.* 2020;395(10229): 1033-1034. [PubMed](#) | [Google Scholar](#)
5. Inciardi RM, Lupi L, Zaccone G, Italia L, Raffo M, Tomasoni D *et al.* Cardiac involvement in a patient with Coronavirus Disease 2019 (COVID-19). *JAMA Cardiol.* 2020 Mar 27. [PubMed](#) | [Google Scholar](#)

6. Chen C, Zhou Y, Wang DW. SARS-CoV-2: a potential novel etiology of fulminant myocarditis. *Herz*. 2020;45(3): 230-232. [PubMed](#) | [Google Scholar](#)
7. Chen C, Chen C, Yan JT, Zhou N, Zhao JP, Wang DW. Analysis of myocardial injury in patients with COVID-19 and association between concomitant cardiovascular diseases and severity of COVID-19. *Zhonghua Xin Xue Guan Bing Za Zhi*. 2020;48(0): E008. [PubMed](#) | [Google Scholar](#)

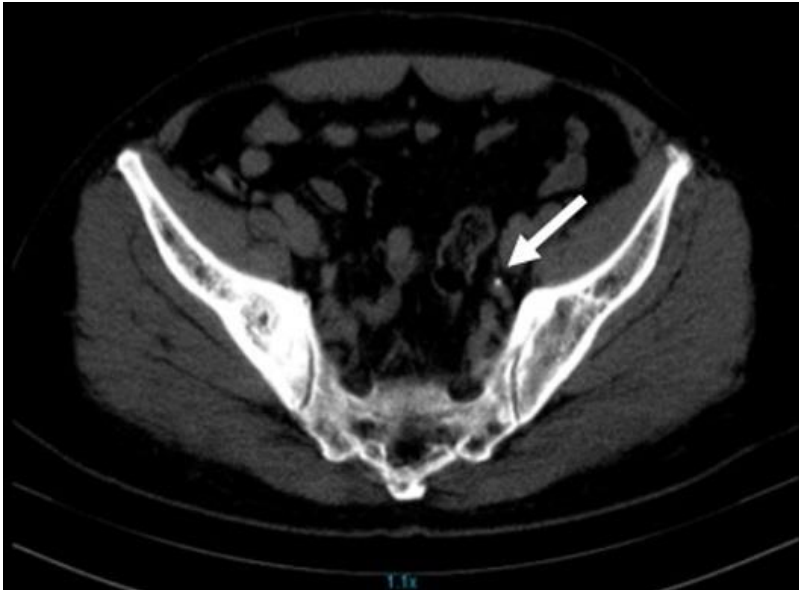

Figure 1: computed tomography of kidneys, ureters, and bladder revealed an obstructive left ureteric calculus at the vesicoureteric junction (VUJ) measuring 4.7 mm with no obvious fat stranding

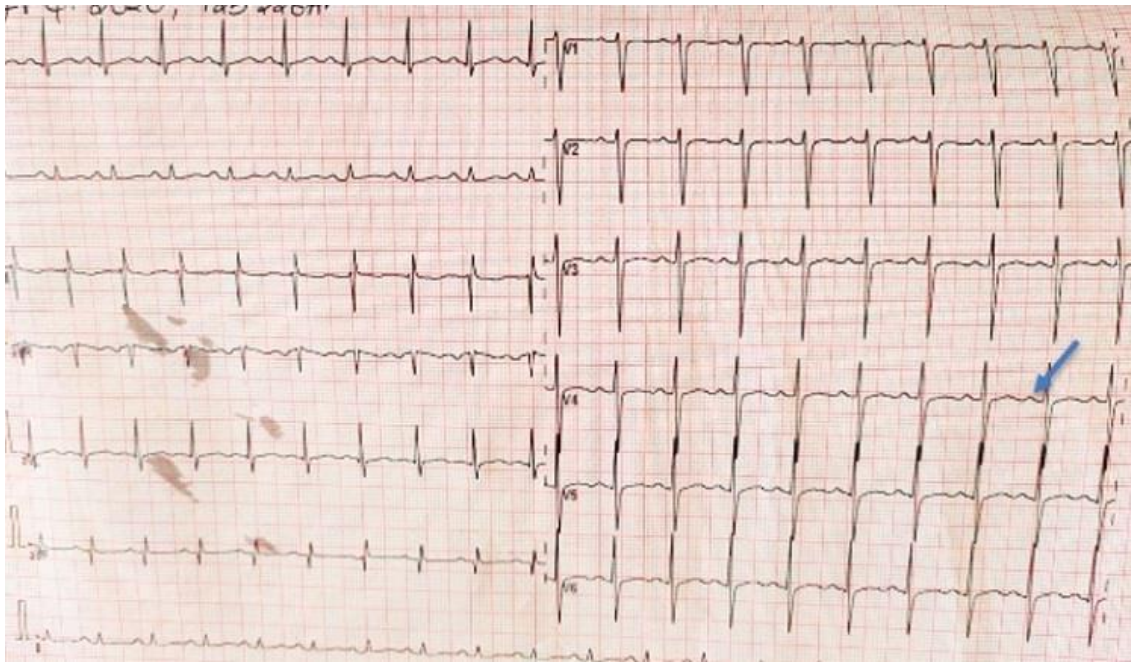


Figure 2: ECG showing normal sinus rhythm with sinus tachycardia

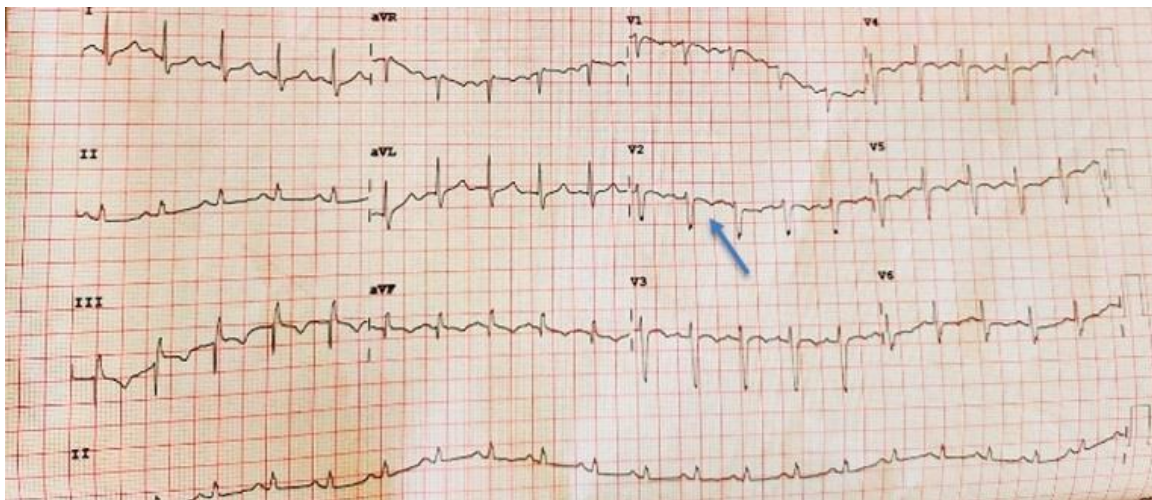


Figure 3: ECG showing nonspecific ST changes and T wave inversion with no ST elevation

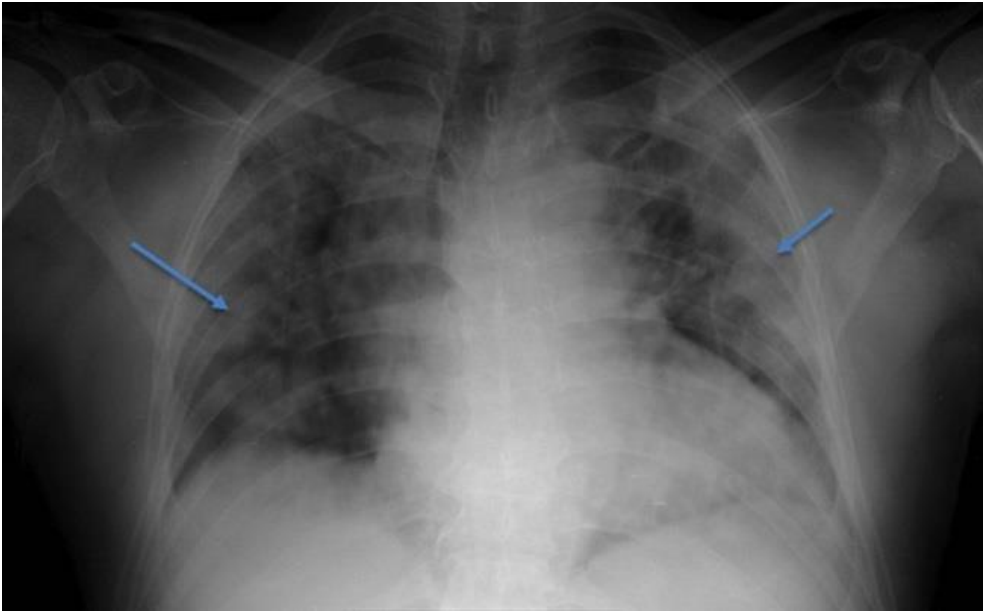


Figure 4: X-ray Chest showing bilateral patchy infiltrates, cardiomegaly, and unfolded aorta are seen