



PRELIMINARY REPORT

Morphometric analysis program: Detection of epileptic foci in young children using an adult normative database: Initial experience

Ximena Stecher^{1,2}  | Valeria Schonstedt¹ | Carla Manterola^{3,4}  | Fernando Carreño¹ | Francisco Zamorano^{1,2,5} | Alvaro Velasquez^{2,3,6} | Mauricio Castillo⁷

¹Radiology Department, Clínica Alemana de Santiago, Vitacura, Chile

²Facultad de Medicina, Clínica Alemana - Universidad del Desarrollo, Santiago, Chile

³Pediatric Department, Clínica Alemana de Santiago, Vitacura, Chile

⁴Facultad de Medicina, Universidad de Chile, Santiago, Chile

⁵Laboratorio de Neurociencia Social y Neuromodulación, Centro de Investigación en Complejidad Social (neuroCICS), Facultad de Gobierno, Universidad del Desarrollo, Santiago, Chile

⁶Chilean League against epilepsy, Santiago, Chile

⁷Department of Radiology, University of North Carolina, Chapel Hill, NC, USA

Correspondence

Ximena Stecher, Radiology Department, Clínica Alemana de Santiago, Av. Vitacura 5951, Vitacura, Santiago.

Email: xstecher@alemana.cl

Abstract

Objective: To report our initial experience using an adult-template MAP in drug-resistant focal epilepsy in five children with apparently normal MRI.

Methods: Patients selected were highly suspicious of harboring focal structural lesions and had negative brain MRI studies. MAP was performed using a locally obtained adult database as a template. Results were reviewed by two neuroradiologists. Pertinence of MAP-positive areas was confirmed by the focal epileptic hypothesis or by pathology when possible (*J Neuroradiol*, 39, 2012, 87). Visual analysis was performed using Mango Software. MRI studies were reanalyzed at the workstation with knowledge of the clinical suspicion to confirm or discard the possibility of FCD.

Results: Five patients aged 19-48 months were studied, all with initial 3T MRI studies interpreted as normal. All had focal epileptic hypothesis with coherence of clinical seizure characterization and electroencephalographic findings. In two patients, histology showed type 1 FCD. Due to the age of our subjects, the junction map always highlighted the subcortical white matter in relationship to maturity differences. FCD was identified as asymmetric U-shaped highlighted regions in the junction map.

Significance: FCD is the most frequent pathology reported in pediatric epilepsy surgery series (*Epileptic Disord*, 18, 2016, 240). Significant number of FCDs may be overlooked on MRIs, reducing the odds of seizure freedom after surgery (*Epilepsy Res*, 89, 2010, 310). MAP is an image postprocessing method for enhanced visualization of FCD; however, when using an adult template in developing brains, normal subcortical regions may be highlighted as pathological. Creating a pediatric template is difficult, due to the need for general anesthesia to acquire the MRI database. Here, we were able to show that MAP identified FCDs as asymmetric “U-” shaped highlighted regions in the junction maps of all five patients, which may indicate that obtaining childhood databases for this purpose may not be necessary and that adult ones suffice for diagnosis of FCD.

KEYWORDS

focal cortical dysplasia, MRI postprocessing, nonlesional, pediatric, refractory epilepsy

This is an open access article under the terms of the Creative Commons Attribution-NonCommercial-NoDerivs License, which permits use and distribution in any medium, provided the original work is properly cited, the use is non-commercial and no modifications or adaptations are made.

© 2020 The Authors. *Epilepsia Open* published by Wiley Periodicals LLC on behalf of International League Against Epilepsy

1 | INTRODUCTION

Focal cortical dysplasia (FCD) is the most common pathology underlying drug-resistant focal epilepsy in children.^{1,2} Magnetic resonance imaging (MRI) detection of FCD is fundamental for surgical planning and leads to better outcomes.^{3,4} Unfortunately, a significant number of FCDs may be overlooked by MRI.^{5–8} MAP is a voxel-based morphometric analysis program that quantifies interindividual variability on T1- and T2-weighted volumetric MRI. Wang et al recently published a study emphasizing the importance of MAP in presurgical evaluation of drug-resistant focal epilepsy in children with apparently normal MRI using an age-specific template created with controls as young as 3 years of age.⁹ Creating templates for children is challenging because they need images from neurologically asymptomatic children which require general anesthesia. Here, we report our initial experience using an adult template in 5 children with epilepsy.

2 | MATERIALS AND METHODS

We report 5 patients under 5 years of age presented to our Multidisciplinary Epilepsy Group. This retrospective study was exempt from IRB review which limits our ability to add individual patient data to this report. Patients were selected as they were highly suspicious of harboring focal structural lesions and had negative brain MRI studies. MAP was performed using a locally obtained adult database as a template.

MAP software compares T1 MPRAGE sequences of every patient with our local template of normality, elaborated based on 50 volunteers of both genders between 18 and 50 years of age, asymptomatic and without a known neurological pathology. The T1 sequence used for the template generation was acquired in a Siemens Skyra 3T scanner (Erlangen, Germany), with 20 channels coil, TR 2520, TE 2.19, TI of 1100, matrix and Field of view (FOV) of 256 × 256, slice thickness of 1 × 1 × 1 mm, sagittal acquisition.

Results were reviewed by two neuroradiologists with a total of 15 years of experience. The pertinence of MAP-positive areas was confirmed by the focal epileptic hypothesis as described by Doelken et al or by pathology when possible.¹⁰ Visual analysis was performed using Mango Software (<http://ric.uthscsa.edu/mango/>). The *z*-score used was previously established, and those areas that exceed recognized limits were highlighted and considered as MAP positive.² MRI studies were reanalyzed at the workstation using all sequences and tools available in everyday practice and with knowledge of the clinical suspicion to confirm or discard the possibility of FCD.

Key Points

- FCD is the most frequent category of pathology reported in pediatric epilepsy surgery series
- A significant number of FCD may be overlooked on MRI reducing the odds of seizure freedom after surgery
- MAP is a postprocessing method for enhanced visualization of FCD
- Creating a pediatric template is challenging due to the need for general anesthesia for the acquisition of the MRI database
- MAP identified FCDs as asymmetric “U-” shaped highlighted regions in the junction maps of all 5 patients using an adult template

3 | RESULTS

Five patients aged 19–48 months were studied. All had focal epileptic hypothesis with coherence of clinical seizure characterization and electroencephalographic findings. Two patients who underwent surgery with intraoperative electrocorticography and histology showed type 1 focal cortical dysplasia.

The patient's initial 3T MRI studies were interpreted as nonlesional. Due to high clinical suspicion of structural lesions, MAP was used to enhance the probability of lesion identification. A locally constructed adult template was used. Due to the age of our subjects, the junction map always highlighted the normally nonmyelinated subcortical white matter and perivascular spaces in relationship to maturity differences. FCD was identified as asymmetric U-shaped highlighted regions in the junction map. Examples of MRI and postprocessed MAP are shown in Figure 1.

4 | DISCUSSION

Our purpose is to describe the use of MAP with an adult template for the detection of FCDs in patients under 5 years of age with refractory epilepsy and nonlesional MRI. Pediatric MAP postprocessing utility is generally limited due to the absence of age-adjusted templates and pitfalls encountered when using adult templates. When using adult templates in young children, differences in structural maturation and myelination will be labeled as false-positive areas (Table 1).

MAP in children under 5 years of age has been generally dismissed due to the lack of age-related templates. Even though the main differences in myelination occur in

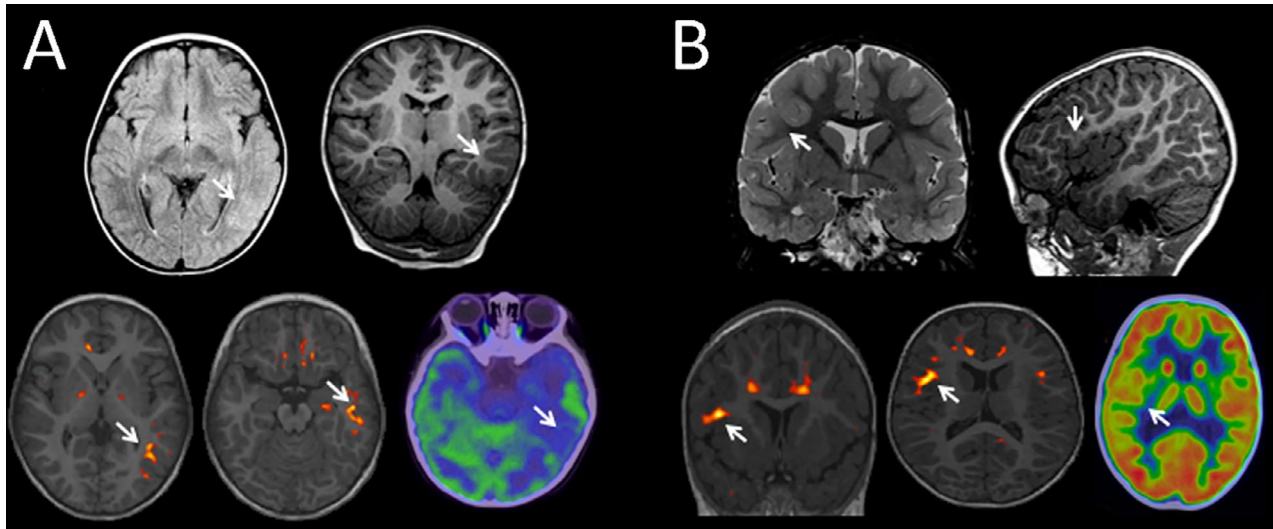


FIGURE 1 MRI and MAP images in two patients with focal epilepsy, younger than 36 months. Patient A: Top row shows axial FLAIR coronal T1 images interpreted as normal although retrospectively there is abnormal subtle high signal in FLAIR and hypointensity of the subcortical white matter in T1 (arrows). The bottom row shows MAP postprocessing demonstrating subcortical highlighted areas in the junction map and an asymmetric lesion (arrows) in the temporo-occipital parenchyma corresponding to the abnormal finding on FLAIR. PET-CT shows expected hypometabolism in the same area. Patient B: Top row shows coronal T2 sagittal T1 images interpreted as normal although retrospectively there is abnormal subtle high signal in T2 and hypointensity of the subcortical white matter in T1 (arrows). Bottom shows the junction map of MAP demonstrating an asymmetry (arrow) in the right frontal lobe. PET-CT shows hypometabolism in a more extensive area

TABLE 1 Focal epileptic hypothesis based on clinical seizure characterization, electroencephalographic findings, surgical treatment, pathology when available, and reanalyzed MRI and PET results

Case	Focal epileptic site	Surgery	Pathology	MRI (reanalyzed)	PET-CT
1	Left temporo-occipital and occipital	(-)		Blurring of the left temporo-occipital cortical-subcortical junction	Extensive left temporo-occipital hypometabolism with a hypermetabolic area, consistent with ictal electric activity
2	Right frontal	(+)	FCD type I	Right frontal cortical-subcortical blurring, cortical thickening, and alteration of the T2 / FLAIR signal	
3	Right frontal	(-)		Right frontal cortex-subcortical blurring, and alteration of the T2 / FLAIR signal	Right frontal hypometabolism in a more extensive area
4	Left occipital	(-)		Left temporo-occipital cortical-subcortical blurring	
5	Right parietal	(+)	FCD type I	Extensive right mesial parieto-occipital cortical-subcortical blurring	Right parieto-occipital hypometabolism

children under 40 months¹¹, in our series there was a difference in the subcortical signal attributable to what we believe is a normal lack of myelination and/or the presence of enlarged perivascular spaces in all the patients. These regions will be symmetrically highlighted when using MAP with an adult template, a pattern which will be recognized as normal if an expert interprets the studies. A FCD may be recognized as a “U-” shaped asymmetrical highlighted

region, which must be interpreted together with the structural MRI.

Our initial experience suggests that using adult templates for MAP postprocessed images may be useful to the identification of FCD in pediatric patients if normal differences caused by maturation and myelination are correctly identified. MAP may contribute to the workup of children with refractory epilepsy and result in relevant changes in treatment and outcome.

Our promising results need to be confirmed with larger patient cohorts. Although only 2 of our patients have histologic proof of lesions, clinical seizure semiology and/or PET-CT findings borne the MRI and MAP findings in the others. We need to stress that MAP findings need to be confirmed with anatomical imaging preferably obtained with 3T MRI units. We think that the use of MAP also has a learning curve but ultimately it enhances our ability to detect FCD in morphological sequences.

In conclusion, MAP using an adult-based template allow us to identify FCD in 5 children. These early observations may indicate that obtaining childhood databases for this purpose may not be necessary and that adult ones suffice for diagnosis of FCD.

CONFLICT OF INTEREST

None of the authors have any conflict of interest to disclose. The work described is consistent with the Journal's guidelines of ethical publication. We confirm that we have read the Journal's position on issues involved in ethical publication and affirm that this report is consistent with those guidelines.

ORCID

Ximena Stecher  <https://orcid.org/0000-0002-7962-9519>

Carla Manterola  <https://orcid.org/0000-0003-3394-1010>

REFERENCES

- Holthausen H, Blümcke I. Epilepsy- associated tumours: what epileptologists should know about neuropathology, terminology, and classification system. *Epileptic Disord.* 2016;18(3):240–51.
- Wang ZI, Alexopoulos AV, Jones SE, Najm IM, Ristic A, Wong C, et al. Linking MRI postprocessing with magnetic source imaging in MRI-negative epilepsy. *Ann Neurol.* 2014;75:759–70.
- Téllez-Zenteno J, Hernandez L, Moien-Afshari F, Wiebe S. Surgical outcomes in lesional and non-lesional epilepsy: a systematic review and meta-analysis. *Epilepsy Res.* 2010;89(2–3):310–8.
- Guerrini R, Duchowny M, Jayakar P, Krsek P, Kahane P, Tassi L, et al. Diagnostic methods and treatment options for focal cortical dysplasia. *Epilepsia.* 2015;56(11):1669–86.
- Salamon N, Kung J, Shaw SJ, Koo J, Koh S, Wu JY, et al. FDG-PET/MRI coregistration improves detection of cortical dysplasia in patients with epilepsy. *Neurology.* 2008;71(20):1594–601.
- Funke ME, Moore K, Orrison WW Jr, Lewine JD. The role of magnetoencephalography in “nonlesional” epilepsy. *Epilepsia.* 2011;52:10–4.
- Itabashi H, Jin K, Iwasaki M, Okumura E, Kanno A, Kato K, et al. Electro- and magneto- encephalographic spike source localization of small focal cortical dysplasia in the dorsal peri-rolandic region. *Clin Neurophysiol.* 2014;125:2358–63.
- Radhakrishnan R, Leach JL, Mangano FT, Gelfand MJ, Rozhkov L, Miles L, et al. Prospective detection of cortical dysplasia on clinical MRI in pediatric intractable epilepsy. *Pediatr Radiol.* 2016;46(10):1430–8.
- Wang W, Lin Y, Wang S, Jones S, Prayson R, Moosa ANV, et al. Voxel-based morphometric magnetic resonance imaging postprocessing in non-lesional pediatric epilepsy patients using pediatric normal databases. *Eur J Neurol.* 2019;26(7):969–e71.
- Doelken MT, Mennecke A, Huppertz HJ, Rampp S, Lukacs E, Kasper BS, et al. Multimodality approach in cryptogenic epilepsy with focus on morphometric 3T MRI. *J Neuroradiol.* 2012;39(2):87–96.
- Parazzini C, Baldoli C, Scotti G, Triulzi F. Terminal zones of myelination: MR evaluation of children aged 20–40 months. *AJNR Am J Neuroradiol.* 2002;23(10):1669–73.

How to cite this article: Stecher X, Schonstedt V, Manterola C, et al. Morphometric analysis program: Detection of epileptic foci in young children using an adult normative database: Initial experience. *Epilepsia Open.* 2021;6:235–238. <https://doi.org/10.1002/epi4.12456>