

Case Report

---

# Expanding the Spectrum of Alkali Retinopathy: Maculopathy following Alkali Burn

Andreas Vanclooster   Julie De Zaeytijd   Dimitri Roels

Department of Ophthalmology, Ghent University Hospital, Ghent, Belgium

## Keywords

Alkali burn · Retinopathy · Cornea

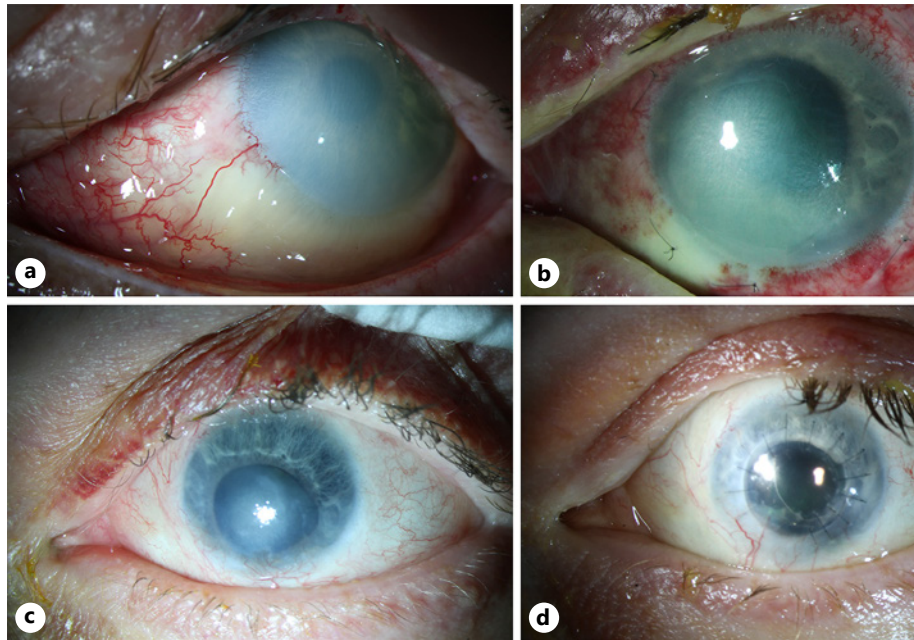
## Abstract

Ocular alkali burns are known to cause profound damage to the anterior segment, especially the cornea and conjunctiva. However, rarely, additional adjacent chorioretinal complications may ensue. These chorioretinal complications appear primary by direct penetration of the alkali or secondary to an elevated intraocular pressure (IOP). In contrast to this, recent animal studies have suggested a causal link with upregulation of proinflammatory mediators. We present a patient with maculopathy following alkali ocular burn.

© 2022 The Author(s).  
Published by S. Karger AG, Basel

## Introduction

Approximately 10% of all ocular injuries result from chemical burn [1]. In general, the most severe chemical injuries occur with alkaline solutions. Alkali damages the corneal epithelium by saponification of fatty acids in cell membranes and cellular disruption. Penetration into the stroma destroys the proteoglycan ground substance and collagen fibers. Strong alkaline substances may even penetrate through the endothelium into the anterior chamber (AC), further damaging the trabecular meshwork [2]. Most studies concentrated on investigating the effects of chemical injuries on the anterior segment. In contrast, posterior segment complications have been rarely investigated, partly because of poor intraocular structure visualization. Since 1976, only a few cases of chemically burned eyes have been described in which damage to the retina and optic nerve was revealed after corneal transplantation [3]. Multiple mechanisms



**Fig. 1.** Anterior segment photography. **a** Left eye at presentation. Note the limbal blanching and corneal and conjunctival epithelium defect with stromal opacification. **b** Left eye after amniotic membrane overlay. Note the persistent corneal epithelial defect and inferior scleral blanching. **c** Left eye after 6 months. Note the corneal stromal scar and inferior iris atrophy with anterior synechiae formation. **d** Left eye 6 months after penetrating keratoplasty, synechiolysis, extracapsular cataract extraction, and IOL implantation. Note the clear corneal graft and IOL.

have been postulated; some of them include a role of the intraocular pressure (IOP) because of typical IOP-induced optic disc changes [1, 4, 5]. Others suggest a direct pH-related alkali diffusion from the AC to the back of the eye, leading to cell toxicity and retinal damage [3, 6]. In recent mouse and rabbit studies, a mechanism in which retinal damage was caused by upregulation and diffusion of inflammatory cytokines, especially tumor necrosis factor alpha (TNF- $\alpha$ ), from the site of the injury to the posterior segment was suggested [1, 4, 7–9]. We present a case of maculopathy following alkali ocular burn, resulting in permanent vision loss despite near complete reconstruction of the anterior segment.

### Case Report/Case Presentation

A 46-year-old man was referred because of an alkali ocular burn with sodium hydroxide in both eyes. Ocular history was negative. Immediate diphtherine application followed by flushing with physiological saline solution for 40 min in the emergency department reduced the pH from 8 to 7.5. The best-corrected visual acuity (BCVA) was 0.5 in the right eye and 0.4 in the left eye. Slit-lamp examination showed a nearly complete corneal epithelial defect with stromal opacification in the left eye. Limbal blanching was present in two clock hours, adjacent to an inferior conjunctival defect (Fig. 1a). Both the AC and IOP were unremarkable. Corneal opacification precluded emergent detailed posterior segment investigation. Damage in the right eye was limited to a corneal epithelial defect. The patient was diagnosed with an alkali ocular burn Roper-Hall grade 1 in the right eye and grade 3 in the left eye. According to the Dua classification, a grade 1 right and a grade 3 left are diagnosed.

He was admitted for immediate intensive treatment with topical antibiotics (chloramphenicol drops and ofloxacin ointment), topical dexamethasone, topical vitamin C, autologous serum 20% eye drops, topical atropine 1%, and oral doxycycline and oral vitamin C. The BCVA in the left eye declined to 0.1 after 2 days. The IOP remained within normal limits.

The corneal epithelial erosion in the right eye healed after 5 days with rapid restoration of BCVA to 1.0. In the absence of clinical improvement after 3 days of topical treatment, the patient underwent amniotic membrane transplantation in the left eye. Four days postoperatively, the amniotic membrane dissolved with a reduction of the corneal epithelial defect. However, BCVA declined to hand motions. Over the course of 1 month, the corneal epithelial defect slowly regressed, yet the inferior conjunctival defect and avascular sclera remained (Fig. 1b). BCVA further declined to light perception with localization. A tenonplasty combined with a second amniotic membrane overlay was performed to facilitate corneal and conjunctival reepithelialization. After 3 months, the corneal epithelial defect was completely closed. IOP measured at every follow-up visit always remained unremarkable. The oral medication and topical antibiotics were stopped, and the autologous serum drops were switched to preservative-free artificial tears.

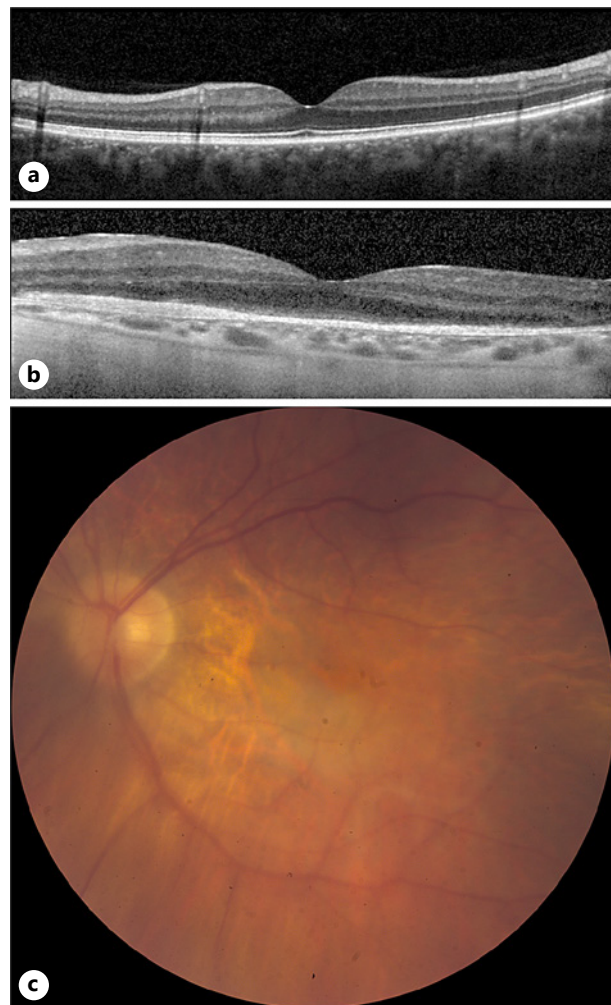
A steady-state examination of the left eye after 6 months showed an inferior 2/3rd corneal scar with an intact but irregular corneal epithelium, inferior limbal neovascularization, inferior peripheral anterior synechiae, and a white intumescent cataract (Fig. 1c). The IOP was 19 mm Hg. BCVA remained limited to light localization. Corneal scarring still precluded a funduscopy. Ultrasound examination confirmed the vitreous cavity to be unremarkable without any signs of vitreous inflammation and the retina attached.

A penetrating keratoplasty with extracapsular cataract extraction, synechiolysis, IOL implantation, and perilimbal injection of bevacizumab was performed 15 months after the trauma. Postoperatively topical dexamethasone and ofloxacin drops were combined with oral prednisone and mycophenolate mofetil. Two weeks postoperatively, an amniotic membrane overlay was performed because of a persisting epithelial defect of the inferior graft-host interface.

Three months postoperatively, BCVA only improved to counting fingers despite a functional clear corneal graft. Funduscopy showed an unremarkable vitreous and optic disc with a physiological cup-disc ratio. However, an area of retinal atrophy was visible in the macular region, extending to the inferonasal part of the posterior pole, with an apparently normal peripheral retina (Fig. 2a). A spectral macular OCT revealed intact inner retinal layers with peripapillary atrophy and foveal subretinal fibrosis (Fig. 2c). OCT of the optic disc showed a normal retinal nerve fiber layer. OCT of the fellow eye was completely normal (Fig. 2b). A diagnosis of suspected alkali retinopathy in the macular region was made, explaining the persistent visual loss. A follow-up 6 months after penetrating keratoplasty showed a clear corneal graft (Fig. 1d). One year after surgery, OCT showed no progression of the macular atrophy and scarring. Fluorescein angiography was performed, which showed no major window defects in the midperiphery, although visualization was limited due to peripheral corneal opacity.

## Discussion/Conclusion

Alkali ocular burns are known to cause profound damage to the anterior segment but may rarely also result in damage to the retina or the optic nerve. The focus is (initially) mainly on the anterior segment as corneal opacification precludes a detailed posterior segment examination. Only a few cases of alkali retinopathy have been described [3, 6]. Several mechanisms have been suggested for posterior segment damage and persistent visual loss following alkali ocular burn.



**Fig. 2.** **a** Macular OCT of the right eye with normal retinal layering. **b** Macular OCT of the left eye 10 months after penetrating keratoplasty. Note the zone of photoreceptor atrophy and subretinal fibrosis in the posterior pole. **c** Fundus photography of the left eye 20 months after trauma, 6 months after penetrating keratoplasty. Note the zone of retinal atrophy in the posterior pole and the physiological optic nerve cup-disc ratio.

First, intraocular pressure problems have been put forward in the development of an optic neuropathy in humans with alkali corneal burns. Peripheral corneal inflammation may contribute to angle closure and subsequent intraocular pressure elevation [1, 4]. This was confirmed by Cade et al. [5], who noted glaucomatous damage with an enlarged cup-disc ratio in patients with corneal alkali burns after a Boston keratoprosthesis was implanted. After chemical burn of the anterior segment and following corneal transplantation, high doses of topical corticosteroids for a longer period are administered, increasing the risk of glaucomatous damage. In our patient, intraocular pressure was measured at every follow-up visit and remained unremarkable. Upon posterior segment evaluation, no glaucomatous optic disc changes have been noted. Optic neuropathy was excluded in our patient.

Second, a direct penetration of the alkalic component through the sclera to involve both the choroid and the retina is suggested by the sharp localization of the retinopathy just internal to the obvious external burn in 3 previous reported patients with alkali retinopathy. In these patients, ocular penetration induced an ischemic necrosis not only of the conjunctiva and sclera but also of the choroid and retina [3, 6]. Remarkably, in our patient, retinal damage was limited to the macular region, extending to the inferonasal part of the posterior pole. This localization excludes a direct penetration effect.

Third, experimental mice and rabbit studies showed an upregulation of multiple inflammatory cytokines as an alternative mechanism for alkali retinopathy, applicable in patients

where the retinopathy cannot be explained solely by direct damage or IOP rise [7–11]. It was shown that a chemical burn of the anterior segment leads to an immune reaction with upregulation of cytokines in the AC. These cytokines rapidly diffuse posteriorly to the retina and cause infiltration of immune cells with activation of apoptotic signals such as caspase 3 and endonuclease G, resulting in cell apoptosis and optic nerve degeneration [8, 9]. In 1998, this mechanism was first suggested in a mice study in which the concentrations of inflammatory cytokines (IL-1 $\alpha$ , IL-1 $\beta$ , and IL-6) were measured after a corneal alkali burn. A significant elevation of IL-1 $\beta$  and IL-6 in the sensory retina was reported [10–12]. More recently, other rodent experimental studies confirmed this theory [8]. In these mice, two chronologically distinct pathways of TNF- $\alpha$  release have been shown. Within 24 h of the burn, peripheral CD45+ monocytes infiltrate the retina from the optic nerve, and they become activated and promote TNF- $\alpha$  synthesis. Second, patrolling myeloid cells of the retina differentiate into macrophages hours after the burn, which reactivate microglia 7 days after the burn [8]. Several animal studies have suggested a role of these inflammatory cytokines in photoreceptor death unrelated to an alkali burn. In a mice study, it was demonstrated that TNF- $\alpha$  upregulation after retinal detachment plays a critical role in photoreceptor degeneration. TNF- $\alpha$  has a neurotoxic effect on photoreceptors, also leading to monocyte recruitment and monocyte-generated oxidative stress. It was shown that the inhibition of TNF- $\alpha$  inhibition suppressed the retinal infiltration of macrophages and microglial cells, which leads to an increase in photoreceptor cell survival in mice after retinal detachment [13]. This is supported by a study in rabbits where a subconjunctival drug delivery system with sustained delivery of infliximab was implanted minutes after a chemical burn showed improved corneal wound healing and retinal neuroprotection [7]. Adalimumab has also been effective in retinal ganglion cell protection [8, 9].

In our patient, fundoscopy and OCT identified photoreceptor atrophy and subretinal fibrosis in the posterior pole. The hypothesis of alkali retinopathy induced by upregulation and posterior diffusion of proinflammatory cytokines, based on animal models, could be a valuable explanation. To our knowledge, this is the first case illustrating this hypothesis in humans. It is important to be aware of the risk of maculopathy following alkali ocular burn, since definite vision loss despite successful anterior segment surgery is extremely frustrating for patients and surgeons. When included in the preoperative counseling of the patient, realistic expectations concerning postoperative visual recovery can be set. Future efforts to elucidate the exact underlying pathophysiological mechanism may guide toward early anti-inflammatory treatments to prevent posterior segment complications and definite visual loss.

## Statement of Ethics

The patient has given his written informed consent to publish this case and the images. This study protocol was reviewed and approved by the Ethical Commission, University Hospital Gent, with approval number EC/111-2021/sds.

## Conflict of Interest Statement

The authors have no conflicts of interest to declare.

## Funding Sources

There is no financial conflict.

## Author Contributions

Andreas Vanclooster has written the first draft of the article with interpretation of the literature and the case report. In cooperation with Dr. Dimitri Roels and Dr. Julie De Zaeytijd, he has approved the final version. He is accountable for all aspects of the work. Julie De Zaeytijd has contributed in the design, analysis, and interpretation of the case report, specifically the retinal part of the work. She has revised the work critically and approved the final version. She is accountable for all aspects of the work. Dimitri Roels has contributed in the design, analysis, and interpretation of the case report, specifically the anterior segment part of the work. He has revised the work critically and approved the final version. She is accountable for all aspects of the work.

## Data Availability Statement

In this case report, the data are not publicly available due to privacy reasons. All data generated or analyzed during this study are included in this article. Further inquiries can be directed to the corresponding author.

## References

- 1 Chen X, Lei F, Zhou C, Chodosh J, Wang L, Huang Y, et al. Glaucoma after ocular surgery or trauma: the role of infiltrating monocytes and their response to cytokine inhibitors. *Am J Pathol*. 2020;190(10):2056–66.
- 2 Bunker DJL, George RJ, Kleinschmidt A, Kumar RJ, Maitz P. Alkali-related ocular burns: a case series and review. *J Burn Care Res*. 2014;35(3):261–8.
- 3 Smith RE, Conway B. Alkali retinopathy. *Arch Ophthalmol*. 1976;94(1):81–4.
- 4 Paschalis EI, Zhou C, Lei F, Scott N, Kapoulea V, Robert MC, et al. Mechanisms of retinal damage after ocular alkali burns. *Am J Pathol*. 2017 Jun;187(6):1327–42.
- 5 Cade F, Grosskreutz CL, Tauber A, Dohlman CH. Glaucoma in eyes with severe chemical burn, before and after keratoprosthesis. *Cornea*. 2011 Dec;30(12):1322–7.
- 6 Houghton OM, Iezzi R. Indocyanine green angiographic features in a case of alkali retinopathy. *Retin Cases Brief Rep*. 2009 Fall;3(4):403–6.
- 7 Zhou C, Robert MC, Kapoulea V, Lei F, Stagner AM, Jakobiec FA, et al. Sustained subconjunctival delivery of infliximab protects the cornea and retina following alkali burn to the eye. *Invest Ophthalmol Vis Sci*. 2017 Jan 1;58(1):96–105.
- 8 Paschalis EI, Lei F, Zhou C, Kapoulea V, Thanos A, Dana R, et al. The role of microglia and peripheral monocytes in retinal damage after corneal chemical injury. *Am J Pathol*. 2018 Jul;188(7):1580–96.
- 9 Cade F, Paschalis EI, Regatieri CV, Vavvas DG, Dana R, Dohlman CH. Alkali burn to the eye: protection using TNF- $\alpha$  inhibition. *Cornea*. 2014 Apr;33(4):382–9.
- 10 Kim SU, de Vellis J. Microglia in health and disease. *J Neurosci Res*. 2005 Aug;81(3):302–13.
- 11 Nakazawa T, Kayama M, Ryu M, Kunikata H, Watanabe R, Yasuda M, et al. Tumor necrosis factor- $\alpha$  mediates photoreceptor death in a rodent model of retinal detachment. *Invest Ophthalmol Vis Sci*. 2011 Mar 14;52(3):1384–91.
- 12 Miyamoto F, Sotozono C, Ikeda T, Kinoshita S. Retinal cytokine response in mouse alkali-burned eye. *Ophthalmic Res*. 1998;30(3):168–71.
- 13 Sotozono C, He J, Tei M, Honma Y, Kinoshita S. Effect of metalloproteinase inhibitor on corneal cytokine expression after alkali injury. *Invest Ophthalmol Vis Sci*. 1999 Sep;40(10):2430–4.