

## A method for semi-automated image analysis of HLA class I tumour epithelium expression in rectal cancer

Daniëlle Krijgsman,  
 Ronald L.P. van Vlierberghe, Vaios  
 Evangelou, Alexander L. Vahrmeijer,  
 Cornelis J.H. van de Velde,  
 Cornelis F.M. Sier, Peter J.K. Kuppen  
 Department of Surgery, Leiden  
 University Medical Centre, Leiden,  
 The Netherlands

### Abstract

Biomarkers may hold the key towards development and improvement of personalized cancer treatment. For instance, tumour expression of immune system-related proteins may reveal the tumour immune status and, accordingly, determine choice for type of immunotherapy. Therefore, objective evaluation of tumour biomarker expression is needed but often challenging. For instance, human leukocyte antigen (HLA) class I tumour epithelium expression is cumbersome to quantify by eye due to its presence on both tumour epithelial cells and tumour stromal cells, as well as tumour-infiltrating immune cells. In this study, we solved this problem by setting up an immunohistochemical (IHC) double staining using a tissue microarray (TMA) of rectal tumours wherein HLA class I expression was coloured with a blue chromogen, whereas non-epithelial tissue was visualized with a brown chromogen. We subsequently developed a semi-automated image analysis method that identified tumour epithelium as well as the percentage of HLA class I-positive tumour epithelium. Using this technique, we compared HCA2/HC10 and EMR8-5 antibodies for the assessment of HLA class I tumour expression and concluded that EMR8-5 is the superior antibody for this purpose. This IHC double staining can in principle be used for scoring of any biomarker expressed by tumour epithelium.

### Introduction

Tissue biomarkers have a variety of applications and their use in the field of oncology is widespread. Immunohistochemistry (IHC) is used worldwide regarding morphological and pathological evaluation of tumour biomarkers, but several limitations and difficulties have been report-

ed.<sup>1,2</sup> The evaluation of IHC staining of tumour tissue sections usually relies on visual microscopic inspection, manual annotation procedures, and inter-observer agreement. This method is prone to subjective criteria and will always be qualitative rather than quantitative. In our opinion, computer-assisted image analysis is crucial for determination of oncological biomarkers to acquire quantitative, objective and reproducible data, especially for large cohorts as used in tissue microarrays (TMAs).

In this study, human leukocyte antigen (HLA) class I was chosen as tissue biomarker of interest for semi-automated analysis on a TMA of rectal cancer. *Via* presentation of tumour-associated antigens by HLA class I molecules, tumour cells can be recognized and killed by cytotoxic T cells. HLA molecules, therefore, play an important role in anti-tumour immune responses. Several cancer types, including rectal cancer, have been reported to downregulate HLA class I expression,<sup>3-5</sup> which might lead to tumour escape from T cells. Studies showed that the degree of HLA class I expression on tumour cells contains important information regarding clinical outcome of patients for various cancer types.<sup>3-11</sup> Therefore, tumour HLA class I expression evaluation may be important for clinical cancer prognosis, but may also be included in the choice of immunotherapy for specific cancer patients. Unfortunately, HLA class I expression is cumbersome to quantify by eye on tumour epithelium, specifically due to its high heterogeneity in expression pattern and its presence on both tumour epithelial cells and tumour stromal cells, as well as tumour-infiltrating immune cells. Additionally, the evaluation of HLA class I expression is complicated due to the widespread use of antibodies that only recognize a selection of HLA class I A, B, and C alleles, such as HCA2 and HC10.<sup>12-14</sup> These two antibodies are often combined to study HLA class I expression in order to cover the detection of as many different HLA class I alleles as possible.<sup>4-6,15</sup> Unfortunately, HCA2 cross-reacts with non-classical HLA class I molecules HLA-E, HLA-F, and HLA-G,<sup>12, 13</sup> thereby possibly leading to overestimation of the total HLA class I tumour expression. The introduction of a novel monoclonal antibody, EMR8-5, recognizing, and only recognizing, HLA class I A, B, and C alleles,<sup>16</sup> may circumvent undetected reactivity and unwanted cross reactivity. In conclusion, HLA class I is a difficult and therefore particularly suited tissue biomarker for setting up semi-automated analysis.

In order to solve the problem of discriminating between tumour epithelium and

Correspondence: Dr. Peter J.K. Kuppen,  
 Leiden University Medical Centre,  
 Albinusdreef 2, 2300 RC, Leiden, The  
 Netherlands.  
 Tel: +31.71.526 4005.  
 E-mail: p.j.k.kuppen@lumc.nl

Keywords: Automated image analysis; MHC class I; tumour epithelium; digital pathology; biomarkers; cross-reactivity.

Acknowledgements: We thank Geeske N.G. Dekker-Ensink for technical support.

Contributions: DK, RLPvV, VE, CFMS, PJKK, study concept; DK, original manuscript drafting, microscopical examination, data curation; DK, RLPvV, formal analysis; DK, RLPvV, VE, investigation, methodology; CJHvdV, PJKK, resources; RLPvV, software applications; DK, PJKK, project administration; ALV, CJHvdV, PJKK, study supervision; DK, RLPvV, study validation; CFMS, PJKK, funding acquisition. All authors contributed to the manuscript review and editing and approved the final version to be published.

Conflict of interest: the authors declare no conflict of interest.

Received for publication: 22 March 2019.

Accepted for publication: 20 April 2019.

This work is licensed under a Creative Commons Attribution-NonCommercial 4.0 International License (CC BY-NC 4.0).

©Copyright D. Krijgsman et al., 2019  
 Licensee PAGEPress, Italy  
 European Journal of Histochemistry 2019; 63:3028  
 doi:10.4081/ejh.2019.3028

non-epithelial tissue, we developed a double staining wherein HLA class I was visualized with a blue chromogen, whereas all non-epithelial tissue, *i.e.* stromal cells, blood vessels, and immune cells, was coloured with a brown chromogen. Using a negative selection method, tumour epithelium could automatically be selected by excluding all brown-stained non-epithelial tissue. With this method we scored HLA class I expression in tumour epithelium in a TMA of primary tumours from rectal cancer patients. Next, we investigated whether EMR8-5 better detects HLA class I expression in tumour epithelium in rectal cancer than the combined HCA2/HC10 antibodies.

### Materials and Methods

#### Study population

The study population consisted of 495 patients diagnosed with rectal cancer included in the Dutch total mesorectal exci-

sion (TME) trial (January 12<sup>th</sup>, 1996, DUT-KWF-CKVO-9504, EORTC-40971, EU-96020) who underwent TME surgery without pre-operative radiotherapy.<sup>7</sup> All patients included in the TME trial gave written informed consent for participation and retrospective use of samples gathered during the trial. A TMA was produced as described in the study by Reimers *et al.*,<sup>5</sup> and used in this study. Tissue sections (4 µm) of the TMA blocks were cut following a standard procedure and transferred onto glass slides using tape.

### Antibodies

The mouse monoclonal antibodies HCA2 and HC10 were used, which were kindly provided by Prof. Dr. J. Neefjes (Leiden University Medical Centre, Leiden, The Netherlands). HCA2 recognizes the heavy chains of all HLA-A molecules except HLA-A24, as well as some HLA-B, HLA-C, HLA-E, HLA-F, and HLA-G heavy chains.<sup>12,13</sup> HC10 is known to react with HLA-B and HLA-C heavy chains and with some alleles of HLA-A heavy chains (HLA-A\*10, A\*28, A\*29, A\*30, A\*31, A\*32, and A\*33).<sup>14</sup> Furthermore, the mouse monoclonal antibody EMR8-5 (ab70328, AbCam, Cambridge, UK) was used, which is reported to be an anti-pan classical HLA class I antibody, recognizing HLA-A, -B, and -C alleles.<sup>16</sup> It has been shown to strongly react with the extracellular domains that were tested (*i.e.* HLA-A\*2402, A\*0101, A\*1101, A\*0201, A\*0207, B\*0702, B\*0801, B\*1501, B\*3501, B\*4001, B\*4002, B\*4006, B\*4403, Cw\*0102, Cw\*0801, Cw\*1202, and Cw\*1502).<sup>16</sup> Additionally, a mix of rabbit polyclonal antibodies targeting collagen I, collagen VI, and elastin (ab34710, ab6588, and ab23747 respectively, all from AbCam) was used in order to stain extracellular matrix (ECM), to stain stromal tissue and blood vessels in tumour tissue. A rabbit monoclonal anti-CD45 antibody (ab40763, AbCam) was included to target tumour-infiltrating immune cells. For each antibody, the dilution to obtain optimal staining was determined.

### Immunohistochemistry

An IHC double staining was set up wherein HLA expression was visualized with blue chromogen, whereas tumour stromal tissue, blood vessels, and tumour-infiltrating immune cells were coloured with brown chromogen. Briefly, 4 µm thick TMA sections were deparaffinised and rehydrated followed by heat-mediated antigen retrieval in Envision™ FLEX target retrieval solution low pH (DAKO, Glostrup, Denmark) using a PT Link module (DAKO). Endogenous peroxidase and

phosphatase activity were blocked for 10 min with BloxAll solution (Vector Laboratories, Burlingame, CA, USA). Two distinct antibody mixes were prepared in 1% bovine serum albumin in PBS containing mouse (either HCA2/HC10 or EMR8-5) and rabbit antibodies (against collagen I, collagen VI, elastin and CD45) in the predetermined optimal dilutions. Tissue sections were then incubated overnight with either the HCA2/HC10-ECM-CD45 antibody mix or the EMR8-5-ECM-CD45 antibody mix. The following day, sections were incubated with AP-labelled secondary anti-mouse antibodies (MACH-2 Mouse AP-polymer; Biocare Medical, Pacheco, CA, USA) and developed with a Vector Blue Substrate kit (Vector Laboratories). Sections were subsequently incubated with anti-rabbit HRP-labelled secondary antibodies (Rabbit Envision; DAKO) and developed with a DAB substrate kit (DAKO). Note that the TMA tissue sections were not counterstained with haematoxylin, like in a standard IHC staining procedure. Finally, the sections were dehydrated and mounted with Ecomount (Biocare Medical).

### Semi-automated image analyses

Stained sections were scanned using an IntelliSite Digital pathology slide scanner (Philips, Eindhoven, The Netherlands). Images of the scanned sections were opened with Philips Digital Pathology Solution software (release 2.3.1.1, Philips Electronics). Single tumour TMA cores were then identified within the scanned sections and exported as JPEG images (20x magnification). Next, the JPEG images were imported into *AxioVision* digital image processing software (release 4.9.1, Zeiss) and HLA class I expression in the TMA tumour cores was assessed as percentage HLA class I-positive tumour epithelium from the tumour epithelium area using the following method (For detailed description, see supplementary data). In short, the tissue area of interest in the TMA core was annotated manually in *AxioVision* software, thereby excluding necrotic areas and artefacts as a result of the staining procedure to prevent interference with the analysis. The first step of the computer-assisted analysis was tissue selection based on a threshold in the RGB channels (determined for each staining) for automatic exclusion of areas within the annotated region that did not contain tissue. TMA cores containing <350,000 pixel<sup>2</sup> in the tissue area (equivalent to <10% tissue area of the total core area) were excluded from analysis. In the second step, tumour epithelium was identified using hue luminance saturation (HLS) settings to discriminate between brown-stained stromal tissue, blood vessels,

immune cells and HLA class I-positive or negative tumour epithelium. To correct for deposition of blue chromogen outside the tissue area, the settings for this step in the analysis were manually adapted for each TMA core. TMA cores with <5% tumour epithelium area (of the total tissue area) were excluded from analysis. Finally, HLA class I-positive tumour epithelium was identified within the total defined tumour epithelium area. This was accomplished by generation of a black and white image which was sorted into 256 levels of greyscale from black (0) to white (255). The two independent observers then determined the threshold for positive staining based on blinded assessment of five randomly selected TMA cores using the following method. The threshold for positive staining was decreased by 1 level at a time by the person responsible for the automated analysis until the independent observers indicated that the threshold resulted in optimal separation of HLA class I-positive and negative tumour epithelium. The mean of the 5 determined thresholds was used as cut-off value. Finally, to include the whole cell area of an HLA class I-positively stained tumour cell, the non-stained area within the cell (*i.e.* cytoplasm and nucleus) was included into the total tumour area considered as HLA class I-positive. The percentage of HLA class I-positive tumour epithelium among the total tumour epithelium area was semi-automatically scored in steps of 0.1%. In addition, HLA class I scores were categorized as follows: <60%, 60-80%, 80-95%, or 95-100% HLA class I-positive tumour epithelium.

### Statistical analyses

The percentage of HLA class I-positive tumour epithelium expression was compared between assessment by HCA2/HC10 and EMR8-5 antibodies using the Spearman correlation test. Furthermore, a Chi square test was used to correlate HLA class I categorical scoring between assessment by HCA2/HC10 and EMR8-5 antibodies. P-values ≤0.05 were considered statistically significant.

## Results

### HLA class I double staining

HLA class I expression was evaluated in a TMA of 495 primary rectal tumours either by a combination of HCA2/HC10 antibodies or by EMR8-5. It was chosen to analyse one TMA core per patient in order to include a high variety of tissue cores in the analysis regarding morphology and HLA class I expression as heterogeneity of

HLA class I expression among tumours and not within the tumours was subject of this study. Due to staining artefacts and loss of tissue cores during the staining procedure, the HCA2/HC10 and EMR8-5 staining could be evaluated in 284 (57.4%) and 298 tissue cores (60.2%) respectively. In total, 280 tissue cores were successfully evaluated for both IHC staining. Figure 1 shows an example of HLA class I IHC staining in TMA cores of rectal tumours as assessed using HCA2/HC10 (Figure 1A) and EMR8-5 antibodies (Figure 1B). Please note that no overlap of blue and brown chromogens was present on tumour epithelium using this double staining, allowing for clear evaluation of HLA class I expression by tumour epithelium. Furthermore, this staining method enabled clear visualization of brown-stained tumour-infiltrating immune cells (inserts in Figure 1).

### Semi-automated scoring of HLA class I expression with HCA2/HC10 antibodies

HLA class I expression was semi-automatically scored in the tissue cores IHC-

stained with HCA2/HC10 antibodies. Figure 1A shows the sequential steps in the semi-automated image analysis, starting with selection of the total tissue area using RGB colour settings. Due to deposition of blue chromogen outside the tissue area, probably as a result of binding of the antibodies to remnants of the tape that was used to transfer the TMA sections onto glass slides, the total tissue area was overestimated in approximately 20% of the evaluated TMA cores. These non-tissue containing areas were excluded from the semi-automated analysis in the next step in which all non-epithelial tissue was excluded from the tissue selection (*i.e.* negative selection). Please note that brown-stained tumour-infiltrating immune cells, together with brown-stained stromal tissue, were excluded from the tumour epithelium area selection (Figure 1A). Due to different composition of stromal tissue between tumours, the brown staining intensity varied between the tissue cores but this did not affect the image analysis. Finally, the area of HLA class I-positive tumour epithelium was selected. Based on blinded manual assessment of five

randomly selected TMA cores, the threshold for HLA class I-positive staining using semi-automated image analysis was determined as greyscale level 195. Thus, every pixel present in the tumour epithelium selection with a greyscale level between 0-195 was defined as HLA class I-positive, while all pixels with a greyscale level between 196-255 were defined as HLA class I negative. Figure 2 shows a representative area of the TMA stained for HLA class I expression, using the method we developed. In total, 9/19 (42.1%) of the TMA cores containing rectal tumour tissue in Figure 2 could not be analysed due to loss of tissue cores during the staining procedure, a phenomenon that is often observed when evaluating stained TMA tissue sections. The output from the semi-automated analysis for the example cores shown in Figure 2 is summarized in Table 1 and expressed as the number of pixels in the tissue area, tumour epithelium area and HLA class I-positive tumour epithelium area with the corresponding percentages. This information can be used to compensate for variation in the amount of tissue in different

**Table 1. Example of the semi-automated image analysis output of TMA cores with rectal tumour tissue stained for HLA class I expression with EMR8-5 antibodies. The table summarizes the output of the semi-automated image analysis of the TMA cores stained for HLA class I expression shown in Figure 2. TMA cores A3, A4, A5, B4, B5, C3 and D5 were excluded from analyses since <350,000 pixel<sup>2</sup> were present in the tissue area (equivalent to <10% tissue area of the total core area. C5 contained control placenta tissue and was therefore not analysed. Finally, D1 could not be analysed since the tissue that may be tumour epithelium stained brown. As a result, no discrimination could be made in D1 between tumour epithelium and non-epithelial tissue.**

TMA Core	Analysed	Tissue area		Tumour epithelium area		HLA class I-positive tumour epithelium area	
	Y/N	Pixel <sup>2</sup>	% of total core area	Pixel <sup>2</sup>	% of tissue area	Pixel <sup>2</sup>	% of tumour epithelium area
A1	Y	2493655	71.2%	1561920	62.6%	1107401	70.9%
A2	Y	2965056	84.7%	1107682	37.4%	1094390	98.8%
A3	N	NA	NA	NA	NA	NA	NA
A4	N	NA	NA	NA	NA	NA	NA
A5	N	152566	4.4%	NA	NA	NA	NA
B1	Y	2399358	68.6%	263289	11.0%	263026	99.9%
B2	Y	2552283	72.9%	301687	11.8%	299877	99.4%
B3	Y	2899882	82.9%	1578167	54.4%	1549760	98.2%
B4	N	NA	NA	NA	NA	NA	NA
B5	N	173445	5.0%	NA	NA	NA	NA
C1	Y	2803175	80.1%	1328377	47.4%	1253988	94.4%
C2	Y	2393691	68.4%	1567623	65.5%	1500215	95.7%
C3	N	NA	NA	NA	NA	NA	NA
C4	N	NA	NA	NA	NA	NA	NA
C5	Y	3230220	92.3%	1233284	38.1%	1209852	98.1%
D1	N	2370722	67.7%	NA	NA	NA	NA
D2	Y	1212719	34.6%	936256	77.2%	870718	93.0%
D3	Y	2810333	80.3%	690631	24.6%	556649	80.6%
D4	y	1965909	56.2%	590244	30.0%	526498	89.2%
D5	n	238838	6.8%	NA	NA	NA	NA

TMA, tissue microarray; HLA, human leukocyte antigen; NA, not available.

cores in case multiple tumour cores were evaluated per patient. In this study, we evaluated a single tumour core per patient and therefore, we did not compensate for variation in the amount of tissue in different cores.

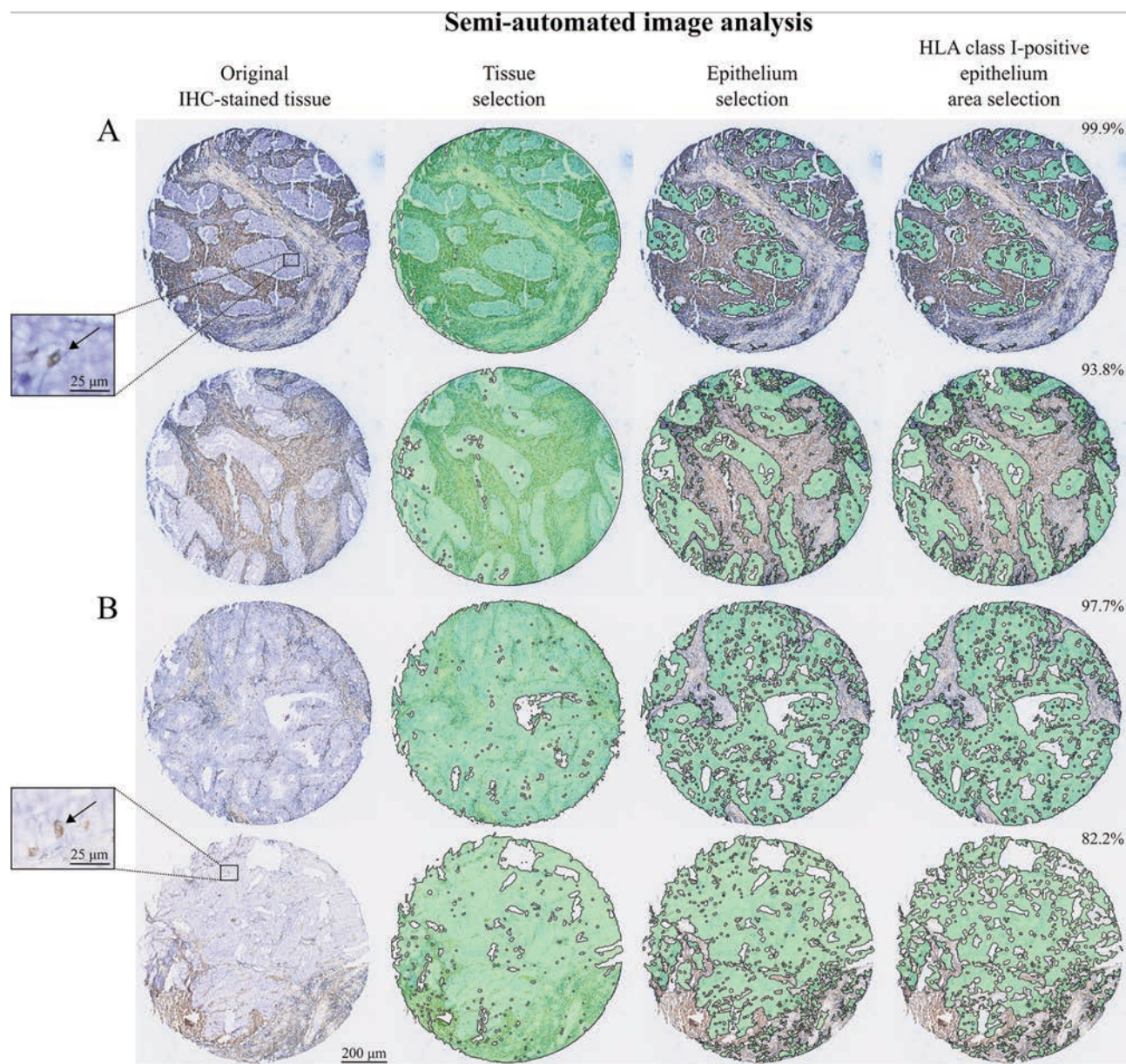
The mean percentage HLA class-I positive tumour epithelium area scored with the HCA2/HC10 antibody mix was  $96.7\% \pm 5.3$  (Table 2). In total, 220/284 (77.5%) of the

TMA cores were scored with 95-100% HLA class I-positive tumour epithelium (Table 2). Additionally, 56/284 (19.7%) and 8/284 (2.8%) tissue cores were scored with 80-95% and 60-80% HLA class I-positive tumour epithelium respectively (Table 2). No TMA cores were scored with <60% HLA class I-positive tumour epithelium (Table 2). These results indicate that the double staining method and subsequent

semi-automated image analysis can be used to score HLA class I expression in TMA cores of rectal cancer, enabling use of objective and consequent scoring criteria.

### Semi-automated scoring of HLA class I expression using EMR8-5 antibodies

Next, we assessed HLA class I expression in TMA cores of rectal cancer with



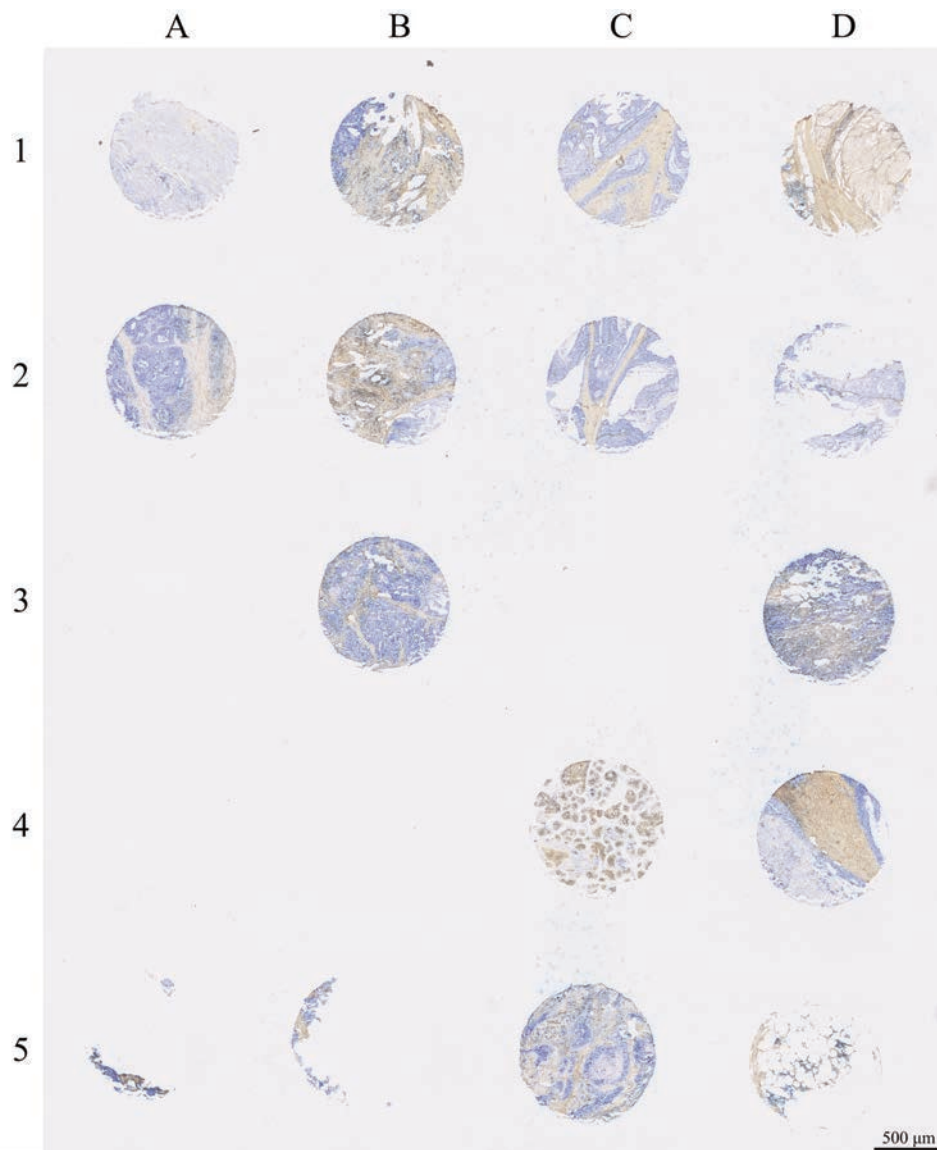
**Figure 1.** IHC double staining with subsequent semi-automated image analysis for HLA class I expression in four different TMA cores of rectal tumours with HCA2/HC10 or EMR8-5 antibodies. An IHC double staining was set up to analyse HLA class I expression in rectal cancer. Stromal tissue, blood vessels, and immune cells were stained brown whereas HLA class I expression (HCA2/HC10 antibody mix or EMR8-5) was stained blue. Representative images are presented of two TMA cores stained with the HCA2/HC10 antibody mix (A) and two TMA cores stained with EMR8-5 antibodies (B). The arrows in the high magnification inserts indicate (brown-stained) tumour-infiltrating immune cells. The images illustrate the different steps of the semi-automated image analysis of HLA class I expression in rectal cancer. Tissue selected in each step of the analysis is indicated in green. First, all tissue in the core was selected. Second, tumour epithelium was identified within the tissue selection by subtraction of the brown stroma. Third, the percentage of HLA class I-positive epithelium area was scored within the epithelium selection as displayed in the upper right corner of each TMA core. IHC, immunohistochemistry; HLA, human leukocyte antigen; TMA, tissue microarray.

EMR8-5 antibodies using the same image analysis workflow as described above. The threshold for HLA class I-positive staining was used as determined for the HCA2/HC10 stained TMA cores. Figure 1B shows two representative TMA cores stained with EMR8-5 with the sequential steps in the semi-automated image analysis. More variation was observed in the percentages of HLA class I-positive tumour epithelium in TMA cores with EMR8-5 compared to HCA2/HC10 (Table 2). The mean percentage HLA class-I positive tumour epithelium area scored with the EMR8-5 antibodies was  $92.9\% \pm 9.5$  (Table 2). In contrast with the HCA2/HC10 antibody mix, almost no deposition of blue chromogen outside the tissue area was observed

**Table 2. Overview of semi-automated scoring of HLA class I expression in a TMA of rectal cancer using HCA2/HC10 or EMR8-5 antibodies. Tumour epithelium expression of HLA class I was scored in TMA tumour cores of 284 rectal cancer patients with HCA2/HC10 antibodies, and in 298 patients with EMR8-5 antibodies. The mean percentage of HLA class I-positive tumour epithelium area is shown in the table. In addition, HLA class I scores were categorized as follows: <60%, 60-80%, 80-95%, or 95-100% HLA class I-positive tumour epithelium.**

	HCA2/HC10 N=284 (%)	EMR8-5 N=298 (%)
HLA class I expression		
Mean $\pm$ SD	96.7 $\pm$ 5.3	92.9 $\pm$ 9.5
Range	69.1-100.0	18.9-100.0
HLA class I expression		
<60%	0 (0.0)	3 (1.0)
60-80%	8 (2.8)	16 (5.4)
80-95%	56 (19.7)	113 (37.9)
95-100%	220 (77.5)	166 (55.7)

HLA, human leukocyte antigen; SD, standard deviation.



**Figure 2. Example of TMA cores with rectal tumour tissue stained for HLA class I expression with EMR8-5 antibodies. An IHC double staining was set up to analyse HLA class I expression in rectal cancer. Stromal tissue, blood vessels, and immune cells were stained brown whereas HLA class I expression (EMR8-5) was stained blue. A representative area of a TMA stained for HLA class I expression, containing 20 TMA cores, is shown. TMA, tissue microarray; IHC, immunohistochemistry; HLA, human leukocyte antigen.**

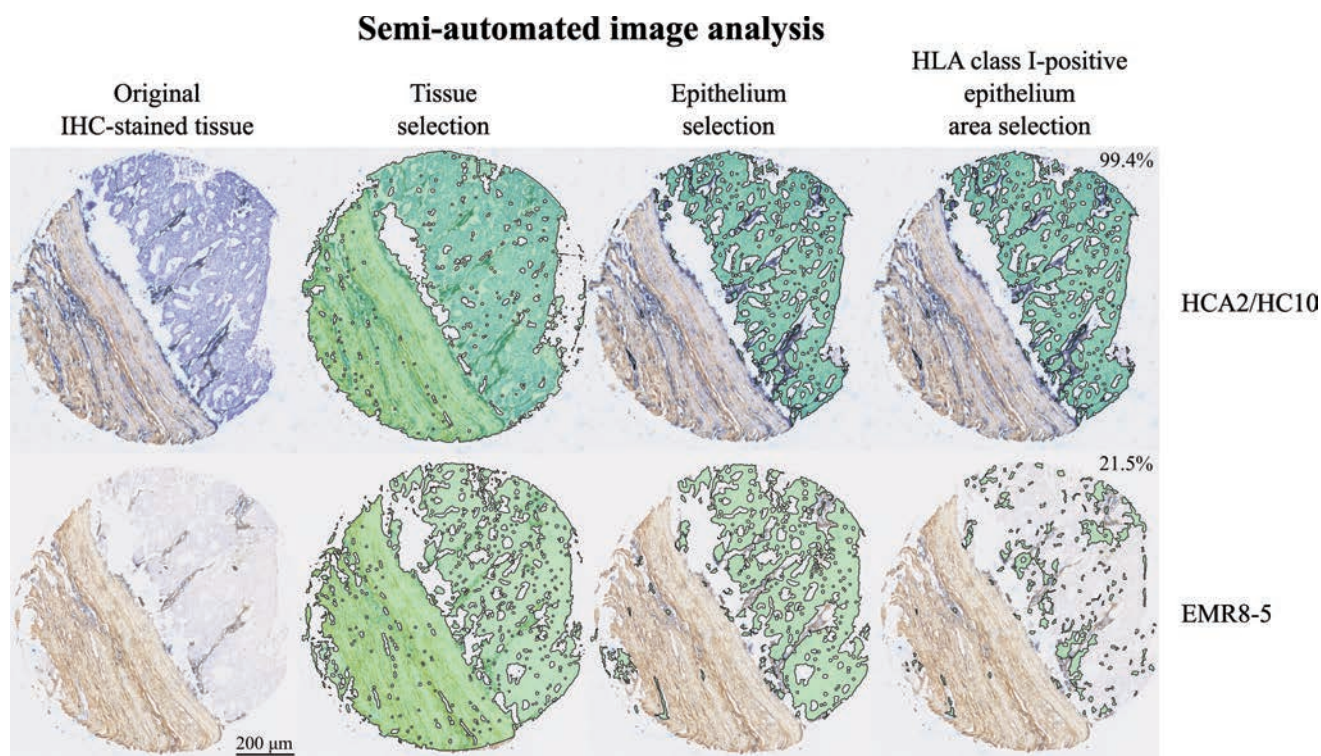
in the EMR8-5 staining, suggesting that EMR8-5 did not bind to remnants of the used tape. As a result, the total tissue area was not overestimated using EMR8-5. In conclusion, these results indicate that our IHC double staining technique and subsequent semi-automated image analysis can be used to score HLA class I expression on tumour epithelium using antibodies that recognize different HLA class I epitopes.

### Comparison of HCA2/HC10 and EMR8-5 antibodies for the assessment of HLA class I expression

Finally, we compared the percentage of HLA class I-positive tumour epithelium in TMA cores of rectal cancer as assessed by HCA2/HC10 and EMR8-5 antibodies, respectively. In total, 280 tissue cores were successfully analysed for both IHC staining. Scorings of HLA class I expression on tumour epithelium with HCA2/HC10 and EMR8-5 antibodies significantly correlated ( $\rho=0.136$ ,  $P=0.022$ ). Hence, tumour cores

scored with a high area percentage of HLA class-I positive tumour epithelium assessed by HCA2/HC10 antibodies were also scored with a high area percentage of HLA class-I positive tumour epithelium using EMR8.5 antibodies and the other way around. However, scoring of HLA class I expression in categories did not correlate when assessed with HCA2/HC10 and EMR8-5 antibodies ( $P=0.101$ ). We hypothesized that tumour epithelium would be scored equal or higher for HLA class I expression with HCA2/HC10 compared to EMR8-5 antibodies due to known cross reactivity of HCA2 with non-classical HLA molecules.<sup>12,13</sup> In the majority of the TMA cores (82.5%), the percentage of HLA class I-positive tumour epithelium was scored equal ( $\pm 10\%$ ) with HCA2/HC10 and EMR8-5 antibodies. In a fraction of the tissue cores (4.3%), the percentage of HLA class I-positive epithelium was scored  $>10\%$  higher with EMR8-5 compared to HCA2/HC10. When examined in further

detail, the scored differences in these tissue cores were due to inaccurate selection of the tumour epithelium as a result of tissue damage and a relatively high amount of blue chromogen deposition outside the tissue area in the HCA2/HC10 staining. In contrast, 4 times as many tissue cores (13.2%) were observed with  $>10\%$  higher HLA class I-positive percentage tumour epithelium area when assessed by HCA2/HC10 antibodies compared to EMR8-5. A representative tumour that was scored  $>10\%$  higher with HCA2/HC10 compared to EMR8-5 is shown in Figure 3. TMA cores with this staining pattern might express non-classical HLA class I molecules such as HLA-E, HLA-F and/or HLA-G that are recognized by HCA2/HC10 antibodies, but not by EMR8-5. In conclusion, the staining patterns of HCA2/HC10 and EMR8-5 antibodies are different, characterized by recognition of additional epitopes by HCA2/HC10, most likely non-classical HLA class I molecules.



**Figure 3.** Comparison of HCA2/HC10 and EMR8-5 antibodies for the evaluation of HLA class I expression in a TMA core of rectal cancer. An IHC double staining was set up to analyse HLA class I expression with HCA2/HC10 and EMR8-5 antibodies in a TMA of rectal cancer. Stromal tissue, blood vessels, and immune cells were stained brown whereas HLA class I expression was stained blue. The percentage of HLA class I-positive tumour epithelium area (indicated in the figure) was evaluated using semi-automated image analysis. Tissue selected by the software in each step of the analysis is indicated in green. First, all tissue in the TMA cores was selected. Second, tumour epithelium was identified within the tissue selection. Third, the percentage of HLA class I-positive epithelium area was scored within the epithelium selection. The example shows a TMA core that was observed to be positively stained with the HCA2/HC10 antibody mix, while being mostly negative regarding EMR8-5. These tissue cores might express non-classical HLA class I molecules such as HLA-E, HLA-F and/or HLA-G that are recognized by the HCA2/HC10 antibody mix but not by EMR8-5. HLA, human leukocyte antigen; TMA, tissue microarray; IHC, immunohistochemistry.

## Discussion

In order to study the expression of clinical predictive and prognostic biomarkers in tumour tissue using IHC, it is essential that scoring is standardized. Here, we presented an IHC double staining and subsequent semi-automated image analysis method that can be used to score the tumour epithelium expression of HLA class I in rectal cancer. Importantly, our developed technique has a major advantage by allowing discrimination between epithelium and non-epithelial tissue, which enabled simple semi-automated tissue selection based on colour. This method therefore enabled quantification of a biomarker (*i.e.* HLA class I) on tumour epithelium, even when also expressed by stromal tissue and/or immune cells. Using our relatively simple IHC double staining technique, a straight forward slide scanner is sufficient in order to obtain images that can be analysed at digital platforms that support JPEG files and that may be chosen based on availability and/or user experience. With the described image analysis method using *AxioVision* software, it was possible to calculate the percentage of HLA class I-positive tumour epithelium with a set threshold, thereby acquiring objective data. Since this scoring method is relatively fast and simple, it is highly suitable for analysis of biomarker expression on tumour tissue in both research and clinical settings. To the best of our knowledge, we are the first to describe a double staining method for semi-automated image analysis of biomarkers expressed by cancer tissue using a TMA.

Many different techniques have been reported to evaluate biomarkers on tumour tissue.<sup>17-22</sup> Some studies, using *MATLAB* software, could give insights in the relocation of tumour biomarkers between a cell's membrane, cytoplasm and nucleus using RGB unmixing of images of conventional IHC-stained sections (DAB and haematoxylin signals).<sup>20,21</sup> Additionally, *MATLAB* software (*MIAQuant* code) was recently reported as novel computational method for the quantification of IHC stained tissue sections.<sup>23,24</sup> This software is already used in clinical cancer research for determination of the expression of microRNAs in melanomas, which might have value in prediction of poor immunotherapy outcome.<sup>25</sup> As no discrimination could be made between tumour epithelium and non-epithelial tissue, this method is not suitable for quantification of tumour biomarkers that are also expressed by non-epithelial cells. Other studies reported that the software platform *ImageJ* can be used to evaluate the expression of biomarkers based on its immunohistochemical staining intensity on

a TMA in a high throughput manner.<sup>17-19</sup> Using this method, the tumour-epithelium specific expression of biomarkers could be analysed since the biomarker expression signal on epithelium was higher compared to non-epithelial tissue. Hence, the threshold for positive staining was set in a way that the relatively low signal in stromal tissue was scored as negative. Unfortunately, this method cannot be used for tumour epithelium-specific evaluation of biomarkers like HLA class I, that are also expressed at high levels on non-tumour cells. Recent studies using digital image analysis software *QuPath* or *ImageJ* showed that it is in principle possible to score biomarkers such as p53, Ki67, PR, HER2, and CD3 on tumour epithelium cells with standard IHC and haematoxylin counterstaining without a need for tumour or stromal identification markers.<sup>26-28</sup> However, it should be considered that the deep learning algorithms used in these analyses have disadvantages as a large number of training samples are required that need to be manually annotated by experts, thereby making it a time-consuming method to set up.<sup>29,30</sup> Additionally, deep learning algorithms often require the use of expensive microscopes and complicated software. For the future, it is likely that deep-learning algorithms in combination with the presented IHC double staining are even better for accurate scoring of biomarker expression on tumour epithelium. Importantly, deep learning algorithms might be less complicated to set up based on our IHC double staining since we used staining of non-epithelial cells instead of morphological features to distinguish tumour cells from other cells.

Although our semi-automated image analysis method has many advantages compared to other automated image analysis techniques, it also presents with some limitations. For instance, it provides information regarding the percentage of HLA class I-positive tumour epithelial area instead of percentage of tumour cells. Inclusion of a nuclear stain to the presented IHC staining would be required to estimate the latter. For this purpose, it is necessary to discriminate between more than two colours on one tissue slide for which the current software like we used is not suitable. Deep learning software, for instance in combination with spectral imaging, may solve this problem. Additionally, although infiltrating immune cells could be visualised and excluded from the tumour epithelium selection, it was not possible to quantify them in TMA tumour cores. This was due to the use of one chromogen for both immune cells and other non-epithelial cells, thereby complicating discrimination of these cell types. For detailed analyses of infiltrating immune

cells, multiplex immunofluorescence is advised.<sup>31,32</sup> Furthermore, our IHC double staining does not discriminate between normal epithelium and tumour epithelium. This is not an issue when analysing TMA tumour cores since the location of these tumour tissue cores has been annotated and checked by a pathologist. When analysing whole tissue sections, however, it will be necessary to visually verify which areas contain tumour epithelium and should therefore be analysed. Finally, as described in the Materials and Methods section, the presented IHC double staining uses species-specific antibodies, meaning that in combination with the rabbit-derived ECM/CD45 antibody mix, biomarkers can be evaluated using any non-rabbit-derived antibodies. In case only rabbit antibodies are available for the evaluation of a specific biomarker, a new ECM/CD45 mix has to be prepared with antibodies derived from another species.

HCA2 and HC10 antibodies are often used to study HLA class I expression in cancer.<sup>4-6,15</sup> Importantly, the combination of HCA2 and HC10 antibodies overestimates the total HLA class I expression due to the cross reaction of HCA2 with non-classical HLA molecules<sup>12,13</sup> that are known to be present in rectal tumours.<sup>5,15</sup> In this study, we showed that some TMA cores of rectal cancer positively stained with HCA2/HC10 antibodies while being negative regarding EMR8-5, thereby suggesting that EMR8-5 indeed does not cross react with additional non-classical HLA molecules.<sup>16</sup> Therefore, in our opinion, EMR8-5 is a better monoclonal antibody to assess the expression of HLA class I specifically compared to a mix of HCA2/HC10 antibodies.

In conclusion, the presented IHC double staining and subsequent semi-automated image analysis can be used for the scoring of HLA class I expression on tumour epithelium, thereby acquiring quantitative and objective data. This staining method and automated analysis can be expanded to any other tissue biomarker and also to different (epithelial) cancer types, and is therefore widely applicable for tumour biomarker analysis.

## References

1. Yaziji H, Barry T. Diagnostic Immunohistochemistry: what can go wrong? *Adv Anat Pathol* 2006;13:238-46.
2. Matos LL, Trufelli DC, de Matos MG, da Silva Pinhal MA. Immunohistochemistry as an important tool in biomarkers detection and clinical practice. *Biomark Insights* 2010;5:9-20.
3. de Bruin EC, van de Velde CJ, van

- Krieken JH, Marijnen CA, Medema JP. Epithelial human leukocyte antigen-DR expression predicts reduced recurrence rates and prolonged survival in rectal cancer patients. *Clin Cancer Res* 2008;14: 1073-9.
4. Speetjens FM, de Bruin EC, Morreau H, Zeestraten EC, Putter H, van Krieken JH, et al. Clinical impact of HLA class I expression in rectal cancer. *Cancer Immunol Immunother* 2008;57: 601-9.
  5. Reimers MS, Engels CC, Putter H, Morreau H, Liefers GJ, van de Velde CJ, et al. Prognostic value of HLA class I, HLA-E, HLA-G and Tregs in rectal cancer: a retrospective cohort study. *BMC Cancer* 2014;14:486.
  6. Zeestraten EC, Reimers MS, Saadatmand S, Goossens-Beumer IJ, Dekker JW, Liefers GJ, et al. Combined analysis of HLA class I, HLA-E and HLA-G predicts prognosis in colon cancer patients. *Br J Cancer* 2014;110:459-68.
  7. Kapiteijn E, Kranenbarg EK, Steup WH, Taat CW, Rutten HJ, Wiggers T, et al. Total mesorectal excision (TME) with or without preoperative radiotherapy in the treatment of primary rectal cancer. Prospective randomised trial with standard operative and histopathological techniques. Dutch ColoRectal Cancer Group. *Eur J Surg* 1999;165: 410-20.
  8. Watson NF, Ramage JM, Madjd Z, Spendlove I, Ellis IO, Scholefield JH, et al. Immunosurveillance is active in colorectal cancer as downregulation but not complete loss of MHC class I expression correlates with a poor prognosis. *Int J Cancer* 2006;118:6-10.
  9. Sandel MH, Speetjens FM, Menon AG, Albertsson PA, Basse PH, Hokland M, et al. Natural killer cells infiltrating colorectal cancer and MHC class I expression. *Mol Immunol* 2005;42:541-6.
  10. Mizukami Y, Kono K, Maruyama T, Watanabe M, Kawaguchi Y, Kamimura K, et al. Downregulation of HLA Class I molecules in the tumour is associated with a poor prognosis in patients with oesophageal squamous cell carcinoma. *Br J Cancer* 2008;99:1462-7.
  11. Kaneko K, Ishigami S, Kijima Y, Funasako Y, Hirata M, Okumura H, et al. Clinical implication of HLA class I expression in breast cancer. *BMC Cancer* 2011;11:454.
  12. Seitz C, Uchanska-Ziegler B, Zank A, Ziegler A. The monoclonal antibody HCA2 recognises a broadly shared epitope on selected classical as well as several non-classical HLA class I molecules. *Mol Immunol* 1998;35:819-27.
  13. Sernee MF, Ploegh HL, Schust DJ. Why certain antibodies cross-react with HLA-A and HLA-G: epitope mapping of two common MHC class I reagents. *Mol Immunol* 1998;35:177-88.
  14. Perosa F, Luccarelli G, Prete M, Favoino E, Ferrone S, Dammacco F. Beta 2-microglobulin-free HLA class I heavy chain epitope mimicry by monoclonal antibody HC-10-specific peptide. *J Immunol* 2003;171:1918-26.
  15. Swets M, Konig MH, Zaalberg A, Dekker-Ensink NG, Gelderblom H, van de Velde CJ, et al. HLA-G and classical HLA class I expression in primary colorectal cancer and associated liver metastases. *Immunol* 2016;77:773-9.
  16. Torigoe T, Asanuma H, Nakazawa E, Tamura Y, Hirohashi Y, Yamamoto E, et al. Establishment of a monoclonal anti-papan HLA class I antibody suitable for immunostaining of formalin-fixed tissue: unusually high frequency of downregulation in breast cancer tissues. *Pathol Int* 2012;62:303-8.
  17. Wang Q, Symes AJ, Kane CA, Freeman A, Nariculam J, Munson P, et al. A novel role for Wnt/Ca2+ signaling in actin cytoskeleton remodeling and cell motility in prostate cancer. *PLoS One* 2010;5:e10456.
  18. Symes AJ, Eilertsen M, Millar M, Nariculam J, Freeman A, Notara M, et al. Quantitative analysis of BTF3, HINT1, NDRG1 and ODC1 protein over-expression in human prostate cancer tissue. *PLoS One* 2013;8:e84295.
  19. Cao K, Arthurs C, Atta-UI A, Millar M, Beltran M, Neuhaus J, et al. Quantitative Analysis of Seven New Prostate Cancer Biomarkers and the Potential Future of the 'Biomarker Laboratory'. *Diagnostics (Basel)* 2018;8 pii:E49.
  20. Newberg J, Murphy RF. A framework for the automated analysis of subcellular patterns in human protein atlas images. *J Proteome Res* 2008;7:2300-8.
  21. Kumar A, Rao A, Bhavani S, Newberg JY, Murphy RF. Automated analysis of immunohistochemistry images identifies candidate location biomarkers for cancers. *Proc Natl Acad Sci USA* 2014;111:18249-54.
  22. Ali HR, Irwin M, Morris L, Dawson SJ, Blows FM, Provenzano E, et al. Astronomical algorithms for automated analysis of tissue protein expression in breast cancer. *Br J Cancer* 2013;108: 602-12.
  23. Casiraghi E, Cossa M, Huber V, Rivoltini L, Tozzi M, Villa A, et al. MIAQuant, a novel system for automatic segmentation, measurement, and localization comparison of different biomarkers from serialized histological slices. *Eur J Histochem* 2017;61:2838.
  24. Casiraghi E, Huber V, Frasca M, Cossa M, Tozzi M, Rivoltini L, et al. A novel computational method for automatic segmentation, quantification and comparative analysis of immunohistochemically labeled tissue sections. *BMC Bioinformatics* 2018;19(S10):357.
  25. Huber V, Vallacchi V, Fleming V, Hu X, Cova A, Dugo M, et al. Tumor-derived microRNAs induce myeloid suppressor cells and predict immunotherapy resistance in melanoma. *J Clin Invest* 2018;128:5505-16.
  26. Bankhead P, Fernandez JA, McArt DG, Boyle DP, Li G, Loughrey MB, et al. Integrated tumor identification and automated scoring minimizes pathologist involvement and provides new insights to key biomarkers in breast cancer. *Lab Invest* 2018;98:15-26.
  27. Loughrey MB, Bankhead P, Coleman HG, Hagan RS, Craig S, McCorry AMB, et al. Validation of the systematic scoring of immunohistochemically stained tumour tissue microarrays using QuPath digital image analysis. *Histopathology* 2018;73:327-38.
  28. Liu J, Xu B, Zheng C, Gong Y, Garibaldi J, Soria D, et al. An end-to-end deep learning histochemical scoring system for breast cancer TMA. *IEEE Trans Med Imaging* 2019;38:617-28.
  29. Komura D, Ishikawa S. Machine learning methods for histopathological image analysis. *Comput Struct Biotechnol J* 2018;16:34-42.
  30. Sirinukunwattana K, Ahmed Raza SE, Tsang YW, Snead DRJ, Cree IA, Rajpoot NM. A spatially constrained deep learning framework for detection of epithelial tumor nuclei in cancer histology images. Wu G, Coupé P, Zhan Y, Munsell B, Rueckert D, Editors; *Patch-Based Techniques in Medical Imaging*. Cham, Springer: 2015; p. 154-62.
  31. Parra ER, Uraoka N, Jiang M, Cook P, Gibbons D, Forget MA, et al. Validation of multiplex immunofluorescence panels using multispectral microscopy for immune-profiling of formalin-fixed and paraffin-embedded human tumor tissues. *Sci Rep* 2017;7:13380.
  32. Park IJ, An S, Kim SY, Lim HM, Hong SM, Kim MJ, et al. Prediction of radioresponsiveness with immune-profiling in patients with rectal cancer. *Oncotarget* 2017;8:79793-802.