

Use of topical lidocaine in eliminating mechanically stimulated ventricular fibrillation in a patient with short QT syndrome



Maria J. Farag, BS,* Joseph Atallah, MD CM, MS†

From the *National University of Ireland, Galway, Ireland, and †Department of Pediatrics, University of Alberta, Edmonton, Canada.

Introduction

Congenital short QT syndrome (SQTS) is a rare cardiac channelopathy characterized by ventricular arrhythmias, atrial fibrillation, and a short QT interval. A contemporary review reported that 22 different causative mutations in 9 genes have been associated with the syndrome.¹ Mutations associated with SQTS result in shortening of the action potential duration (APD) and myocardial effective refractory period (ERP). These electrophysiological aberrations lead to increased ventricular and atrial susceptibility to premature stimulation and inducible tachyarrhythmias.² Clinically, the syndrome is characterized by cardiac symptoms in a significant proportion of patients, a prevalent family history of sudden cardiac death, and specific electrocardiogram findings including short QT as well as tall and peaked T waves.^{1,3} Sudden cardiac death or aborted sudden cardiac death is the most common clinical presentation.^{1,3} Peculiar to this syndrome is the rare susceptibility to mechanical induction of ventricular arrhythmias, observed during an electrophysiology (EP) study.⁴ This case of a 7-year-old child with SQTS demonstrates the reproducible susceptibility to ventricular fibrillation (VF) with both epicardial and endocardial mechanical stimulation, as well as the antiarrhythmic efficacy of topical lidocaine.

Case report

This case involves a 7-year-old patient with SQTS (Figure 1) and recurrent VF episodes. At 7 months of age, the patient had been suspected to be in a persistent 2:1 atrial tachycardia, having failed treatment with digoxin, flecainide, and amiodarone. He was put forward for an EP study and possible ablation. During the procedure, a single mechanically provoked premature ventricular beat, during catheter placement

KEYWORDS Epicardial; Implantable cardioverter-defibrillator; Lidocaine; Short QT syndrome; Sudden cardiac death; Ventricular fibrillation (Heart Rhythm Case Reports 2019;5:152–154)

Address reprint requests and correspondence: Dr Joseph Atallah, Department of Pediatrics, 4C1.19 Stollery Children's Hospital, 8440-112 St, Edmonton, Alberta, Canada, T6G 2B7. E-mail address: joseph.atallah@ahs.ca.

KEY TEACHING POINTS

- Mechanically induced ventricular fibrillation is rare in patients with short QT syndrome.
- Both endocardial and epicardial mechanical stimulation can trigger premature myocardial activity and lead to ventricular fibrillation in patients with short QT syndrome.
- The application of topical lidocaine can allow prompt suppression of mechanically induced tachyarrhythmias without affecting myocardial function.

in the right ventricle, induced VF (Figure 2). This occurred on 2 separate occasions and required direct current cardioversion. During the EP study, correlation of the atrial and ventricular catheter electrocardiogram recordings showed 1:1 correlation and no evidence of a 2:1 atrial tachycardia. It became evident that the early and peaked T wave had been mistaken for a P wave, with matching TP and PT intervals. The procedure was terminated and subsequently the diagnosis of SQTS was made.

After detailed counseling, the family opted for an automated external defibrillator and declined other treatment options. After the patient experienced an episode of aborted VF arrest at home at 7 years of age, the family agreed to proceed with an epicardial single-chamber implantable cardioverter-defibrillator (ICD). During the procedure, the heart was found to be very arrhythmogenic with mechanical stimulation. During attempts to sew on the epicardial lead, VF was repeatedly induced with instrument manipulation or when the needle would touch the epicardium. After 3 episodes of sustained VF requiring cardioversion, an intravenous amiodarone bolus was ordered and while the patient awaited administration, 2% topical lidocaine was sprayed on the heart. Within less than 2 minutes, surgical manipulation of the heart became possible without VF induction, facilitating the suturing of the epicardial lead using the same

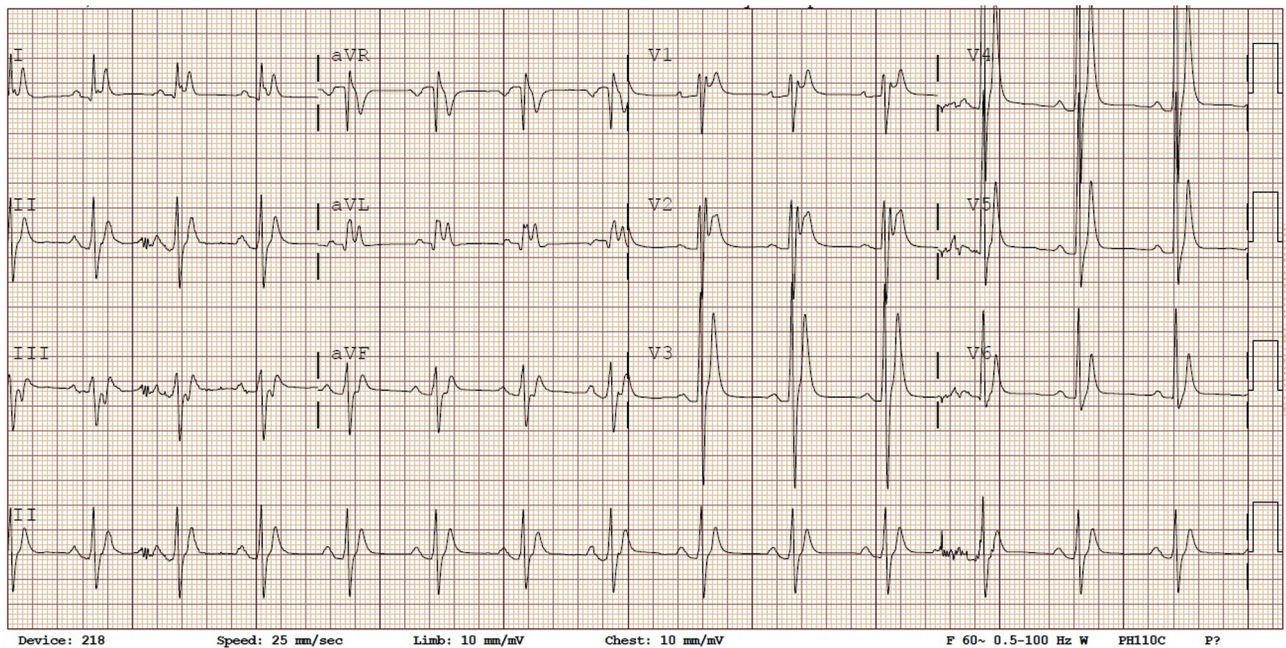


Figure 1 Standard 12-lead electrocardiogram showing a QT of 210 ms and QTc of 246 at a heart rate of 82 beats per minute. Note the narrow and peaked tall T waves.

surgical approach. Once the coil was placed in the retrosternal area and all surgical epicardial manipulation was completed, lead testing showed bipolar sensing of 16.5 mV, capture threshold of 0.75 V at 0.6 ms, and impedance of 836 ohms.

The patient remained stable throughout the remainder of the procedure and during the subsequent hospital course. There were no documented arrhythmias, specifically during testing of the pace-sense lead with ventricular pacing. Repeat

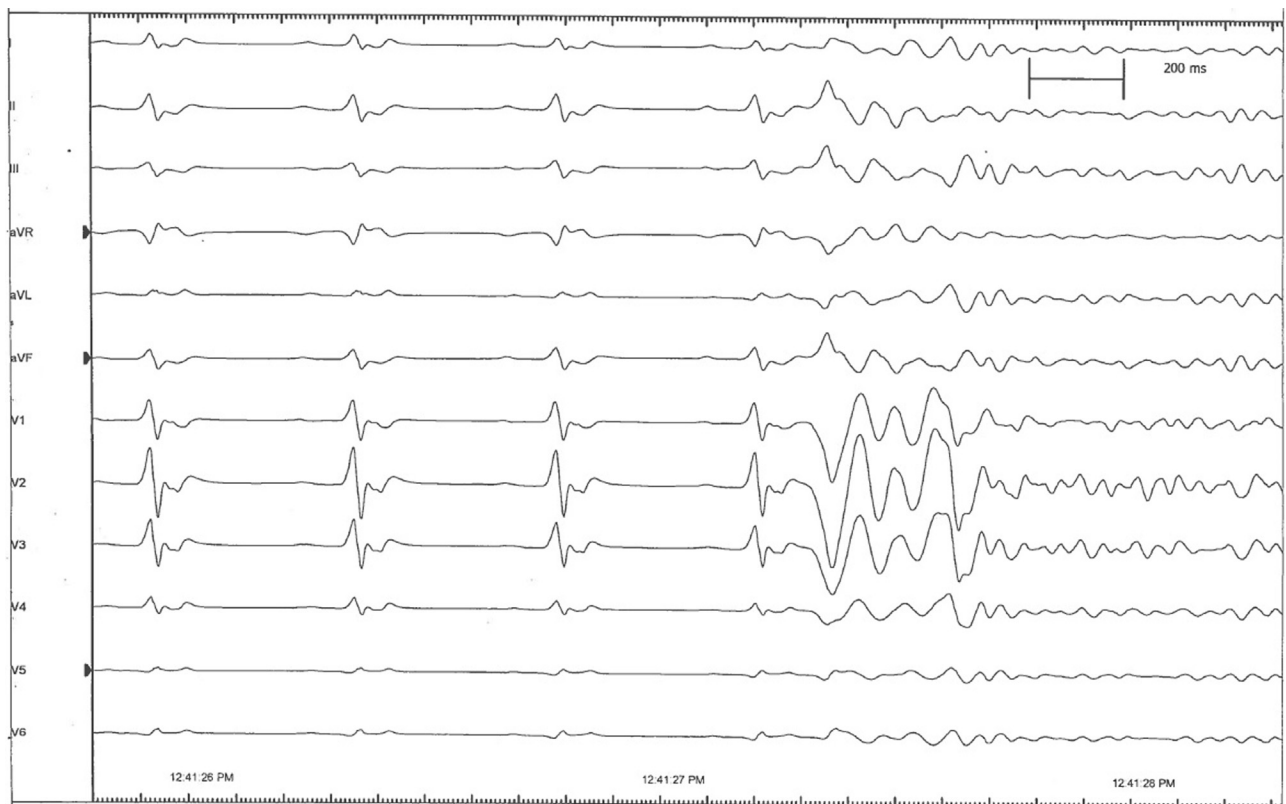


Figure 2 Mechanically induced ventricular ectopy and subsequent ventricular fibrillation during the electrophysiology study (there are no simultaneous intra-cardiac tracings available, as recording was not being performed during catheter placement).

lead integrity testing on postoperative day 3 showed bipolar sensing of 21 mV, capture threshold of 0.8 V at 0.4 ms, and impedance of 760 ohms. Over the subsequent 5 years, the impedance remained stable at 590–600 ohms. At 12 years of age, the patient returned for epicardial lead revision and generator change. Mechanically induced VF with epicardial manipulation was again encountered during initial dissection, in an attempt to add an atrial lead. As consented to with the parents prior to the procedure, the atrial lead placement was aborted due to the inducible VF and only the generator replacement was performed.

Discussion

This case highlights the high susceptibility for VF induction, with either endocardial or epicardial mechanical stimulation, in rare patients with SQTS. It also brings to light the efficacy of topical lidocaine as an effective and expeditious antiarrhythmic in this pathophysiological scenario involving an epicardial intervention. Topical lidocaine allowed timely completion of a class I indication ICD implant that had evolved into a high-risk procedure with recurrent sustained VF episodes.

In the congenital SQTS series published by Giustetto and colleagues,⁴ they report on a 6-month-old child who experienced similar mechanical VF induction. The patient was undergoing an EP study when catheter positioning induced VF on 2 occasions, resulting in termination of the procedure. We are not aware of other published cases of SQTS complicated by mechanical VF induction. Although data have been published on the *in vivo* inducibility of VF, comparing endocardial vs epicardial programmed stimulation,⁵ there are no similar reports evaluating inducibility with mechanical stimulation. On the other hand, the value of endocardial vs epicardial mechanical stimulation in terminating arrhythmias was studied by Befeler.⁶

Mechanoelectric coupling (MEC) is thought to be the underlying mechanism whereby VF is easily induced with mechanical stimulation. One of the major factors in the mechanism of MEC are mechanosensitive ion channels that are activated in response to an extrinsic stimulus (such as cardiac catheterization), extracorporeal impacts, or precordial thump application.⁷ These mechanosensitive ion channels include stretch-activated cations and cell volume-activated channels.⁷ Nonselective stretch-activated cations and potassium-selective stretch-activated cations are thought to be responsible for mechanical action potential induction.⁷ The additional activation of potassium-selective stretch-activated cations is also likely to form one of the mechanisms that help sustain tachyarrhythmic responses.⁷

Lidocaine, a sodium channel blocker, is a class Ib antiarrhythmic. When administered transvenously, it causes shortening of the APD and ERP duration, and it raises the

depolarization threshold. Hence, its antiarrhythmic effect results from a decrease in the nonuniformity of APDs and a more uniform recovery of excitability in Purkinje and myocardial cells.^{8–10} However, when administered locally, significantly higher concentrations are achieved.¹¹ *In vitro* studies have shown that high local concentrations of lidocaine do not shorten the myocardial fiber APD; rather, they alter depolarization and render the myocardial cells unexcitable, without resulting in global myocardial depression.^{10,11} We hypothesize that the antiarrhythmic effect of topical lidocaine in this case was achieved as high local concentrations temporarily inhibited depolarization of mechanically stimulated cells. The latter prevented the reinduction of VF without negatively impacting the electrophysiological and mechanical properties of unexposed myocardial tissue.

Conclusion

Mechanically induced VF was an unfortunate complication during multiple procedures in this young patient with SQTS. The latter proved to be a risk with endocardial stimulation, as previously reported in a similar patient, and, unexpectedly, with epicardial stimulation as well. The topical application of lidocaine was effective in suppressing mechanically induced arrhythmias and allowed completion of a class I indication ICD implant.

References

1. Bjerregaard P. Diagnosis and management of short QT syndrome. *Heart Rhythm* 2018;15:1261–1267.
2. Crotti L, Taravelli E, Girardengo G, Schwartz PJ. Congenital short QT syndrome. *Indian Pacing Electrophysiol J* 2010;10:86–95.
3. Villafane J, Atallah J, Gollob MH, et al. Long-term follow-up of a pediatric cohort with short QT syndrome. *J Am Coll Cardiol* 2013;61:1183–1191.
4. Giustetto C, Di Monte F, Wolpert C, Borggreffe M, Schimpf R, Sbragia P, Leone G, Maury P, Anttonen O, Haissaguerre M, Gaita F. Short QT syndrome: clinical findings and diagnostic-therapeutic implications. *Eur Heart J* 2006;27:2440–2447.
5. Dailey SM, Kay GN, Epstein AE, McGiffin DC, Kirklín JK, Plumb VJ. Comparison of endocardial and epicardial programmed stimulation for the induction of ventricular tachycardia. *J Am Coll Cardiol* 1989;13:1608–1612.
6. Befeler B. Mechanical stimulation of the heart: its therapeutic value in tachyarrhythmias. *Chest* 1978;73:832–838.
7. Quinn TA, Kohl P. Mechanical triggers and facilitators of ventricular tachyarrhythmias. In: Kohl P, Sachs F, Michael R, Franz MR, eds. *Cardiac Mechano-electric Coupling and Arrhythmias*. Oxford, United Kingdom: Oxford University Press; 2011:160–167.
8. Carlisle EJ, Allen JD, Kernohan WG, Leahey W, Adgey AA. Pharmacological analysis of established ventricular fibrillation. *Br J Pharmacol* 1990;100:530–534.
9. Collinsworth KA, Kalman SM, Harrison DC. The clinical pharmacology of lidocaine as an antiarrhythmic drug. *Circulation* 1974;50:1217–1230.
10. Bigger JT Jr, Mandel WJ. Effect of lidocaine on the electrophysiological properties of ventricular muscle and Purkinje fibers. *J Clin Invest* 1970;49:63–77.
11. Weinberg L, Peak B, Tan C, Nikfarjam M. Pharmacokinetics and pharmacodynamics of lignocaine: a review. *World J Anesthesiol* 2015;4:17–29.