

Deployment of a Resuscitative Endovascular Balloon Occlusion of the Aorta Device in a Case of Gunshot Wound Injury to a Horseshoe Kidney

Karen Castaneda ¹, Yana Puckett ², Andres Leal ³, Catherine A. Ronaghan ³

1. School of Medicine, Texas Tech Health Sciences Center, Lubbock, TX, USA 2. Surgery, Texas Tech University Health Sciences Center, Atlanta, GA, USA 3. Surgery, Texas Tech University Health Sciences Center, Lubbock, TX, USA

✉ **Corresponding author:** Karen Castaneda, karen.castaneda@ttuhsc.edu
Disclosures can be found in Additional Information at the end of the article

Abstract

A horseshoe kidney (HSK) is a urological malformation that is typically found incidentally after a traumatic injury due to its asymptomatic nature. We present a 25-year-old male with multiorgan injuries secondary to blunt abdominal trauma caused by a gunshot wound. We report the courses of action taken that led to the identification of the HSK and other associated intra-abdominal injuries and the subsequent surgical management. Resuscitative endovascular balloon occlusion of the aorta (REBOA) is an improving minimally invasive technique that was used to control hemorrhage in the early preoperative stages and during surgical repair of the injuries. Multiorgan injuries that involve an HSK are uncommon. Our interest in the case relies on the rarity and unique aspects of the injuries and the recovery of the patient following the use of REBOA.

Categories: Emergency Medicine, General Surgery, Nephrology

Keywords: horseshoe kidney, gunshot wound, blunt abdominal trauma, reboa

Introduction

Horseshoe kidneys (HSK) are among the most common congenital malformations of the urinary tract involving anomalies such as ectopia, malrotation, and vascular changes. They have an approximate frequency of 1:500 and are twice as likely to occur in males [1-2]. Kidneys generally appear between the fourth and the sixth week of development [3-4]. Fusion anomalies also occur during this time and can occur up to week nine of development [4-5]. Kidneys are initially located in the pelvis and ascend to their final position in the retroperitoneal renal fossa by the ninth week [4]. As they ascend, the blood supply originates from the aorta at continuously higher levels, while inferior branches degenerate [4,6]. The kidneys also rotate medially [7]. Occasionally, the kidneys can be pushed together during their ascent leading to the fusion of lower poles and the formation of an HSK [1-2]. An HSK is usually found at the level of the lumbar vertebra as its ascent is impeded by the inferior mesenteric artery [6]. However, it can be found anywhere along the normal path of ascent with the position being more ectopic as the fusion is more complete [4].

The vascular supply is variable in terms of the origin, number, and size of the renal arteries and veins. Arterial origins can come from the aorta, common iliac artery, medial sacral artery, lumbar artery, internal iliac artery, external iliac artery, and phrenic artery [2,4]. The

Received 09/14/2018

Review began 09/17/2018

Review ended 09/24/2018

Published 10/02/2018

© Copyright 2018

Castaneda et al. This is an open access article distributed under the terms of the Creative Commons Attribution License CC-BY 3.0., which permits unrestricted use, distribution, and reproduction in any medium, provided the original author and source are credited.

How to cite this article

Castaneda K, Puckett Y, Leal A, et al. (October 02, 2018) Deployment of a Resuscitative Endovascular Balloon Occlusion of the Aorta Device in a Case of Gunshot Wound Injury to a Horseshoe Kidney. Cureus 10(10): e3399. DOI 10.7759/cureus.3399

vasculature of the isthmus is also variable. It can obtain its blood supply from the main renal artery, aorta, common iliac artery, or inferior mesenteric artery [4].

There are various factors that explain the embryogenesis of an HSK, from positional factors, anomalous fusion related to proximity, abnormalities in the migration of metanephric cells, intrauterine factors, and genetic factors [4]. The isthmus of an HSK can contain fibrous or parenchymatous tissue. The majority of HSKs, 80%, are found to have a parenchymatous isthmus that is thought to result from the abnormal migration of posterior nephrogenic cells across the primitive streak [4,7]. In this theory, the isthmus occurs due to ectopic mesenchymal tissue as opposed to the fusion of nephrogenic blastemas when they come in close contact, which results in a fibrous isthmus [7].

Findings of an HSK are typically incidental, since most, approximately 60%, are asymptomatic [3]. Their anatomical position, outside from the normal protection provided by the lower part of the ribcage, make them more susceptible to abdominal trauma. Renal injury occurs in 10% of abdominal traumas and 7% occurs in kidneys with a congenital or acquired disorder [3]. We present a renal trauma case from a gunshot wound (GSW) in a patient with an unknown HSK.

Case Presentation

A 25-year-old male presented to the emergency department (ED) at our Level I Trauma Unit after receiving a GSW in the back. The patient was found to be peritonitic and tachycardic upon physical examination in the ED triage. A focused assessment with sonography for trauma exam showed fluid in the peritoneum. A resuscitative endovascular balloon occlusion of the aorta (REBOA) was deployed in the ED for active proximal control of the hemorrhage. He was transferred to the operating room (OR) for an exploratory laparotomy, where numerous intra-abdominal injuries were found, including a splenic hilum injury, renal artery injury, and proximal bowel injury. The patient was noted to have an HSK, making the hemorrhage from the kidney more difficult to control (Figure 1). The renal capsule was opened and a 5 mm penetrating wound was found going through the left side of the HSK. Due to ongoing hemorrhage, the REBOA device was once again deployed. A large left renal vein was noted to be lacerated. This vein was ligated using 0-silk suture. The patient did well postoperatively and was discharged on postoperative Day 5.

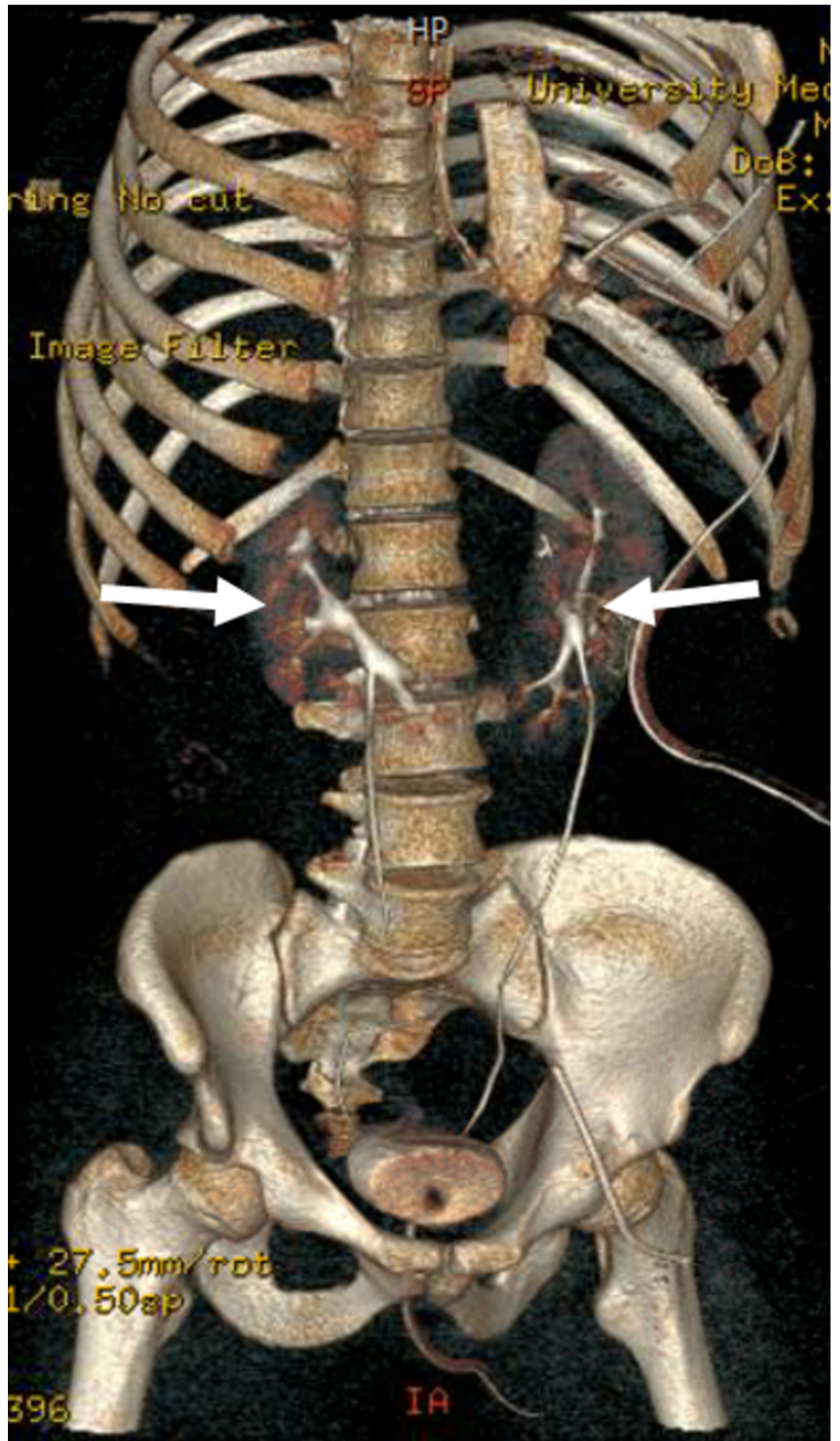


FIGURE 1: Postoperative three-dimensional view of the

horseshoe kidney of the patient with gunshot wound injury and subsequent repair to the left portion of the horseshoe kidney.

Discussion

Renal traumatic injuries in an unsuspected HSK are rare, especially following a GSW. Most, approximately 63%, are primarily due to motor vehicle collisions [8]. Their initial management is similar to that of any other patient presenting with blunt abdominal trauma, but special considerations regarding treatment must be taken into account. Albeit challenging to determine, early recognition is of critical importance for prognosis.

Standards of treatment for traumatic injuries tend to follow the most conservative options from observation to minimally invasive procedures to open surgical management [8-9]. Cases have been reported with successful outcomes using minimally invasive procedures such as the use of stents, while others have presented with complications that require exploratory laparotomies and open surgery [9]. The anatomical complexity of an HSK adds to the difficulty in surgical management of multiorgan injuries due to the high variability in location, orientation, and blood supply [3,9]. On account of this complexity, reports have suggested that abnormal kidneys be treated on an individual basis to focus on the patient's clinical course to guide management [9-10].

Non-compressible hemorrhages from blunt abdominal trauma can be difficult to control using a conservative approach. The current management is highly invasive [3]. REBOA is a technique that involves the insertion of a catheter through the common femoral artery and the expansion of a balloon at a level appropriate for hemorrhage control. It is less invasive than open thoracotomies and exploratory laparotomies. There have been studies identifying REBOA as a favorite alternative such as one prospective study that compared the use of open thoracotomy and REBOA, and others in Japan that compared the use of aortic cross-clamping and REBOA [11-12]. However, the data is inconclusive, and more research is still needed to identify the effectiveness of REBOA [13]. REBOA carries a risk for irreversible organ damage, cardiac failure, and exacerbation of traumatic brain injury [14-15]. Partial REBOA (pREBOA) where the balloon is partially deflated, and intermittent REBOA (iREBOA) where the balloon is fully deflated for brief periods of time, have been developed to address these limitations. However, data on these are also limited.

Conclusions

In our case, deployment of a REBOA device intraoperatively allowed us to visualize the injury to an HSK with ease, allowing quick repair of the injury. Overall, REBOA has been increasingly used worldwide, but further research and training are needed to ensure reliable indications and methods and establish its effectiveness.

Additional Information

Disclosures

Human subjects: Consent was obtained by all participants in this study. NA issued approval NA. No identifying information appears in this case report. **Conflicts of interest:** In compliance with the ICMJE uniform disclosure form, all authors declare the following: **Payment/services info:** All authors have declared that no financial support was received from any organization for the submitted work. **Financial relationships:** All authors have declared that they have no financial relationships at present or within the previous three years with any organizations that might have an interest in the submitted work. **Other relationships:** All

authors have declared that there are no other relationships or activities that could appear to have influenced the submitted work.

References

1. Crawford ES, Coselli JS, Safi HJ, Martin TD, Pool JL: The impact of renal fusion and ectopia on aortic surgery. *J Vasc Surg.* 1998, 8:375-383. [10.1016/0741-5214\(88\)90098-5](https://doi.org/10.1016/0741-5214(88)90098-5)
2. Glodny B, Petersen J, Hofmann KJ, et al.: Kidney fusion anomalies revisited: clinical and radiological analysis of 209 cases of crossed fused ectopia and horseshoe kidney. *BJU Int.* 2009, 103:224-235. [10.1111/j.1464-410X.2008.07912.x](https://doi.org/10.1111/j.1464-410X.2008.07912.x)
3. Cortese F, Fransvea P, Marcello R, Saputelli A, Lepre L, Gioffrè A, Sganga G: Challenging case of horseshoe kidney double fracture. *Int J Surg Case Rep.* 2017, 41:158-161. [10.1016/j.ijscr.2017.08.070](https://doi.org/10.1016/j.ijscr.2017.08.070)
4. Taghavi K, Kirpatrick J, Mirjalili SA: The horseshoe kidney: surgical anatomy and embryology. *J Pediatr Urol.* 2016, 12:275-280. [10.1016/j.jpuro.2016.04.033](https://doi.org/10.1016/j.jpuro.2016.04.033)
5. Friedland GW, De Vries P: Renal ectopia and fusion. *Urol.* 1975, 5:698-706. [10.1016/0090-4295\(75\)90137-5](https://doi.org/10.1016/0090-4295(75)90137-5)
6. Sadler TW: *Langman's Medical Embryology.* Lippincott Williams & Wilkins, Baltimore; 2011.
7. Natsis K, Piagkou M, Skotsimara A, Protergerou V, Tsitouridis I, Panagiotis S: Horseshoe kidney: a review of anatomy and pathology. *Surg Radiol Anat.* 2013, 36:517-526. [10.1007/s00276-013-1229-7](https://doi.org/10.1007/s00276-013-1229-7)
8. Voelzke BB, Leddy L: The epidemiology of renal trauma. *Transl Androl Urol.* 2014, 3:143-149. [10.3978/j.issn.2223-4683.2014.04.11](https://doi.org/10.3978/j.issn.2223-4683.2014.04.11)
9. Prakash RP, Pauline HG, Zachary K, Mark I: Trauma to a horseshoe kidney: case report and review of the literature. *UroToday Int J.* 2011, 4:47. [10.3834/uij.1944-5784.2011.08.03](https://doi.org/10.3834/uij.1944-5784.2011.08.03)
10. Gaffney CM: Rupture of horseshoe kidney in a child secondary to blunt abdominal trauma. *Urol.* 1974, 4:446-447. [10.1016/0090-4295\(74\)90017-X](https://doi.org/10.1016/0090-4295(74)90017-X)
11. Abe T, Uchida M, Nagata I, Saitoh D, Tamiya N: Resuscitative endovascular balloon occlusion of the aorta versus aortic cross clamping among patients with critical trauma: a nationwide cohort study in Japan. *Crit Care.* 2016, 20:400. [10.1186/s13054-016-1577-x](https://doi.org/10.1186/s13054-016-1577-x)
12. Dubose JJ, Scalea TM, Brenner M, et al.: The AASST prospective Aortic Occlusion for Resuscitation in Trauma and Acute Care Surgery (AORTA) registry: data on contemporary utilization and outcomes of aortic occlusion and resuscitative balloon occlusion of the aorta (REBOA). *J Trauma Acute Care Surg.* 2016, 81:409-419. [10.1097/TA.0000000000001079](https://doi.org/10.1097/TA.0000000000001079)
13. Ribeiro Junior MWF, Brenner M, Nguyen ATM, Feng CYD, De-Moura RR, Rodrigues VC, Prado RL: Resuscitative endovascular balloon occlusion of the aorta (REBOA): an updated review. *Rev Col Bras Cir.* 2018, 45:1709. [10.1590/0100-6991e-20181709](https://doi.org/10.1590/0100-6991e-20181709)
14. Johnson MA, Davidson AJ, Russo RM, et al.: Small changes, big effects: the hemodynamics of partial and complete aortic occlusion to inform next generation resuscitation techniques and technologies. *J Trauma Acute Care Surg.* 2017, 82:1106-1111. [10.1097/TA.0000000000001446](https://doi.org/10.1097/TA.0000000000001446)
15. Russo RM, Neff LP, Lamb CM, et al.: Partial resuscitative endovascular balloon occlusion of the aorta in swine model of hemorrhagic shock. *J Am Coll Surg.* 2016, 223:359-368. [10.1016/j.jamcollsurg.2016.04.037](https://doi.org/10.1016/j.jamcollsurg.2016.04.037)