

Strategies to successfully complete complex ESD in the colon ▶

OPEN
ACCESS

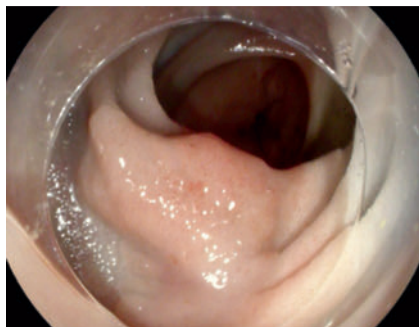
Introduction

Endoscopic submucosal dissection (ESD) is challenging in the colon. Lesions with fibrosis and located in diverticular areas add extra technical difficulty [1, 2, 3].

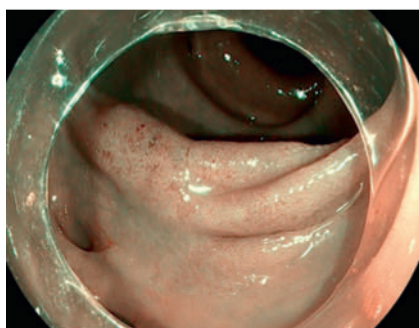
We describe the case of a 71-year-old woman with a sigma 20-mm nongranular, laterally spreading tumor (LST NG) with a type Vi pit pattern and NICE 2, surrounded by diverticula and in contact with a tattoo (▶ **Fig. 1** and ▶ **Fig. 2**). A tattoo close to a lesion can make its resection even harder [4].

Endoscopy

The procedure was performed with a Pentax gastroscope (EPI-i 7010 processor) with a straight cap and a Type-T HybridKnife connected to the ERBEJET system and combined with VIO3 electro-surgery equipment (endoCUT Q and preciseSECT).



▶ **Fig. 1** Lesion.




▶ **Fig. 2** Lesion i-Scan.

Due to the anatomical difficulty and the presence of fibrosis secondary to the tattoo, an immersion dissection with bottled water was performed with creation of a pocket for greater stability and safety. Fibrosis was managed with the knife in "probe mode," which consists of using the knife in a closed position that offers a cutting diameter of 1.5 mm and a cutting depth of 0.5 mm, offering security and precision [5] (▶ **Fig. 3**). The dissection was largely performed in preciseSECT

mode, which offers a perfect balance between cutting ability and hemostasis (▶ **Video 1**).

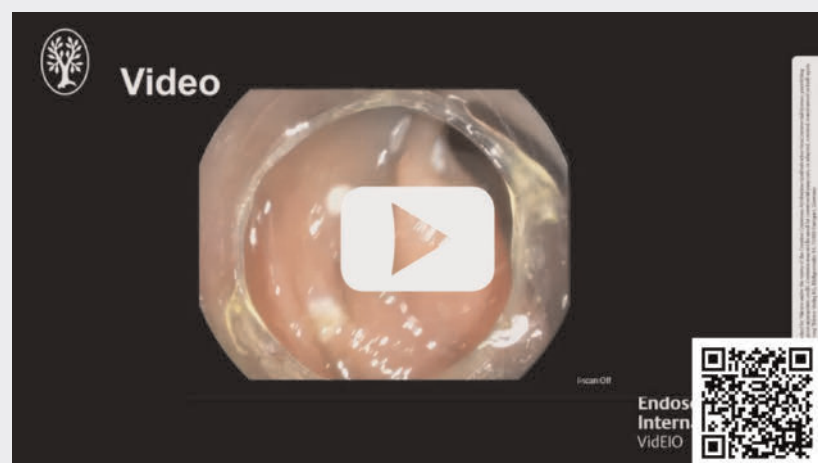
The ESD was performed and an en-bloc specimen measuring 30 × 28 mm was obtained. Histologic examination revealed an adenoma with high-grade dysplasia and extensive areas of intramucosal adenocarcinoma. The lateral and deep margins were disease-free (> 1 mm).

Review 6 months later showed a clean scar with normal biopsies (▶ **Fig. 4**).

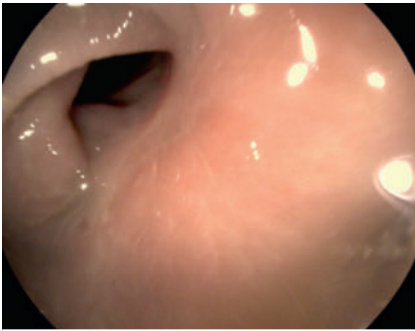

▶ **Fig. 3** The "probe mode". Courtesy of MD, PhD F. Ramos-Zabala.

▶ VIDEO



▶ **Video 1** Complex ESD in colon.



► Fig. 4 Scar at 6 months.

Conclusions

Immersion dissection with pocket creation may be useful when treating challenging lesions. Using the HybridKnife in “probe mode” and preciseSECT is effective and safe in fibrotic areas.

We recommend evaluating the need for tattooing prior to dissection due to the risk of extension into the submucosa with consequent secondary fibrosis.

Conflict of Interest

The authors declare that they have no conflict of interest.

The authors

David Barquero Declara¹, Alex Blasco Pelicano¹, Claudia Berbel Comas¹, Alfredo Mata Bilbao¹

¹ Gastroenterology Unit, Hospital de Sant Joan Despi Moisès Broggi, Sant Joan Despi, Spain

Corresponding author

Dr. David Barquero Declara

Hospital de Sant Joan Despi Moisès Broggi, Gastroenterology, Calle Jacinto Verdaguer 90, 08970 Sant Joan Despi, Spain
david.barquerodeclara@sanitatintegral.org

References

- [1] Ikezawa N, Toyonaga T, Tanaka S et al. Feasibility and safety of endoscopic submucosa dissection for lesions in proximity to a colonic diverticulum. *Clin Endosc* 2022; 55: 1–2
- [2] Muramoto T, Ohata K, Sakai E et al. Endoscopic submucosal dissection for colorectal neoplasms in proximity or extending to a diverticulum. *Surg Endosc* 2021; 35: 3479–3487 doi:10.1007/s00464-020-07795-y32671524
- [3] Jimenez-García VA, Yamada M, Ikematsu H et al. Endoscopic submucosal dissection in management of colorectal tumors near or involving a diverticulum: a retrospective case series. *Endosc Int Open* 2019; 7: E664–E671 doi:10.1055/a-0848-804831061878
- [4] Barquero D, González V, García O et al. Ways to perform an endoscopic tattoo. Prospective and randomized study in patients with colorectal neoplasm. *Rev Esp Enferm Dig* 2021; 113: 519–523
- [5] Ramos Zabala F, García M, Domínguez A et al. Combination of immersion in saline solution, pocket-creation method, water-jet hydrodissection, and hybrid knife “probe mode” simplifies endoscopic submucosa dissection in giant rectal polyp. *VideoGIE* 2019; 4: 478–480

Bibliography

Endosc Int Open 2024; 12: E914–E915

DOI 10.1055/a-2348-8027

ISSN 2364-3722

© 2024. The Author(s).

This is an open access article published by Thieme under the terms of the Creative Commons Attribution-NonDerivative-NonCommercial License, permitting copying and reproduction so long as the original work is given appropriate credit.

Contents may not be used for commercial purposes, or adapted, remixed, transformed or built upon. (<https://creativecommons.org/licenses/by-nc-nd/4.0/>)

Georg Thieme Verlag KG, Rüdigerstraße 14, 70469 Stuttgart, Germany

