



Pediatrics

## Bilateral ureteral triplication: A case report

Irfan Wahyudi<sup>\*</sup>, Muhammad Fahri, Gerhard Reinaldi Situmorang, Arry Rodjani

Department of Urology, Cipto Mangunkusumo General Hospital, Faculty of Medicine, Universitas Indonesia, Jakarta, Indonesia



### ARTICLE INFO

#### Keywords:

Ureteral triplication  
Bilateral  
Laparoscopic  
Ureteral tailoring

### ABSTRACT

Ureteral triplication is among the rarest congenital disorder of the urinary tract. A review of the literature has shown that only about one hundred cases have been reported worldwide. The reports on bilateral ureteral triplication cases, however, are extremely scarce. A female infant was presented with a history of recurrent febrile UTI since birth. Computed tomography scan revealed bilateral ureteral triplication. Combination of contrast studies and endoscopic procedure were utilized to establish the diagnosis. Management for this anomaly varies from conservative to interventional surgery. This patient underwent laparoscopic left ureteroneocystostomy and ureteral tailoring.

### Introduction

In the fourth week of gestational age, ureteric bud arises from the mesonephric duct and contacts nephrogenic blastema. This so-called mesenchymal-epithelial interaction is the state when metanephric mesenchyme induces the ureteric bud to branch and divide. Variation or defect of this branching process will cause some anomalies. Theoretically, if more than one ureteric buds arise, it will result in duplication or triplication of the ureter.<sup>1,2</sup>

Ureteral triplication is one of the rarest congenital disorder of the urinary tract. This anomaly is often associated with other urinary tract anomalies. A search of the literatures has shown that only about one hundred cases have been reported worldwide.<sup>1,2</sup> The published reports on bilateral ureteral triplication cases is even more scarce.

#### Case presentation

A ten-month-old female infant was presented to our clinic with a chief complaint of cloudy urine. She had a history of recurrent febrile urinary tract infection since birth, and she was given prophylactic antibiotics. Her parents also noticed the presence of rash around the patient's groin from exposure to urine due to continuous urinary incontinence. Urine culture confirmed the presence of *Klebsiella pneumoniae* colonization.

Ultrasound (US) examination showed the presence of left hydronephrosis with tortuous hydroureter. There were no abnormal findings on the right kidney and bladder from ultrasound. Computed tomography

(CT) scan urography revealed a bilateral triple collecting system with dilatation of the left pelvicalyceal system (Fig. 1). Further examination by renal scan showed a decreased function of the left kidney with a split function of 28%.

Voiding cystourethrogram (VCUG) revealed left grade 5 vesicoureteral reflux (VUR), marked by a tortuous ureter and dilatation of all kidney poles. Cystoscopy and bilateral retrograde pyelography (RPG) confirmed the presence of bilateral ureteral triplications. On the right side, we found triple ureters which joined into two ureteral orifices in the bladder. This is in accordance with type 2 Smith's classification. On the left side, triple ureters which confluence into a single ectopic ureter and drain into the urethra below the bladder neck. This is in accordance with type 3 Smith's classification (Figs. 2 and 3A).

We decided to perform laparoscopic left ureteroneocystostomy and ureteral tailoring. The left ectopic ureter was freed from surrounding tissue meticulously and was incised as distally as possible. The tortuous ureter was then tailored using extracorporeal methods (Fig. 3B and C). A 4.7 Fr. double J stent was inserted into the trimmed ureter. Subsequently, the ureter was brought back inside the body and reimplanted to the bladder using Lich-Gregoir extravesical technique. After surgery, patient had no clinical signs and symptoms (no urinary leaks, no episode of UTI) in the absence of prophylactic antibiotics. Hydronephrosis was resolved during one-year ultrasound evaluation.

### Discussion

Ureteral triplication may be responsible for repeated UTI,

<sup>\*</sup> Corresponding author. Jalan Diponegoro No. 71, Kenari, Senen, Jakarta, Indonesia.

E-mail addresses: [irf.wahyudi2011@gmail.com](mailto:irf.wahyudi2011@gmail.com) (I. Wahyudi), [fahri.al.kaff.84@gmail.com](mailto:fahri.al.kaff.84@gmail.com) (M. Fahri), [gr.urorscm@gmail.com](mailto:gr.urorscm@gmail.com) (G.R. Situmorang), [arry\\_rodjani@yahoo.com](mailto:arry_rodjani@yahoo.com) (A. Rodjani).

<https://doi.org/10.1016/j.eucr.2020.101406>

Received 22 August 2020; Received in revised form 5 September 2020; Accepted 8 September 2020

Available online 10 September 2020

2214-4420/© 2020 The Authors.

Published by Elsevier Inc.

This is an open access article under the CC BY-NC-ND license

(<http://creativecommons.org/licenses/by-nc-nd/4.0/>).

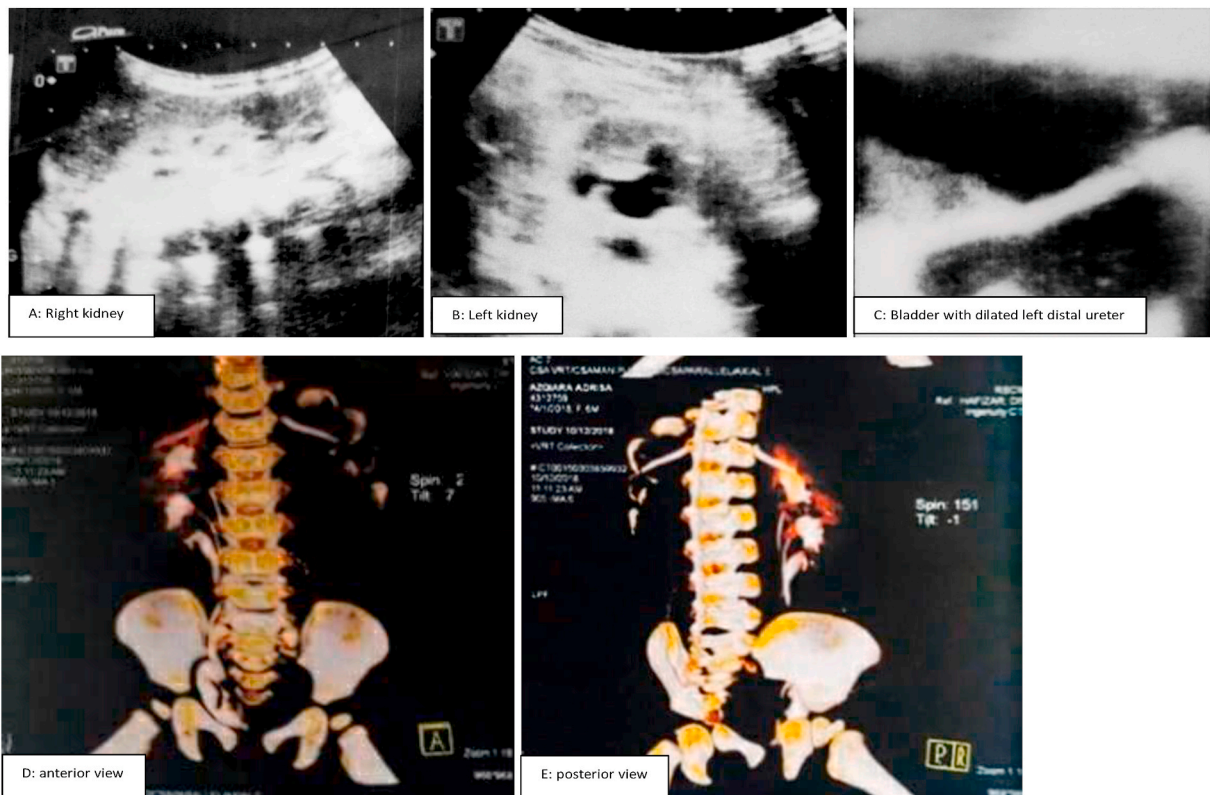


Fig. 1. Pictures of kidney-bladder ultrasound (A–C) and CT urography (D, E). Note the hydronephrosis of the left kidney and tortuous of the ureter until distal side on ultrasound and bilateral triple ureters on CT scan.

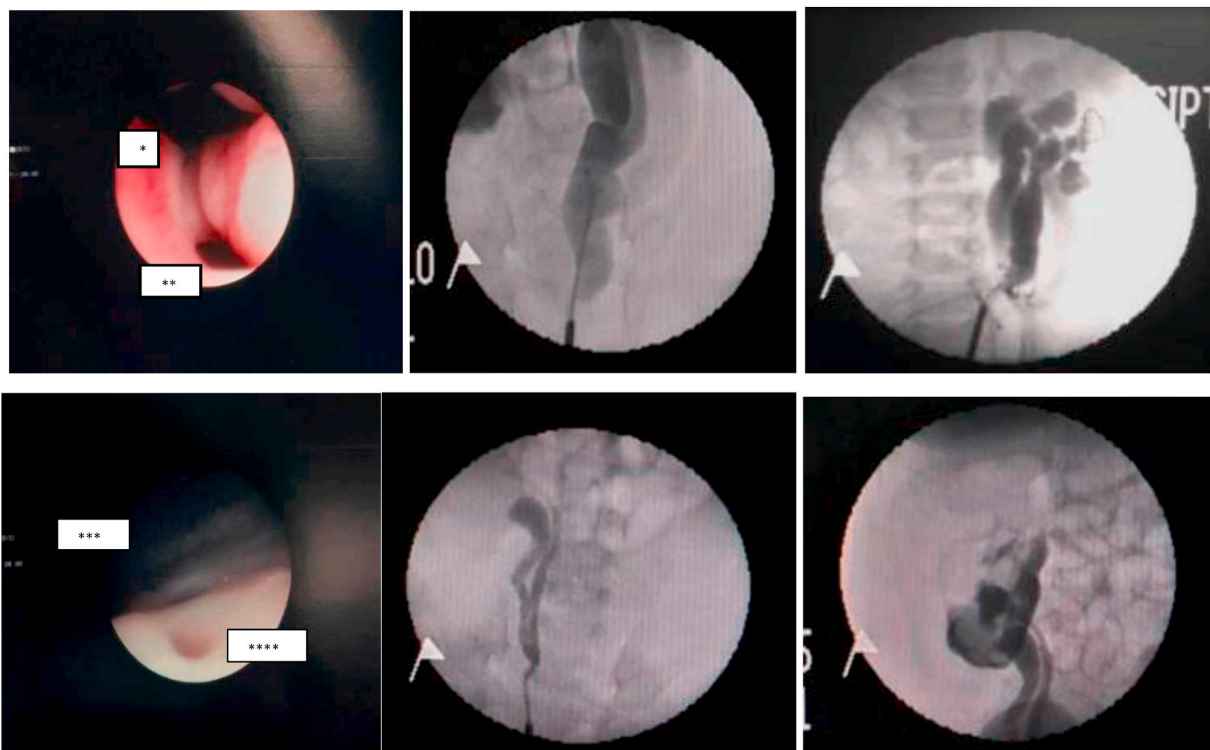
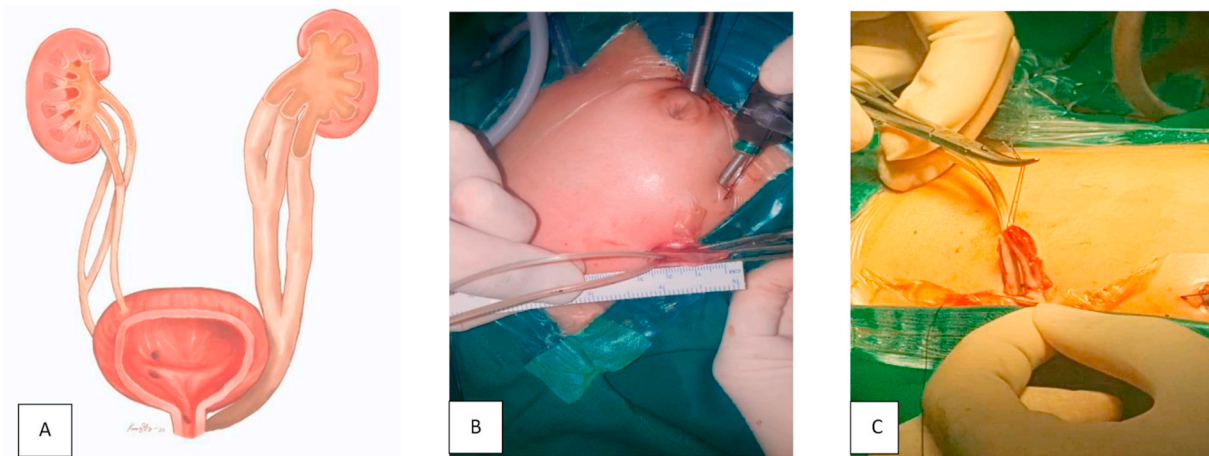


Fig. 2. Upper row pictures: cystoscopy and left retrograde pyelography appearance (\*: bladder neck, \*\*: left ectopic ureter orifice). Contrast showed the feature of one ureter came from orifice which then branched to triple ureters proximally. Lower row pictures: cystoscopy and right retrograde pyelography appearance (\*\*\*: upper ureter orifice, \*\*\*\*: lower ureter orifice). Contrast showed the feature of two ureters came from two different orifice. The ureter from upper orifice position then branched into two ureters proximally.



**Fig. 3.** Schematic illustration of bilateral triplication in our case (A). Laparoscopic Lich-Gregoir extravesical ureter reimplantation (B, C). The tortuous ureter with 2.5 cm in circumference was tailored using extracorporeal technique.

incontinence, or discomfort, but this condition is mostly asymptomatic.<sup>1</sup> In our case, the presence of recurrent UTI and continuous urinary incontinence were caused by the ectopic left ureter orifice, which was located below the bladder neck.

According to Smith's classification, the triplication of the collection system is anatomically divided into four types<sup>3</sup>: (1) triple ureters or complete triplication (35%), (2) incomplete triplication where two out of the three ureter joins on their course to the bladder, resulting in two orifices present in the bladder (21%), (3) trifid ureters which unite and drain through a single orifice (31%), and (4) double kidney ureters with one bifurcation as an inverted Y draining into three orifices (9%). In this case, we found two different types of ureteral configuration: type 2 on the right side and type 3 on the left.

Confirming the diagnosis of ureteral triplication requires thorough investigations, which include laboratory examination, US, nuclear renal scan, and contrast study (intravenous urography, CT or MR urography and VCUG).<sup>1,3</sup> Urethrocytoscopy and RPG are essential to accurately examine the configuration of ureteral triplication, especially in patients with impaired kidney functions.

Ureteral triplication was also associated with other urinary tract anomalies. Contralateral ureter duplication (37%), ectopic ureter (28%), and renal dysplasia (8%) are among the most commonly cases associated with this condition.<sup>2</sup> Occasionally, ureterocele, VUR, syndactyl, angiomas, or sex organ malformation could also be found.<sup>2,4</sup> In this case, ectopic ureter and VUR were found on the left ureter. These anomalies became predisposing factors for recurrent febrile UTI and impaired her left kidney function.

Laparoscopic approach was chosen in this case due to its minimum complication rate and prompt recovery. The ureteral tailoring was

implemented using extracorporeal methods introduced by Ansari MS et al.<sup>5</sup> This procedure provides ease in tailoring technique and offered promising result; thus, its potential should be explored further to its application. Albeit it should be noted that laparoscopic procedure in infants requires a steep learning curve and routine performance to achieve proficiency. At present, open surgery is more widely accepted and performed in this rare case.

## Conclusion

A bilateral triple collecting system is a rare anomaly of the urinary tract. Contrast study combined with endoscopic procedure was the mainstay of diagnosis. Other associated anomalies should be anticipated in this case. Management for this anomaly varies from conservative treatment in asymptomatic patient to interventional surgery in patient with symptoms or deteriorating kidney function.

## References

1. Al-Zubi M, Al Faqieh A, Altamimi O, Albeitawi S. Unilateral triplicate ureter with ipsilateral ureterocele a case report. *Int. J. Surg. Case Rep.* 2020;70:178–181.
2. Pejovic T, Acimovic M, Dzamic Z, Maksimovic H, et al. Bilateral triple renal pelvis: a case report. *Vojnosanit Pregl.* 2015;72(2):185–187.
3. Alhajri F, Ammar Al-Jumah A, Al-Mutawa S. Ureteral triplication with a contralateral duplication and ureterocele: a case report. *Cases Journal.* 2009;2:7510.
4. Kokabi N, Price N, Smith GHH, Gibbons PJ, Holland AJA. Ureteral triplication: a rare anomaly with a variety of presentations. *J Pediatr Urol.* 2011;7(4):484–487.
5. Ansari MS, Mandhani AA, Khurana N, Kumar A. Laparoscopic ureteral reimplantation with extracorporeal tailoring for megaureter: a simple technical nuance. *J Urol.* 2006; 176:2640–2642.