

# Coronary angiography using the left distal radial approach - An alternative site to conventional radial coronary angiography

Elton Soydan, Mustafa Akın

Department of Cardiology, Faculty of Medicine, Ege University; İzmir-Turkey

## ABSTRACT

**Objective:** To share our experience with the left distal radial approach for transradial coronary angiography and interventions. By performing the radial puncture in the fossa radialis or the so called anatomical "Snuffbox" we aimed to present the feasibility and complications of this new technique.

**Methods:** Left distal radial artery was used as an access site in 54 patients admitted to our clinic for coronary angiography and intervention between May 25<sup>th</sup> and October 20<sup>th</sup> 2017. All of them had pulse in their left distal radial artery. In the laboratory, they had their left arm gently flexed at the shoulder so that the hand was placed over their right groin. The operator stood on the right side of the patient and performed coronary angiography and interventions. During the hospital stay, demographic features and complications were recorded.

**Results:** Mean age of patients was 59.3 years and 80% were male. We used Judkins 6 French catheters for the procedures. Seventeen patients admitted with acute coronary syndrome. They all underwent successful left distal transradial coronary angiography and intervention. Primary angioplasty was performed in 10 patients. In total, 20 patients had coronary intervention. Left anterior descending artery was the artery requiring most intervention (11 patients). Two patients experienced brachial spasm requiring crossover to right femoral artery. There were no cases of radial artery occlusion, hematoma, or hand numbness. The radial sheath was removed at procedure termination. Hemostasis was achieved with manual compression.

**Conclusion:** Left distal radial approach is safe and feasible as a new technique for coronary angiography and interventions.  
(*Anatol J Cardiol* 2018; 19: 243-8)

**Keywords:** left distal radial artery, transradial coronary angiography, fossa radialis, anatomical snuffbox

## Introduction

Cardiac catheterization has continually evolved since the first procedure in 1929 (1). Improvement in technology and understanding the anatomic features of the vascular system, have lead to new insights in coronary angiography procedures. With regard to arterial access sites, much research has been devoted to determine which access site is best suited for particular patients and circumstances. In spite of the ease of access of femoral artery for coronary angiography, vessel-related complications and bleeding have given rise to increased morbidity, mortality, and hospital stay, particularly when anticoagulation and antiplatelet therapy are administered (2, 3). The femoral approach has been compared with radial approach for both coronary angiography and interventional procedures in multiple randomized and observational studies. Increased safety and patient comfort with reduction of bleeding complications and im-

mediate postprocedural mobilization were found as the major advantages of radial access (4, 5). On the basis of the results of these randomized studies, transradial access is considered as the default technique for coronary access (6, 7). Most operators prefer the right radial artery, as they work on the right side of the patients. However, right radial artery occlusion, underdeveloped right radial artery, extreme tortuosity, sclerosis, calcifications, arteria lusoria, past or future use of right radial artery as free arterial graft make the operators choose the left radial artery. Left radial artery catheterization shows similar anatomic course with transfemoral approach and is appropriate for post coronary artery bypass grafting patients requiring left internal mammary artery angiography. Moreover, left radial access is the preferred site for right handed patients because of temporary postprocedural disability caused by hemostasis process in right radial artery access (8). From the other hand, left radial access can be somewhat difficult for the operator as he should bend over

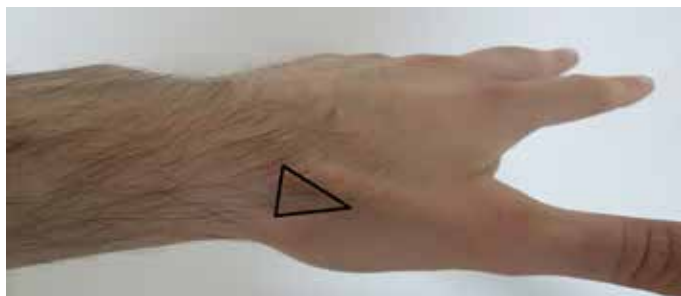This study was presented as an oral presentation in the 33<sup>rd</sup> Turkish Cardiology Congress on October 6<sup>th</sup> 2017.

**Address for correspondence:** Dr. Elton Soydan, Ege Üniversitesi Tıp Fakültesi, Kardiyoloji Anabilim Dalı, İzmir-Turkey  
Phone: +90 507 455 66 32 Fax: +90 232 390 32 87 E-mail: eltonsoydan@hotmail.com

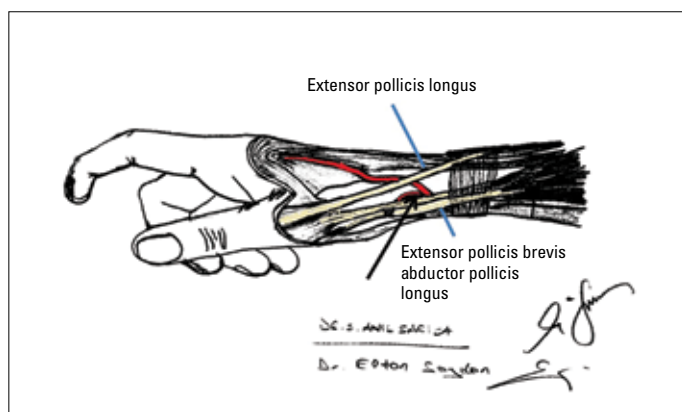
**Accepted Date:** 15.02.2018 **Available Online Date:** 25.03.2018

©Copyright 2018 by Turkish Society of Cardiology - Available online at [www.anatoljcardiol.com](http://www.anatoljcardiol.com)  
DOI:10.14744/AnatolJCardiol.2018.59932



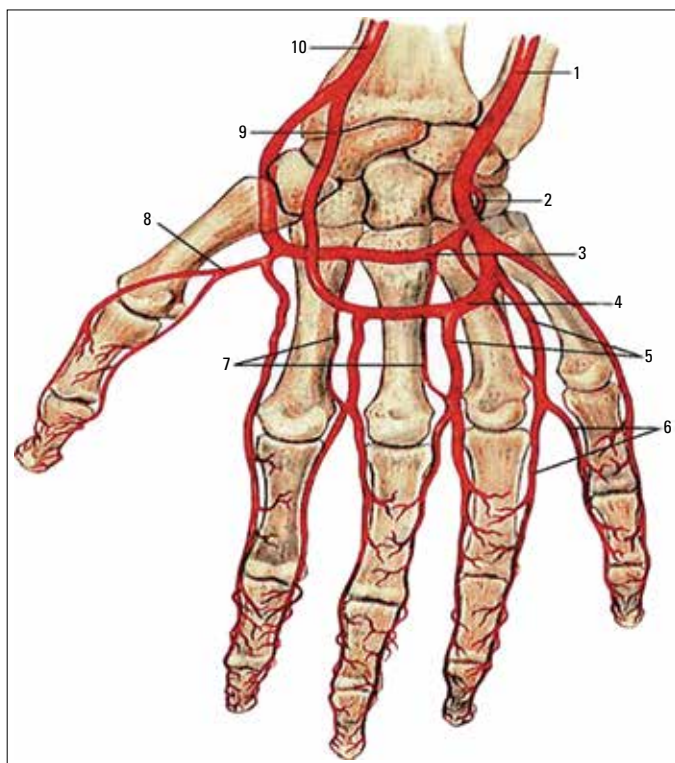


**Figure 1.** The left anatomical snuffbox (triangular area) surrounded on the palmar side by the tendons of abductor pollicis longus and extensor pollicis brevis muscles, and on the dorsal side the tendon of extensor pollicis longus muscle



**Figure 2.** Catheterization site in the anatomical snuffbox surrounded by the tendons of extensor pollicis longus, extensor pollicis brevis, and abductor pollicis longus muscle. Black arrow shows the radial artery segment where the puncture is performed

the patient to introduce the sheath to the left radial artery. This unpleasant position could make the catheterization procedure inconvenient and perhaps crossover to another artery access site. An alternative way to have a comfortable position for both the patient and the operator is access the left distal radial artery located in the anatomical snuffbox or "fossa radialis" on the dorsal side of the hand. Anatomical snuffbox (AS) is a depression space located in the radial part of the wrist. It shows up when the thumb is extended. It is surrounded laterally by the tendons of abductor pollicis longus and extensor pollicis brevis muscles and medially by the tendon of extensor pollicis longus muscle. The base and the lateral sides of this triangular structure are formed by the distal retinaculum of extensor muscles and attachment of the tendons of extensor pollicis longus and extensor pollicis brevis muscles respectively (Fig. 1, 2). The distal radius, scaphoid, trapezium and the base of the first metacarpal bone form the base of this triangular area (9). The distal part of the radial artery passes in a deep fashion through AS. Distally it continues as the deep palmar branch of the radial artery and joins the distal part of the ulnar artery, thus forming the deep palmar arch of the hand (Fig. 3). The distinctive feature of this arterial segment is its location distally to the superficial palmar branch of radial artery that joins the superficial palmar arch. There are



**Figure 3.** Blood vessels of the distal forearm and hand. 1 - ulnar artery; 2, 3 - deep palmar branch of radial artery; 4, 9 - superficial palmar arch; 5 - digital arteries; 8 - artery of the thumb; 10 - radial artery

collateral vessels communicating between the palmar arches. If any occlusion at the AS site occurs, tissue ischemia is prevented because of the maintenance of antegrade flow through the superficial palmar arch and the communicating collaterals (10). In consideration of these anatomic and physiological features we aimed to describe our experience, feasibility and complications with this new access site for transradial coronary angiography and interventions.

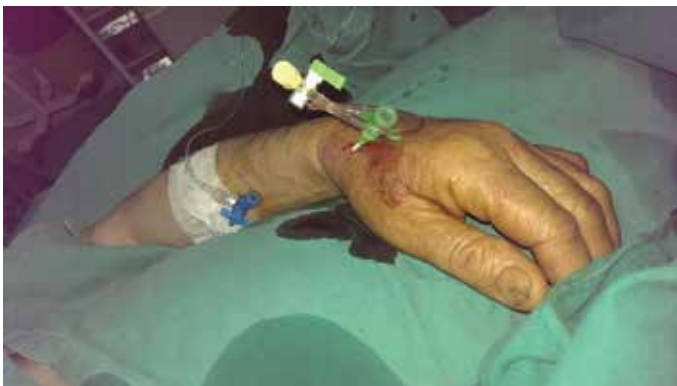## Methods

Left distal radial artery access site was used in 54 patients admitted to our clinic for coronary angiography and intervention between May 25<sup>th</sup> and October 20<sup>th</sup> 2017. Our study was designed in a prospective according to the principles of the declaration of Helsinki and got approval by the Local Ethics Committee. All patients had a palpable arterial pulse in their AS area. In the catheterization laboratory after disinfection with povidone iodine the patients left hand was bent toward their right groin. Then their left hand was slightly abducted with the thumb underneath the other four fingers, thus making the fossa radialis more prominent. The operator was positioned at the right side of the patients preparing for left distal radial artery puncture. After 2 mL of 2% Prilocain over AS, the left distal radial artery access was achieved with a 21 gauge open needle. Successful puncture was followed by an insertion of 0.018-inch straight guidewire with a

**Table 1. Demographic features of study population**

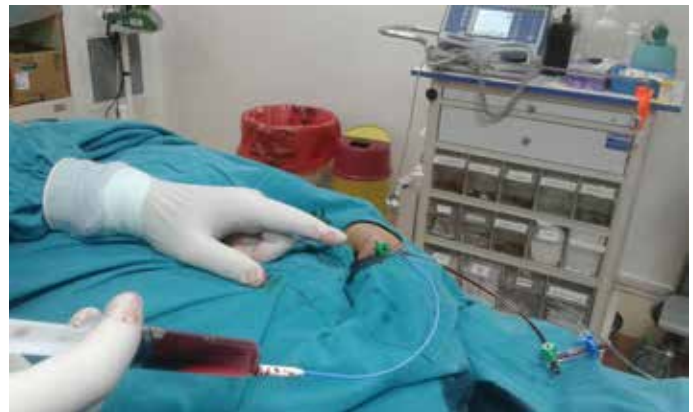Demographic parameters	Mean±SD (min.-max.)
Age	59.3±11.9 (30-79)
Length (cm)	170.72±6.226 (150-187)
Weight (kg)	81.48±10.024 (57-110)
Hospital stay (days)	3.71±3.938 (0-20)
LVEF	0.52±0.083 (0.37-0.60)
	<b>n=54 (%)</b>
Male	43 (80%)
Female	11 (20%)
DM	18 (33.3%)
HT	33 (61.1%)
Smoking	14 (26%)
AF	4 (7.4%)
Chronic CAD	19 (35%)
New onset CAD	23 (42%)

AF - atrial fibrillation; CAD - coronary artery disease; cm - centimeters; DM - diabetes mellitus; HT - hypertension; kg - kilogram; LVEF - left ventricle ejection fraction; min - minimal; max - maximal; n - number of patients; SD - standard deviation



**Figure 4.** The introduction of 6 French hydrophilic radial sheath into the left distal radial artery in the anatomical snuffbox

soft, flexible proximal part and a rigid distal part. Then a 6 French radial hydrophilic sheath (Prelude Ease, Merit Medical) was introduced into the left distal radial artery and a cocktail of 2500 units of unfractionated heparin, 200 mcg of nitrate and serum physiological was administered to all patients to prevent radial spasm (Fig. 4). In case of interventions being performed, heparin dose was adequately adjusted. Calcium-channel blockers and sedative therapy was not administered. After flushing the radial sheath, the operator on the right side (groin) of the patient would begin the transradial coronary angiography or intervention (Fig. 5). Judkins catheters (6-French diameter and 4-cm curvature distance) were used in all patients. The advancing of the catheters was achieved by 0.032 inch J-tipped wire. At procedure termination, the radial sheath was pulled out and early hemostasis was obtained by compression with the thumb of the assistant for



**Figure 5.** Operator on the right side of the patient performing coronary angiography with left distal radial access

approximately 15 min then a slightly compressive bandage with gauze was applied over the access site for complete hemostasis for 3 h. The left radial artery pulse at the forearm and at AS was checked by palpation after the procedure and at discharge day.

## Results

We had 54 patients assigned to our operating program from May 25<sup>th</sup> and October 20<sup>th</sup> 2017 who had normal pulse in their forearm and left AS. Demographic and procedural features are shown in Tables 1 and 2. There was a young population group with a mean age of 59.3 years and male predominance of 80%. Hypertension and diabetes mellitus were the most frequent risk factors for cardiovascular disease, with rates of 61.1% and 33.3% respectively. Seventeen patients were admitted to our clinic with acute coronary syndrome. Four of them had anterior ST elevation myocardial infarction (STEMI). Inferior STEMI was diagnosed in six patients. The other six patients presented with non-STEMI, and the last one referred with unstable angina pectoris. In total we had 20 angioplasty procedures, among which half were primary coronary interventions. Patients undergoing primary angioplasty were in a preserved functional capacity with no heart failure symptoms. The left anterior descending artery was the most frequently stented artery (20.3%). Approximately 11.1% and 5.5% patients, respectively, underwent angioplasty with stenting in the right coronary artery and the left circumflex artery. The left distal radial artery access was successful in all patients. We encountered brachial artery spasm in two patients, and both had a tortuosity in the brachial artery silhouette identified thanks to the shape of the guidewire. This made advancing the catheters impossible, and we decided to continue the procedure with the right femoral artery approach as the patients anxiety increased. Mean time to puncture of artery was 1.19 min. Mean fluoroscopy time was assessed as 9.7 min. Catheters used for diagnostic and interventional procedures were Judkins 6 French with a 4-cm curvature for all patients. Patients felt little discomfort or pain at access site during coronary angiography or during intervention.

**Table 2. Procedural features of patients undergoing left distal transradial coronary angiography and interventions**

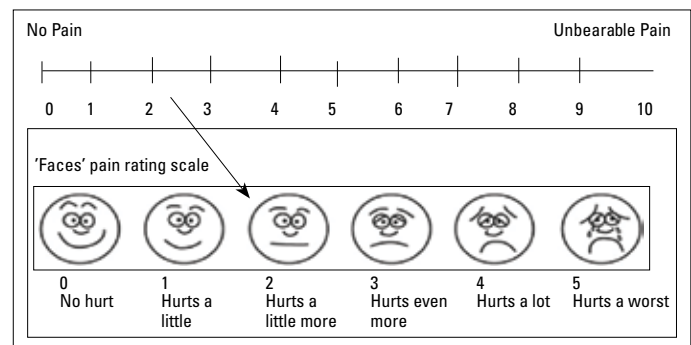
Procedural features	n=54 (%)
Radial sheath (6 French)	54 (100%)
Judkins catheters	54 (100%)
Acute coronary Syndrome	17 (31.4%)
Anterior STEMI	4 (7.4%)
Inferior STEMI	6 (11.1%)
Non-STEMI	6 (11.1%)
UAP	1 (1.8%)
Angioplasty	20 (37%)
Primary coronary intervention	10 (18.5%)
Right coronary intervention	6 (11.1%)
Left anterior descending intervention	11 (20.3%)
Left circumflex artery intervention	3 (5.5%)
Brachial artery spasm /	2 (3.7%)
Radial occlusion	0
Crossover to femoral artery	2 (3.7%)
Hematoma	0
Numbness	0
Left arm movement disability	0
<b>Mean±SD</b>	
Artery puncture time	1.19±0.94
Fluoroscopy time	9.6±7.1 (1.2-40.1)
Radiation exposure (Total air kerma: mGy)	951.6±656.2 (160.8-2485)
Radiation exposure (Total dose area product: µGy·m <sup>2</sup> )	7380.4±4524.6 (1453.2-16796.2)

n - number of patients; SD - standard deviation; STEMI - ST elevation myocardial infarction

None of the patients experienced any radial artery occlusion or hematoma at their left forearm and AS. Left radial artery pulse was found in a bounding strength (grade 4) both at the forearm and at the fossa radialis both after complete hemostasis was achieved in 3 h as well as at discharge. No numbness or movement disorder of the hand was observed. Four patients were discharged on the same day after their coronary angiography showed no atherosclerotic lesions. The mean hospital stay was 3 days.

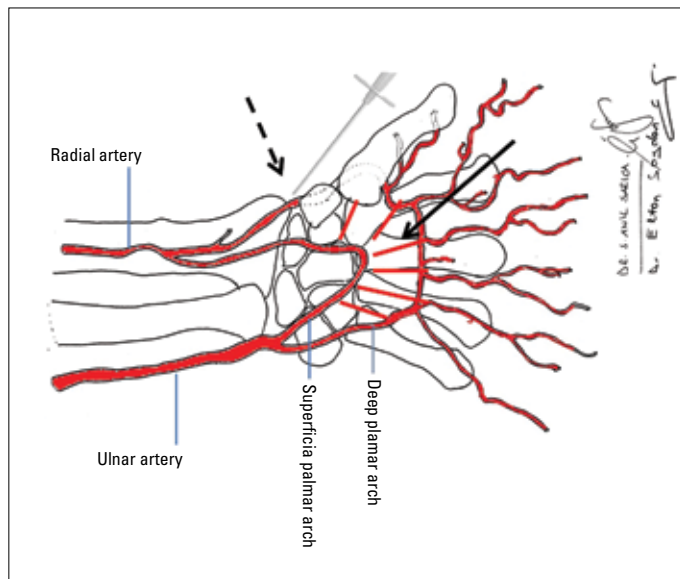
## Discussion

Our first and new experience with an approach through the left distal radial artery for coronary angiography and intervention demonstrates its feasibility as a safe access site. First of all, the left radial artery access is more compatible than the right radial artery, because the anatomy of the radial-aortic passage resem-



**Figure 6.** Visual analog scale: Pain describing visual scale during left distal transradial coronary angiography

bles that of the femoral–aortic passage. Hence, advancing of the catheters and anchoring at the coronary ostiums is easier from the left radial artery than from the right radial artery (11). Most of the population is right handed. With this technique, operators have the chance to use the left hand as an access site by not restricting the right hand after the procedure, especially for people with professions requiring right hand dexterity (mechanic, musician, etc.). However, bending of the operator over the patient toward his or her left arm makes the procedure inconvenient and disturbing, especially in obese patients. So, the left distal radial artery access in AS provides advantages for both the patient and the operator. The patient’s left arm was positioned over his/her abdomen toward the right groin with no need of any support. A hydrophilic radial sheath of 6 French (Prelude Ease; Merit Medical) was successfully introduced in all patients. Kaledin et al. (12) showed that the left distal radial artery diameter was 2.4 mm, and the most used radial introducer was 6 French in 98.4%; this shows that our radial introducer selection was appropriate with the left distal radial artery in AS. In addition, we did not experience any resistance advancing the guidewire and the 6 French catheters through the introduced sheath in AS, meaning that the angle of the introduced sheath was coaxial with the forearm left radial artery. One of the features of this new technique, encouraging us to continue using it, was its ease of access. Especially in patients with acute coronary syndrome, the ease of access provided more confidence toward contemplating the intervention. However, all these patients were in KILLIP class I, with no decompensation signs; so we had more confidence choosing the left distal radial artery as the site for arterial access. In total, the visual analog scale score was low (2). Although it is not an objective scale, it showed that the patients were comfortable during the procedure (Fig. 6). The most painful step was the insertion of the 6 French hydrophilic radial sheath into the left distal radial artery; after that, no discomfort was felt by the patients. This is an important point because inside AS, there are many structures passing together from this constricted triangular area that have to be considered. Regarding the size of AS, the length and width of AS was found on average as 6 and 1.5 cm, respectively (13). Various authors described in their studies and anatomical books that left distal radial artery traversed through the base of AS and



**Figure 7.** Puncture needle in the anatomical snuffbox (dotted arrow). Straight black arrow depicting the collaterals between the superficial and deep palmar arch

penetrated deeply to the tendons of the abductor pollicis longus and extensor pollicis brevis muscles (9). It then continues as the deep palmar branch of the radial artery, which connects with the ulnar artery, thus forming the deep palmar arch of the hand (12). In an anatomical study, Robson et al. (14) found that the superficial branch of the radial nerve was closely related (2 mm) to the radial artery and the cephalic vein in AS. We did not encounter any neurological deficit after the procedure, and studies assessing this technique supported our findings (8, 12). The proximity between the vascular and neural structures in AS should be considered, because multiple puncture attempts at this site can lead to injury of the peripheral nerves, artery aneurysm, arteriovenous fistulas, and thrombosis (9). Post-catheterization radial artery occlusion is the most common complication during the transradial coronary angiography, and it is reported to be 1%-10% in patients undergoing catheterization (15). Relatively high rates of this complication encouraged us to utilize the left distal radial artery as the access site. We did not encounter any absence of pulsation in the left forearm and AS. The pulse at both the left radial artery and at the AS area was in a bounding strength (grade 4), that convinced us not to perform any arterial Doppler ultrasonography. Although the occlusion ratio at this access site is reported to be 2.2%, the hand will not be influenced. This is because the radial portion in AS is a segment distal from the origin of the superficial palmar arch as well as antegrade blood flow through the superficial palmar arch would still continue without any dysregulation (12). In addition, multiple collateral vessels communicating between the superficial and deep palmar arches act as salvage artery vessels if any occlusion occurred in the hand artery circulation (Fig. 7) (16). From this anatomic and physiological evaluation of the palmar arches, it is not expected any forearm radial artery occlusion and this supports all the studies examining this new access site. This can be a

safe way for multiple transradial coronary procedures or coronary bypass surgery with use of a free radial artery graft. Early hemostasis control was immediately achieved in 15 min, regardless of the administered anticoagulation dose. Moreover, complete hemostasis was achieved in almost 3 h with a slightly compression bandage with gauze applied over AS. As the left distal radial artery passes over a bony basement, compression with the thumb over that area can lead to arterial occlusion. Hence, we decided to apply it just for 15 min. No hematoma in the study population shows that the access site is safe in terms of hemorrhagic complications, and this is supported by other studies (8, 12). The easy and feasibility of this new radial approach should be kept in mind to prevent radial artery occlusion, radial artery spasm, and extended procedure times.

### Study limitations

The left distal radial artery is the arterial segment that is a continuation of the forearm radial artery. Its puncture can be challenging as its diameter is smaller than the radial artery. Its access requires a learning curve, especially when the pulse in AS is weak or not felt at all. We experienced difficulty in patients who had a prominent left radial styloid process and a small AS area. Although there is bounding pulse in that area, we had to try a few times to puncture the artery. On the other hand, variations in the palmar arches can lead to perfusion compromise of the hand after the procedure (17). The incomplete superficial arch was found to have a low incidence of 18% (18). These congenital variations do not increase the complication risk over the left distal radial artery catheterization. In addition, it seems that the contemporary rich collateral vessels assuring blood perfusion can adequately maintain normal blood circulation to the hand. We did not need to perform duplex ultrasonography in any patient as we found a bounding pulse in the AS area in all while checking for hemostasis on the discharge day. Although patients did not state any complaint, thrombotic complications might have been missed. Although our study has only a small population group, it showed favorable results in terms of patient and operator comfortability, which was in concordance with other studies (8, 12).

### Conclusion

Left distal radial artery access technique is feasible and safe for coronary angiography and interventions. It merits consideration regarding proper patient selection, preparation, and equipment for successful transradial catheterization.

**Acknowledgements:** We want to thank Dr. Anil Sarica for his special contribution in drawing original pictures Figure 2 and Figure 7.

**Conflict of interest:** None declared.

**Peer-review:** Externally peer-reviewed.

**Authorship contributions:** Concept – E.S.; Design – E.S., M.A.; Supervision – M.A.; Materials – E.S., M.A.; Data collection &/or processing – E.S., M.A.; Analysis &/or interpretation – E.S., M.A.; Literature search – E.S.; Writing – E.S.; Critical review – E.S., M.A.

## References

1. Mueller RL, Sanborn TA. The history of interventional cardiology; cardiac catheterization, angioplasty and related interventions. *Am Heart J* 1995; 129: 146-72.
2. Brueck M, Bandorski D, Kramer W, Wieczorek M, Höltgen R, Tillmanns H. A randomized comparison of transradial versus transfemoral approach for coronary angiography and angioplasty. *JACC Cardiovasc Interv* 2009; 2: 1047-54.
3. Cantor WJ, Puley G, Natarajan MK, Dzavik V, Madan M, Fry A, et al. Radial versus femoral access for emergent percutaneous coronary intervention with adjunct glycoprotein IIb/IIIa inhibition in acute myocardial infarction-- the RADIAL-AMI pilot randomized trial. *Am Heart J* 2005; 150: 543-9.
4. Jolly SS, Yusuf S, Cairns J, Niemelä K, Xavier D, Widimsky P, et al; RIVAL trial group. Radial versus femoral access for coronary angiography and intervention in patients with acute coronary syndromes (RIVAL): a randomised, parallel group, multicentre trial. *Lancet* 2011; 377: 1409-20.
5. Valgimigli M, Gagnor A, Calabró P, Frigoli E, Leonardi S, Zaro T, et al; MATRIX Investigators. Radial versus femoral access in patients with acute coronary syndromes undergoing invasive management: a randomised multicentre trial. *Lancet* 2015; 385: 2465-76.
6. Kiemeneij F, Laarman GJ, Odekerken D, Slagboom T, van der Wieken R. A randomized comparison of percutaneous transluminal coronary angioplasty by the radial, brachial and femoral approaches: the access study. *J Am Coll Cardiol* 1997; 29: 1269-75.
7. Agostoni P, Biondi-Zoccai GG, de Benedictis ML, Rigattieri S, Turri M, Anselmi M, et al. Radial versus femoral approach for percutaneous coronary diagnostic and interventional procedures; Systematic overview and meta-analysis of randomized trials. *J Am Coll Cardiol* 2004; 44: 349-56.
8. Kiemeneij F. Left distal transradial access in the anatomical snuff-box for coronary angiography (IdTRA) and interventions (IdTRI). *Euro Intervention* 2017; 13: 851-7.
9. Cerda A, del Sol M. Anatomical snuffbox and its clinical significance. A literature review. *Int J Morphol* 2015; 33: 1355-60.
10. Doscher W, Viswanathan B, Stein T, Margolis IB. Hemodynamic assessment of the circulation in 200 normal hands. *Ann Surg* 1983; 198: 776-9.
11. Shah RM, Patel D, Abbate A, Cowley MJ, Jovin IS. Comparison of transradial coronary procedures via right radial versus left radial artery approach: A meta-analysis. *Catheter Cardiovasc Interv* 2016; 88: 1027-33.
12. Kaledin AL, Kochanov IN, Podmetin PS, Seletsky SS, Ardeev VN. Distal radial artery in endovascular interventions. Distal radial artery in endovascular interventions (p.) 2017. Unpublished. <https://doi.org/10.13140/rg.2.2.13406.33600>.
13. Tubbs RS, Salter EG, Oakes WJ. The tabatière anatomique. *Clin Anat* 2006; 19: 299-303.
14. Robson AJ, See MS, Ellis H. Applied anatomy of the superficial branch of the radial nerve. *Clin Anat* 2008; 21: 38-45.
15. Gupta S, Nathan S. Radial Artery Use and Reuse. *Cardiac Interventions Today* 2015; 49-56.
16. McLean KM, Sacks JM, Kuo YR, Wollstein R, Rubin JP, Lee WP. Anatomical landmarks to the superficial and deep palmar arches. *Plast Reconstr Surg* 2008; 121: 181-5.
17. Loukas M, Holdman D, Holdman S. Anatomical variations of the superficial and deep palmar arches. *Folia Morphol (Warsz)* 2005; 64: 78-83.
18. Joshi SB, Vatsalaswamy P, Bahetee BH. Variation in formation of superficial palmar arches with clinical implications. *J Clin Diagn Res* 2014; 8: AC06-9.