



NOTE

Surgery

Fluoroscopic observation of the development of displaced abomasum in dairy cows

Megumi ITOH¹⁾, Takahiro AOKI¹⁾, Yoshie SAKURAI²⁾, Naoki SASAKI¹⁾, Hisashi INOKUMA¹⁾, Satoshi KAWAMOTO³⁾* and Kazutaka YAMADA⁴⁾

¹⁾Department of Clinical Veterinary Medicine, Obihiro University of Agriculture and Veterinary Medicine, Inada, Obihiro, Hokkaido 080-8555, Japan

²⁾Animal Research Center, Hokkaido Research Organization, Sintoku, Hokkaido 081-0038, Japan

³⁾School of Veterinary Medicine, Rakuno Gakuen University, 582 Midorimachi, Bunkyodai, Ebetsu, Hokkaido 069-8501, Japan

⁴⁾Laboratory of Veterinary Radiology, School of Veterinary Medicine, Azabu University, Fuchinobe, Chuoku, Sagami-hara, Kanagawa 252-5201, Japan

ABSTRACT. To clarify the mechanisms underlying the development of displaced abomasum (DA), we repositioned DA in 12 cows by rolling and observed the course of redispacement using X-ray fluoroscopy. Displacement of the abomasum was observed to follow three patterns: displacement to the left side of the abdominal cavity through the gap formed at the reticulum, atrium of the rumen and ventral sac of the rumen (n=7); displacement to the left side after cranial movement along the diaphragm (n=3); displacement to the right side after cranial movement along the diaphragm (n=2). These differences were considered to be associated with the rumen volume. To the best of our knowledge, this is the first study reporting the visual observation of the course of DA in dairy cows.

KEY WORDS: dairy cow, displaced abomasum, fluoroscopy

J. Vet. Med. Sci.

79(12): 1952–1956, 2017

doi: 10.1292/jvms.16-0611

Received: 25 November 2016

Accepted: 27 September 2017

Published online in J-STAGE:

17 October 2017

Displaced abomasum (DA) is a gastrointestinal disorder caused by a combination of factors [6] and has never been reproduced experimentally. DA occurs only in cows with abomasal atony and an excessive accumulation of abomasum gas [11, 14]. Abomasal atony is believed to be associated with aging or vagal nerve injury [18]. However, the mechanisms of displacement and gas accumulation in the abomasum remain unclear. Abomasum gas can be observed using X-ray fluoroscopy [17]; however, because the accurate prediction of the onset of DA is impossible, the precise timing of abomasum displacement cannot be determined. Rolling is a method whereby a cow's position is changed from lateral to supine while pressing the abdomen with force for the repositioning of DA [1, 8]. This method is effective in discharging the accumulated gas in the abomasum to the forestomach or the succeeding intestinal tract. However, recurrence is common if abomasal atony is not improved and the abomasum is not surgically fixed to the abdominal wall [1, 8]. Although rolling is rarely used clinically because of the high recurrence rate, it can be used in recurrence experiments. Therefore, for morphological examination of displacement and gas accumulation in the abomasum, we performed rolling on dairy cows with DA and observed the pattern of relapse using X-ray fluoroscopy.

Holstein milking cows reported to have a decreased appetite or milk yield according to their farmers and those diagnosed with DA on the basis of auscultation of a ping sound by veterinarians were evaluated. From these, 12 [left DA (LDA): 9, right DA (RDA): 3] cows with recurrent DA, despite repositioning through rolling were included in this study (Table 1). Rolling was performed as follows. Cows with LDA were placed in right lateral recumbency, whereas those with RDA were placed in left lateral recumbency. The cow's body was rotated into a supine position and the abdomen was pressed to remove the abomasum gas. Disappearance of the ping sound was confirmed by auscultation. The abomasum in all cows remained unfixed. During the rolling of cows with RDA, care was taken to prevent the occurrence of abomasal volvulus, with advance preparations for surgery in case it occurred. After rolling, the abomasum was observed in the normal position using X-ray fluoroscopy. Subsequently, cows were maintained in a standing position in the restraining stall. The right paramedian of the caudal third from the xiphoid process to the umbilicus was punctured using a trocar after subcutaneous administration of 10 ml of 2% procaine hydrochloride (Procaine Hydrochloride Injection KS, Kyoritsu Seiyaku Corp., Tsukuba, Japan) around the puncture site. To ensure accurate injection of the contrast agent (barium sulfate) into the abomasum, the liquid material adhering to the tip of the inner needle was applied to a

*Correspondence to: Kawamoto, S.: kawamoto@rakuno.ac.jp

©2017 The Japanese Society of Veterinary Science



This is an open-access article distributed under the terms of the Creative Commons Attribution Non-Commercial No Derivatives (by-nc-nd) License. (CC-BY-NC-ND 4.0: <https://creativecommons.org/licenses/by-nc-nd/4.0/>)

Table 1. Age, parity, day after parturition and displacement at the time of clinical diagnosis and recurrent of displaced abomasum in 12 Holstein dairy cows

Case No.	Age (year)	Parity	Day after parturition (day)	Occurrence in the field	Recurrence after rolling	Pattern of displacement
1	1	1	5	LDA	LDA	A
2	2	1	22	LDA	LDA	A
3	4	3	13	LDA	LDA	A
4	5	3	11	LDA	LDA	A
5	5	4	10	LDA	LDA	A
6	5	4	12	LDA	LDA	A
7	7	5	26	LDA	LDA	A
8	4	3	34	LDA	LDA	B
9	4	4	12	LDA	LDA	B
10	2	1	8	RDA	LDA	B
11	2	1	90	RDA	RDA	C
12	7	5	2	RDA	RDA	C

LDA: left displaced abomasum, RDA: right displaced abomasum. A: developed LDA by movement of the abomasum through the gap formed at the reticulum, atrium of the rumen, and ventral sac of the rumen to the left side of the abdominal wall. B: developed LDA after the abomasum had moved to the cranial side along the diaphragm, C: developed RDA after the abomasum had moved to the cranial side along the diaphragm.

test paper with a pH of 3.2–5.6 (phenol blue test paper, Advantech, Tokyo, Japan), and the puncture site was confirmed to be the abomasum (pH<3.0). In order to confirm the position and form of the abomasum more easily, 1,200 ml of barium sulfate (100% w/v; Baritop100, Kaigen Pharma, Tokyo, Japan) was injected into the abomasum. Fluoroscopic images of dynamic changes in the abomasum were obtained every 3 hr before and every 1 hr after a change in the form of the abomasum using an X-ray inspection apparatus (MG325 320 kV, Royal Philips, Amsterdam, The Netherlands) and X-ray image intensifier (IT-12HTL, Hitachi Medical Corp., Tokyo, Japan). On the X-ray fluoroscopic images, positions close to the image intensifier appear unmagnified and clear, whereas positions far from the image intensifier appear magnified and blurred. The location of the abomasum on the left or right side of the abdominal cavity was judged from the magnification ratio of the fluoroscopic image according to the distance from the image intensifier. All experiments were approved by the ethics committee of Hokkaido Research Organization Animal Research Center.

The cows presented with DA recurrence within 24 hr after rolling. Immediately after repositioning the inflow of air bubbles from the forestomach to the abomasum in conjunction with reticular contraction was observed in some cows, and stepwise gas accumulation in the abomasum body was observed in all 12 cows.

These findings were considered to indicate that the gas in DA was generated by rumen fermentation and inflow from the forestomach, rather than being produced in the abomasum. This was consistent with the findings in studies indicating the absence of differences in H₂ and CH₄ concentrations between abomasum gas and rumen gas in cows with DA [9] and the absence of gas generation on abomasum fluid culture [13]. Cows with DA exhibit reduced feed intake before its onset [16], along with a decreased rumen volume. Therefore, during reticular motility, gas in the forestomach probably flows easily into the abomasum. In addition, because these cows have abomasal atony [11], gas accumulates easily in the abomasum body. This gas accumulation is likely to cause floating of the abomasum. Consequently, the forestomach gas can flow more easily into the abomasum, from where it cannot escape. In this way, abomasum gas was considered to increase and accumulate rapidly.

Three different patterns of displacement were observed in the present study (Table 1). The first pattern (Pattern A) was observed in seven of the 10 cows (cases 1–7) that finally developed LDA. The second pattern (Pattern B) was observed in the remaining three cows (cases 8–10). The third pattern (Pattern C) was observed in two cows (cases 11 and 12) that finally developed RDA. The seven cows displaying Pattern A exhibited the following findings. Gas appeared in the abomasum body (Fig. 1-1). Gas in the abomasum body further increased and the abomasum moved dorsally (Fig. 1-2). The flow of gas toward the pyloric region as well as the abomasum body caused displacement of the abomasum through the gap formed at the reticulum, atrium of the rumen and ventral sac of the rumen to the left side of the abdominal wall (Fig. 1-3). LDA developed when the abomasum reached the left dorsal side of the abdominal cavity (Fig. 1-4). The development of LDA was also supported by auscultation of the ping sound over the left ribs. The three cows displaying Pattern B exhibited the following findings. Gas appeared in the abomasum body (Fig. 2-1). Gas in the abomasum body further increased and the abomasum moved cranially (Fig. 2-2). The flow of gas toward the pyloric region as well as the abomasum body caused displacement of the abomasum to the cranial dorsal side along the diaphragm (Fig. 2-3). The abomasum moved to the left side of the abdominal wall, and LDA developed when it reached the dorsal side (Fig. 2-4). The development of LDA was also supported by auscultation of the ping sound over the left ribs. The two cows displaying Pattern C exhibited the following findings. Gas appeared in the abomasum body (Fig. 3-1). Gas in the abomasum body further increased and the abomasum moved cranially (Fig. 3-2). The flow of gas toward the pyloric region as well as the abomasum body caused displacement of the abomasum to move to the cranial dorsal side along the diaphragm (Fig. 3-3). RDA developed when the abomasum reached the right dorsal side of the abdominal cavity (Fig. 3-4). The development of RDA was also supported

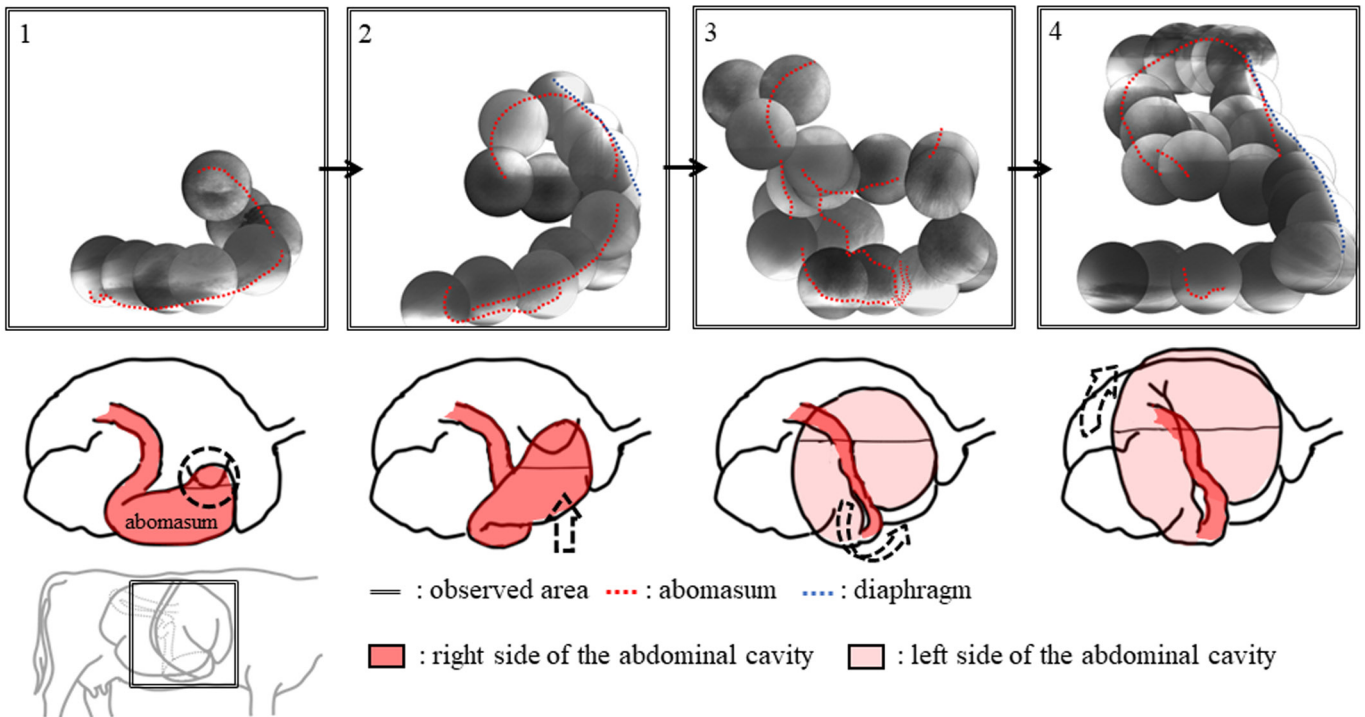


Fig. 1. Representative X-ray fluoroscopic image for a cow (case 4) with left displaced abomasum (LDA; Pattern A). 1. Gas appears in the abomasum body. 2. Gas in the abomasum body further increases and the abomasum moves dorsally. 3. The flow of gas toward the pyloric region as well as the abomasum body causes displacement of the abomasum through the gap formed at the reticulum, atrium of the rumen and ventral sac of the rumen to the left side of the abdominal wall. 4. LDA develops when the abomasum reaches the left dorsal side of the abdominal cavity.

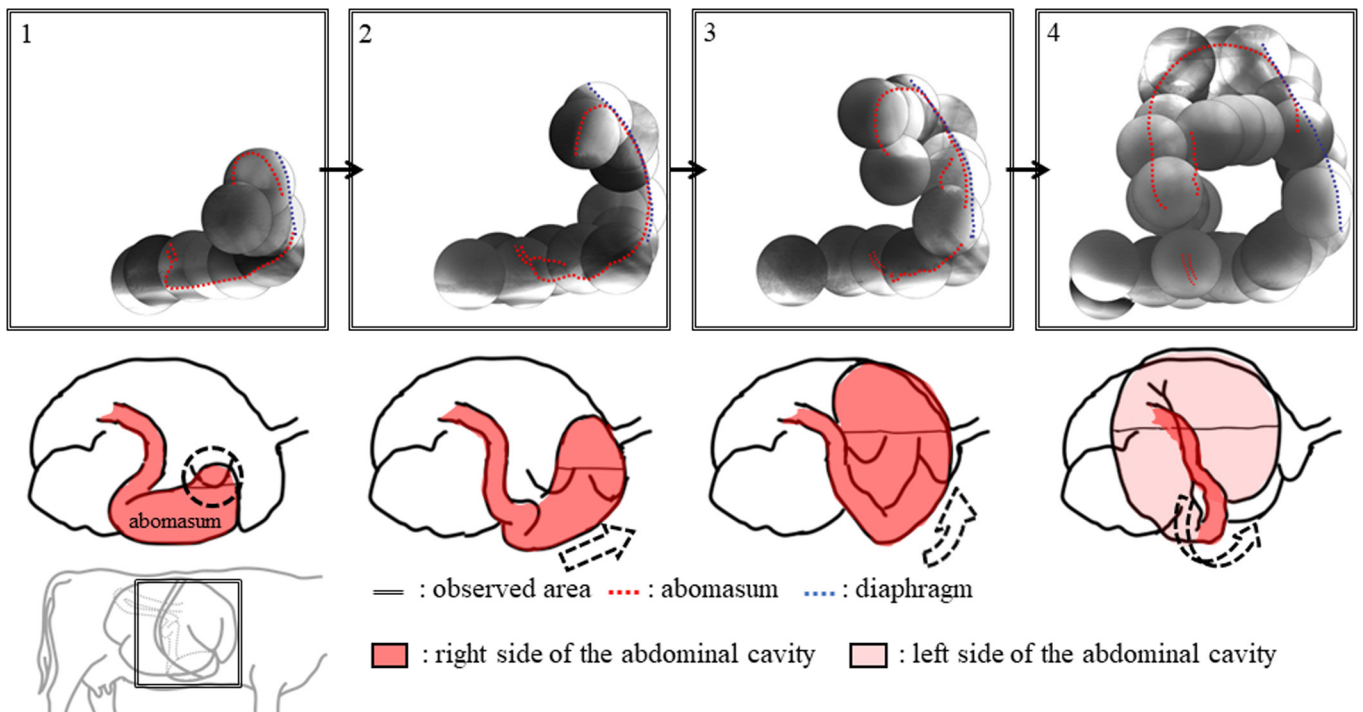


Fig. 2. Representative X-ray fluoroscopic image for a cow (case 10) with left displaced abomasum (LDA; Pattern B). 1. Gas appears in the abomasum body. 2. Gas in the abomasum body further increases and the abomasum moves cranially. 3. The flow of gas toward the pyloric region as well as the abomasum body causes displacement of the abomasum to the cranial dorsal side along the diaphragm. 4. The abomasum moves to the left side of the abdominal wall, and LDA develops when it reaches the dorsal side.

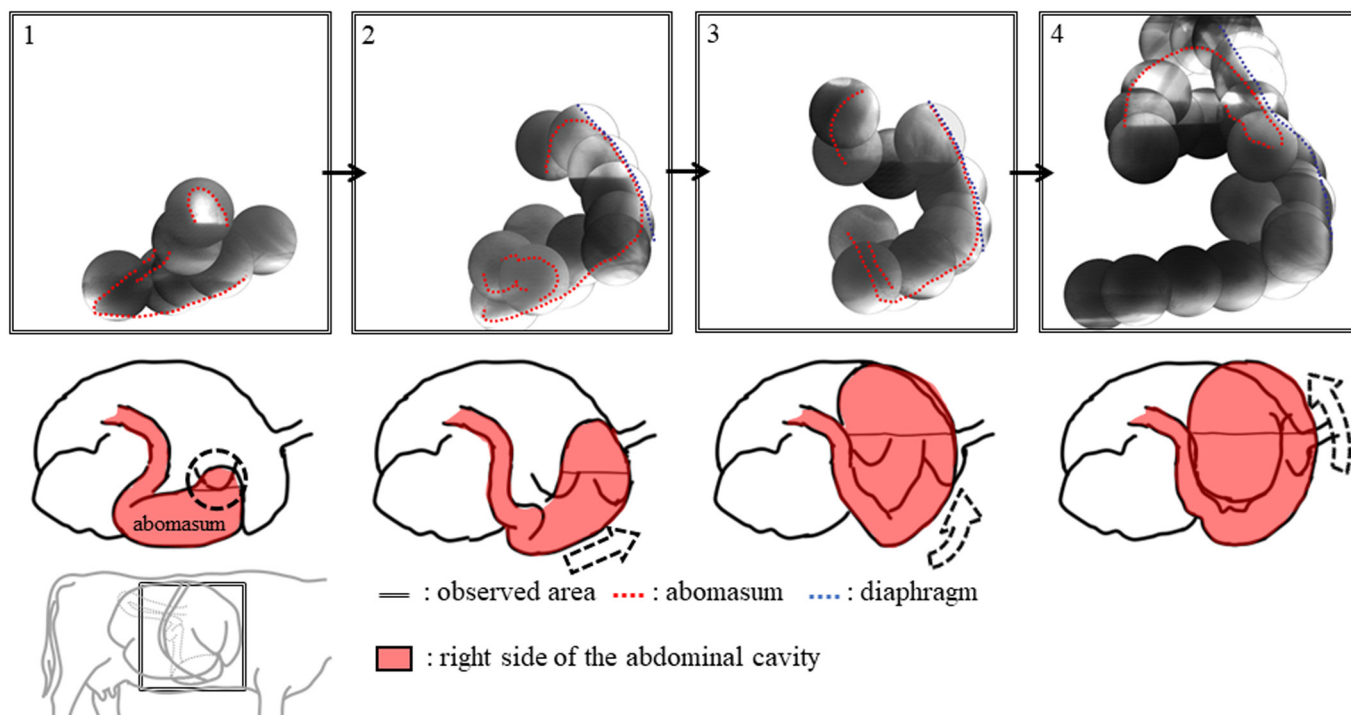


Fig. 3. Representative X-ray fluoroscopic image for a cow (case 12) with right displaced abomasum (RDA; Pattern C). 1. Gas appears in the abomasum body. 2. Gas in the abomasum body further increases and the abomasum moves cranially. 3. The flow of gas toward the pyloric region as well as the abomasum body causes displacement of the abomasum to the cranial dorsal side along the diaphragm. 4. RDA develops when the abomasum reaches the right dorsal side of the abdominal cavity.

by auscultation of the ping sound over the right ribs.

The abomasum in the two cows (cases 11 and 12) with RDA had displaced in a cranial dorsal direction along the diaphragm. On the other hand, in seven cows (cases 1–7; Pattern A) with LDA it had displaced to the left side of the abdominal wall through the gap formed at the reticulum, atrium of the rumen and ventral sac of the rumen. This gap probably resulted from a decrease in the rumen volume due to decreased feed intake. This suggests that cows with DA present with insufficient feed intake before the onset of the condition. Three cows (cases 8–10; Pattern B) developed LDA after the abomasum had moved to the cranial side along the diaphragm. We were unable to observe the time point at which the abomasum moved to the left of the abdominal wall. However, we propose that the movement occurred when the cows were repeatedly recumbent or standing between X-ray fluoroscopy measurements, considering the abomasum of these cows was easily moved within the abdominal cavity. One cow (case 10) that presented with RDA in the field developed LDA after the abomasum moved cranially along the diaphragm. This is believed to have occurred because of insufficient feed intake even after rolling, which facilitated movement of the abomasum within the abdominal cavity.

In previous studies, the form of the abomasum in cases of DA was based on frozen autopsy findings [12], radiographic images [7, 17], ultrasonography [2, 3] and laparoscopy [15]. In addition, it was reported that DA occurred in cows with insufficient feed intake and a decreased rumen volume [16]. Furthermore, the gap (groove) of the rumen has been found to act as a pathway for the abomasum in DA [10]. An interesting report described an anterior displaced abomasum, wherein the abomasum displaced between the diaphragm and reticulum [19, 20]. The findings for the recurrence cases in the present study were consistent with the findings in these previous reports, both anatomically and clinically. Schematic diagrams [5, 8] and computer graphic videos [4] have also conjectured the course of DA on the basis of previous morphological and anatomical findings. The course of LDA shown in these reports is highly consistent with that observed in the present study. The displacement observed in this study was actually a recurrence following rolling; however, it is possible that the mechanism is the same as that for spontaneous DA.

To the best of our knowledge, this is the first study reporting the visual observation of the course of DA in dairy cows.

REFERENCES

1. Ames, N. K. 1987. Left displaced abomasum in dairy cows. *Agri-Pract.* **8**: 11–16.
2. Braun, U. and Feller, B. 2008. Ultrasonographic findings in cows with right displacement of the abomasum and abomasal volvulus. *Vet. Rec.* **162**: 311–315. [[Medline](#)] [[CrossRef](#)]
3. Braun, U., Pusterla, N. and Schönmann, M. 1997. Ultrasonographic findings in cows with left displacement of the abomasum. *Vet. Rec.* **141**: 331–335. [[Medline](#)] [[CrossRef](#)]

4. Desrochers, A. and Harvey, D. 2002. Surgeries of the Abomasum in Cattle (CD-ROM). University of Montreal, Montreal.
5. Espersen, G. 1961. Die rechtsseitige labmagenerweiterung und -verlagerung (dilatatio abomasi cum dislocatione dextra) beim rind. *Dtsch. Tierarztl. Wochenschr.* **68**: 2–7.
6. Fecteau, G., Sattler, N. and Rings, D. M. 1999. Abomasal physiology, and dilatation, displacement and volvulus. pp. 522–527. *In*: Current Veterinary Therapy: Food Animal Practice, 4th ed. (Howard, J. L. and Smith, R. A. eds.), Saunders, Philadelphia.
7. Hawkins, C. D., Fraser, D. M., Bolton, J. R., Wyburn, R. S., McGill, C. A. and Pearse, B. H. 1986. Left abomasal displacement and ulceration in an eight-week-old calf. *Aust. Vet. J.* **63**: 53–55. [[Medline](#)] [[CrossRef](#)]
8. Hoffsis, G. F. and McGuiirk, S. M. 1986. Diseases of the abomasum and the intestinal tract. pp. 724–738. *In*: Current Veterinary Therapy, Food Animal Practice, 2nd ed. (Howard, J. L. ed.), W. B. Saunders Co., Philadelphia.
9. Itoh, M., Kamiyoshi, T., Sasaki, N., Yamada, H. and Inokuma, H. 2008. Concentrations of H₂ and CH₄ in exhaled breaths and stomachs of dairy cattle with abomasal displacement. *J. Jpn. Vet. Med. Assoc.* **61**: 533–535. [[CrossRef](#)]
10. Jackson, P. and Cockerfort, P. 2008. Clinical examination of the gastrointestinal system. pp. 81–112. *In*: Clinical examination of farm animals, John Wiley & Sons, Hoboken.
11. Kuiper, R. 1991. Abomasal disorders. *Bovine Practitioner.* **26**: 111–116.
12. Sack, W. O. 1968. Abdominal topography of a cow with left abomasal displacement. *Am. J. Vet. Res.* **29**: 1567–1576. [[Medline](#)]
13. Sarashina, T., Ichijo, S., Takahashi, J. and Osame, S. 1990. Origin of abomasum gas in the cows with displaced abomasum. *Nippon Juigaku Zasshi* **52**: 371–378. [[Medline](#)] [[CrossRef](#)]
14. Van Winden, S. C. and Kuiper, R. 2003. Left displacement of the abomasum in dairy cattle: recent developments in epidemiological and etiological aspects. *Vet. Res.* **34**: 47–56. [[Medline](#)] [[CrossRef](#)]
15. Wilson, A. D. and Ferguson, J. G. 1984. Use of a flexible fiberoptic laparoscope as a diagnostic aid in cattle. *Can. Vet. J.* **25**: 229–234. [[Medline](#)]
16. Van Winden, S. C., Jorritsma, R., Müller, K. E. and Noordhuizen, J. P. T. M. 2003. Feed intake, milk yield, and metabolic parameters prior to left displaced abomasum in dairy cows. *J. Dairy Sci.* **86**: 1465–1471. [[Medline](#)] [[CrossRef](#)]
17. Yamada, H. 1982. Clinical and pathological studies on the etiological factors of bovine abomasal displacement and atony. I. Clinical cases. *Nippon Juigaku Zasshi* **44**: 39–50. [[Medline](#)] [[CrossRef](#)]
18. Yamada, H. 1982. Clinical and pathological studies on the etiological factors of bovine abomasal displacement and atony. II. Experimental cases. *Nippon Juigaku Zasshi* **44**: 51–62. [[Medline](#)] [[CrossRef](#)]
19. Yamada, H. 1988. Displacement and Torsion of the abomasum. pp. 473–480. *In*: Diseases of Cattle, 2nd ed. (Shimizu, T., Onuma, M., Fujinaga, T., Inaba, Y., Kanagawa, H. and Sato, M. eds.), Kindai Shuppan, Tokyo (in Japanese).
20. Zadnik, T. 2003. Review of anterior displacement of the abomasum in cattle in Slovenia. *Vet. Rec.* **153**: 24–25. [[Medline](#)] [[CrossRef](#)]