

# Refractive surgery with simultaneous collagen cross-linking for borderline corneas - A review of different techniques, their protocols and clinical outcomes

Sheetal Brar, Megha Gautam, Smith Snehal Sute, Sri Ganesh

Simultaneous corneal cross-linking (CXL) has been proposed as an adjunct therapy to corneal refractive procedures to prevent future ectasia, especially when performed in borderline corneas. This review analyses the currently available literature (minimum follow-up 6 months) on corneal refractive surgery and simultaneous CXL (PRK Xtra, LASIK Xtra, and SMILE Xtra) to evaluate the overall results including the safety, efficacy, and potential complications associated with these procedures. A comprehensive literature search of various electronic databases (PubMed, PubMed Central, Cochrane database, and MEDLINE) was performed up to 20<sup>th</sup> May 2020. Four relevant studies were found for PRK Xtra, 12 for LASIK Xtra, and 3 for SMILE Xtra. The total number of eyes included in this review was 1,512: 294 for PRK Xtra, 221 for PRK-only, 446 eyes for LASIK Xtra, 398 eyes for LASIK-only, 91 for SMILE Xtra and 62 for SMILE-only. Current literature suggests that refractive surgery and simultaneous CXL is generally safe and delivers comparable results in terms of visual and refractive outcomes than refractive surgery alone. However, there is no consensus on a standard cross-linking protocol, and complications such as diffuse lamellar keratitis, central toxic keratopathy, and corneal ectasia following Xtra procedures have been reported. It is therefore suggested that surgeons exercise caution in case-selection and counsel their patients regarding the potential risks and benefits with Xtra procedures. Also, further studies are required to standardize the UV-A irradiation protocols and to evaluate the long-term effect on safety, refractive predictability, and stability of these procedures.

**Key words:** Accelerated cross-linking, PRK Xtra, laser refractive surgery, LASIK Xtra, SMILE Xtra

Corneal refractive surgeries such as photorefractive keratectomy (PRK), Laser in-situ keratomileusis (LASIK), and small-incision lenticule extraction (SMILE) have evolved tremendously in the past few decades and are shown to be safe and effective procedures.<sup>[1-6]</sup> However, complications such as post-operative regression and iatrogenic keratectasia are inherently associated with all these procedures, which can potentially be sight-threatening.<sup>[7-10]</sup> Post-operative keratectasia remains the most dreaded complication of corneal refractive surgeries, mechanisms underlying which are poorly understood.<sup>[11-15]</sup> Tissue subtraction coupled with creation of vertical or delamination cuts in LASIK and SMILE respectively, and injury to Bowman's Membrane (BM) in PRK leading to biomechanical instability are known mechanisms of ectasia development<sup>[16-19]</sup> procedure. Along with these, risk factors such as pre-operative high myopia or hyperopia, thin corneas and patients with abnormal topography (forme fruste keratoconus), eye rubbing, pregnancy, hormonal imbalances and certain systemic conditions and medications have also been implicated in the causation of ectasia.<sup>[19,20-25]</sup>

Of all the corneal refractive surgeries, LASIK is associated with the highest risk of ectasia, the prevalence of which has been reported from 0.02% to 0.6% in various studies.<sup>[14,18,22,23]</sup>

Nethradhama Superspeciality Eye Hospital, Bengaluru, Karnataka, India

**Correspondence to:** Dr. Sheetal Brar, 256/14, Kanakapura Main Road, Jayanagar 7<sup>th</sup> block, Bangalore - 560 070, Karnataka, India. E-mail: brar\_sheetal@yahoo.co.in

Received: 31-May-2020

Revision: 24-Sep-2020

Accepted: 28-Sep-2020

Published: 23-Nov-2020

#### Access this article online

##### Website:

www.ijo.in

##### DOI:

10.4103/ijo.IJO\_1709\_20

#### Quick Response Code:



This was mainly attributed to creation of a corneal flap which may weaken the corneal structure and decrease corneal rigidity.<sup>[26]</sup> However, flap-less procedures such as PRK and SMILE have also been associated with keratectasia.<sup>[27-29]</sup> SMILE was shown to biomechanically more stable compared to LASIK and PRK,<sup>[30]</sup> however; ectasia was shown to occur even after SMILE, with most of these cases having borderline or abnormal pre-operative topography.<sup>[31]</sup> More recently, the possibility of association between low expression of Lysyl Oxidase (LOX) enzyme and post-SMILE corneal ectasia has been proposed in a case of high myopic individual with normal topography.<sup>[32]</sup>

Due to these factors, pre-operative evaluation for corneal refractive surgery has received significant attention in recent years, as performing a tissue subtraction surgery in thin or suspicious corneas has been associated with higher risk of postoperative corneal ectasia, compared to normal corneas.<sup>[33-35]</sup> Various risk scoring systems and tomographic indices combined with biomechanics have come into existence to help a refractive surgeon identify corneas at risk.<sup>[36-40]</sup> Along

This is an open access journal, and articles are distributed under the terms of the Creative Commons Attribution-NonCommercial-ShareAlike 4.0 License, which allows others to remix, tweak, and build upon the work non-commercially, as long as appropriate credit is given and the new creations are licensed under the identical terms.

**For reprints contact:** WKHLRPMedknow\_reprints@wolterskluwer.com

**Cite this article as:** Brar S, Gautam M, Sute SS, Ganesh S. Refractive surgery with simultaneous collagen cross-linking for borderline corneas - A review of different techniques, their protocols and clinical outcomes. Indian J Ophthalmol 2020;68:2744-56.

with these advanced screening systems, a new form of refractive surgery; i.e., combined collagen cross-linking (CXL) with the primary corneal refractive surgery has emerged in recent years, which aims at improving post-operative biomechanical stability of the cornea; thereby potentially preventing the risk of future kerectasia.<sup>[40-42]</sup> This was based on the proven evidence, backed up by numerous studies, that CXL lead to halting of progression and corneal stabilization of keratoconic corneas.<sup>[43-48]</sup>

This class of refractive surgeries, popularly known as "Xtra procedures" can be combined with PRK, LASIK as well as SMILE, and are typically performed in cases where the topographic/tomographic indices or the clinical history is suggestive of "at risk" corneas. This review aims at analyzing the currently available literature (minimum follow-up 6 months) on corneal refractive surgery and simultaneous CXL (PRK Xtra, LASIK Xtra and SMILE Xtra) to evaluate the overall results including the safety, efficacy, stability, and potential complications associated with these procedures.

## Methods

A comprehensive literature search of various electronic databases (PubMed, PubMed Central, Cochrane database and MEDLINE) was performed up to 20<sup>th</sup> May 2020, using keywords such as "photorefractive keratectomy", "PRK", "PRK Xtra", "surface ablation", "laser epithelial keratomileusis", "LASEK", "laser *in situ* keratomileusis", "LASIK", "LASIK Xtra", "small incision lenticule extraction", "SMILE", "SMILE Xtra", "crosslinking", "cross-linking", "cross linking" and "CXL". The retrieved articles were carefully studied to extract relevant data about the indications, operative protocol, visual and refractive data, safety, efficacy, refractive predictability, stability, and associated complications. The following types of studies were excluded from our review: (1) studies involving known keratoconus or corneal ectasia patients, (2) studies performed with sequential refractive surgery and CXL, (3) *in vitro* or animal studies, and (4) studies with a follow-up period of <6 months. Four relevant studies were found for PRK Xtra, 11 for LASIK Xtra, and 3 for SMILE Xtra. The total number of eyes included in this review was 1,512: 294 for PRK Xtra, 221 for PRK-only, 446 eyes for LASIK Xtra, 398 eyes for LASIK-only, 91 for SMILE Xtra and 62 for SMILE-only. The average follow-up ranged from 6 months to 4 years. Safety and efficacy indices were calculated for studies reporting the corrected distance visual acuity (CDVA) and uncorrected distance visual acuity (UDVA) values. The formula used to calculate efficacy index was mean postoperative UDVA (decimal)/pre-operative CDVA (decimal) and for safety index was mean post-operative CDVA (decimal)/mean preoperative CDVA (decimal).<sup>[49]</sup>

### Patient selection criteria

There is currently no consensus on patient selection criteria or protocol for refractive surgery and simultaneous CXL. Most studies have included patients at high risk of iatrogenic kerectasia and regression such as those having young age, high myopia/hyperopia, thin corneas, borderline residual bed thickness, high ectasia risk score, suspicious corneal topography not amounting to a diagnosis of keratoconus (I/S asymmetry, posterior elevation, borderline Belin Ambrosio (BAD) display); along with any contributing history (notably H/O allergic eye disease, eye rubbing and family history of keratoconus).<sup>[18,50-53]</sup> Fig. 1 shows an example of a case with thin pachymetry and borderline BAD parameters, but no keratoconus; which could

be a potential candidate for an Xtra procedure. Fig. 2 provides a simplified algorithm to help in decision making regarding suitability for combined refractive surgery with CXL, followed at our center. The current selection criteria are, thus, based upon the evaluation of individual case scenarios and are predominantly reserved for at-risk patients.

### Surgical procedure

Similar to the selection criteria, there is no common consensus on the riboflavin dye, the power and duration of UV-A irradiation to be used and the final energy to be delivered to the cornea for any of the combined refractive surgery and CXL procedures. Published studies on each of the Xtra procedures have reported the use of different prophylactic cross-linking protocols.

For PRK Xtra, the procedure is performed in the following sequence: (1) Epithelial debridement using transepithelial PRK photoablation<sup>[54,55]</sup>/PTK-PRK mode<sup>[56]</sup>/alcohol- assisted<sup>[57]</sup> (2) 0.1% riboflavin with hydroxypropyl methylcellulose (Vibex Rapid, Avedro) or 0.22 or 0.25% without dextran (Vibex Xtra, Avedro) applied for 90s-15 mins and subsequently rinsed off with a chilled balanced salt solution; (3) UV-A irradiation of 30 mW/cm<sup>2</sup> is performed for 90s (total energy 2.7 J/cm<sup>2</sup>) or 9 mW/cm<sup>2</sup> for 10 mins (total energy 5.4 J/cm<sup>2</sup>) (4) 0.02% mitomycin C (MMC) is applied for 20s and subsequently rinsed off. This step was optional. (5) bandage lens application.

Hence, the riboflavin concentration, soak time, UV-A irradiation power and duration vary in different protocols. Sachdev *et al.* omitted the application of MMC (step 4).<sup>[56]</sup>

For LASIK Xtra protocol, the recommended protocol by Avedro is as follows<sup>[58,59]</sup>: (1) Creation of LASIK flap followed by laser ablation (2) Lifting of the flap and with the flap open, application of 0.22% riboflavin (VibeX Xtra riboflavin, Avedro) onto the underlying stromal bed and allowed to soak for 45-120s; (3) irrigation of the stromal bed to rinse off the riboflavin solution followed by corneal flap repositioning; (4) UV-A irradiation performed through the corneal flap at 30 mW/cm<sup>2</sup> for 45-90s, delivering 1.4-5.4 J/cm<sup>2</sup> energy in total (Avedro KXL system, Avedro). In LASIK Xtra too, there are variations in the protocol in terms of riboflavin concentration, soak time and amount of UV-A energy delivered.<sup>[60-63]</sup>

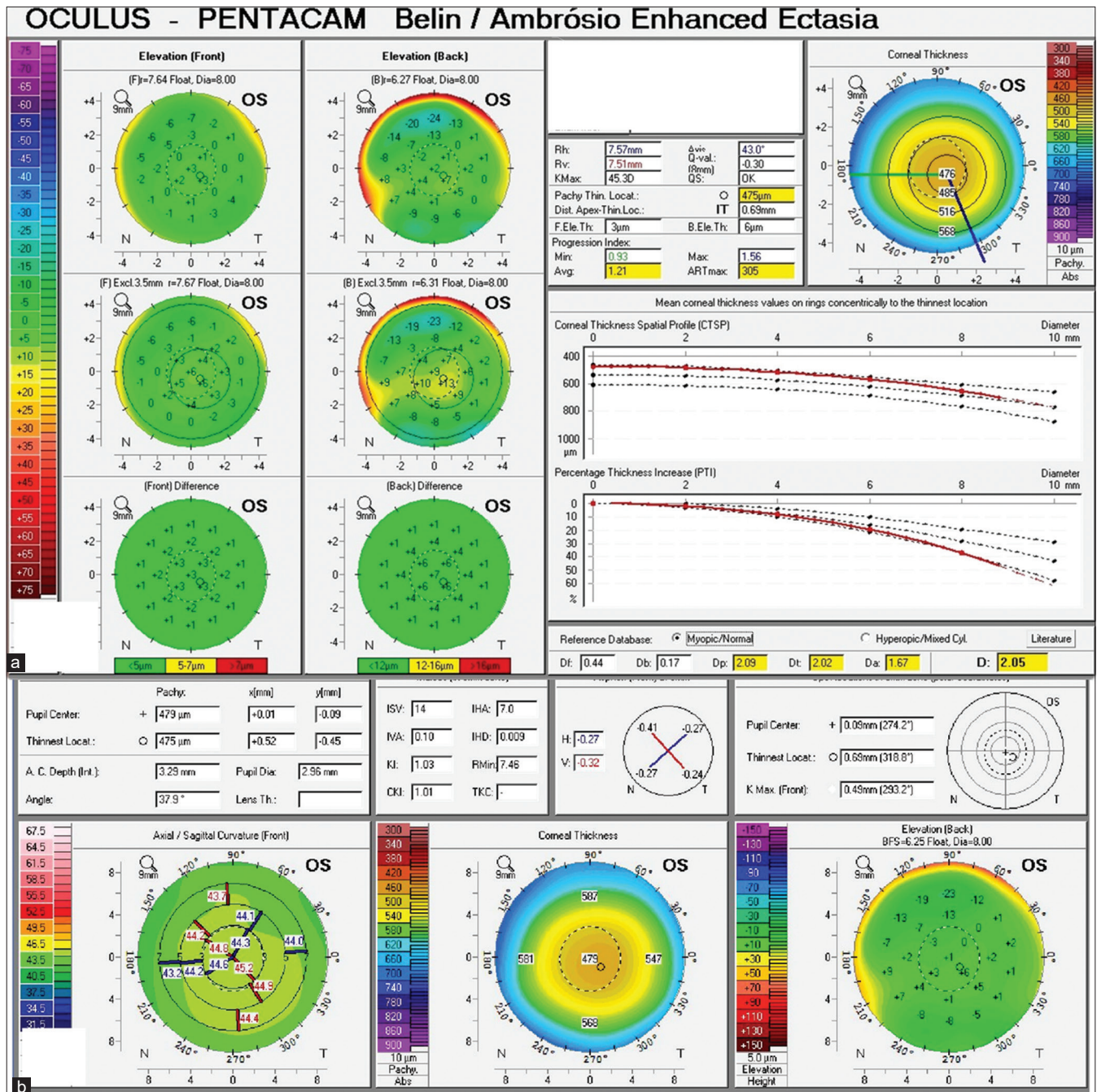
For SMILE Xtra, the procedure described by Ganesh *et al.* is as follows<sup>[64]</sup> (1) SMILE is performed following the standard protocol (2) 0.25% riboflavin in saline (Vibex Xtra, Avedro) injected into the interface and allowed to diffuse for 60s, after which it is rinsed off with balanced salt solution; (3) UV-A irradiation performed through the cap using 45 mW/cm<sup>2</sup> for 75s, delivering a total energy 3.4 J/cm<sup>2</sup>. However, recent studies report using different riboflavin concentration, soak time, UV-A irradiation power and duration.<sup>[65,66]</sup>

## Results

### Visual and refractive outcomes

#### PRK Xtra

Table 1 summarizes the results of PRK Xtra from the 4 relevant studies on this topic. There are currently two retrospective comparative studies, one prospective comparative study and one retrospective cohort study, with a minimum follow-up of 6 months in the literature on this subject<sup>[55-58]</sup> [Table 1]. These studies have been performed only on myopic eyes.



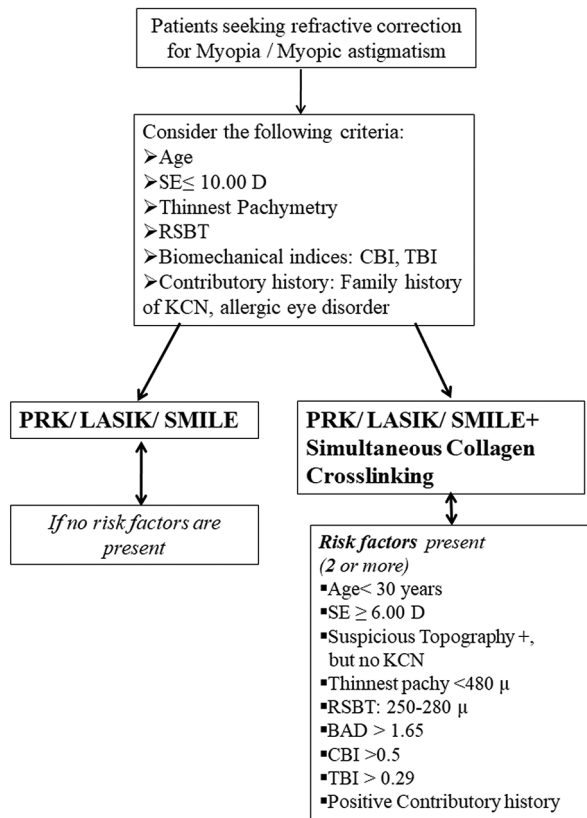
**Figure 1:** Pre-operative Pentacam topography [a -Belin Ambrósio Display map, b- Keratoconus screening map] of a 22 year old female patient with low myopia (-2.00 DS), thin pachymetry of 475 microns, borderline BAD scores but no keratoconus in the left eye, who was found to be eligible for SMILE Xtra

In a study by Hyun *et al.*<sup>[57]</sup> comparing LASEK Xtra versus LASEK for high myopia, the percentage of eyes achieving 20/20 or better was similar in both groups (72.5% in LASEK Xtra and 72.1% in LASEK) at the end of mean follow-up of 6 months. Efficacy Index was slightly better in LASEK Xtra (0.99) compared to LASEK (0.96) group.

Another comparison study by Lee *et al.*<sup>[54]</sup> showed PRK Xtra having similar or better results as compared to PRK alone in terms of refractive outcomes. Although the UDVA was better in the PRK Xtra group in the early post-op period (1 month), there was no significant difference at 1-year post-op (p=0.289).

Similarly, Sachdev *et al.*<sup>[56]</sup> did not find a significant difference in the postoperative uncorrected visual acuity (UCVA) between both groups, even though PRK Xtra was performed on significantly thinner corneas with corneal tomographic abnormalities (p = 0.02). Refractive outcome was also similar with 36 (95.4%) of the eyes in the PRK Xtra group and 97.4% in the PRK-only group achieving a refractive predictability within 0.50D (p = 0.8).

However, a retrospective case series of 98 eyes that underwent PRK Xtra by Ohana *et al.*<sup>[55]</sup> found a slightly lower efficacy index of 0.90, compared to other published studies at a follow-up



SE: spherical equivalent, RSBT: residual stromal bed thickness, BAD: Belin Ambrosio Display  
CBI: corvis biomechanical index, TBI: tomographic biomechanical index, KCN: keratoconus,

**Figure 2:** A simplified algorithm to aid in decision making regarding suitability for combined refractive surgery with CXL

of >24 months, [Table 1]. The percentage of eyes seeing 20/20 or better was 57% compared to 92.6% as reported by Sachdev *et al.* This was most likely attributed to the post-operative corneal haze, which was significantly higher in the study by Ohana *et al.* Refractive outcome, in this study, however, was stable throughout the 1-year follow-up, with xc a slight hyperopic drift which was not statistically significant ( $p = 0.10$ ).

#### LASIK Xtra

There are currently 12 long-term studies (1-year follow-up) in the literature on LASIK Xtra of which 9 were conducted for myopia, and 3 for hyperopia treatment. Of the 9 studies on myopia, 7 were comparative studies and 2 were case series. [Table 2].

For myopia, all comparative studies reported either similar or better long-term refractive results (in terms of post-operative spherical equivalent [SE] refraction, efficacy index, UDVA) with LASIK Xtra as compared to LASIK alone.<sup>[60-63,67-69]</sup> Kanellopoulos *et al.*<sup>[70]</sup> in their consecutive case series found LASIK Xtra to be safe and effective, without significant regression or any eye progressing to ectasia in a follow-up of 42 months. Efficacy index observed in the study was 1.09. Two prospective comparison studies by the same authors observed less refractive shift and better keratometric stability in LASIK Xtra group with no forward keratometric shift as compared to the LASIK-only group.<sup>[67,68]</sup> At 1 year,

LASIK Xtra eyes had 90.4% eyes with UDVA of 20/20 or better as compared to 85.4% of LASIK-only eyes ( $p = 0.042$ ).<sup>[67]</sup> In high myopes as well, the LASIK Xtra group had better visual outcomes with 93.8% eyes seeing 20/20 or better versus 84.8% in the LASIK-only group.<sup>[68]</sup> Tomita *et al.* compared LASIK Xtra vs LASIK and found similar efficacy indices between both the groups (LASIK Xtra = 0.99 and LASIK = 1.00) at 1-year post-op.<sup>[61]</sup> Seiler *et al.* so noted similar refractive results in both groups at 1-year follow-up in a study on myopic patients with high ectasia risk scores of 3-6.<sup>[69]</sup> Celik *et al.*<sup>[60]</sup> reported that all LASIK Xtra eyes preserved their post-operative UDVA, whereas myopic changes were seen in 2 LASIK-only eyes at 1-year follow-up. The case series by Xu *et al.* showed an improvement in the mean keratometry from 44.15 D pre-operatively to 39.75 D, two-years post-operatively.<sup>[71]</sup>

For hyperopia, there are currently 3 long-term studies with  $\geq 1$ -year follow-up in the literature 2 of which are comparative studies, 1 of which is a case report [Table 2]. Both comparative studies reported either similar or better long-term refractive results with LASIK Xtra, compared with LASIK alone.<sup>[72,73]</sup> Both studies showed better stability and reduced regression in the LASIK Xtra group. In a study by Kanellopoulos *et al.*, the authors reported statistically significant greater regression in LASIK-only eyes, where the mean 2-year postoperative SE cycloplegic refraction was +0.20 D, compared to LASIK Xtra eyes, where it was -0.20 D on patients with hyperopia or hyperopic astigmatism.<sup>[72]</sup> Aslanides *et al.* in a comparative study with a follow-up of 3-4.5 years (5 LASIK Xtra eyes and 5 matched LASIK-only controls), found that there was a trend towards hyperopic regression in the LASIK-only group, whereas no significant hyperopic regression in the LASIK Xtra group was observed. The calculated efficacy index in the LASIK Xtra group was higher (1.07), as compared to LASIK-only group (0.83).<sup>[73]</sup>

#### SMILE Xtra

There were only 3 relevant studies on SMILE Xtra with a follow-up of  $\geq 6$  months in the literature [Table 3], of which two were comparative and one was a prospective case series. Ganesh *et al.* in their prospective case series on SMILE Xtra performed on 40 eyes of 20 myopic patients with moderate to high risk of ectasia (Randleman Scoring  $\geq 3$ ) observed good stability and an efficacy index of 1.04.<sup>[64]</sup> On the other hand, Ng *et al.* conducted a prospective comparison study, and found a comparatively lower efficacy index with SMILE Xtra (0.88) and SMILE (0.97)<sup>[65]</sup> at a mean follow-up of 6 months. A retrospective comparison study by Osman *et al.*<sup>[66]</sup> observed a similar efficacy index in both the SMILE Xtra (1.09) and SMILE group (1.12) at 2 years follow-up, suggesting that CXL may not have a significant impact on the uncorrected visual acuity when combined with SMILE.

#### Safety and complications

##### PRK Xtra

All four studies on PRK Xtra report good safety of the procedure in the treatment of myopia. Hyun *et al.* reported a comparable safety index of 1.09 with LASEK Xtra, versus 0.97 in the LASEK group. Although 25% eyes in LASEK Xtra group showed evidence of haze as against 18% in LASEK group, the % of eyes with visual acuity loss was higher in LASEK group (18%) versus LASEK Xtra group (15%).<sup>[57]</sup> Ohana *et al.* reported a calculated safety index of 0.95 in their retrospective study. However, they observed 51% eyes with grade 1-2, 3% eyes with grade 3 and 1% eyes with grade 4.<sup>[55]</sup> In a comparative

**Table 1: Long term studies on PRK Xtra for treatment of myopia**

Author and year of publication	Study design	No. of eyes (PRK Xtra, PRK)	CXL protocol and Riboflavin used	SE (D)		Mean post op UDVA/% eyes ≥ 20/20 (PRK Xtra, PRK)	Safety index	Efficacy index	Complications	Follow-up (months)	Conclusion
				Pre-op	Post-op						
Hyun <i>et al.</i> , <sup>[57]</sup> 2017	Retrospective comparative	40, 61	30 mW/cm <sup>2</sup> , 90s/ Avedro KXL/2.7 J/cm <sup>2</sup> / 0.22% riboflavin, 90s	-7.53±1.52, -7.82±1.29	-0.42±0.34, -0.50±0.36	72.5%, 72.1%	1.01±0.20, 0.97±0.11	0.99±0.21, 0.96±0.15	Corneal haze (LASEK Xtra 25%, LASEK 18%), Visual acuity loss (LASEK Xtra 15%, LASEK 18%)	6	LASEK, and LASEK-CXL surgery appear to be safe and effective for high-degree myopic correction.
Lee <i>et al.</i> , <sup>[54]</sup> 2017	Retrospective comparative	47, 42	30 mW/cm <sup>2</sup> , 90s/ Avedro KXL/2.7 J/cm <sup>2</sup> / 0.1% riboflavin with HPMC, 120s	-6.22±2.74, -5.63±1.53	+0.17±0.18, +0.31±0.13	(decimal) 1.19±0.15, 1.16±0.08	1.25±0.22, 1.18±0.17	1.17±0.15, 1.13±0.11	None	12	PRK Xtra provided better refractive outcomes than PRK alone
Ohana <i>et al.</i> , <sup>[55]</sup> 2018	Retrospective cohort	98	9 mW/cm <sup>2</sup> , 10 min/ UVX 2000 IROC/5.4 J/cm <sup>2</sup> /0.1% riboflavin, 15 min	-4.45±2.87	±0.20 0.90	(logMAR) 0.15±0.24/57%	0.98±0.20	0.90±0.32	Corneal haze: grade 1 or 2 (51%), grade 3 (3%), grade 4 (1%)	25.3±11.51	Refractive outcome stable throughout follow up
Sachdev <i>et al.</i> , <sup>[56]</sup> 2018	Comparative	109, 118	30 mW/cm <sup>2</sup> , 90s/ Avedro KXL/2.7 J/cm <sup>2</sup> / 0.25% riboflavin, 90s	-3.64±1.44, -3.38±1.65	0.04±0.20, -0.01±0.10	92.67%, 95.75%	-	-	Grade I superficial corneal haze (PRK Xtra 9 eyes)	12	Comparable refractive and keratometric stability in both groups

UV: ultraviolet; conc: concentration; pre-op: pre-operative; post-op: post-operative; SE: Spherical equivalent; D: diopters UDVA: uncorrected distance visual acuity Avedro KXL (Avedro, Inc., Waltham, MA, USA); UVX 2000 IROC (IROC Innocross AG, Zurich, Switzerland). Efficacy index was calculated with the formula: mean post-operative UDVA (decimal)/pre-operative CDVA (decimal); safety index was calculated with the formula: mean post-operative CDVA (decimal)/mean pre-operative CDVA (decimal)

study by Sachdev *et al.* good safety with PRK Xtra was reported, as most eyes (82.56%) had unchanged CDVA, 15.59% gained one line, 0.91% gained 2 lines and only 1 eye (0.91%) lost one line of CDVA. They reported no significant complications in either group but some eyes in PRK Xtra group had grade 1 superficial corneal haze which resolved within 6 months.

One patient in the PRK Xtra group developed a sterile marginal infiltrate in the early postoperative period as reported by Lee *et al.*, which did not affect visual acuity and resolved after topical steroid treatment. Otherwise, no significant complications such as delayed epithelial healing, corneal ectasia or significant corneal haze were observed in the PRK Xtra group.<sup>[54]</sup>

Both Lee *et al.* and Sachdev *et al.* did not show any significant difference in post-operative endothelial cell counts between PRK Xtra and PRK-only.<sup>[54,56]</sup> Davey *et al.* reported a case of central toxic keratopathy after 3 days post-PRK Xtra, resulting in poor visual outcome at 3 months postoperatively (CDVA 0.5, refraction +13.00/-6.50 x 106)<sup>[75]</sup>

**LASIK Xtra**

For both myopia and hyperopia, LASIK Xtra is a safe procedure. For myopic LASIK Xtra, calculated safety index in various studies ranges from 0.98-1.25, suggesting that no eye had a decrease in CDVA in these studies.<sup>[61-63,70,71]</sup> Kanellopoulos *et al.* in their two-year follow-up study evaluated postoperative CDVA between LASIK Xtra and LASIK-only eyes. They found that in the LASIK Xtra group, 35.4% eyes remained unchanged, 56.9% gained 1 line and 7.9% gained 2 or more Snellen lines, and no eye lost a line of CDVA. In the LASIK-only group, 34.7% eyes were unchanged, 60.0% gained 1 line, and 4.0% gained 2 or more lines of Snellen’s visual acuity. One eye (1.3%), however, lost 1 line of CDVA.<sup>[68]</sup> Tomita also reported a similar safety index of 1.01 in LASIK Xtra and 1.05 in LASIK-only group.<sup>[61]</sup> In most of the studies which evaluated endothelial cell density (ECD), the postoperative ECD was not found to be significantly different between LASIK Xtra and LASIK-only groups.<sup>[60,67-69]</sup>

For hyperopia, studies by Aslanides *et al.* and Kanellopoulos *et al.* showed LASIK Xtra to be a safe procedure.<sup>[72,73]</sup> A comparative 2- year study by Kanellopoulos *et al.* with 34 LASIK Xtra eyes and 34 LASIK-only eyes, concluded that both procedures were safe and effective for the treatment of hyperopia and hyperopic astigmatism.<sup>[72]</sup> Aslanides *et al.*<sup>[73]</sup> found that the postoperative BCVA was slightly better in the LASIK Xtra group (0.017 logMAR) compared to the LASIK-only group (0.06 logMAR). Safety index was also higher in the LASIK Xtra group (1.27) versus LASIK-only group (1.07). However, the sample size of this study was very small and the data is insufficient to draw meaningful conclusions.

Complications reported with LASIK Xtra are minimal, rare and usually transient. Both the studies by Kanellopoulos *et al.* on myopic LASIK Xtra did not show complications such as epithelial ingrowth, diffuse lamellar keratitis (DLK), post-operative haze, or other complications in either group.<sup>[67,68]</sup> However, Seiler *et al.* reported a higher prevalence of transient side effects such as DLK and delayed visual rehabilitation in the LASIK Xtra group, although no corneal ectasia was seen in either group.<sup>[69]</sup> Celik *et al.* reported faint stromal haze (grade 0.5) in LASIK Xtra eyes in the first postoperative week.<sup>[61]</sup> It should be noted that a case of corneal ectasia was reported by

**Table 2: Long term studies on LASIK Xtra for treatment of myopia and hyperopia**

Author and year of publication	Study design	No. eyes (LASIK Xtra, LASIK)	LASIK Xtra (myopia)		SE (D)	Mean post op UDVA/% eyes $\geq 20/20$
			CXL protocol and Riboflavin used	Pre-op		
Kanellopoulos et al., [70] 2012	Consecutive case series	43	10 mW/cm <sup>2</sup> , 3 min/Priavision/1.8 J/cm <sup>2</sup> /0.1% riboflavin, 60s	-7.5 $\pm$ 2.5	-0.2 $\pm$ 0.5	83.7%
Celik et al., [60] 2012	Prospective comparative	4,4	30 mW/cm <sup>2</sup> , 3 min/Avedro KXL/5.4 J/cm <sup>2</sup> /0.1% riboflavin, 90s	-5.00 to -8.50, -3.00 to -7.25	Mean Sph -0.50 to 0.25, -0.75 to -0.25	75%, 25%
Kanellopoulos et al., [70] 2014	Prospective comparative	73,82	30 mW/cm <sup>2</sup> , 80s/Avedro KXL/2.4 J/cm <sup>2</sup> /0.1% riboflavin with dextran, 60s	-6.58 $\pm$ 1.98, -5.14 $\pm$ 2.34	-0.19 $\pm$ 0.17, -0.27 $\pm$ 0.23	90.4%, 85.4%
Tomita et al., [61] 2014	Comparative	24,24FE	30 mW/cm <sup>2</sup> , 60s/Avedro KXL/1.8 J/cm <sup>2</sup> /0.1% riboflavin with 20% dextran, 60s	-4.45 $\pm$ 2.18, -4.43 $\pm$ 2.21	-0.13 $\pm$ 0.38-0.18 $\pm$ 0.34	100%, 95.7%
Kanellopoulos et al., [66] 2015	Randomised prospective comparative	65,75	30 mW/cm <sup>2</sup> , 80s/Avedro KXL/2.4 J/cm <sup>2</sup> /0.1% riboflavin, 60s	-6.67 $\pm$ 2.14, -5.49 $\pm$ 1.99	-0.18 $\pm$ 0.17, -0.32 $\pm$ 0.24	$\geq 20/20$ (93.8%), $\geq 20/25$ (95.5%), $\geq 20/20$ (84.8%), $\geq 20/25$ (89.3%), NA
Seiler et al., [69] 2015	Prospective comparative (high ectasia risk score of 3-6)	76,76	9 mW/cm <sup>2</sup> , 5 min/UVX 2000, IROC/2.7 J/cm <sup>2</sup> /0.5% riboflavin w/o dextran, 2 min	Mean sph, mean cyl -5.3 $\pm$ 2.9, -0.9 $\pm$ 0.7, -4.9 $\pm$ 1.9, -0.7 $\pm$ 0.6,	-0.21 $\pm$ 0.45, -0.05 $\pm$ 0.41,	
Wu et al., [62] 2016	Prospective controlled clinical trial	48, 48	30 mW/cm <sup>2</sup> , 90s/Avedro KXL/2.7 J/cm <sup>2</sup> /0.25% riboflavin, 90s	-6.54 $\pm$ 2.03-5.95 $\pm$ 2.33	-0.05 $\pm$ 0.33-0.02 $\pm$ 0.42	(logMAR)-0.17 $\pm$ 0.04/ 62.50% -0.18 $\pm$ 0.04/ 56.25%
Low et al., [63] 2017	Retrospective, comparative	50, 50	30 mW/cm <sup>2</sup> , 46s/Avedro KXL/1.4 J/cm <sup>2</sup> /0.22% riboflavin in saline, 45s	-9.45 $\pm$ 1.83-9.42 $\pm$ 0.97	+0.36 $\pm$ 0.42, +0.33 $\pm$ 0.46+0.26 $\pm$ 0.34	80%, 66%
Xu et al., [71] 2017	Prospective case series (unsatisfactory corneas)	22	30 mW/cm <sup>2</sup> , 90s/Avedro KXL/2.7 J/cm <sup>2</sup> /0.25% riboflavin, 90s	-5.53 $\pm$ 2.27	0.03 $\pm$ 0.82	(decimal) 1.03 $\pm$ 0.19
<b>LASIK Xtra (hyperopia)</b>						
Kanellopoulos et al., [72] 2012	Prospective randomised comparative	34,34	10 mW/cm <sup>2</sup> , 3 min/Avedro KXL/1.8 J/cm <sup>2</sup> /0.1% riboflavin, 60s	+3.15 $\pm$ 1.46, +3.40 $\pm$ 1.78	-0.20 $\pm$ 0.56, +0.20 $\pm$ 0.40	
Aslanides et al., [73] 2013	Prospective (LASIK Xtra) and retrospective (LASIK) comparative	5,5	3 mW/cm <sup>2</sup> , 30 min/UVX/1000 IROC/5.4 J/cm <sup>2</sup> /0.1% riboflavin, 2 min	+3.6 $\pm$ 2.1, +4.15 $\pm$ 2.0	-	(logMAR) 0.09, 0.17
Taneri et al., [74] 2017	Case report	2	30 mW/cm <sup>2</sup> , 90s/Avedro KXL/2.7 J/cm <sup>2</sup> /0.22% riboflavin, 90s	Refraction R:+1.25/-2.75 x 10° L: +0.50/-2.00 x 163°	-	(logMAR) R: 1.25 L: 0.25

Contd...

Table 2: Contd...

Author and year of publication	LASIK Xtra (hyperopia)			Complications	Follow-up (months)	Conclusion
	Safety index (LASIK Xtra, LASIK)	Efficacy index				
Kanellopoulos <i>et al.</i> , <sup>[70]</sup> 2012	1.09	1.09			42 (12-54)	LASIK Xtra appears safe and effective. No ectasia or significant regression observed.
Celik <i>et al.</i> , <sup>[60]</sup> 2012	-	-	None		12	All LASIK Xtra eyes preserved UDVA. Two LASIK eyes had myopic change: $\geq 2$ lines UDVA loss.
Kanellopoulos <i>et al.</i> , <sup>[67]</sup> 2014	-	-	None		12	Less refractive shift ( $P=0.063$ ) and better keratometric stability ( $P=0.039$ ) in LASIK Xtra group.
Tomita <i>et al.</i> , <sup>[61]</sup> 2014	1.01, 1.05	0.99, 1.00	Superficial punctuate keratitis (1 eye in each group)		12	No significant difference in refractive or keratometry ( $P>0.05$ ) results between the 2 groups.
Kanellopoulos <i>et al.</i> , <sup>[68]</sup> 2015	-	-	None		24	Less refractive shift ( $P=0.065$ ), better keratometric stability ( $P=0.032$ ) in LASIK Xtra group.
Seller <i>et al.</i> , <sup>[69]</sup> 2015	-	-	Erosions (16% DLK Stage 1 (38%), DLK Stage 2 (5%) Re-surgery planned in 2 eyes, performed in 1 (abandoned in 1 due to adherent flap)		12	Similar visual and refractive results in both groups but higher prevalence of transient side effects like DLK and delayed visual rehabilitation in LASIK Xtra group.
Wu <i>et al.</i> , <sup>[62]</sup> 2016	1.09 $\pm$ 0.32, 1.15 $\pm$ 0.23	1.02 $\pm$ 0.18 1.06 $\pm$ 0.25	2 eyes (4.17%) in the LASIK-ACXL group lost one or more lines		6	LASIK-ACXL can effectively correct myopia, with no significant complications, indicating stability and morphologic change similar to those with LASIK-only treatment.
Low <i>et al.</i> , <sup>[63]</sup> 2017	1.11 $\pm$ 0.19 1.11 $\pm$ 0.18	0.99 $\pm$ 0.17 0.94 $\pm$ 0.17	Grade 1 diffuse lamellar keratitis in 4 (8.0%) LASIK Xtra eyes, all resolved by post-operative day 2, Mild haze in 5 (10.0%) eyes, which resolved by last follow up in 3 eyes (2 eyes lost to follow up)		3 (both groups), 6-12 (LASIK Xtra)	LASIK Xtra achieved comparable safety, predictability and efficacy as LASIK in patients with high myopia. Good refractive stability was attained at 6-12 months
Xu <i>et al.</i> , <sup>[71]</sup> 2017	1.20	1.16	Mild glare (2 eyes)		24	LASIK Xtra is effective and safe for improving visual acuity for myopic patients with thin corneas.
<b>LASIK Xtra (hyperopia)</b>						
Kanellopoulos <i>et al.</i> , <sup>[72]</sup> 2012	-	-			24	LASIK only eyes showed significantly greater regression ( $P=0.0001$ )
Aslanides <i>et al.</i> , <sup>[73]</sup> 2013	1.27, 1.07	1.07, 0.83			48, 36	LASIK Xtra eyes showed no significant hyperopic regression but LASIK-only eyes showed a suggestive trend towards hyperopic regression.
Taneri <i>et al.</i> , <sup>[74]</sup> 2017	-	-	Corneal ectasia		24	Corneal ectasia developed in a patient with no risk factors for ectatic disease.

UV: ultraviolet; conc: concentration; pre-op: pre-operative; post-op: post-operative; SE: spherical equivalent; D: diopters; UDVA: uncorrected distance visual acuity; sph: sphere; cyl: cylinder; DLK: diffuse lamellar keratitis; FE: fellow eye Avedro KXL (Avedro, Inc., Waltham, MA, USA); UVX 2000 IROC (IROC Innocross AG, Zurich, Switzerland); Praviision (Praviision, Inc., Menlo Park, CA, USA) Efficacy index was calculated with the formula: mean post-operative UDVA (decimal)/pre-operative CDVA (decimal) Safety index was calculated with the formula: mean post-operative CDVA (decimal)/mean pre-operative CDVA (decimal) R: right eye; L: left eye

**Table 3: Long term studies on SMILE Xtra for treatment of myopia**

Author and year of publication	Study design	Number of eyes (SMILE Xtra, SMILE)	CXL protocol and Riboflavin used	SE (D)		Mean post op UDVA (logMAR)/% eyes $\geq$ 20/20 (SMILE Xtra, SMILE)	Safety index	Efficacy index	Complications	Followup (months)	Conclusion
				Pre-op	Post-op						
Ganesh <i>et al.</i> , <sup>[64]</sup> 2015	Prospective case series (moderate to high risk of ectasia - Randleman Scoring $\geq$ 3)	40	45 mW/cm <sup>2</sup> , 75s/ Avedro KXL/3.4 J/ cm <sup>2</sup> /0.25% riboflavin in saline, 60s	-5.02 $\pm$ 2.06	-0.24 $\pm$ 0.18	0.020 $\pm$ 0.06/95%	1.29	1.04	Nil	12	SMILE Xtra may be safe and feasible. No complications observed.
Ng <i>et al.</i> , <sup>[65]</sup> 2016	Prospective, comparative	21, 32	18 mW/cm <sup>2</sup> , 45s/ CXL-365 variosystem/0.8 J/ cm <sup>2</sup> /0.22% riboflavin with saline, 45s	-7.08 $\pm$ 1.67 -6.56 $\pm$ 1.05	-0.17 $\pm$ 0.26 +0.03 $\pm$ 0.25	20/25 (67%), 20/25 (94%)	0.96 $\pm$ 0.06 1.00 $\pm$ 0.00	0.88 $\pm$ 0.13 0.97 $\pm$ 0.06	Nil	6	SMILE Xtra had good overall safety profile and predictability at 6 months but in the early postoperative period, the safety index and efficacy index were significantly lower compared to controls.
Osman <i>et al.</i> , <sup>[66]</sup> 2019	Retrospective, comparative	30,30	18 mW/cm <sup>2</sup> , 3 min/CXL-365 variosystem/3.2 J/ cm <sup>2</sup> /0.1% riboflavin with 20% dextran, 15 min	-8.6 $\pm$ 1.1 -8.2 $\pm$ 1.2	-0.18 $\pm$ 0.19 -0.19 $\pm$ 0.18	0.031 $\pm$ 0.06/90% 0.028 $\pm$ 0.05/94%	1.29 1.28	1.09 1.12	Nil	24	SMILE Xtra is a safe and simple procedure for patients undergoing SMILE with risk for ectasia.

UV: ultraviolet; conc: concentration; pre-op: pre-operative; post-op: post-operative; SE: spherical equivalent; D: diopters; UDVA: uncorrected distance visual acuity; Avedro KXL (Avedro, Inc., Waltham, MA, USA); CXL-365 variosystem (CXL-365 variosystem, Inc., Schwind, Germany). Efficacy index was calculated with the formula: mean post-operative UDVA (decimal)/pre-operative CDVA (decimal); safety index was calculated with the formula: mean post-operative CDVA (decimal)/mean pre-operative CDVA (decimal)



Taneri *et al.*, 2 years post-LASIK Xtra in a hyperopic patient.<sup>[74]</sup> Similar to the observations of Celik *et al.* in myopic LASIK Xtra, Aslanides *et al.* reported a faint mid-stromal haze in the hyperopic LASIK Xtra on the first post-operative day, which resolved within 1 week.<sup>[73]</sup>

#### SMILE Xtra

All the three studies on SMILE Xtra reported good safety without any visually threatening complications observed at the end of the mean follow-up. In the prospective series by Ganesh *et al.*, CDVA remained stable and no complications such as keratitis, ectasia or regression were observed.<sup>[64]</sup> Two eyes which developed Grade 2 corneal haze, resolved within 3 months following treatment with topical steroids. No deleterious effect on endothelial cell counts was observed at 1 year ( $p = 0.22$ ). Both Ganesh *et al.* and Osman *et al.* observed high safety index of 1.29 with SMILE Xtra in their studies.<sup>[64,65]</sup> Ng *et al.* also concluded SMILE Xtra to be an overall safe procedure, however, the safety index of SMILE Xtra was slightly low (0.96) versus only SMILE (1.00).<sup>[65]</sup>

## Discussion

Post-operative refractive regression and corneal ectasia are two main post-op issues concerning the long-term safety and efficacy of corneal refractive surgeries. In LASIK, the average retreatment rate is 12%, most of which occur within the 2 years post-LASIK.<sup>[76-79]</sup> In cases of higher myopia, the rate of retreatment was as high as up to 30%.<sup>[80,81]</sup> On the other hand, the incidence of post-LASIK ectasia was found to be 0.03-0.66% in various studies.<sup>[16,82]</sup>

Both the ectasia and regression have been postulated to occur as a result of biomechanical changes affecting the strength of the cornea due to tissue removal.<sup>[72,73]</sup> Collagen cross-linking (CXL), is already a proven procedure to improve the biomechanical stability of corneas in keratoconus,<sup>[60,68]</sup> by creating additional chemical bonds between proteoglycans, histidine, hydroxyproline, hydroxylysine, tyrosine and threonine amino-acid residues within the collagen in the corneal stroma.<sup>[83,84]</sup> Apart from the biomechanical advantage, simultaneous CXL may also lead to less epithelial thickness increase, which is also implicated in the causation of regression.<sup>[85]</sup> Kanellopoulos *et al.* found that LASIK Xtra patients had less epithelial hyperplasia as compared to LASIK-only, suggesting that this could be a possible mechanism for the lower regression rates seen in LASIK Xtra.<sup>[86]</sup>

Li *et al.* in their recent review found that refractive surgery and simultaneous CXL produces comparable or better results in terms of refractive and keratometric stability than refractive surgery alone.<sup>[48]</sup> Analysing the refractive stability in long term studies (>1 year), we found that two comparative studies showed better keratometric stability in the LASIK Xtra group as compared to the LASIK-only group.<sup>[67,68]</sup> In hyperopic LASIK especially, the procedure consistently provided better refractive stability in both the comparative studies of hyperopic LASIK Xtra by Kanellopoulos *et al.* and Aslanides *et al.*, which concluded that LASIK Xtra eyes showed no significant hyperopic regression but LASIK-only eyes showed a suggestive trend towards hyperopic regression.<sup>[72,73]</sup> With PRK Xtra as well, Lee *et al.* observed similar keratometric changes in both PRK Xtra and PRK-only groups over 1-year follow-up. Mean MRSE remained stable and did not show any progressive flattening or refractive shift in either of the groups.<sup>[54]</sup> Sachdev *et al.* also

found no statistical difference in the 1 year mean postoperative MRSE between the two groups.<sup>[56]</sup> For SMILE Xtra, Osman *et al.* compared SMILE Xtra with SMILE for high myopia (SE pre SMILE Xtra -8.6 D vs -8.2 D pre SMILE) and found similar MRSE values (-0.18D in SMILE Xtra, -0.19 D in SMILE) in both the groups at 24 months, suggesting that SMILE Xtra provided stable results and no hyperopic shift was observed over time.<sup>[66]</sup>

With regards to post-operative ectasia, none of the eyes treated with PRK Xtra and SMILE Xtra procedures progressed to ectasia in long term studies published so far.<sup>[55,56]</sup> However, one case report of post-operative unilateral ectasia occurring 2 years after Hyperopic LASIK Xtra in an 18-year-old young male patient has been published by Taneri *et al.*<sup>[77]</sup> As per the report, the pre-operative topography of the left eye was suggestive of forme fruste keratoconus (FFKC), in which a microkeratome assisted LASIK surgery was performed. This was implicated as the cause of ectasia as the flap thickness achieved was uneven, resulting in biomechanical instability leading to ectasia in this patient.<sup>[74]</sup>

The choice of procedure (PRK/LASIK/SMILE) to be combined with simultaneous CXL, may also influence the incidence of post-operative ectasia development. Theoretically, flapless procedures such as PRK and SMILE may be preferred over LASIK (where a corneal flap is made), for combination with Xtra procedures in borderline corneas. It is well known that vertical cuts (for flap creation in LASIK) lead to greater biomechanical weakening compared to delamination cuts (such as with SMILE procedure).<sup>[30]</sup> Hence, the biomechanical stability of LASIK Xtra may be questionable, where in addition to tissue removal, a corneal flap is also created which does not contribute to the post-operative corneal strength. This may lead to higher degree of biomechanical instability and the simultaneous CXL done with the purpose of future prophylaxis, may not be effective enough to prevent ectasia. An indirect evidence of improved stability achieved with SMILE Xtra comes from a recent publication by Hernandez *et al.*, where the authors performed SMILE Xtra in 15 eyes of diagnosed cases of FFKC/irregular corneas, and follow up ranging from 12- 24 months suggested good refractive outcomes and stability, as no case deteriorated to further ectasia. The authors concluded that combined SMILE with intrastromal cross-linking could be a promising treatment option for patients for whom conventional laser refractive surgery is contraindicated.<sup>[87]</sup> However, it is not recommended to perform refractive surgery with simultaneous cross-linking in eyes with FFKC, or suspect KCN, as the safety of the same in this scenario has not been yet established. Moreover, these corneas are already compromised, and performing an Xtra procedure may not be prevent the future risk of ectasia, in our opinion.

However, both LASIK Xtra and SMILE Xtra may have a distinct advantage over PRK Xtra, in terms of post-operative healing and patient comfort, as the CXL is performed through the flap/cap through an intact epithelium, which significantly reduces the chances of post-op complications such as prolonged wound healing, pain, infectious keratitis, and excessive haze formation.<sup>[55,66,68,70]</sup>

One aspect in the context of combined refractive surgery and simultaneous CXL which is unclear, and needs further evaluation is the CXL protocol to be used with different kinds of surgeries. The total UV-A energy exposure used in studies varies greatly from as low as 0.8 J/cm<sup>2</sup> to as high as 5.4 J/cm<sup>2</sup>.<sup>[18,39,58,65]</sup>

The rationale for using a lower UV-A total energy is that it is performed in normal and not keratoconic eyes and thus, the indication for CXL is prophylactic rather than therapeutic. Additionally, the accelerated protocol is expected to prevent excessive keratometric flattening, which may be an outcome with the conventional CXL.<sup>[88]</sup> Also, lower UV-A energy may reduce the severity of potential complications. Higher total UV-A energy exposures were shown to be associated with diffuse lamellar keratitis in myopic LASIK Xtra [Seiler *et al.*: 2.7 J/cm<sup>2</sup>],<sup>[69]</sup> central toxic keratopathy in PRK Xtra [Davey *et al.* 3.6 J/cm<sup>2</sup>]<sup>[75]</sup> and excessive interface haze in SMILE Xtra [Hernandez *et al.*: 5.4 J/cm<sup>2</sup>].<sup>[87]</sup> It is noteworthy to mention here that the SMILE Xtra series by Hernandez *et al.* was conducted on eyes with FFKC, and hence a full therapeutic dose of 5.4 J/cm<sup>2</sup> was indicated. The interface haze was observed in 60% (9 eyes of 5 patients) had clinically significant opacity. The haze appeared to be maximal at around the first month of follow-up but improved gradually. At the third month visit, almost no haze was detectable.

This is in accordance with a study by Piyacomn *et al.* evaluating the corneal densitometry changes after various Xtra procedures (PRK Xtra, LASIK Xtra and SMILE Xtra), wherein they found that corneal densitometry at anterior layer of 0–10 mm zone and central layer of 0–6 mm zone increased at 1 and 3 months ( $p < 0.05$ ). At 6 months, the densitometry at 0–6 mm zone returned to baseline level.<sup>[89]</sup> However, which procedure out of the three resulted in maximum change in densitometry has not been specified in the paper.

Theoretically, as well as based on the present evidence, PRK Xtra may be associated with highest risk of post-operative development of haze. This is because in addition to the CXL associated haze, PRK procedure inherently can lead to haze formation, especially in higher degrees of corrections.<sup>[10]</sup> In the reviewed literature, corneal haze of varying degrees was observed in 3 out of 4 studies in PRK Xtra.<sup>[55-57]</sup> In contrast, only 2 studies on LASIK Xtra reported mild haze in the early post-op period, while no study on SMILE Xtra showed evidence of significant haze at the end of mean follow-up.<sup>[60,61,64-74]</sup>

Ohana *et al.* reported significant corneal haze in 4 eyes undergoing PRK Xtra, of which 3 eyes lost >2 Snellen's lines. The haze persisted at a mean follow up of 25.34 months and did not resolve with topical steroids.<sup>[55]</sup> Sachdev *et al.* observed grade 1 corneal haze in 9/109 eyes in PRK Xtra group, of which 1 eye lost 1 line of CDVA at 12 months.<sup>[56]</sup> In the study by Hyun *et al.* comparing SMILE, LASEK and LASEK-Xtra for high myopia, no eye had corneal haze after SMILE, however, 18% eyes following LASEK and 25% eyes following LASEK-Xtra had corneal haze persisting at the last follow-up of 6 months.<sup>[57]</sup> However, no haze was reported by Lee *et al.* in their study comparing transepithelial PRK (tPRK) versus tPRK Xtra at 12 months.<sup>[54]</sup> This may be attributed to the intra-operative use of 0.02% Mitomycin-C (MMC) by the authors, which is already known to reduce the incidence of post-op haze after PRK procedure due to its inhibitory action on fibroblast proliferation causing cell apoptosis.<sup>[90]</sup> However, the reason behind avoidance of MMC in PRK- Xtra studies<sup>[55,57]</sup> was not specified, except in the study by Sachdev *et al.*, wherein the authors expected lower incidence of haze due to cross-linking induced keratocyte apoptosis in the anterior corneal stroma.<sup>[56]</sup>

The only study reporting clinically significant haze with SMILE Xtra is the one reported by Hernandez *et al.* which was

performed in FFKC eyes using a high energy of 5.4 J/cm<sup>2</sup> of UV-A radiation, which resolved over time and did not affect the final visual outcomes.<sup>[87]</sup>

Comparative studies show that combined refractive surgery and simultaneous accelerated CXL have similar or better efficacies as compared to refractive surgery alone. Six out of 7 studies comparing LASIK Xtra versus LASIK- only for myopia correction reported better UDVA outcomes and efficacy index in LASIK Xtra group.<sup>[60-63,67,68]</sup> Data on efficacy of PRK Xtra versus PRK and SMILE Xtra versus SMILE is limited, however, reported studies<sup>[54,56,57,65,66]</sup> with these procedures have shown comparable visual outcomes in terms of UDVA suggesting that simultaneous CXL along with corneal refractive surgery did not lead to any significant side effects affecting UDVA.

Data on corneal biomechanics after Xtra procedures is limited. One comparison study on SMILE Xtra by Osman *et al.*<sup>[66]</sup> reported that both SMILE and SMILE Xtra procedures significantly reduced corneal resistance factor (CRF) measured with Ocular Response Analyzer (ORA), from pre-operative levels; however, the mean post-op value of CRF was significantly higher in the SMILE Xtra group at 24 months, suggesting that SMILE Xtra may be biomechanically a more stable procedure than SMILE alone.

The use of simultaneous CXL with refractive surgeries at present is recommended in borderline corneas which are "at risk" of post-operative ectasia or eyes where a higher incidence of regression is expected (higher degrees of myopia/hyperopia). The use of Xtra procedures in routine clinical practice may not be justified considering the additional cost and CXL related potential complications.<sup>[91-94]</sup>

## Conclusion

Results of this review suggest that combined refractive surgery and simultaneous CXL is generally safe and effective in stabilising refractive and keratometric outcomes in patients. The Xtra procedures have certainly expanded the scope of corneal refractive surgeries, especially for cases which are borderline with respect to pre-op topography, pachymetry, residual bed thickness etc., as they possess higher risk of iatrogenic ectasia development in future. However, it may still be early to draw solid conclusions on this subject, as the sample sizes used in many of the studies (especially on LASIK Xtra for hyperopia, PRK Xtra and SMILE Xtra) were relatively small and there is a lack of long-term data. Since iatrogenic keratectasia can occur anywhere from 1 week to several years after refractive surgery, more randomised comparative studies with longer follow-ups (> 2 years), are suggested to further evaluate the safety and efficacy of these procedures. Additionally, there is a need to optimize UV-A irradiation settings, specific for various procedures, in order to reduce the incidence and severity of potential complications. Since, refractive surgery with simultaneous cross linking is not recognised as a standard treatment of care and many aspects linked to these procedures are still unanswered, it is therefore essential to weigh the long-term benefits and risks associated with these procedures.

## Financial support and sponsorship

Nil.

### Conflicts of interest

There are no conflicts of interest.

### References

- Seiler T, Kahle G, Kriegerowski M, Wollensak J. [Laser keratomileusis for correction of myopia]. *Fortschr Ophthalmol* 1990;87:479-83.
- Gartry DS, Kerr Muir MG, Marshall J. Photorefractive keratectomy with an argon fluoride excimer laser: A clinical study. *Refract Corneal Surg* 1991;7:420-35.
- O'Brart DP, Gartry DS, Lohmann CP, Muir MG, Marshall J. Excimer laser photorefractive keratectomy for myopia: Comparison of 4.00- and 5.00-millimeter ablation zones. *J Refract Corneal Surg* 1994;10:87-94.
- Pallikaris IG, Siganos DS. Excimer laser *in situ* keratomileusis and photorefractive keratectomy for correction of high myopia. *J Refract Corneal Surg* 1994;10:498-510.
- O'Brart DP. Excimer laser surface ablation: A review of recent literature. *Clin Exp Optom* 2014;97:12-7.
- Moshirfar M, McCaughey MV, Reinstein DZ, Shah R, Santiago-Caban L, Fenzl CR. Small-incision lenticule extraction. *J Cataract Refract Surg* 2015;41:652-65.
- Lohmann C. P., Reischl U., Marshall J. Regression and epithelial hyperplasia after myopic photorefractive keratectomy in a human cornea. *J Cataract Refract Surg* 1999;25:712-5.
- Chayet AS, Assil KK, Montes M, Espinosa-Lagana M, Castellanos A, Tsioulias G. Regression and its mechanisms after laser *in situ* keratomileusis in moderate and high myopia. *Ophthalmology* 1998;105:1194-9.
- Mattila JS, Holopainen JM. Bilateral ectasia after femtosecond laser-assisted Small Incision Lenticule Extraction (SMILE). *J Refract Surg* 2016;32:497-500.
- Spadea L, Giovannetti F. Main complications of photorefractive keratectomy and their management. *Clin Ophthalmol* 2019;13:2305-15.
- Seiler T, Koufala K, Richter G. Iatrogenic keratectasia after laser *in situ* keratomileusis. *J Refract Surg* 1998;14:312-7.
- Jaycock PD, Lobo L, Ibrahim J, Tyrer J, Marshall J. Interferometric technique to measure biomechanical changes in the cornea induced by refractive surgery. *J Cataract Refract Surg* 2005;31:175-84.
- Dawson DG, Grossniklaus HE, McCarey BE, Edelhofer HF. Biomechanical and wound healing characteristics of corneas after excimer laser keratorefractive surgery: Is there a difference between advanced surface ablation and sub-Bowman's keratomileusis? *J Refract Surg* 2008;24:S90-6.
- Chen MC, Lee N, Bourla N, Hamilton DR. Corneal biomechanical measurements before and after laser *in situ* keratomileusis. *J Cataract Refract Surg* 2008;34:1886-91.
- Roberts CJ, Dupps WJ Jr. Biomechanics of corneal ectasia and biomechanical treatments. *J Cataract Refract Surg* 2014;40:991-8.
- Pallikaris IG, Kymionis GD, Astyrakakis NI. Corneal ectasia induced by laser *in situ* keratomileusis. *J Cataract Refract Surg* 2001;27:1796-802.
- Parmar D, Claoue C. Keratectasia following excimer laser photorefractive keratectomy. *Acta Ophthalmol Scand* 2004;82:102-5.
- Binder PS. Analysis of ectasia after laser *in situ* keratomileusis: Risk factors. *J Cataract Refract Surg* 2007;33:1530-8.
- El-Naggar MT. Bilateral ectasia after femtosecond laser-assisted small-incision lenticule extraction. *J Cataract Refract Surg* 2015;41:884-8.
- Seiler T, Quirke AW. Iatrogenic keratectasia after LASIK in a case of forme fruste keratoconus. *J Cataract Refract Surg* 1998;24:1007-9.
- Buzard KA, Tuengler A, Febraro JL. Treatment of mild to moderate keratoconus with laser *in situ* keratomileusis. *J Cataract Refract Surg* 1999;25:1600-9.
- El-Naggar MT. Bilateral ectasia after femtosecond laser-assisted small-incision lenticule extraction. *J Cataract Refract Surg* 2015;41(4):884-888
- Santhiago MR, Giacomini NT, Smadja D, Bechara SJ. Ectasia risk factors in refractive surgery. *Clin Ophthalmol* 2016;10:713-20.
- Sorkin N, Kaiserman I, Domniz Y, Sela T, Munzer G, Varssano D. Risk assessment for corneal ectasia following photorefractive keratectomy. *J Ophthalmol* 2017;2017:2434830. doi: 10.1155/2017/2434830.
- Giri P, Azar DT. Risk profiles of ectasia after keratorefractive surgery. *Curr Opin Ophthalmol* 2017;28:337-42.
- Sinha Roy A, Dupps WJ Jr, Roberts CJ. Comparison of biomechanical effects of small-incision lenticule extraction and laser *in situ* keratomileusis: Finite-element analysis. *J Cataract Refract Surg* 2014;40:971-80.
- Malecaze F, Couillet J, Calvas P, Fournié P, Arné JL, Brodaty C. Corneal ectasia after photorefractive keratectomy for low myopia. *Ophthalmology* 2006;13:742-6.
- Wang Y, Cui C, Li Z, Tao X, Zhang C, Zhang X, *et al.* Corneal ectasia 6.5 months after small-incision lenticule extraction. *J Cataract Refract Surg* 2015;41:1100-6.
- Sachdev G, Sachdev MS, Sachdev R, Gupta H. Unilateral corneal ectasia following small-incision lenticule extraction. *J Cataract Refract Surg* 2015;41:2014-8.
- Reinstein DZ, Archer TJ, Randleman JB. Mathematical model to compare the relative tensile strength of the cornea after PRK, LASIK, and small incision lenticule extraction [published correction appears in *J Refract Surg* 2017 Nov 1;33:788]. *J Refract Surg* 2013;29:454-60.
- Moshirfar M, Albarracin JC, Desautels JD, Birdsong OC, Linn SH, Hoopes PC Sr. Ectasia following small-incision lenticule extraction (SMILE): A review of the literature. *Clin Ophthalmol* 2017;11:1683-8.
- Shetty R, Kumar NR, Khamar P, Francis M, Sethu S, Randleman JB, *et al.* Bilaterally asymmetric corneal ectasia following SMILE with asymmetrically reduced stromal molecular markers. *J Refract Surg* 2019;35:6-14.
- Wang JC, Hufnagel TJ, Buxton DF. Bilateral keratectasia after unilateral laser *in situ* keratomileusis: A retrospective diagnosis of ectatic corneal disorder. *J Cataract Refract Surg* 2003;29:2015-8.
- Randleman JB, Trattler WB, Stulting RD. Validation of the Ectasia Risk Score System for preoperative laser *in situ* keratomileusis screening. *Am J Ophthalmol* 2008;145:813-8.
- Wolle MA, Randleman JB, Woodward MA. Complications of refractive surgery: Ectasia after refractive surgery. *Int Ophthalmol Clin* 2016;56:127-39.
- Belin MW, Ambrosio R Jr. Corneal ectasia risk score: Statistical validity and clinical relevance. *J Refract Surg* 2010;26:238-40.
- Randleman JB, Woodward M, Lynn MJ, Stulting RD. Risk assessment for ectasia after corneal refractive surgery. *Ophthalmology* 2008;115:37-50.
- Ambrósio R Jr, Lopes BT, Faria-Correia F, Salomão MQ, Bühren J, Roberts CJ, *et al.* Integration of Scheimpflug-based corneal tomography and biomechanical assessments for enhancing ectasia detection. *J Refract Surg* 2017;33:434-43.
- Ong HS, Farook M, Tan BBC, Williams GP, Santhiago MR, Mehta JS. Corneal ectasia risk and percentage tissue altered in myopic patients presenting for refractive surgery. *Clin Ophthalmol* 2019;13:2003-15.

40. Rabinowitz YS. Keratoconus. *Surv Ophthalmol* 1998;42:297–319.
41. Wollensak G, Spoerl E, Seiler T. Riboflavin/ultraviolet-a-induced collagen crosslinking for the treatment of keratoconus. *Am J Ophthalmol* 2003;135:620-7.
42. Sharif R, Fowler B, Karamichos D. Collagen cross-linking impact on keratoconus extracellular matrix. *PLoS One* 2018;13:e0200704.
43. Subasinghe SK, Ogbuehi KC, Dias GJ. Current perspectives on corneal collagen crosslinking (CXL). *Graefes Arch Clin Exp Ophthalmol* 2018;256:1363-84.
44. Hersh PS, Greenstein SA, Fry KL. Corneal collagen crosslinking for keratoconus and corneal ectasia: One-year results. *J Cataract Refract Surg* 2011;37:149-60.
45. Sorkin N, Varssano D. Corneal collagen crosslinking: A systematic review. *Ophthalmologica* 2014;232:10-27.
46. Deshmukh R, Hafezi F, Kymionis GD, Kling S, Shah R, Padmanabhan P, et al. Current concepts in crosslinking thin corneas. *Indian J Ophthalmol* 2019;67:8-15.
47. Hersh PS, Lai MJ, Gelles JD, Lesniak SP. Transepithelial corneal crosslinking for keratoconus. *J Cataract Refract Surg* 2018;44:313-22.
48. Lim EWL, Lim L. Review of laser vision correction (LASIK, PRK and SMILE) with simultaneous accelerated corneal crosslinking-long-term results. *Curr Eye Res* 2019;44:1171-80.
49. Gomel N, Negari S, Frucht-Pery J, Wajnsztajn D, Strassman E, Solomon A. Predictive factors for efficacy and safety in refractive surgery for myopia. *PLoS One* 2018;13:e0208608.
50. Pérez-Santonja JJ, Bellot J, Claramonte P, Ismail MM, Alió JL. Laser *in situ* keratomileusis to correct high myopia. *J Cataract Refract Surg* 1997;23:372–85.
51. Amoils SP, Deist MB, Gous P, Amoils PM. Iatrogenic keratectasia after laser *in situ* keratomileusis for less than – 4.0 to – 7.0 diopters of myopia. *J Cataract Refract Surg* 2000;26:967–77.
52. Spadea L, Cantera E, Cortes M, Conocchia NE, Stewart CW. Corneal ectasia after myopic laser *in situ* keratomileusis: A long-term study. *Clin Ophthalmol* 2012;6:1801-13.
53. Moshirfar M, Smedley JG, Muthappan V, Jarsted A, Ostler EM. Rate of ectasia and incidence of irregular topography in patients with unidentified preoperative risk factors undergoing femtosecond laser-assisted LASIK. *Clin Ophthalmol* 2014;8:35-42.
54. Lee H, Yong Kang DS, Ha BJ, Choi JY, Kim EK, Seo KY, et al. Comparison of outcomes between combined transepithelial photorefractive keratectomy with and without accelerated corneal collagen cross-linking: A 1-year study. *Cornea* 2017;36:1213-20.
55. Ohana O, Kaiserman I, Domniz Y, Cohen E, Franco O, Sela T, et al. Outcomes of simultaneous photorefractive keratectomy and collagen crosslinking. *Can J Ophthalmol* 2018;53:523-8.
56. Sachdev GS, Ramamurthy S, Dandapani R. Comparative analysis of safety and efficacy of photorefractive keratectomy versus photorefractive keratectomy combined with crosslinking. *Clin Ophthalmol* 2018;12:783-90.
57. Hyun S, Lee S, Kim JH. Visual outcomes after SMILE, LASEK, and LASEK combined with corneal collagen cross-linking for high myopic correction. *Cornea* 2017;36:399-405.
58. Avedro product literature: KXL cross-linking protocols for LASIK Xtra, keratoconus and corneal ectasia. April 2015. MA-00255C.
59. Tan J, Lytle GE, Marshall J. Consecutive laser *in situ* keratomileusis and accelerated corneal crosslinking in highly myopic patients: Preliminary results. *Eur J Ophthalmol* 2014. doi: 10.5301/ejo.5000543.
60. Celik HU, Alagoz N, Yildirim Y, Agca A, Marshall J, Demirok A, et al. Accelerated corneal crosslinking concurrent with laser *in situ* keratomileusis. *J Cataract Refract Surg* 2012;38:1424-31.
61. Tomita M, Yoshida Y, Yamamoto Y, Mita M, Waring Gt. *In vivo* confocal laser microscopy of morphologic changes after simultaneous LASIK and accelerated collagen crosslinking for myopia: One- year results. *J Cataract Refract Surg* 2014;40:981-90.
62. Wu Y, Tian L, Wang LQ, Huang YF. Efficacy and safety of LASIK combined with accelerated corneal collagen cross-linking for myopia: Six-month study. *Biomed Res Int* 2016;2016:5083069. doi: 10.1155/2016/5083069.
63. Low JR, Lim L, Koh JCW, Chua DKP, Rosman M. Simultaneous accelerated corneal crosslinking and laser *in situ* keratomileusis for the treatment of high myopia in Asian eyes. *Open Ophthalmol J* 2018;12:143-53.
64. Ganesh S, Brar S. Clinical outcomes of small incision lenticule extraction with accelerated cross- linking (ReLEx SMILE Xtra) in patients with thin corneas and borderline topography. *J Ophthalmol* 2015;2015:263412. doi: 10.1155/2015/263412.
65. Ng AL, Chan TC, Cheng GP, Jhanji V, Ye C, Woo VC, et al. Comparison of the early clinical outcomes between combined small-incision lenticule extraction and collagen cross-linking versus SMILE for myopia. *J Ophthalmol* 2016;2016:2672980. doi: 10.1155/2016/2672980.
66. Osman IM, Helaly HA, Abou Shousha M, AbouSamra A, Ahmed I. Corneal safety and stability in cases of small incision lenticule extraction with collagen cross-linking (SMILE Xtra). *J Ophthalmol* 2019;2019:6808062. doi: 10.1155/2019/6808062.
67. Kanellopoulos AJ, Asimellis G, Karabatsas C. Comparison of prophylactic higher fluence corneal cross-linking to control, in myopic LASIK, one year results. *Clin Ophthalmol* 2014;8:2373-81.
68. Kanellopoulos AJ, Asimellis G. Combined laser *in situ* keratomileusis and prophylactic high-fluence corneal collagen crosslinking for high myopia: Two-year safety and efficacy. *J Cataract Refract Surg* 2015;41:1426-33.
69. Seiler TG, Fischinger I, Koller T, Derhartunian V, Seiler T. Superficial corneal crosslinking during laser *in situ* keratomileusis. *J Cataract Refract Surg* 2015;41:2165-70.
70. Kanellopoulos AJ. Long-term safety and efficacy follow-up of prophylactic higher fluence collagen cross-linking in high myopic laser-assisted *in situ* keratomileusis. *Clin Ophthalmol* 2012;6:1125-30.
71. Xu W, Tao Y, Wang L, Huang Y. Evaluation of biomechanical changes in myopia patients with unsatisfactory corneas after Femto Second-Laser *In Situ* Keratomileusis (FS-LASIK) concurrent with accelerated corneal collagen cross-linking using Corvis-ST: Two-year follow-up results. *Med Sci Monit* 2017;23:3649-56.
72. Kanellopoulos AJ, Kahn J. Topography-guided hyperopic LASIK with and without high irradiance collagen cross-linking: Initial comparative clinical findings in a contralateral eye study of 34 consecutive patients. *J Refract Surg* 2012;28 (11 Suppl):S837-40.
73. Aslanides IM, Mukherjee AN. Adjuvant corneal crosslinking to prevent hyperopic LASIK regression. *Clin Ophthalmol* 2013;7:637-41.
74. Taneri S, Kiessler S, Rost A, Dick HB. Corneal ectasia after LASIK combined with prophylactic corneal cross-linking. *J Refract Surg* 2017;33:50-2.
75. Davey N, Aslanides IM, Selimis V. A case report of central toxic keratopathy in a patient post TransPRK (followed by corneal collagen cross-linking). *Int Med Case Rep J* 2017;10:131-8.
76. Yuen LH, Chan WK, Koh J, Mehta JS, Tan DT; SingLasik Research Group. A 10-year prospective audit of LASIK outcomes for myopia in 37,932 eyes at a single institution in Asia. *Ophthalmology* 2010;117:1236-44.e1
77. Alio JL, Muftuoglu O, Ortiz D, Perez-Santonja JJ, Artola A, Ayala MJ, et al. Ten-year follow-up of laser *in situ* keratomileusis for high myopia. *Am J Ophthalmol* 2008;145:55-64.

78. Hersh PS, Fry KL, Bishop DS. Incidence and associations of retreatment after LASIK. *Ophthalmology* 2003;110:748-54.
79. Randleman JB, White AJ Jr, Lynn MJ, Hu MH, Stulting RD. Incidence, outcomes, and risk factors for retreatment after wavefront-optimized ablations with PRK and LASIK. *J Refract Surg* 2009;25:273-6.
80. Sugar A, Rapuano CJ, Culbertson WW, Huang D, Varley GA, Agapitos PJ, *et al.* Laser *in situ* keratomileusis for myopia and astigmatism: Safety and efficacy: A report by the American Academy of Ophthalmology. *Ophthalmology* 2002;109:175-87.
81. Alio JL, Soria F, Abbouda A, Pena-Garcia P. Laser *in situ* keratomileusis for -6.00 to -18.00 diopters of myopia and up to -5.00 diopters of astigmatism: 15-year follow-up. *J Cataract Refract Surg* 2015;41:33-40.
82. Bohac M, Koncarevic M, Pasalic A, Biscevic A, Merlak M, Gabric N, *et al.* Incidence and clinical characteristics of post LASIK Ectasia: A review of over 30,000 LASIK cases. *Semin Ophthalmol* 2018;33:869-77.
83. McCall AS, Kraft S, Edelhauser HF, Kidder GW, Lundquist RR, Bradshaw HE, *et al.* Mechanisms of corneal tissue cross-linking in response to treatment with topical riboflavin and long-wavelength ultraviolet radiation (UVA). *Invest Ophthalmol Vis Sci* 2010;51:129-38.
84. Hovakimyan M, Guthoff RF, Stachs O. Collagen cross-linking: Current status and future directions. *J Ophthalmol* 2012;2012:406850. doi: 10.1155/2012/406850.
85. Kanellopoulos AJ, Asimellis G. Longitudinal postoperative lasik epithelial thickness profile changes in correlation with degree of myopia correction. *J Refract Surg* 2014;30:166-71.
86. Kanellopoulos AJ, Asimellis G. Epithelial remodeling after femtosecond laser-assisted high myopic LASIK: Comparison of stand-alone with LASIK combined with prophylactic high-fluence cross-linking. *Cornea* 2014;33:463-9.
87. Graue-Hernandez EO, Pagano GL, Garcia-De la Rosa G, Ramirez-Miranda A, Cabral-Macias J, Lichtinger A, *et al.* Combined small-incision lenticule extraction and intrastromal corneal collagen crosslinking to treat mild keratoconus: Long-term follow-up. *J Cataract Refract Surg* 2015;41:2524-32.
88. Shetty R, Pahuja NK, Nuijts RM, Ajani A, Jayadev C, Sharma C, *et al.* Current protocols of corneal collagen cross-linking: Visual, refractive, and tomographic outcomes. *Am J Ophthalmol* 2015;160:243-9.
89. Piyacomn Y, Kasetsuwan N, Puangsrucharern V, Reinprayoon U, Satitpitakul V, Chantaren P. Topometric indices and corneal densitometry change after corneal refractive surgery combined with simultaneous collagen crosslinking. *Clin Ophthalmol* 2019;13:1927-33.
90. Diakonis VF, Kankariya VP, Kymionis GD, Kounis G, Kontadakis G, Gkenos E, *et al.* Long term followup of photorefractive keratectomy with adjuvant use of mitomycin C. *J Ophthalmol* 2014;2014:821920. doi: 10.1155/2014/821920.
91. Lim L, Lim EWL. A review of corneal collagen cross-linking-Current trends in practice applications. *Open Ophthalmol J* 2018;12:181-213.
92. Raiskup-Wolf F, Hoyer A, Spoerl E, Pillunat LE. Collagen crosslinking with riboflavin and ultraviolet-A light in keratoconus: Long-term results. *J Cataract Refract Surg* 2008;34:796-801.
93. Caporossi A, Mazzotta C, Baiocchi S, Caporossi T. Long-term results of riboflavin ultraviolet a corneal collagen cross-linking for keratoconus in Italy: The Siena eye cross study. *Am J Ophthalmol* 2010;149:585-93.
94. Dhawan S, Rao K, Natrajan S. Complications of corneal collagen cross-linking. *J Ophthalmol* 2011;2011:869015. doi: 10.1155/2011/869015.