



Open Access

ORIGINAL ARTICLE

Male Endocrinology

Time-dependent effects of castration on the bladder function and histological changes in the bladder and blood vessels

Tomohiro Magari^{1,2}, Yasuhiro Shibata¹, Seiji Arai¹, Bunzo Kashiwagi¹, Keiji Suzuki³, Kazuhiro Suzuki¹

We examined the effect of androgens on bladder blood flow (BBF), bladder function and histological changes in castrated male rats. Male Wistar rats were classified into unoperated group (control group), groups castrated at the age of 8 weeks (group 8wPC) and groups castrated at the age of 4 weeks (group 4wPC). Each rat was used at the age of 20 weeks. BBF was measured using fluorescent microspheres. Bladder cystometry was performed without anesthesia or restraint; the bladder was first irrigated with saline and then with 0.25% acetic acid (AA) solution. Maximum voiding pressure and voiding interval were measured. The bladder and iliac artery were histologically examined for differences in smooth muscle and quantity of collagen fiber to analyze the effect of castration on the smooth muscle content. No differences were noted in BBF following castration. The voiding intervals for all groups were shortened ($P < 0.001$) following AA irrigation. No significant difference was noted in the maximum voiding pressure. Histological changes were observed in bladder and iliac artery. Smooth muscle/collagen ratio at the bladder was lower in groups 8wPC and 4wPC compared to the control group ($P < 0.01$), while that at the iliac artery was decreased in group 4wPC compared to the control group ($P < 0.001$). In conclusion, our findings indicate that castration does not alter BBF, but leads to histological changes in the bladder as well as its associated blood vessels.

Asian Journal of Andrology (2014) 16, 457–460; doi: 10.4103/1008-682X.123676; published online: 18 February 2014

Keywords: bladder blood flow; bladder function; castration; fluorescent microsphere method; histological changes; smooth muscle/collagen ratio

INTRODUCTION

Androgens may participate in male lower urinary tract symptoms (LUTS), primarily through their effects on prostate growth and function.^{1–6} Although the effects of androgens on the prostate are well-established, there are certain symptoms that cannot be explained by changes in prostate size and function alone. Some reports have investigated the relationship between androgens and bladder function, and an evaluation of the effect of androgens on blood vessels has indicated that vascular endothelial cell growth is suppressed due to low testosterone along with enhanced calcification of the blood vessel wall.⁷ Similarly, a previous report has examined the association between bladder blood flow (BBF) and bladder outlet obstruction;^{8,9} however, there are few studies that examined the association between male hormones and BBF.^{10,11} Therefore, in this study, we examined the effects of androgens on BBF, bladder irritability and histological changes after castration using a castrated Wistar rat model.

MATERIALS AND METHODS

Animal protocol

All surgical and experimental procedures were approved by the Institutional Laboratory Animal Care and Use Committee of Gunma University School of Medicine and were conducted in accordance with

their guidelines. The male Wistar rats used in this study were purchased from Charles River Laboratories Inc (Kanagawa, Japan), housed under controlled conditions, and given water and food pellets *ad libitum* for at least 1 week before and during the experiments. The rats were classified into the following groups: control unoperated group (control), mature group castrated at the age of 8 weeks (group 8wPC) and immature group castrated at the age of 4 weeks (group 4wPC) (Table 1). Each rat was used at the age of 20 weeks. Castration was performed by the scrotal route.

BBF measurement

We measured BBF using the fluorescent microsphere method described below and examined changes in BBF following castration.

The microsphere method is known to reliably measure organ blood flow, including that in the lower urinary tract.^{8,9} All three groups of rats ($n = 8$ in each group) were anesthetized with pentobarbital

Table 1: Body weight and bladder weight of each group

	Control	8wPC group	4wPC group
Body weight (g)	542.5±36.0	489.0±32.8	555.3±60.0
Bladder weight (g)	0.23±0.05	0.20±0.03	0.20±0.04

s.d.: standard deviation. Values are represented as the mean ± s.d.

¹Department of Urology, Gunma University Graduate School of Medicine, Maebashi; ²Department of Urology, Kurosawa Hospital, Takasaki; ³Department of Pathology, Gunma University Graduate School of Health Sciences, Maebashi, Japan.

Correspondence: Dr. T Magari (magari@showa.gunma-u.ac.jp)

Received: 07 May 2013; Revised: 14 July 2013; Accepted: 01 September 2013

sodium (40 mg kg^{-1} intraperitoneal); the left carotid artery and left femoral artery were cannulated (Becton Dickinson Co. Ltd, Flanklin Lakes, USA); and the bladder was punctured anteriorly with an indwelling needle to collect the residual urine. Arterial blood pressure was measured with a pressure amplifier (Nihon Kohden, Tokyo, Japan) via a pressure transducer (Nihon Kohden) connected to a catheter inserted into the carotid artery. Then, 0.5 ml of saline was injected into the bladder to ensure uniformity in the degree of bladder stretching (approximately 30% of bladder capacity). Arterial blood pressure was continuously measured using the catheter placed in the carotid artery. The femoral arterial cannula was connected to a heparinized syringe to collect blood (0.9 ml) at the rate of 0.6 ml min^{-1} using a syringe pump (Minato Concept Inc, Tokyo, Japan). At the same time, 0.2 ml of a yellow-green polystyrene microsphere suspension (10^6 microspheres per ml, Triton Technology Inc, Grantham, UK) was injected through the carotid artery cannula (0.6 ml min^{-1}) and flushed with 0.7 ml of saline (1 ml min^{-1}) to equalize the injecting and withdrawing volumes. At the end of the experiment, the rats were exsanguinated and the bladder was removed and weighed. The microspheres were extracted from the removed bladder and the collected blood according to the manufacturer's instructions. The concentration of fluorescent dye was measured in triplicate using a microplate reader (Hitachi Hi Tec, Ibaragi, Japan) at the following wavelengths: excitation wavelength, 490 nm; emission wavelength, 530 nm; and bandwidth, 5 nm. BBF ($\text{Y ml min}^{-1} \text{ g}^{-1}$) was calculated using the mean fluorescence intensity values for the bladder ($\text{FI}_{\text{bladder}}$) and the blood (FI_{blood}) with the following formula:

$$\text{Y (ml min}^{-1} \text{ g}^{-1}) = (\text{FI}_{\text{bladder}} / \text{bladder mass (g)}) \times 0.6 (\text{ml min}^{-1}) / \text{FI}_{\text{blood}}$$

Filling cystometry and bladder contractility experiment

We assessed androgen and bladder function in all three groups by examining the bladder reaction to irritation. A bladder cystostomy was created under pentobarbital sodium anesthesia using a polyethylene tube (PE-50). One week later, the rats were placed in metabolic cages (Tecniplast Japan Co., Ltd., Tokyo, Japan) and cystometry was performed without anesthesia or restraint. Voiding behavior was monitored using a PowerLab data acquisition system (AD Instruments, New South Wales, Australia) connected to the dial scales. The bladder catheter was connected via a T tube to a pressure transducer and an infusion pump (Terumo, Tokyo, Japan). The bladder was irrigated with normal saline at room temperature and 0.25% acetic acid (AA) liquid solution was then injected for 1 h at a speed of 5 ml h^{-1} . The parameters examined included maximum voiding pressure ($\text{cm H}_2\text{O}$) and voiding interval (s).

Examination of androgen-related histological changes in the bladder and blood vessels

The stained smooth muscles were quantified using color-assisted quantitative image analysis. All the rats from all groups were sacrificed, and the bladders and iliac arteries were removed and histologically examined for differences in smooth muscle and quantity of collagen fibers to analyze the effect of castration on the smooth muscle content. Each bladder was transected at the urethra level and sagittal sections were prepared; the blood vessels were sliced in a cross-sectional manner. All specimens were examined under hematoxylin and eosin and/or Mallory staining. The Mallory method stains muscle cells red and collagen fibers deep blue. We used Mallory-stained specimens for the examination of histological changes, such as denaturation or fibrosis. Sections of stained tissues were observed at a magnification

of $\times 400$ under a light microscope (Nikon, Tokyo, Japan) and the images were captured using a Fujix Digital Camera (Fujifilm, Tokyo, Japan). The images were analyzed using Photograb-2500 for Macintosh SH-25/MO (Fujifilm) and a Macintosh PowerMac G4 (Apple Computer, California, USA) and were quantified using Image J 1.46 software (Research Service Branch, National Institutes of Health, Bethesda, MD, USA). The components of smooth muscles and connective tissues were calculated from at least 10 fields from each tissue section.

Statistical analysis

BBF data and micturition parameter data are expressed as the means \pm s.d. Significant differences were analyzed using Welch's *t*-test in the blood flow study and micturition behavior study and using the Mann-Whitney U-test in the histological examination. The results were considered statistically significant at $P < 0.05$. All analyses were performed using Statcel: the useful add-in software forms on Excel, 2nd ed. (OMS Publication, Tokyo, Japan).

RESULTS

The mean body weights and bladder weights were listed in **Table 1**. Compared with the control and 4wPC groups, the body weight was lighter in the 8wPC group ($P < 0.01$). Compared to the control group, the bladder weight was lighter in the 8wPC group ($P < 0.05$).

Differences in BBF caused by androgen changes: fluorescent microsphere method

The mean BBF rates for the experimental rats were 1.37 ± 0.30 , 1.22 ± 0.46 and $1.23 \pm 0.41 \text{ ml min}^{-1} \text{ g}^{-1}$ for the control, 8wPC and 4wPC groups, respectively (**Figure 1**). Castration led to no changes in the BBF.

Relationship between androgen changes and bladder function: examination of bladder irritability

No significant difference was noted in the maximum voiding pressure between normal saline irrigation and AA irrigation among the control, 8wPC and 4wPC groups (**Figure 2a**).

The voiding intervals in each group were shortened ($P < 0.001$) following AA irrigation (**Figure 2b**). Further, the voiding intervals for the 8wPC and 4wPC groups were longer than the intervals for the control group; however, the differences were not significant.

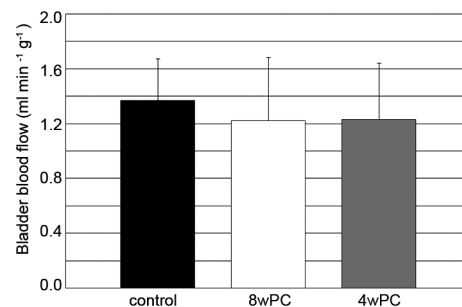


Figure 1: Androgen-related changes in BBF (not significant). The left carotid and left femoral arteries of rats were cannulated. A total of 0.2 ml of a yellow-green microsphere was injected through the carotid artery cannula and was flushed with 0.7 ml of saline to equalize the injecting and withdrawing volumes. The microspheres were extracted from the removed bladder and the collected blood according to the manufacturer's instructions. The concentration of fluorescent dye was measured in triplicate using a microplate reader at the following wavelengths: excitation wavelength, 490 nm; emission wavelength, 530 nm; and bandwidth, 5 nm.

Examination of androgen-related histological changes in the bladder and blood vessels

Histological examinations of the bladder and iliac artery revealed that the smooth muscles (red) decreased and connective tissues (deep blue) increased in the 4wPC group (Figure 3). The mean bladder smooth muscle/collagen ratios were showed in Figure 4a. Compared with the control group, the smooth muscle/collagen ratio was lower in the 8wPC and 4wPC groups ($P < 0.01$) (Figure 4a). The mean smooth muscle/collagen ratios at the iliac artery were listed in Figure 4b. Compared to the control group, the smooth muscle/collagen ratio was lower in group 4wPC ($P < 0.001$) (Figure 4b).

DISCUSSION

The relationships between androgen, blood vessels and lower urinary tract function remain unclear. Androgen deprivation possibly leads first to arterial sclerosis, followed by decreased arterial blood flow, decreased BBF and finally, the development of overactive bladder. However, no reports have yet described an association between overactive bladder and low androgen levels. Therefore, we conducted this study to identify a relationship between male hormone levels and lower urinary tract function, focusing on changes in BBF, bladder irritability as evaluated by cystometry and histological changes in the bladder and associated blood vessels.

In this study, BBF showed no differences following castration; further, the time at which castration was performed also did not affect BBF. Except for reports on the prostate, few reports have reviewed organ blood flow after castration. Only two studies have reported on BBF in

which they investigated acute changes following castration in rats.^{10,11} To the best of our knowledge, this is the first study to describe the long-term changes following castration and subsequent androgen deprivation.

In our cystometric analysis, the evaluation of bladder irritability revealed no changes in the BBF or bladder function. Thus, androgen levels and bladder function may not be affected by blood flow. Reports have described a similar relationship between low androgen levels and poor lower urinary tract function.^{5,6} The relationship between BBF and functional disorders of the bladder has been intensively investigated recently.^{9,12} As described above, low blood flow and ischemia of the lower urinary tract are considered to lead to LUTS.

In our study, histological examination revealed fibrosis in the bladder, which was significantly progressed in the 8wPC and 4wPC groups compared to the fibrosis in the control. The histological changes in the iliac artery, fibrosis at media, were significantly progressed in group 4wPC compared to the control.

LUTS has been correlated with histological changes in the lower urinary tract. Further, castration is known to decrease the amount of smooth muscle and to increase the amount of collagen in the bladder.⁸ In a chronic ischemia model, the primary lesion was reported to be caused by fibrillation of the subepithelial tissue of the bladder.¹² Few reports have described an association between the condition of blood vessels and androgen.¹³ Several reports have implicated low levels of testosterone in the development of arterial sclerosis with replacement therapy leading to improvement in arterial sclerosis and vascular endothelial function. Moreover, it has been reported that the quantity of muscle fibers, the number of vessels and the thickness of the urothelium in castrated rat bladder increased by androgenic administration.¹⁴ However, the authors used estrogen and androgen, and the reported results may have been due to the cooperative effects of both hormones; our study examined the effects of androgen only.

Some reports have compared immature cases with mature cases. For example, the reactivity of α_1 receptors was decreased in an immature group of castrated female rats compared to a mature group;¹⁵ rats require testosterone for developing and maintaining the

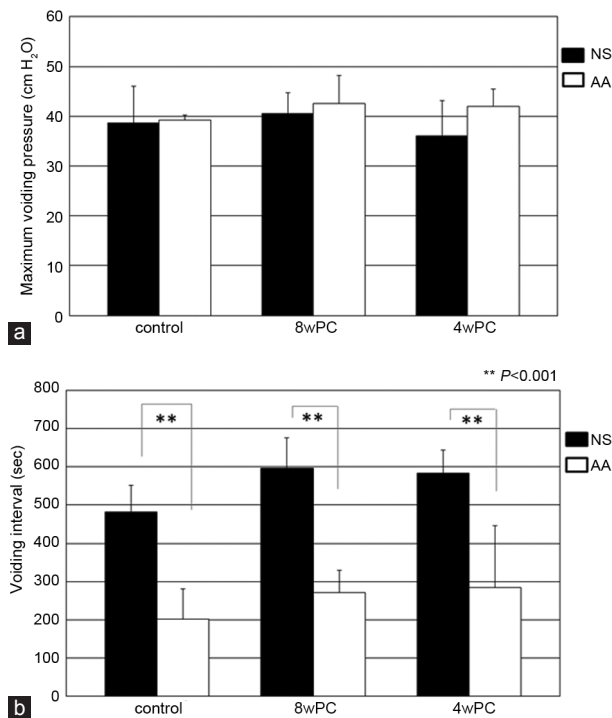


Figure 2: Androgen changes and bladder function: examination of bladder irritability. (a) Change of maximum voiding pressure. (b) Change of voiding interval. The rats in all three groups were placed in metabolic cages, and cystometry was performed without anesthesia or restraint. The bladder was irrigated with normal saline (NS) at room temperature, and 0.25% acetic acid (AA) liquid solution was then injected for 1 h at a speed of 5 ml h^{-1} . The parameters examined included maximum voiding pressure ($\text{cm H}_2\text{O}$) and voiding interval (s).

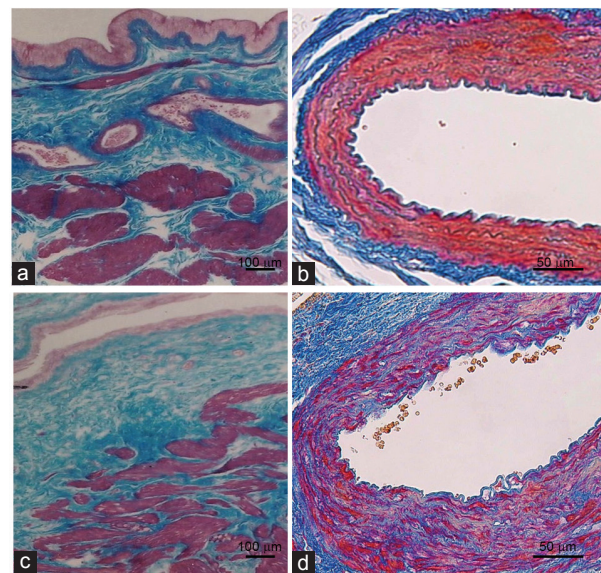


Figure 3: Histological examination of the bladder and iliac artery by Mallory staining. Mallory staining of rat bladders and iliac arteries of control (a and c) and 4wPC groups (b and d). Red indicates smooth muscle and blue indicates collagen.

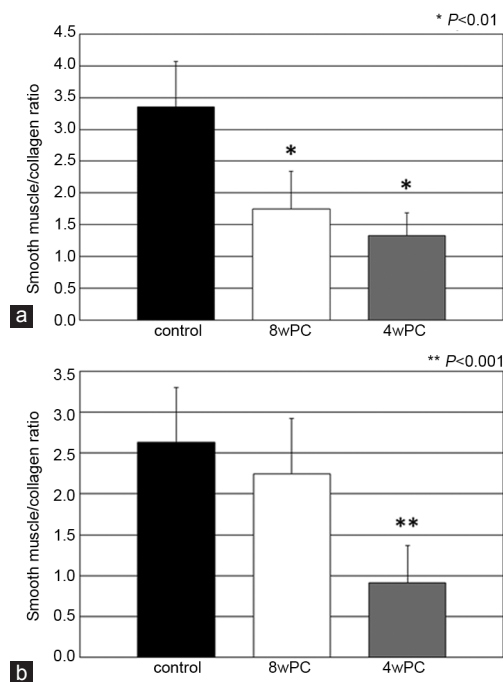


Figure 4: Examination of androgen-related histological changes in the bladder and blood vessels. (a) Smooth muscle/collagen ratio: bladder. (b) Smooth muscle/collagen ratio: common iliac artery. The bladders and iliac arteries of rats were histologically examined for differences in smooth muscle and the quantity of collagen fiber to analyze the effect of castration on the smooth muscle content. We used Mallory-stained specimens for the examination of histological changes such as denaturation or fibrosis. Sections of stained tissues were observed at a magnification of $\times 400$ under a light microscope. The components of smooth muscles and connective tissues were calculated from at least 10 fields from each tissue section.

pelvic sympathetic nerve system that controls the bladder.¹⁶ From the above report, we expect that bladder function is influenced by both the maturity and the time of castration in immature animals. We cannot confirm the clear association between maturity and blood vessels. However, from the above report, it is thought that fibrosis of the bladder and blood vessels may progress with early androgen deprivation.

It was confirmed that castration caused histological changes to occur in not only the bladder but also the blood vessels. In addition, it was also confirmed that the degree of the histological changes varied based on the age at castration. On analyzing the relationship between androgen and bladder function, we observed that the histological changes were associated with bladder function, but that the contribution of the blood flow was low. We consider that these effects of castration may constitute the key mechanisms underlying LUTS.

CONCLUSIONS

Our findings confirmed that castration led to histological changes not only in the bladder, but also in the blood vessels. Further, the age at which castration was performed affected the degree of the histological changes, although bladder irritability was not significantly affected. The relationship between androgen levels and bladder function appeared to be affected by the histological changes in the blood vessels and bladder rather than the blood flow to the bladder.

AUTHOR CONTRIBUTIONS

TM, YS, SA and BK participated in the design of the study and performed BFF measurement. TM performed filling cystometry and statistical analysis. YS and Kazuhiro Suzuki also critically revised the manuscript for important intellectual content. Keiji Suzuki performed the examinations of the histological changes in the bladder and blood vessels. All authors read and approved the final manuscript.

COMPETING INTEREST

The authors declare no competing interests.

ACKNOWLEDGMENTS

This study was supported in part by Grant-in-Aid for Young Scientists (B) 2007–2008.

REFERENCES

- Homma Y, Hamada K, Nakayama Y, Tsujimoto G, Kawabe K. Effects on contraction and alpha 1 adrenoceptor expression in the rat. *Br J Pharmacol* 2000; 131: 1434–60.
- Anderson GF, Navarro SP. The response of autonomic receptors to castration and testosterone in the urinary bladder of the rabbit. *J Urol* 1988; 140: 885–9.
- Takyu S. Effects of testosterone on the autonomic receptor-mediated function in lower urinary tract from male rabbits. *Nihon Hinyokika Gakkai Zasshi* 1993; 84: 330–8.
- Nakazawa R, Tanaka M, Takahashi T, Kobayashi S, Iwamoto T. Effects of castration and testosterone administration on angiotensin II receptor mRNA expression and apoptosis-related proteins in rat urinary bladder. *Endocr J* 2007; 54: 211–9.
- Mesut T, Ebru B, Burak Ç, Ozan E, Izzet O, *et al*. The effect of testosterone replacement therapy on bladder functions and histology in orchietomized mature male rats. *Urology* 2010; 75: 886–90.
- Keast JR. The autonomic nerve supply of male sex organs: an important target of circulating androgens. *Behav Brain Res* 1999; 105: 81–92.
- Hak AE, Witteman JC, de Jong FH, Geerlings MI, Hofman A, *et al*. Low levels of endogenous androgens increase the risk of atherosclerosis in elderly men: the Rotterdam study. *J Clin Endocrinol Metab* 2002; 87: 3632–9.
- Das AK, Leggett RE, Whitbeck C, Eagen G, Levin RM. Effect of doxazosin on rat urinary bladder function after partial outlet obstruction. *Neurourol Urodyn* 2002; 21: 160–6.
- Okutsu H, Matsumoto S, Hanai T, Noguchi Y, Fujiyasu N, *et al*. Effects of tamsulosin on bladder blood flow and bladder function in rats with bladder outlet obstruction. *Urology* 2010; 75: 235–40.
- Shabsigh A, Chang DT, Heitjan DF, Kiss A, Olsson CA, *et al*. Rapid reduction in blood flow to the rat ventral prostate gland after castration: preliminary evidence that androgens influence prostate size by regulating blood flow to the prostate gland and prostatic endothelial cell survival. *Prostate* 1998; 36: 201–6.
- Magari T, Shibata Y, Arai S, Kashiwagi B, Suzuki K. Influence of castration on bladder blood flow and function during the rapid phase of androgen deprivation. *Scand J Urol* 2013; 47: 236–41.
- Azadzoi KM, Tarcan T, Kozlowski R, Krane RJ, Siroky MB. Overactivity and structural changes in the chronically ischemic bladder. *J Urol* 1999; 162: 1768–78.
- Akishita M, Hashimoto M, Ohike Y, Ogawa S, Iijima K, *et al*. Low testosterone level is an independent determinant of endothelial dysfunction in men. *Hypertens Res* 2007; 30: 1029–34.
- Madeiro A, Girão M, Sartori M, Acquaroli R, Baracat E, *et al*. Effects of the association of androgen/estrogen on the bladder and urethra of castrated rats. *Clin Exp Obstet Gynecol* 2002; 29: 117–20.
- Longhurst PA. Functional development of the rat urinary bladder after pre- or postpubertal castration. *Pharmacology* 2003; 67: 72–82.
- Salmi S, Santti R, Gustafsson JA, Makela S. Co-localization of androgen receptor with estrogen receptor beta in the lower urinary tract of the male rat. *J Urol* 2001; 166: 674–7.

How to cite this article: Magari T, Shibata Y, Arai S, Kashiwagi B, Suzuki K, Suzuki K. Time-dependent effects of castration on the bladder function and histological changes in the bladder and blood vessels. *Asian J Androl* 18 February 2014. doi: 10.4103/1008-682X.123676. [Epub ahead of print]