Received: 1 April 2021 | Revised: 9 December 2021 | Accepted: 28 January 2022

DOI: 10.1002/ajmg.a.62730

ORIGINAL ARTICLE

AMERICAN JOURNAL OF medical genetics PART A WILEY

Microdeletion of 16q24.1–q24.2—A unique etiology of Lymphedema–Distichiasis syndrome and neurodevelopmental disorder

Marina Michelson[1,2,3] | Gabriel Lidzbarsky[4] | Daniella Nishri[5] | Ifat Israel-Elgali[3,6] | Rachel Berger[2] | Michal Gafner[3] | Noam Shomron[3,6] | Dorit Lev[1,2,3] | Yael Goldberg[2,3,4]

[1]Institute of Medical Genetics, Wolfson Medical Center, Holon, Israel

[2]The Genetic Institute of Maccabi Health Medicinal Organization, Tel-Aviv, Israel

[3]Sackler School of Medicine, Tel-Aviv University, Tel-Aviv, Israel

[4]Raphael Recanati Genetic Institute, Rabin Medical Center–Beilinson Hospital, Petach Tikva, Israel

[5]Child Developmental Center of Maccabi Health Medicinal Organization, Tel-Aviv, Israel

[6]Sagol School of Neuroscience, Tel-Aviv University, Tel-Aviv, Israel

Correspondence
Marina Michelson, Institute of Medical Genetics, Wolfson Medical Center, Holon, The Genetic Institute of Maccabi Health Medicinal Organization, Sackler School of Medicine, Tel-Aviv University, Tel-Aviv, Israel.
Email: mashakerman@gmail.com

Abstract

Interstitial deletions of 16q24.1–q24.2 are associated with alveolar capillary dysplasia, congenital renal malformations, neurodevelopmental disorders, and congenital abnormalities. Lymphedema–Distichiasis syndrome (LDS; OMIM # 153400) is a dominant condition caused by heterozygous pathogenic variants in *FOXC2*. Usually, lymphedema and distichiasis occur in puberty or later on, and affected individuals typically achieve normal developmental milestones. Here, we describe a boy with congenital lymphedema, distichiasis, bilateral hydronephrosis, and global developmental delay, with a de novo microdeletion of 894 kb at 16q24.1–q24.2. This report extends the phenotype of both 16q24.1–q24.2 microdeletion syndrome and of LDS. Interestingly, the deletion involves only the 3′-UTR part of *FOXC2*.

KEYWORDS

16q24.1–q24.2 microdeletion, 3′-UTR *FOXC2*, congenital lymphedema, developmental delay, distichiasis

1 | INTRODUCTION

Microdeletions of the long arm of chromosome 16 are not rare. In 1993, Callen et al. reported seven patients with interstitial deletions of 16q (Callen et al., 1993). Patients had global developmental delay, microcephaly, and dysmorphic features (Callen et al., 1993). The deleted segments comprised the interstitial parts of the 16q, occurring proximal to band 16q24.2. Since then, patients with haploinsufficiency of the 16q subtelomeric region have been identified with broad phenotypic variability (Handrigan et al., 2013; Kozłowska et al., 2020; Seeley et al., 2014; Stankiewicz et al., 2009; Szafranski et al., 2016; Szafranski et al., 2018; Yu et al., 2010; Zufferey et al., 2011).

Microdeletions at 16q24.2 are phenotypically apparent. Affected individuals present with intellectual disability, autistic spectrum disorder, seizures, speech delay and brain malformations, and congenital renal disease (Handrigan et al., 2013).

We describe a patient with a deletion at 16q24.1–q24.2 who presented with congenital lymphedema, distichiasis, developmental delay, and congenital hydronephrosis. Lymphedema–Distichiasis syndrome (LDS) is a distinct condition caused by heterozygous pathogenic variants in *FOXC2*. LDS may also be associated with renal disease and diabetes mellitus (Yildirim-Toruner et al., 2014).

The deleted region harbors the morbid gene *FBXO31* and the 3′-UTR region of *FOXC2*.

Although *FOXC2* and *FBXO31* have been included in some of the reported cases, LDS has not been reported as part of the syndrome. We compare the features of our patient with the reported 16q24 microdeletion syndrome cases and to those described with LDS.

2 | MATERIALS AND METHODS

2.1 | Chromosomal microarray analysis

Deoxyribonucleic acid (DNA) extraction from peripheral blood was performed by the MagNA Pure Compact (MPC) nucleic acid isolation kit I and an Automated MPC instrument (RocheDiagnostics) in accordance with manufacturer's protocol. Quantity and quality assessment of the extracted DNA was performed by a NanoDrop ND-1000 Spectrophotometer (NanoDrop Technologies, Inc.). DNA samples were diluted to a concentration of 50 ng/ml.

Chromosomal microarray (CMA) analysis was performed using Illumina Human Omni express (GxG Comprehensive Array, v1.0 Beadchip 709,671 SNP loci) microarrays. Gene by Gene's GxG Comprehensive Array analysis was done. Coordinated are according to UCSC Genome Browser GRCh37.

2.2 | Expression studies

Expression analysis was done on the proband and his healthy parents. Ribonucleic acid (RNA) was extracted from peripheral blood mononuclear cells (PBMC) using TRIzol reagent (Thermo Fisher Scientific). Reverse transcription reactions for mRNA were performed using the High-Capacity cDNA Reverse-Transcription Kit with random primers, according to the manufacturer's protocol (Thermo Fisher Scientific). Real-time quantitative PCR (RT-PCR) was performed using Quanta qPCR Gene Expression Master Mix (Quanta Technology). Comparative critical threshold (Ct) values, obtained by real-time PCR analysis, were used for relative quantification of gene expression, and determination of the fold-change of expression. Fold change values were obtained using the formula: $2^{-\Delta\Delta Ct}$ (Schmittgen & Livak, 2008). Normalization for mRNAs was performed compared to human B-actin expression. Primers sequences: Forward-AGCAGCAAACTTTCCCCAACG, Reverse-CATTGCCACTCA CCTGGGA.

2.3 | Sanger cDNA sequencing of *FOXC2*

In order to confirm that the proband possesses a wild type copy of the *FOXC2* 3′-UTR, a region located downstream of the deletion was amplified (using PCR) and sequenced. Complementary DNA (cDNA) was synthesized, and amplification of *FOXC2* was performed using custom primers: 5′-ATTTCTCCAACCGTGCTGTAC-3′, 5′-ACTTATCCAGTG AACTCAACTT-3′. The PCR product was run through a 1.5% Agarose gel. Discrete bands were extracted from the gel and were confirmed using Sanger sequencing technology.

3 | RESULTS

3.1 | Clinical characterization

The clinical features of the affected patient are summarized in Table 1. The proband is a 6-year-old boy who first attended the genetic clinic at 10 months of age due to congenital lymphedema, hypotonia, and global developmental delay.

The boy is a son of healthy nonconsanguineous parents of Bukharin Jewish origin. Family history is negative for neurological disorders or congenital anomalies.

The pregnancy was uneventful. Fetal sonographic scan revealed bilateral pyelectasis. He was born at term; birth weight and occipital frontal circumference were within normal ranges. He was diagnosed with moderate hydronephrosis and vesicouretheral reflux.

During the first weeks of life moderate swelling of both calves and feet, more on the right leg, occurred. Ultrasound of lower extremities revealed increased skin and subcutaneous thickness, and pronounced subcutaneous echogenicity, with normal venous Doppler ultrasound.

His development was slow without stagnation or regression. He walked independently at 19 months. Single words appeared at 13 months of age; however, further attainment was significantly delayed. He attained special education since 3 years of age. At that age, his vocabulary and understanding were significantly limited. He was diagnosed with attention deficit hyperactivity disorder at the age of 5 years.

At the age of 5 years, physical development and head circumference were age appropriate. The right foot was longer than the left. There was a moderate difference in the lower shin circumference (right thicker than left; Figure 1b).

Distichiasis-double rows of eyelashes was observed at the age of 6 years (Figure 1a).

3.2 | Chromosomal microarray

CMA showed a 894.4 kb deletion at genomic coordinates chr16:86602575–87497027 (GRCh 37; Figure 2). The proband also had a maternally inherited 317 kb duplication at chr8:14779676–15096705, classified as likely benign. The 16q24 deletion was de novo. It and included the OMIM morbid *FBXO31*, the 3UTR of *FOXC2* genes, and the *FOXL1* and, *MAP1LC3B* genes, which are not associated with diseases.

Full details of the genes located in the deletion can be found in Table S1.

This deletion detected for the first time in our cohort of 53,498 CMA cases done in Maccabi HMO from August 2014 to December 2020, of them 6195 postnatal tests, done on patients with intellectual deficiency, ASD or major malformations. Sanger sequencing of *FBXO31* did not detect any suspected variant.

3.3 | Real-time PCR

Real-time PCR analysis of *FOXC2* expression levels demonstrated 71% reduction of expression in PBMCs from the proband, compared to PBMCs from control samples ($p = 0.031$; Figure 3).

TABLE 1 Features of patients with 16q24.1–q24.2 deletion harboring *FOXC2*

Described by	Present case	Stankiewicz et al.	Yu S et al.	Zufferey et al.	Garabedian et al. 2012	Szafranski et al.	Kozlowska et al
Number of patients	1	10	1	1	1	13	2
Deleted region	16q24.1– q24.2	16q24.1–q24.2	16q24.1–q24.2	16q24.1	16q24.1	16q24.1	16q24.1
Genome coordinates (GRCh37/hg19)	86602575–87497027	100 to 3500 kb (range) chr16:84350698–87920754	chr16:85890261–7257585	chr16:85108709–86720212	85728812–86831579	chr16:86266902–86301803	First case: 85863000-87370500 Second case: 85738000-86446500
Mode of inheritance	De novo	De novo (8/9) Maternal (1/9)	De novo	NA	NA	De novo 12/13	NA
OMIM MORBID genes	*FOXC2* 3′-UTR *FBXO31*	*FOXC2 (8/10)* *FOXF1 (6/10)*	*FOXC2* *FOXF1* *IRF8*	*FOXC2* *FOXF1* *IRF8*	*FOXC2* *FOXF1, IRF8* *COX4I1 COX4NB*	*FOXC2* *FOXF1*	*FOXC2* *FOXF1* *IRF8* *FENDRR*
Other deleted genes	*MAP1LC3B* *FOXL1* *ZCCHC14*	*MTHFSD* *FOXL1(5/10)*	*MTHFSD* *FOXL1*	*MTHFSD* *FOXL1*	*MTHFSD* *FOXL1*	*MTHFSD* *FOXL1*	*MTHFSD*
NDD disorder	Global developmental delay Language disorder ADHD	Developmental delay (Bell et al., 2001) Ventriculomegay, Chiari malformation. NA (Jin et al., 2020) due to early death	No	No	No	None	None
Genitourinary anomalies	Congenital hydronephrosis	6/10: Hydronephrosis, uretero-pelvocaliectasias	Hypospadias, hydronephrosis tortuous dilated ureters, urethral obstruction	Pelvocaliectasis with ureteral stenosis	No	Renal agenesis	1/2: Hydronephrosis
Lymphedema	Congenital lymphedema	None	No	No	No	None	None
Distichiasis	Yes	None	No	No	No	None	None
Multiple congenital anomalies	No	ACDMPV (5/10) CHD: (6/10):hypoplasia of left ventricle TOF, VSD Gastrointestinal Malformations (5/10): tracheoesophageal fistula, esophageal atresia, duodenal and anal atresias, imperforate anus Single umbilical artery (3/10) Cleft lip and palate (1/10) Butterfly vertebrae (2/10)	ACDMPV: hypoplasia of left ventricle, pulmonary valve atresia, subaortic VSD with overriding of aorta, pulmonary artery stenosis, patent foramen ovale, persistent left superior vena cava; Intestinal malrotation	ACDMPV; CHD: AV canal, dysplastic tricuspid and mitral valve; Annular pancreas, duodenal diltation	Cystic hygroma; Fetal hydrops; Single umbilical artery	ACDMPV; CHD; Esophageal fistula, gut malrotation, absent gall bladder; imperforate anus, single umbilical artery	1/2: Polyhydramnion omphalocele

Abbreviations: ACDMPV, alveolar capillary dysplasia with misalignment of pulmonary veins; ADHD, attention deficit hyperactivity disorder; CHD, congenital heart disease; NA, not available; NDD, neurodevelopmental disorders; TOF, tetralogy of Fallot; VSD, ventricular septal defect.

3.4 | Sanger cDNA sequencing of *FOXC2*

The sequencing matched the *FOXC2* mRNA sequence (Figure S1), implying the presence of a 3′-UTR from the wild-type copy of the *FOXC2* gene for the proband.

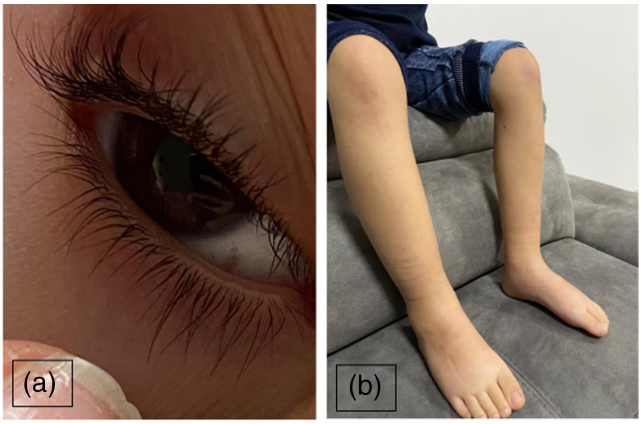

FIGURE 1 Pictures of the proband's eyelashes and calves.
(a) Distichiasis: The picture depicts double row eyelashes
(b) Lymphedema: The picture depicts moderate swelling of the right shin comparing with the left one

4 | DISCUSSION

The overlapping deletions at 16q24.1–q24.2 have been described with diverse associations. These included alveolar capillary dysplasia, cystic hygroma and hydrops fetalis, structural brain malformations, unspecific dysmorphic features, autism, and vascular malformations (Table 1).

We describe a patient with 16q24.1–q24.2 microdeletion with congenital lymphedema, distichiasis, developmental delay, and renal abnormalities.

Previous studies have shown that microdeletion at the 16q24.1–q24.2 may be associated with neurodevelopmental disorders (Table 1).

However, the deletion in our patient is proximal to those reported cases. The overlapping deleted region included the OMIM morbid *FBXO31* and four other genes—*ZCCHC14 MAP1LC3B*, *FOXL1*, and *C16orf95* (Table 2), which scarce information regarding neurodevelopment exists about them.

FBXO31 controls neuronal morphogenesis and migration in the developing brain (Vadhvani et al., 2013). Bi-allelic mutations in that gene have been associated with intellectual disability (Mir et al., 2014). Sequencing of the gene did not detect additional pathogenic variant. Recently, two patients with cerebral palsy, heterozygous for de novo mutations in *FBXO31* were described (Mental retardation autosomal recessive-45, OMIM # 615979; Jin et al., 2020). Therefore, *FBXO31* may contribute to the neurodevelopmental delay, either

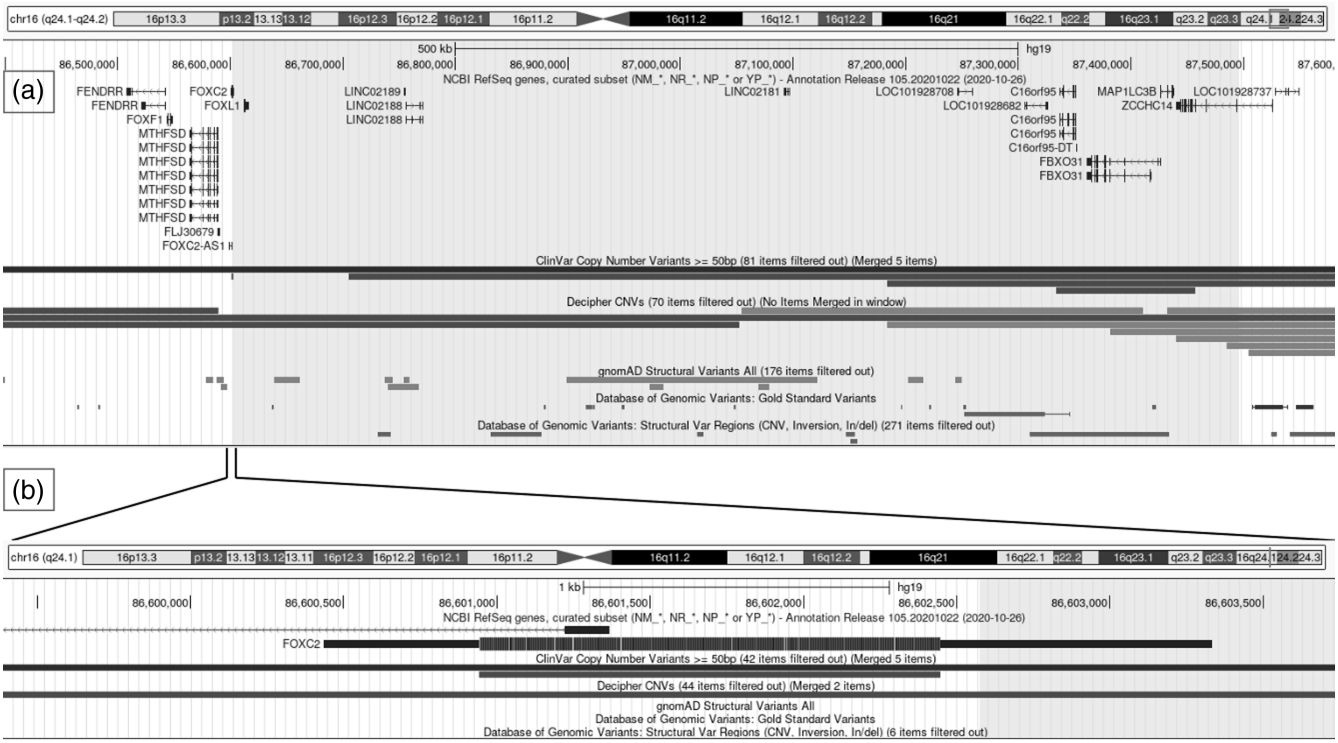

FIGURE 2 Known CNV variants located in the deletion region: Data taken from UCSC (GRCh37) using the UCSC tracks ClinVar (P/LP/VUS, gain and loss CNVs, >5 kb), decipher (P/LP/VUS deletions, >5 kb), DGV (deletions, >5 kb), and gnomAD SV (deletions, >5 kb). Items that span the region shown in the graph were merged. The region presented in this article (chr16:86602575–87497027) is highlighted in light gray. (a) A 1.3 mb area surrounding the region presented in this article (highlighted in light gray). (b) A 5 kb area congaing the gene *FOXC2*

directly or by an effect on the allelic architecture (Yuan et al., 2020). The deleted region in our patient also includes long noncoding RNAs that may affect the phenotype. Recent studies have demonstrated the role of long noncoding RNAs in CNS development, by regulation of gene expression in neuronal differentiation, synaptogenesis, and synaptic plasticity (Cuevas-Diaz Duran et al., 2019).

LDS is a distinct syndrome characterized by unique combination of lymphedema and distichiasis (McDermott & Lahiff, 2016). The lymphedema is confined to the lower limbs and appears in puberty or later on. Distichiasis usually occurs in puberty or in young adulthood (Table 1).

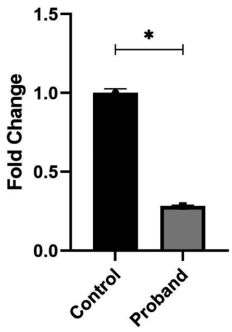

FIGURE 3 *FOXC2* expression in PBMC samples from control and proband: Real-time PCR analysis of *FOXC2* expression from control and proband samples. The data are shown as means ± *SEM*. $^*p < 0.05$, Welch's *t*-test. $n = 2$ control, $n = 1$ Proband. *FOXC2* expression in the proband's sample was 71% less compared to the parents

Forkhead transcription factor (*FOXC2*) is considered the only causative gene for LDS (Tavian et al., 2016; van Steensel et al., 2009). *FOXC2* regulates genes and signaling pathways involved in lymphangiogenesis (Norden et al., 2020; Wu & Liu, 2011). Mutations impair transcriptional activity and cell proliferation (Tavian et al., 2020). *FOXC2* also negatively regulates increased Ras/ERK signaling during lymphangiogenesis.

LDS phenotype is caused by numerous mutations along the entire gene, and has been attributed to promoter–enhancer dissociation of a topological-associated domain (Wallis et al., 2021; Table 2). The CMA results, presented here, include only the 3′-UTR of the *FOXC2* gene. 3′-UTR regulates translation efficiency of synthesized protein, mRNA stability, export to cytoplasm, and subcellular localization (Matoulkova et al., 2012). rs1035550 (NM_005251.3:c.*260A>C/T/G), a variant in the *FOXC2* 3′-UTR, was associated with secondary lymphedema following breast cancer surgery (Miaskowski et al., 2013) and risk of varicose veins (Shadrina et al., 2016). The *FOXC2* 3′-UTR also contains several MicroRNAs (miRNA) targets (Nimir et al., 2017). MiRNAs were found to play a role in embryonic lymphangiogenesis through the activation the *NFATC1* transcriptional factor, which is associated with *FOXC2*. Knock down of endothelial miRNAs have shown to result in defective lymphatic vessels development (Jung et al., 2019). Regulation of gene expression through 3′-UTR was shown to be directly mediated by overexpression of miR-204 and miR-495, and affected by miR-374c-5p and MiR-204-5p (Yang et al., 2017).

The role of the *FOXC2* 3′-UTR deletion is further supported by the results of the current study. Quantitative PCR results showed significantly lower expression level of *FOXC2* in the proband compared to his parents, thus supporting the genomic finding. To support a

TABLE 2 Clinical features in current patient and previously reported patients with *FOXC2* variants

Described by	Presented case	Bell et al.	Erickson et al. 2001	Finegold et al. 2001	Brice et al. 2002	van Steensel et al.	Tavian et al.	Wallis et al.
Number of patients	1	14	31	44	74	11	6	5
Mutation	3′-UTR deletion	Frameshift	Truncating	Truncating	Frameshift, Missense	Nonsense Missense Frameshift	Missense Frameshift Stop codon	*FOXC2* promoter–enhancer dissociation due to balanced translocation t (16;22) (q24; q13.1)
Lymphedema – age of onset	Birth	Puberty or later on	4–82 yo	6–80 yo 2 cases-birth	11–36 yo	6–16 yo	14–50 yo	15 yo
Distichiasis – age of onset	6 yo	Puberty	puberty	0–30 yo	puberty	2/11 NA	26–48 yo	NA
Renal anomalies	Bilateral hydronephrosis	None	None	None	5/74 Hydronephrosis	None	None	None
NDD disorder	Global developmental delay Language disorder ADHD	None	None	None	1/74 learning disabilities and autistic features	None	None	None
Other anomalies	No	Varicose veins CHD Pierre-Robin sequence Scoliosis	2/31 Cystic hygroma TOF Cleft palate	1/44 Cystic hygroma. TOF Cleft palate Yellow nail	Varicose veins CHD Scoliosis	Varicose veins	1/6 Bicuspid aortic valve	Hydrops Nuchal edema

Abbreviations: ADHD, attention deficit hyperactivity disorder; CHD, Congenital heart disease; NDD, neurodevelopmental disorders; TOF, tetralogy of Fallot; Yo, years old.

possible role of heterozygote deletion in the *FOXC2* 3′-UTR, this region was sequenced using DNA and cDNA samples. Both tests showed the existence of wild-type allele.

In conclusion, we report a novel phenotype of 16q24.1–q24.2 microdeletion syndrome of congenital LDS. Our results indicate a possible newly described role of *FOXC2* 3′-UTR deletion in LDS, which needs to be further studied.

ACKNOWLEDGMENTS

We sincerely thank the participating family. RNA studies were partially supported by the Sagol School of Neuroscience.

CONFLICT OF INTEREST

The authors declare no conflict of interest.

AUTHOR CONTRIBUTIONS

The authors confirm contribution to the paper as follows: study conception and design: Marina Michelson, Yael Goldberg, Dorit Lev; data collection: Marina Michelson, Daniella Nishri, Rachel Berger, Noam Shomron, Ifat Israel-Elgali; data analysis and interpretation: Marina Michelson, Gabriel Lidzbarsky, Yael Goldberg, Ifat Israel-Elgali; draft manuscript preparation: Marina Michelson, Gabriel Lidzbarsky, Michal Gafner; critical revision of the article: Yael Goldberg, Dorit Lev. All the authors reviewed the results and approved the final version of the manuscript.

DATA AVAILABILITY STATEMENT

Data sharing is not applicable to this article as no new data were created or analyzed in this study.

ORCID

Marina Michelson https://orcid.org/0000-0002-3794-0843
Michal Gafner https://orcid.org/0000-0002-3851-7334
Dorit Lev https://orcid.org/0000-0001-6869-6727

REFERENCES

Bell, R., Brice, G., Child, A. H., Murday, V. A., Mansour, S., Sandy, C. J., Collin, J. R., Brady, A. F., Callen, D. F., Burnand, K., Mortimer, P., & Jeffery, S. (2001). Analysis of lymphoedema-distichiasis families for *FOXC2* mutations reveals small insertions and deletions throughout the gene. *Human Genetics*, *108*(6), 546–551.

Brice, G., Mansour, S., Bell, R., Collin, J. R., Child, A. H., Brady, A. F., Sarfarazi, M., Burnand, K. G., Jeffery, S., Mortimer, P. & Murday, V. A. (2002). Analysis of the phenotypic abnormalities in lymphoedema-distichiasis syndrome in 74 patients with *FOXC2* mutations or linkage to 16q24. Journal of Medical Genetics, *39*(7), 478–483.

Callen, D. F., Eyre, H., Lane, S., Shen, Y., Hansmann, I., Spinner, N., Zackai, E., McDonald-McGinn, D., Schuffenhauer, S., Wauters, J., et al. (1993). High resolution mapping of interstitial long arm deletions of chromosome 16: Relationship to phenotype. *Journal of Medical Genetics*, *30*(10), 828–832.

Cuevas-Diaz Duran, R., Wei, H., Kim, D. H., & Wu, J. Q. (2019). Invited review: Long non-coding RNAs: Important regulators in the development, function and disorders of the central nervous system. *Neuropathology and Applied Neurobiology*, *45*(6), 538–556.

Erickson, R. P., Dagenais, S. L., Caulder, M. S., Downs, C. A., Herman, G., Jones, M. C., Kerstjens-Frederikse, W. S., Lidral, A. C., McDonald, M., Nelson, C. C., Witte, M., & Glover, T. W. (2001). Clinical heterogeneity in lymphoedema-distichiasis with *FOXC2* truncating mutations. *Journal of Medical Genetics*, *38*(11), 761–766.

Finegold, D. N., Kimak, M. A., Lawrence, E. C., Levinson, K. L., Cherniske, E. M., Pober, B. R., Dunlap, J. W., & Ferrell, R. E. (2001). Truncating mutations in *FOXC2* cause multiple lymphedema syndromes. *Human Molecular Genetics*, *10*(11), 1185–1189.

Garabedian, M. J., Wallerstein, D., Medina, N., Byrne, J., & Wallerstein, R. J. (2012). Prenatal diagnosis of cystic Hygroma related to a deletion of 16q24.1 with Haploinsufficiency of FOXF1 and *FOXC2* genes. *Case Reports in Genetics*, *2012*, 490408.

Handrigan, G. R., Chitayat, D., Lionel, A. C., Pinsk, M., Vaags, A. K., Marshall, C. R., Dyack, S., Escobar, L. F., Fernandez, B. A., Stegman, J. C., Rosenfeld, J. A., Shaffer, L. G., Goodenberger, M., Hodge, J. C., Cain, J. E., Babul-Hirji, R., Stavropoulos, D. J., Yiu, V., Scherer, S. W., & Rosenblum, N. D. (2013). Deletions in 16q24.2 are associated with autism spectrum disorder, intellectual disability and congenital renal malformation. *Journal of Medical Genetics*, *50*(3), 163–173.

Jin, S. C., Lewis, S. A., Bakhtiari, S., Zeng, X., Sierant, M. C., Shetty, S., Nordlie, S. M., Elie, A., Corbett, M. A., Norton, B. Y., van Eyk, C. L., Haider, S., Guida, B. S., Magee, H., Liu, J., Pastore, S., Vincent, J. B., Brunstrom-Hernandez, J., Papavasileiou, A., … Kruer, M. C. (2020). Mutations disrupting neuritogenesis genes confer risk for cerebral palsy. *Nature Genetics*, *52*(10), 1046–1056.

Jung, H. M., Hu, C. T., Fister, A. M., Davis, A. E., Castranova, D., Pham, V. N., Price, L. M., & Weinstein, B. M. (2019). MicroRNA-mediated control of developmental lymphangiogenesis. *eLife*, *8*, 8–9.

Kozłowska, Z., Owsiańska, Z., Wroblewska, J. P., Kałużna, A., Marszałek, A., Singh, Y., Mroziński, B., Liu, Q., Karolak, J. A., Stankiewicz, P., Deutsch, G., Szymankiewicz-Bręborowicz, M., & Szczapa, T. (2020). Genotype-phenotype correlation in two polish neonates with alveolar capillary dysplasia. *BMC Pediatrics*, *20*(1), 320.

Matoulkova, E., Michalova, E., Vojtesek, B., & Hrstka, R. (2012). The role of the 3′ untranslated region in post-transcriptional regulation of protein expression in mammalian cells. *RNA Biology*, *9*(5), 563–576.

McDermott, S., & Lahiff, C. (2016). Lymphedema-distichiasis syndrome. *CMAJ*, *188*(2), E44.

Miaskowski, C., Dodd, M., Paul, S. M., West, C., Hamolsky, D., Abrams, G., Cooper, B. A., Elboim, C., Neuhaus, J., Schmidt, B. L., Smoot, B., & Aouizerat, B. E. (2013). Lymphatic and angiogenic candidate genes predict the development of secondary lymphedema following breast cancer surgery. *PLoS One*, *8*(4), e60164.

Mir, A., Sritharan, K., Mittal, K., Vasli, N., Araujo, C., Jamil, T., Rafiq, M. A., Anwar, Z., Mikhailov, A., Rauf, S., Mahmood, H., Shakoor, A., Ali, S., So, J., Naeem, F., Ayub, M., & Vincent, J. B. (2014). Truncation of the E3 ubiquitin ligase component FBXO31 causes non-syndromic autosomal recessive intellectual disability in a Pakistani family. *Human Genetics*, *133*(8), 975–984.

Nimir, M., Abdelrahim, M., Abdelrahim, M., Abdalla, M., Ahmed, W. E., Abdullah, M., & Hamid, M. M. A. (2017). In silico analysis of single nucleotide polymorphisms (SNPs) in human *FOXC2* gene. *F1000Res*, *6*, 243.

Norden, P. R., Sabine, A., Wang, Y., Demir, C. S., Liu, T., Petrova, T. V., & Kume, T. (2020). Shear stimulation of FOXC1 and *FOXC2* differentially regulates cytoskeletal activity during lymphatic valve maturation. *eLife*, *9*, 7–8.

Schmittgen, T. D., & Livak, K. J. (2008). Analyzing real-time PCR data by the comparative C(T) method. *Nature Protocols*, *3*(6), 1101–1108.

Seeley, A. H., Durham, M. A., Micale, M. A., Wesolowski, J., Foerster, B. R., & Martin, D. M. (2014). Macrocerebellum, epilepsy, intellectual disability, and gut malrotation in a child with a

16q24.1-q24.2 contiguous gene deletion. *American Journal of Medical Genetics. Part A*, *164a*(8), 2062–2068.

Shadrina, A. S., Smetanina, M. A., Sokolova, E. A., Sevost'ianova, K. S., Shevela, A. I., Demekhova, M. Y., Shonov, O. A., Ilyukhin, E. A., Voronina, E. N., Zolotukhin, I. A., Kirienko, A. I., & Filipenko, M. L. (2016). Association of polymorphisms near the *FOXC2* gene with the risk of varicose veins in ethnic Russians. *Phlebology*, *31*(9), 640–648.

Stankiewicz, P., Sen, P., Bhatt, S. S., Storer, M., Xia, Z., Bejjani, B. A., Ou, Z., Wiszniewska, J., Driscoll, D. J., Maisenbacher, M. K., Bolivar, J., Bauer, M., Zackai, E. H., McDonald-McGinn, D., Nowaczyk, M. M., Murray, M., Hustead, V., Mascotti, K., Schultz, R., … Shaw-Smith, C. (2009). Genomic and genic deletions of the FOX gene cluster on 16q24.1 and inactivating mutations of FOXF1 cause alveolar capillary dysplasia and other malformations. *American Journal of Human Genetics*, *84*(6), 780–791.

Szafranski, P., Gambin, T., Dharmadhikari, A. V., Akdemir, K. C., Jhangiani, S. N., Schuette, J., Godiwala, N., Yatsenko, S. A., Sebastian, J., Madan-Khetarpal, S., Surti, U., Abellar, R. G., Bateman, D. A., Wilson, A. L., Markham, M. H., Slamon, J., Santos-Simarro, F., Palomares, M., Nevado, J., … Stankiewicz, P. (2016). Pathogenetics of alveolar capillary dysplasia with misalignment of pulmonary veins. *Human Genetics*, *135*(5), 569–586.

Szafranski, P., Kośmider, E., Liu, Q., Karolak, J. A., Currie, L., Parkash, S., Kahler, S. G., Roeder, E., Littlejohn, R. O., DeNapoli, T. S., Shardonofsky, F. R., Henderson, C., Powers, G., Poisson, V., Bérubé, D., Oligny, L., Michaud, J. L., Janssens, S., De Coen, K., … Stankiewicz, P. (2018). LINE- and Alu-containing genomic instability hotspot at 16q24.1 associated with recurrent and nonrecurrent CNV deletions causative for ACDMPV. *Human Mutation*, *39*(12), 1916–1925.

Tavian, D., Missaglia, S., Maltese, P. E., Michelini, S., Fiorentino, A., Ricci, M., Serrani, R., Walter, M. A., & Bertelli, M. (2016). *FOXC2* disease-mutations identified in lymphedema-distichiasis patients cause both loss and gain of protein function. *Oncotarget*, *7*(34), 54228–54239.

Tavian, D., Missaglia, S., Michelini, S., Maltese, P. E., Manara, E., Mordente, A., & Bertelli, M. (2020). *FOXC2* disease mutations identified in lymphedema distichiasis patients impair transcriptional activity and cell proliferation. *International Journal of Molecular Sciences*, *21*(14), 7–8.

Vadhvani, M., Schwedhelm-Domeyer, N., Mukherjee, C., & Stegmüller, J. (2013). The centrosomal E3 ubiquitin ligase FBXO31-SCF regulates neuronal morphogenesis and migration. *PLoS One*, *8*(2), e57530.

van Steensel, M. A., Damstra, R. J., Heitink, M. V., Bladergroen, R. S., Veraart, J., Steijlen, P. M., & van Geel, M. (2009). Novel missense mutations in the *FOXC2* gene alter transcriptional activity. *Human Mutation*, *30*(12), E1002–E1009.

Wallis, M., Pope-Couston, R., Mansour, J., Amor, D. J., Tang, P., & Stock-Myer, S. (2021). Lymphedema distichiasis syndrome may be caused by *FOXC2* promoter-enhancer dissociation and disruption of a topological associated domain. *American Journal of Medical Genetics. Part A*, *185*(1), 150–156.

Wu, X., & Liu, N. F. (2011). *FOXC2* transcription factor: A novel regulator of lymphangiogenesis. *Lymphology*, *44*(1), 35–41.

Yang, Z., Jiang, S., Cheng, Y., Li, T., Hu, W., Ma, Z., Chen, F., & Yang, Y. (2017). FOXC1 in cancer development and therapy: Deciphering its emerging and divergent roles. *Therapeutic Advances in Medical Oncology*, *9*(12), 797–816.

Yildirim-Toruner, C., Subramanian, K., El Manjra, L., Chen, E., Goldstein, S., & Vitale, E. (2014). A novel frameshift mutation of *FOXC2* gene in a family with hereditary lymphedema-distichiasis syndrome associated with renal disease and diabetes mellitus. *American Journal of Medical Genetics. Part A*, *131*(3), 281–286.

Yu, S., Shao, L., Kilbride, H., & Zwick, D. L. (2010). Haploinsufficiencies of FOXF1 and *FOXC2* genes associated with lethal alveolar capillary dysplasia and congenital heart disease. *American Journal of Medical Genetics. Part A*, *152a*(5), 1257–1262.

Yuan, B., Wang, L., Liu, P., Shaw, C., Dai, H., Cooper, L., Zhu, W., Anderson, S. A., Meng, L., Wang, X., Wang, Y., Xia, F., Xiao, R., Braxton, A., Peacock, S., Schmitt, E., Ward, P. A., Vetrini, F., He, W., … Bi, W. (2020). CNVs cause autosomal recessive genetic diseases with or without involvement of SNV/indels. *Genetics in Medicine*, *22*(10), 1633–1641.

Zufferey, F., Martinet, D., Osterheld, M. C., Niel-Bütschi, F., Giannoni, E., Schmutz, N. B., Xia, Z., Beckmann, J. S., Shaw-Smith, C., Stankiewicz, P., Langston, C., & Fellmann, F. (2011). 16q24.1 microdeletion in a premature newborn: Usefulness of array-based comparative genomic hybridization in persistent pulmonary hypertension of the newborn. *Pediatric Critical Care Medicine*, *12*(6), e427–e432.

SUPPORTING INFORMATION

Additional supporting information may be found in the online version of the article at the publisher's website.

How to cite this article: Michelson, M., Lidzbarsky, G., Nishri, D., Israel-Elgali, I., Berger, R., Gafner, M., Shomron, N., Lev, D., & Goldberg, Y. (2022). Microdeletion of 16q24.1–q24.2—A unique etiology of Lymphedema–Distichiasis syndrome and neurodevelopmental disorder. *American Journal of Medical Genetics Part A*, *188*A:1990–1996. https://doi.org/10.1002/ajmg.a.62730