

Received: 2020.04.15

Accepted: 2020.08.09

Available online: 2020.09.01

Published: 2020.10.11

# Diaphragmatic Lipoma in a Woman with Rheumatoid Arthritis: A Case Report and Literature Review

Authors' Contribution:  
Study Design A  
Data Collection B  
Statistical Analysis C  
Data Interpretation D  
Manuscript Preparation E  
Literature Search F  
Funds Collection G

ABCDEF 1 **Khaled Z. Alawneh**  
ABCDEF 2 **Liqaq A. Raffee**  
ABCDEF 3 **Khaldoon M. Alawneh**  
BCDEF 4 **Husam Alawneh**  
BCDEF 4 **Abdelwahab Aleshawi**

1 Department of Diagnostic Radiology and Nuclear Medicine, Jordan University of Science and Technology, Irbid, Jordan  
2 Department of Accident and Emergency Medicine, Jordan University of Science and Technology, Irbid, Jordan  
3 Department of Internal Medicine, Jordan University of Science and Technology, Irbid, Jordan  
4 Department of Internal Medicine, King Abdullah University Hospital, Irbid, Jordan

**Corresponding Author:** Khaled Z. Alawneh, e-mail: [kzalawneh0@just.edu.jo](mailto:kzalawneh0@just.edu.jo)

**Conflict of interest:** None declared

**Patient:** Female, 52-year-old  
**Final Diagnosis:** Diaphragmatic lipoma  
**Symptoms:** Shortness of breath  
**Medication:** —  
**Clinical Procedure:** CT scan  
**Specialty:** Radiology • Rheumatology

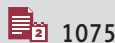
**Objective:** Rare disease

**Background:** A lipoma is a benign tumor made of fat tissue. Diaphragmatic lipomas are frequently reported in case studies.  
**Case Report:** This study presents a case of diaphragmatic lipoma in a woman with rheumatoid arthritis who was complaining of shortness of breath. A literature review of previously reported diaphragmatic lipoma cases was also carried out. In our patient, normal vital signs were detected, and laboratory results showed that antinuclear antibody, complete blood count, erythrocyte sedimentation rate, and C-reactive protein levels were high. A high-resolution CT scan showed pulmonary nodules and an incidentally found diaphragmatic lipoma. The patient was prescribed corticosteroids, methotrexate, folic acid, and chloroquine. The 3-month follow-up visit revealed symptomatic improvements in breathing difficulties and joint attacks.

**Conclusions:** Diaphragmatic lipoma should be identified to avoid misdiagnosis. Most cases of lipoma require observation. Surgical treatment is indicated only if the mass is symptomatic, increasing in size, or of uncertain nature.

**MeSH Keywords:** Arthritis, Rheumatoid • Diaphragm • Lipoma

**Full-text PDF:** <https://www.amjcaserep.com/abstract/index/idArt/925174>




1075



1



4



31



## Background

A lipoma is a benign soft tissue tumor that consists of mature fatty (adipose) tissue [1–3]. Patients with a lipoma typically present in middle age (fifth and sixth decades of life), although there is a wide age spectrum at diagnosis, with 80% of patients presenting between the ages of 26 and 65 years [1–3]. Lipomas occur predominantly on the upper back, shoulder, and abdomen [3,4]. The categorization of lipomas is carried out on the basis of anatomical location and ranges from superficial (subcutaneous) lipomas to deep lipomas. The incidence of superficial lipomas is higher than that of deep lipomas, with the latter accounting for about 1% of cases [1,4–6]. Superficial lipomas are generally asymptomatic and less than 5 cm in size. However, superficial lipomas can be accompanied by local pain and tenderness [2,3]. This is in contrast to deep-seated lipomas, which are typically larger than superficial lipomas [1,2,5]. Lipomas have been reported in unusual anatomical locations, such as the female vulva [7] and the transverse colon [8]. Additionally, giant epicardial lipomas have been found compressing the right atrium [9] and eyelid [10].

Herein, we present a case of a diaphragmatic lipoma that was incidentally discovered in a woman with rheumatoid arthritis, who was complaining of shortness of breath. Additionally, in this case study, we have reviewed and discussed previously reported occurrences of diaphragmatic lipoma [11–31].

## Case Report

A 52-year-old woman, who was diagnosed with rheumatoid arthritis in 2010 and arthritis and lichen planus in 2015, presented to our facility. She had been referred from a rheumatology outpatient clinic due to a history of progressive shortness of breath with an 8-month duration that was associated with joint pain, swelling, and morning stiffness. The shortness of breath had a gradual onset and was aggravated by exercise or cold weather exposure. It was also accompanied by infrequent episodes of dry cough and wheezing. The patient had no chest pain, rhinorrhea, epistaxis, fever, or sweating. Her breathing difficulty was partially relieved by a short-acting beta agonist (salbutamol). She had normal vital signs, characterized by a blood pressure of 120/70 mmHg, a resting pulse rate of 80 beats per min, a respiration rate of 18 breaths per min, and 96% oxygen saturation on room air. Moreover, a chest examination revealed normal auscultatory findings.

The recurrent attacks of rheumatoid arthritis involved joint pain, swelling, hotness, and tenderness in the small hand, elbow, and knee joints. Laboratory tests were requested in the form of antinuclear antibody (ANA), C-reactive protein (CRP), erythrocytes sedimentation rate (ESR), and a complete blood count (CBC). The ANA level was very elevated, indicating the

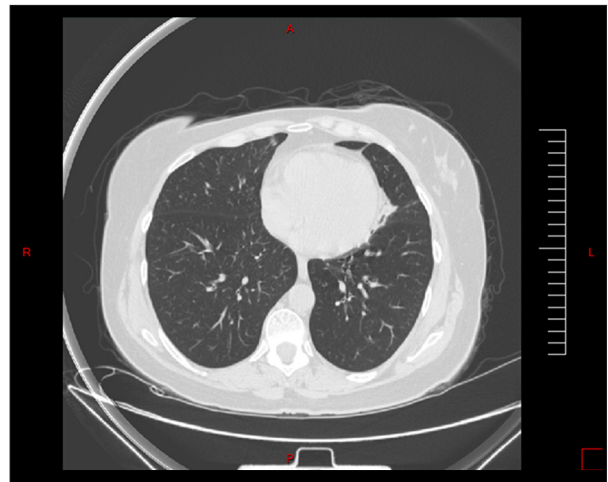

Figure 1. Multiple nodules in the lung parenchyma.

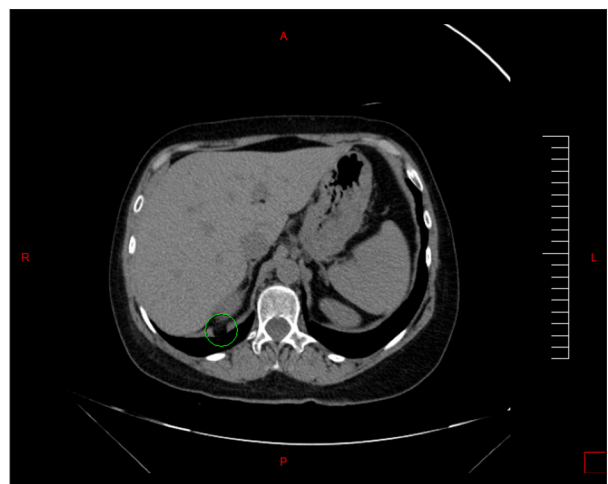
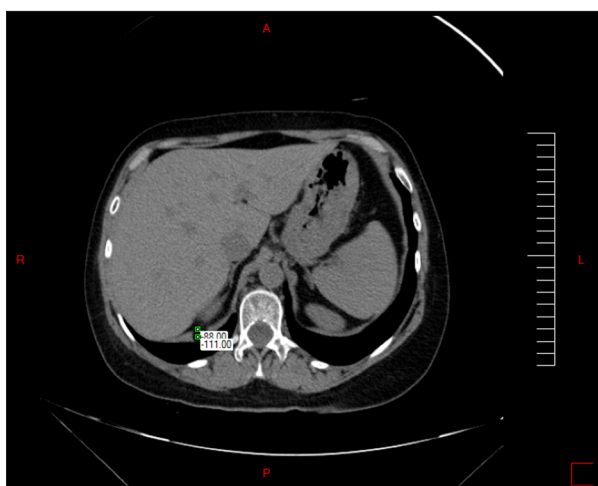

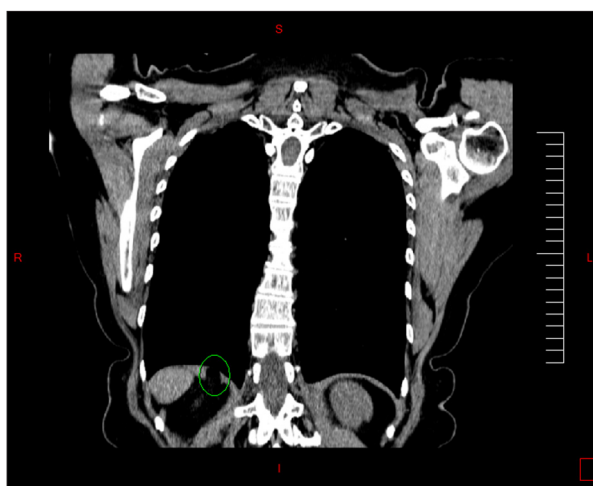
Figure 2. CT scan axial section showing diaphragmatic lipoma marked with a green circle.

presence of active disease. The CRP and ESR levels were also elevated. In addition to normal ECG findings, the CBC results indicated the presence of leukocytes. The rheumatologist had a clinical suspicion of a relapse in rheumatoid arthritis with lung involvement. A high-resolution CT scan was performed as required to accurately diagnose interstitial lung diseases.

The results of the CT scan revealed multiple nodules in the lung parenchyma, which were mostly pulmonary nodules (Figure 1). Incidentally, a well-circumscribed mass lesion measuring 1.26×1.47×1.16 cm was found to involve the crus of the right hemidiaphragm (Figures 2–4). The density of the lesion was –127 Hounsfield units, which was indicative of fat density. The diagnosis of the diaphragmatic lipoma was established based on these clinical and radiological findings. The patient took corticosteroids, methotrexate, folic acid, and chloroquine for the rheumatoid arthritis. A 3-month follow-up examination revealed symptomatic improvements in breathing difficulties and joint attacks.



**Figure 3.** The Hounsfield units of the lipoma.



**Figure 4.** CT scan coronal section showing diaphragmatic lipoma marked with a green circle.

**Table 1.** Review of case studies that conducted diaphragmatic lipoma investigations.

No.	Author	Age	Sex	Location	Tumor size	Clinical features	Treatment modality
1	Margiotta et al. [11]	85	F	Right hemi-diaphragm	20×15×15 cm	Incidental (at autopsy)	Observation
2	Margiotta et al. [11]	45	M	Left pleural cavity, attached to the diaphragm	15×10×10 cm (1100 g)	Incidental (at autopsy)	Observation
3	Naomi et. al. [12]	69	F	Left hemi-diaphragm		Incidental	Surgery
4	Cheon et al. [13]	4	F	Right hemi-diaphragm	8.5×7×6 cm	Intermittent dry cough	Surgery
5	Smahi et al. [14]	54	F	Left hemi-diaphragm	6×3.5 cm	Basithoracic pain	Surgery
6	Sakurai et al. [15]	50	M	Base of left hemi-diaphragm		Incidental	Surgery
7	Sen et al. [16]	67	M	Posterior region of the left hemi-diaphragm	5×5 cm	Incidental	Surgery
8	Vougiouklakisa et al. [17]	39	F	Right hemi-diaphragm	25×20×18 cm (2850 g)	Incidental (at autopsy)	Observation
9	Oyar et al. [18]	50	M	Bilateral and symmetric diaphragmatic crus lipomas	Diameter of the right: 14.7 mm Diameter of the left: 14.9 mm	Incidental	Observation
10	Oyar et al. [19]	37	F	Left diaphragmatic crus		Incidental	Observation
11	Ferguson and Westcott [20]	69	M	Left hemi-diaphragm	Diameter: 8 cm	Incidental (at autopsy)	Observation
12	Ballon and Spector [21]	45	F	Left hemi-diaphragm	4×3×1.5 cm	Incidental (at autopsy)	Observation
13	Shimizu et al. [22]	70	M	Left hemi-diaphragm		Incidental	Surgery
14	Aoyagi et al. [23]	65	M	Under left hemi-diaphragm		Incidental	Surgery

**Table 1 continued.** Review of case studies that conducted diaphragmatic lipoma investigations.

No.	Author	Age	Sex	Location	Tumor size	Clinical features	Treatment modality
15	Aydin et al. [24]	56	F	Right hemi-diaphragm, posterolateral	7×5 cm	Chest pain	Surgery
16	Aydin et al. [24]	59	M	Right hemi-diaphragm, posterolateral	6×5 cm	Chest pain	Surgery
17	Aydin et al. [24]	77	F	Right hemi-diaphragm, posterolateral	6×4 cm	Chest pain and hemoptysis	Surgery
18	Aydin et al. [24]	54	M	Right hemi-diaphragm, posterolateral	5×5 cm	Cough, back pain, hemoptysis	Surgery
19	Aydin et al. [24]	65	F	Right hemi-diaphragm, posterolateral	8×5 cm	Cough, Sputum	Surgery
20	Papachristos et al. [25]	66	F	Left hemi-diaphragm, posterolateral	16×14.5×5.5 cm	Respiratory failure with progressive dyspnea and left pleuritic chest pain	Surgery
21	Clagett and Johnson [26]	45	F	Left hemi-diaphragm	–	Incidental (at autopsy)	Observation
22	Clagett and Johnson [26]	80	F	Right hemi-diaphragm	Diameter: 1 cm	Incidental (at autopsy)	Observation
23	Clagett and Johnson [26]	58	F	Right hemi-diaphragm	Diameter: 1 cm	Incidental (at autopsy)	Observation
24	Soderlund [27]	51	F	Left Hemi-diaphragm	Diameter: 6 cm	Severe left chest pain	Surgery
25	Pavlica [28]	78	M	Left hemi-diaphragm		Severe chest pain with fatal rupture of diaphragm following a severe episode of vomiting	Resulted in death
26	Clark [29]	65	F	Right		Incidental	Observation
27	Soto [30]	14	M	Left		Chest pain	Surgery
28	Weilgoni [31]	57	M	Right		Incidental	Observation
29	Weilgoni [31]	59	F	Left		Incidental	Observation
30	Weilgoni [31]	68	F	Left		Incidental	Observation
31	Weilgoni [31]	64	F	Left		Incidental	Observation
32	Weilgoni [31]	75	M	Right		Incidental	Observation
33	Weilgoni [31]	72	M	Right		Incidental	Observation
34	Weilgoni [31]	69	M	Left		Incidental	Observation
35	Our case	52	F	Right		Incidental	Observation

F – Female; M – Male.

## Discussion

We reviewed 34 diaphragmatic lipoma case reports (Table 1). The patient described in the present case study is the 35<sup>th</sup> on the list. To the best of our knowledge, this is the first case of diaphragmatic lipoma to be associated with rheumatoid arthritis. In 1886, Clark was the first to report on the incidence of diaphragmatic lipoma [29]. In our review, pericardial lipomas were excluded in addition to 2 cases whose original case studies could not be found. According to the data, the female to male ratio was 1.33: 1, indicating that more women (57.2%) are affected by this condition than are men (42.8%). One reason can be the presence of a higher fat content in females. The mean age of the patients was 58.01 years, and 88.6% of patients were above the age of 45 years. Only 2 pediatric cases were reported in the literature: a 14-year-old boy, who presented with chest pain [30], and a 4-year-old girl, who presented with an intermittent cough [13].

Most of the lipomas in the diaphragm presented on the left aspect. A total of 19 cases reported lipoma location on the left side (54.3%), 15 cases reported it on the right side (42.8%), and 1 case reported bilateral location (2.9%). Lipoma location is mostly attributable to the presence of the liver on the right side [24]. Furthermore, most diaphragmatic lipomas have a posterolateral location. It is essential to differentiate between a diaphragmatic lipoma and Bochdalek hernia by the presence of discontinuity of the diaphragmatic musculature in a Bochdalek hernia [19].

A total of 24 cases were reported to be asymptomatic (68.6%). These cases of asymptomatic lipomas were detected either

through postmortem autopsy as conducted by Margiotta [11], Vougiouklakis [17], Claggett [26], Ferguson [20], and Harry [21] or by radiological studies. Conversely, 11 lipoma cases (31.4%) were symptomatic, causing a range from mild symptoms to fatal complications. Joon reported a case of a 4-year-old girl who was complaining of intermittent cough [13]. Yener reported 5 cases of patients who complained of chest pain and other symptoms such as hemoptysis or back pain [24]. Conversely, Pavlica reported a case of a patient who died after an episode of severe vomiting due to a ruptured diaphragm in an area that harbored a lipoma [28]. In our present case, we believe that there was no association between the diaphragmatic lipoma and the rheumatoid arthritis.

Most of the reported cases were managed conservatively by observation. In 19 cases that were under observation, 1 ended in death. Surgical excision was performed in 16 patients, who were mostly symptomatic. As per existing knowledge, surgical treatment is indicated only if a mass is symptomatic, increasing in size, or of uncertain nature.

## Conclusions

Diaphragmatic lipoma should be identified in order to avoid misdiagnosis. Most cases require observation. Surgical treatment is indicated only if the mass is symptomatic, increasing in size, or of uncertain nature.

## Conflicts of Interest

None.

## References:

1. Mangham CD: World Health Organisation classification of tumours: Pathology and genetics of tumours of soft tissue and bone. *J Bone Joint Surg*, 2004; 86-b: 466
2. Bancroft LW, Kransdorf MJ, Peterson JJ, O'Connor MI; Benign fatty tumors: Classification, clinical course, imaging appearance, and treatment. *Skeletal Radiol*, 2006; 35: 719–33
3. Weiss SW, Goldblum JR: Benign lipomatous tumors. In: Enzinger and Weiss's *Soft Tissue Tumors*. 4<sup>th</sup> ed. St Louis: CV Mosby, 2001; 571–639
4. Myhre-Jensen O: A consecutive 7-year series of 1331 benign soft tissue tumours. Clinicopathologic data. Comparison with sarcomas. *Acta Orthop Scand*, 1981; 52: 287–93
5. Johnson CN, Ha AS, Chen E, Davidson D: Lipomatous soft-tissue tumors. *J Am Acad Orthop Surg*, 2018; 26: 779–88
6. Osment LS: Cutaneous lipomas and lipomatosis. *Surg Gynecol Obstet*, 1968; 127: 129–32
7. Jayi S, Laadioui M, El Fatemi H et al: Vulvar lipoma: A case report. *J Med Case Rep*, 2014; 8: 203
8. Gould DJ, Morrison AC, Liscum KR, Silberfein EJ: A lipoma of the transverse colon causing intermittent obstruction: A rare cause for surgical intervention. *Gastroenterol Hepatol*, 2011; 7(7): 487–90
9. Wu S, Teng P, Zhou Y, Ni Y: A rare case report of giant epicardial lipoma compressing the right atrium with septal enhancement. *J Cardiothorac Surg*, 2015; 10: 150
10. Thyparampil P, Diwan AH, Diaz-Marchan P et al: Eyelid lipomas: A case report and review of the literature. *Orbit*, 2012; 31(5): 319–20
11. Margiotta G, Carlini L, Carnevali E et al: Giant diaphragmatic lipoma: Two autopsy case reports and review of the literature. *J Forensic Sci*, 2015; 60(6): 1640–43
12. Naomi A, Oyamatsu Y, Narita K et al: [Diaphragmatic lipoma needed to distinguish from Bochdalek hernia; Report of a case.] *Kyobu Geka*, 2014; 67(10): 942–45 [in Japanese]
13. Cheon JS, You YK, Kim JG et al: Diaphragmatic lipoma in a 4-year-old girl: A case report. *J Pediatr Surg*, 2006; 41(1): e37–39
14. Smahi M, Serraj M, Ouadnoui Y, Lakranbi M: Diaphragmatic lipoma. A case report. *Rev Pneumol Clin*, 2011; 67: 127–28
15. Sakurai H, Kaji M, Suemasu K: Lipoma of the diaphragm; Report of a case. *Kyobu Geka*, 2008; 61(6): 508–11 [in Japanese]
16. Sen S, Discigil B, Badak I: Lipoma of the diaphragm: A rare presentation. *Ann Thorac Surg*, 2007; 83(6): 2203–5
17. Vougiouklakis T, Mitseloua A, Agnantis NJ: Giant lipoma: An unusual cause of intrathoracic mass. *Pathol Res Pract*, 2006; 202(1): 47–49
18. Oyar O, Yesildag A, Gulsoy UK: Bilateral and symmetric diaphragmatic crus lipomas: Report of a case. *Comput Med Imaging Graph*, 2002; 26(2): 135–37
19. Oyar O, Kayalioglu G, Cagirci U: Diaphragmatic crus lipoma: A case report *Comput Med Imaging Graph*, 1998; 22(5): 421–23

20. Ferguson D, Westco J: Lipoma of the diaphragm. *Radiology*, 1976; 118: 527–28
21. Ballon HC, Spector L: Lipoma of the diaphragm. *Can Med Assoc J*, 1939; 41(5): 487–89
22. Shimizu J, Hashimoto T, Imai T, Kawahara E: Primary lipoma of the diaphragm. *Respiration*, 1996; 63: 397–99
23. Aoyagi H, Uetake H, Ishikawa T et al: [A case report of lipoma-like tumor during hepatic arterial infusion chemotherapy.] *Gan To Kagaku Ryoho*, 2008; 35(12): 2141–43 [in Japanese]
24. Aydin Y, Yamac M, Ulas AB et al: Right diaphragmatic lipoma: Report of five cases and review of the literature *Turk J Med Sci*, 2012; 42: 1449–53
25. Papachristos I, Lautides G, Papaefthimiou O, Andrianopoulos EG: Gigantic primary lipoma of the diaphragm presenting with respiratory failure. *Eur J Cardiothorac Surg*, 1998; 13: 609–11
26. Clagett OT, Johnson MA III: Tumors of diaphragm. *Am J Surg*, 1949; 78: 526–30
27. Soderlund G: Beitrag zur Klinik der primaren Zwerchfelltumoren, besonders zur Diagnostik. *Acta Radiol*, 1937; 18: 388–98 [in German]
28. Pavlica E: Lipoma of the diaphragm with unusual fatal complication. *Neoplasma (Bratisl)*, 1962; 9: 429–33
29. Clark FW: Subpleural lipoma of diaphragm. *Trans Path Soc Lond*, 1886; 138: 324
30. Soto MV: Un caso de lipoma de la cara toracica del diafragma. *J Int Coli Surg*, 1943; 6: 146–53 [in Spanish]
31. Weilgoni M: Zwerehfell-Lipom. Obersieht und Bericht uber 7 verifizierte Faile. *Radiologe*, 1963; 3: 401–4 [in German]