

Contents lists available at [ScienceDirect](https://www.sciencedirect.com)

## International Journal of Surgery Case Reports

journal homepage: [www.casereports.com](http://www.casereports.com)

# Partial penile amputation due to Klingsor syndrome: A case report with a successful macroscopic reconstruction

Syakri Syahrir<sup>a</sup>, Muhammad Asykar Palinrunji<sup>a,\*</sup>, Khoirul Kholis<sup>a</sup>, Syarif<sup>a</sup>, Muhammad Faruk<sup>b</sup>, Robert Christeven<sup>b</sup>

<sup>a</sup> Division of Urology, Department of Surgery, Faculty of Medicine, Hasanuddin University, Makassar, Indonesia

<sup>b</sup> Department of Surgery, Faculty of Medicine, Hasanuddin University, Makassar, Indonesia

## ARTICLE INFO

### Article history:

Received 13 August 2020

Received in revised form 31 October 2020

Accepted 31 October 2020

Available online 7 November 2020

### Keywords:

Traumatic  
Penile amputation  
Reimplantation  
Psychiatric illness  
Penile reconstruction  
Case report

## ABSTRACT

**INTRODUCTION:** Traumatic penile amputation is a highly uncommon surgical emergency that requires immediate intervention. Most reported cases involve genital self-mutilation induced by underlying psychiatric disorder, especially schizophrenia. The self-mutilation of external genitals in psychiatric patients, also known as Klingsor syndrome, is a rare form of urotrauma.

**PRESENTATION OF CASE:** We present a case of partial penile amputation in a 46-year-old male with Klingsor syndrome admitted to the hospital 3 days after the incident. Urological examination revealed a subtotal cut of the penis, including the distal part of the mons pubis, dorsal and lateral parts of the penile skin, corpus cavernosum, and corpus spongiosum, as well as a partial bulbous urethra rupture. The penis remained suspended by only a thin ventral part of the penile skin. After macroscopic surgical replantation, the patient recovered well and could urinate without any symptoms of urethral stricture. The entire penis remained viable with minimal scarring at the surgical site, and penile erection could be achieved and maintained.

**CONCLUSION:** The case demonstrates a rare instance of the successful proximal penile shaft amputation via macrosurgical techniques by an experienced urologic surgeon.

© 2020 The Authors. Published by Elsevier Ltd on behalf of IJS Publishing Group Ltd. This is an open access article under the CC BY-NC-ND license (<http://creativecommons.org/licenses/by-nc-nd/4.0/>).

## 1. Introduction

Traumatic penile amputation is a rare surgical emergency typically related to major functional disability and psychological disorders that impact patients' overall quality of life. Most reported cases of traumatic penile amputation occur in response to genital self-mutilation induced by underlying psychiatric disorders, especially schizophrenia [1,2]. The self-mutilation of the external genitals in psychiatric patients, also known as the clinical condition Klingsor syndrome, is a rare form of urotrauma [2], one in which patients with known psychiatric disorders indulge in destroying their genitals but without any intent to commit suicide [3].

Traumatic penile amputation is a critical event for patients and their families, for it entails more than mere medical intervention. A review of 80 cases of traumatic penile amputation performed from 1996 to 2007 revealed that only 37.5% of the cases involved success-

ful penile replantation [4]. Despite the lack of approved guidelines or protocols for the procedure, the current standard of treatment for such an infrequent injury is replantation with an approximation of the urethra and corpus cavernosum, microsurgery on the dorsal vein and artery, and nerve anastomosis [2]. Here, following the 2018 Surgical Case Report guidelines [5], we report the uncommon case of a male with Klingsor syndrome who required traumatic penile amputation.

## 2. Case presentation

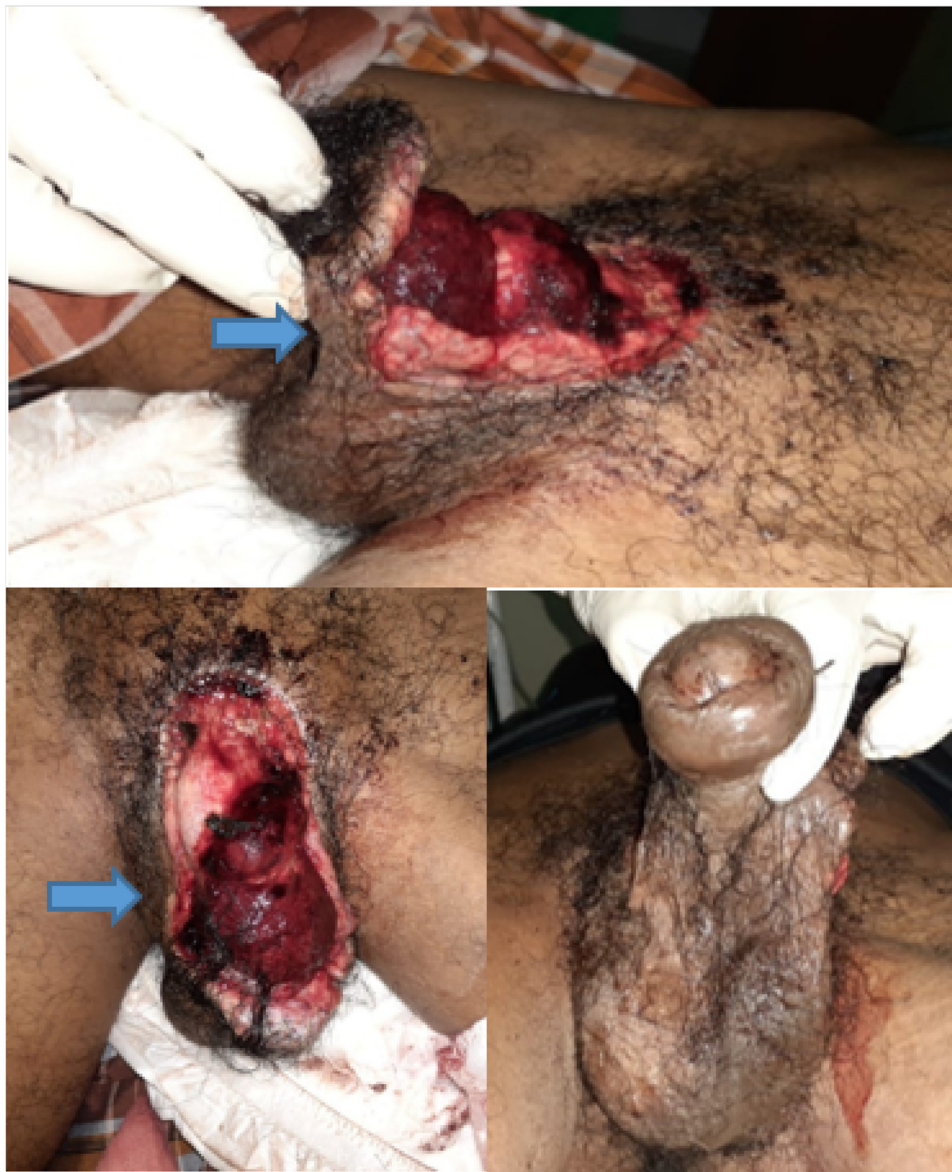A 46-year-old male with a history of paranoid schizophrenia was referred to our hospital after he cut his penile shaft, along with a 3-cm distal part of the mons pubis, with a sharp sickle. Following massive blood loss from the wound, bleeding was controlled after several hours of treatment in a primary health center. The patient also had a history of bloody discharge from the external urethral orifice.

After initial evaluation at a tertiary hospital, the patient was admitted to our hospital approximately 3 days after the injury. Following an initial assessment and resuscitation, the patient was administered tetanus toxoid for prophylaxis and given broad-spectrum antibiotics. Upon admission in the emergency room, mental examination revealed the patient's apathy, consciousness,

\* Corresponding author at: Division of Urology, Department of Surgery, Faculty of Medicine, Hasanuddin University, Jalan Perintis Kemerdekaan KM 11, Makassar, 90245, South Sulawesi, Indonesia.

### E-mail addresses:

[drsyakrisyahrir@gmail.com](mailto:drsyakrisyahrir@gmail.com) (S. Syahrir), [apalirunji@yahoo.com](mailto:apalirunji@yahoo.com) (M.A. Palinrunji), [khoirulkholis@yahoo.com](mailto:khoirulkholis@yahoo.com) (K. Kholis), [syarifbakri@hotmail.com](mailto:syarifbakri@hotmail.com) (Syarif), [farox8283@gmail.com](mailto:farox8283@gmail.com) (M. Faruk), [rchristeven.rc@gmail.com](mailto:rchristeven.rc@gmail.com) (R. Christeven).



**Fig. 1.** Subtotal cut of the penis. The penis remained suspended by only a thin ventral part of the penile skin (blue arrow).

and sometimes agitation. The patient's eye contact was poor, and his speech was incoherent. Urological examination showed a subtotal cut of the penis, including the distal part of the mons pubis and the dorsal and lateral parts of the penile skin, and a clear cut through the corpus cavernosum. The penis remained suspended by only a thin ventral part of the penile skin (Fig. 1).

The patient was immediately transferred to the operating room. After the administration of spinal regional anesthesia, the patient was placed in the lithotomy position. Following disinfection and draping, a 16 Fr silicone Foley catheter was carefully inserted into the external urethral orifice.

A careful assessment on the penile wound revealed a partial-thickness wound with a relatively well-defined traumatic separation of tissues on the dorsal of the penis, one that crossed the base of the penis and was in fact formed by two incised wounds (Fig. 2A). The first wound caused a 5-cm separation of dorsal of the penis from its base, whereas the second wound was located more proximally from the first and separated the penis about 3 cm from its base. The transection of the corpus cavernosum and corpus spongiosum was discovered along with a 1-cm defect of the bulbous

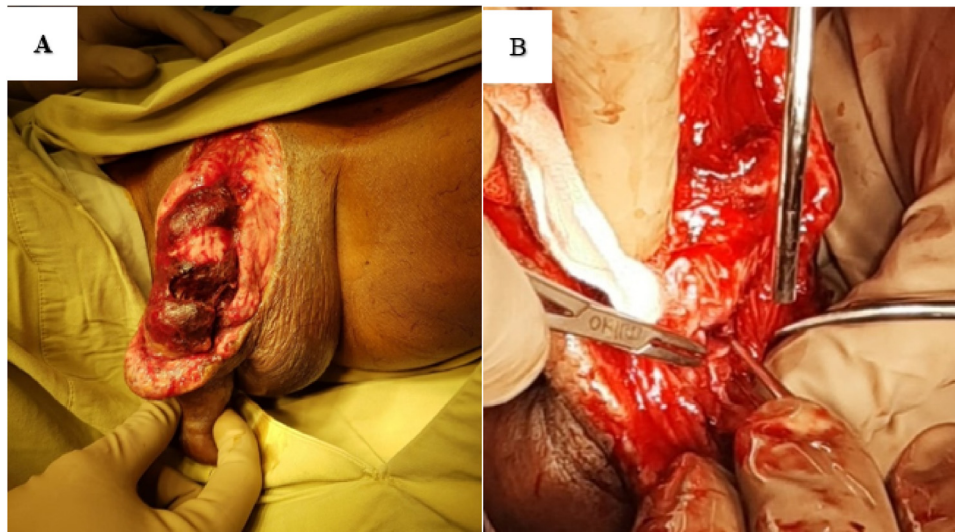
urethra (Fig. 2B). We assessed the wound as Grade IV penile injury according to the American Association for the Surgery of Trauma (AAST), because although the urethral defect was less than 2 cm, the cavernous defect exceeded 2 cm.

Once surgery was planned following a multidisciplinary approach, the patient was transferred to the operating room 2 h after arriving at the emergency department. We (i.e., a urologic surgeon and general surgery resident) performed a debridement procedure and refreshed the wound edge (Fig. 3A). The corpus cavernosum was re-anastomosed with an interrupted suture using absorbable polyglactin 5/0 (Fig. 3B).

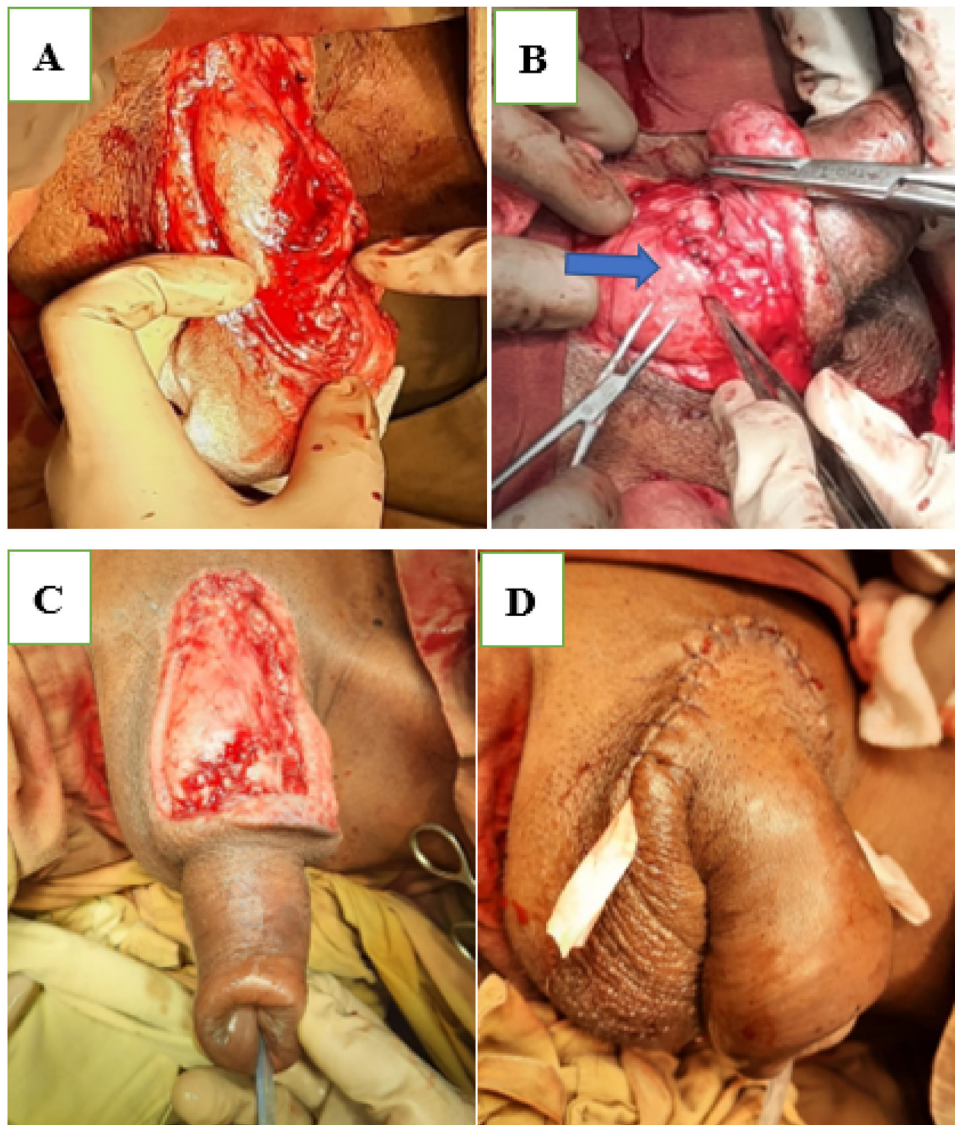
Next, the defect of the bulbous urethra was closed, also with an interrupted suture using absorbable polyglactin 5/0. We did not perform any anastomosis of the dorsal vein, artery, or nerve. After deep (Buck's) and superficial (Dartos) fascia were reapproximated (Fig. 3C), the operation was finished with another interrupted suture of the skin. A Penrose drain was left on each of the right and left sides of the wound (Fig. 3D).

After acute surgery, the patient was transferred to the psychiatric department for the management of his psychiatric condition.

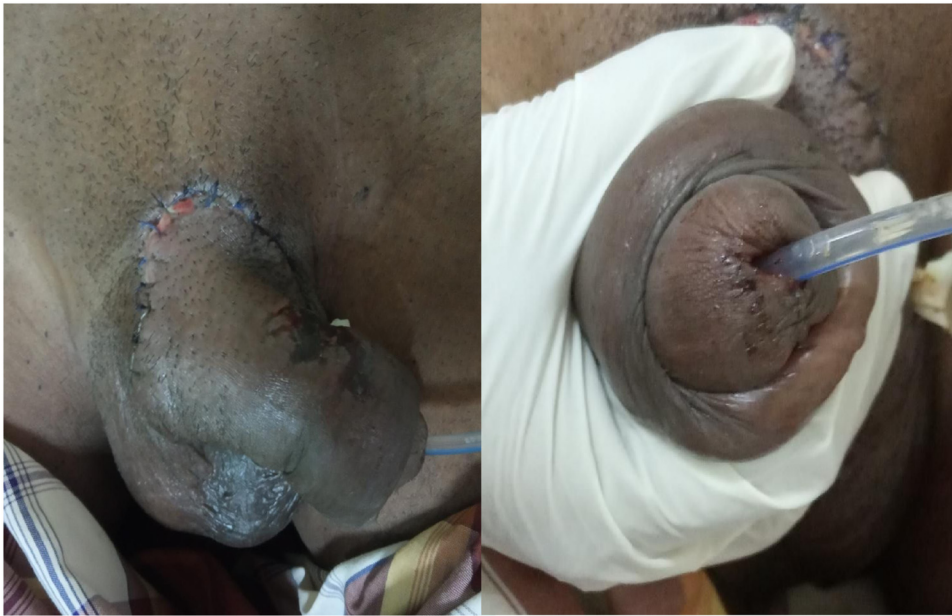



**Fig. 2.** A) The partial-thickness wound with a relatively well-defined traumatic separation of tissue on the dorsal of the penis. B) The defect of the bulbous urethra.



**Fig. 3.** A) Debridement was performed, and the wound edge was refreshed. B). The corpus cavernosum and urethral defect were repaired. C) Deep and superficial fascia were reapproximated. D) The surgical site after interrupted skin suture had two Penrose drains left inside.



**Fig. 4.** The surgical wound recovered well, and the penis remained viable.

Intravenous antibiotic ampicillin–sulbactam was administered 3 times daily. After leaving the psychiatric department, the patient received antipsychotic risperidone (2 mg, twice daily) and clozapine (25 mg, once daily). Proper wound care was performed every 2 days to investigate the wound's condition and to ensure successful wound healing.

On Day 3 postsurgery, the Penrose drains were removed, and on Day 6, the patient was discharged from the hospital. His surgical wound had recovered well, and neither skin necrosis nor infection was observed (Fig. 4). The silicone Foley catheter was maintained for another 21 days. Approximately 4 weeks postsurgery, the Foley catheter was removed, and the patient appeared to have recovered well and was urinating effectively without any symptoms of urethral stricture. The entire penis remained viable with minimal scarring at the surgical site and could achieve and maintain erection.

### 3. Discussion

Traumatic penile amputation, a rare surgical emergency that requires immediate care [3], can trigger significant blood loss and thus require the patient to receive aggressive fluid resuscitation and blood transfusion during primary assessment. Because penile amputation is uncommon, the lack of high-quality evidence has precluded the development of any standardized approach to care [6,7].

A systematic review of the literature revealed approximately 30 cases of successful penile replantation from 80 cases of penile self-amputation from 1966 to 2007 [8]. Isolated accidental amputation is rare and responsible for only approximately 20% of amputations. The most common etiologies are self-inflicted in a clinical condition called “Klingsor syndrome” [9], a term used to describe genital self-mutilation associated with delusions. The term “Klingsor” is based on a fictional character in one of Richard Wagner's operas in which Klingsor, a magician, castrates himself due to his inability to remain pure enough to be accepted as a knight fit to recover the Holy Grail [2]. In our case, the patient had paranoid schizophrenia and had mutilated his genitals in response to delusional thoughts. The corpus cavernosum and spongiosum were cut along with a partial rupture of the bulbous urethra. According to the AAST guideline for penile injury [10], we classified the finding as a Grade IV penile

injury. After initial assessment and resuscitation, we prepared to reconstruct the penis.

Two approaches to replanting amputated penises are currently available—a conventional macroscopic technique and a microscopic technique—both of which have resulted in various outcomes in several studies [7]. In the macroscopic technique of penile replantation in the case of an amputated penis, first reported by Ehrlich in 1929, arterial anastomosis cannot be performed. That technique incorporates a structural approach to the penis without any neurovascular repair. Despite satisfactory functional and cosmetic results, skin necrosis is generalized [11]. By and large, macroscopic replantation techniques have been employed with good postoperative results [7].

The first microscopic replantation, by contrast, was reported by Cohen et al. in 1977. Microscopic replantation involves meticulous microneurovascular surgery to reduce skin, urethral, and graft loss and enables the repair of vessels and nerves. As a result, the technique can preserve the pleasurable sensation of the sex organs, urination, and erectile function, although complications may still occur [2,12]. In some cases, microsurgical repair would have improved outcomes, but equipment, time, and training were lacking [13]. Morrison et al. reported on 106 case reports of penile replantation, in which 91.6% of patients were generally satisfied, although complications did occur [9]. In a systematic review of 80 patients who underwent replantation, 30 patients who received microneurovascular repair reported that microsurgical repair reduced complications (e.g., fistulae, stricture formation, skin necrosis, sensory loss, and erectile dysfunction) and improved graft survival and cosmetic outcomes [4]. Those microscopic techniques constitute a gold standard and have achieved excellent results [7]. In general, microscopic replantation seems to afford better chances of organ survival and lower complication rates, although statistically convincing evidence remains unavailable. The disadvantages of the technique, however, include the requirement of skill and equipment for such procedures that may be unavailable in places with few resources or, at times, in emergency situations [11].

Various studies have shown that repairing a single dorsal penile artery is more important than repairing a single or even multiple deep arteries [2,11,12]. For that reason, microscopic and macroscopic repairs may exhibit the same results. Macroscopic repair has



also been employed with good postoperative outcomes, although with a higher rate of complications such as partial skin necrosis, urethral strictures, and fistulae [7,14]. In our case, the patient had recovered well, and the penis remained viable without any complication (e.g., urethral stricture or erectile dysfunction).

#### 4. Conclusion

Our case demonstrates a rare instance of the successful proximal penile shaft amputation via macrosurgical techniques by an experienced urologic surgeon.

#### Declaration of Competing Interest

Nothing to declare.

#### Funding

No funding or sponsorship.

#### Ethical approval

The study is exempt from ethical approval in our institution.

#### Consent

Written informed consent was obtained from the patient for publication of this case report and accompanying images. A copy of the written consent is available for review by the Editor-in-Chief of this journal on request.

#### Author contribution

**Syakri Syahrir, Muhammad Asykar Palinrungi, and Muhammad Faruk:** study concept, surgical therapy for this patient. **Syakri Syahrir:** Data collection, Writing-Original draft preparation. **Khoirul Kholis:** senior author and the manuscript reviewer. **Syarif:** reviewed the manuscript. **Muhammad Faruk and Robert Christeven:** Editing, Writing. **All authors** read and approved the final manuscript.

#### Registration of research studies

N/A.

#### Guarantor

Syakri Syahrir.

#### Provenance and peer review

Not commissioned, externally peer-reviewed.

#### References

- [1] R. Bhattacharyya, D. Sanyal, K. Roy, A case of Klingsor syndrome: when there is no longer psychosis, *Isr. J. Psychiatry Relat. Sci.* 48 (2011) 30–33 <http://www.ncbi.nlm.nih.gov/pubmed/21572240>.
- [2] Y. El harrech, N. Abaka, O. Ghoundale, D. Touiti, Genital self-amputation or the Klingsor syndrome: successful non-microsurgical penile replantation, *Urol. Ann.* 5 (2013) 305, <http://dx.doi.org/10.4103/0974-7796.120309>.
- [3] S.C. Bhargava, S. Sethi, A.K. Vohra, Klingsor syndrome: a case report, *Indian J. Psychiatry* 43 (2001) 349–350 <https://pubmed.ncbi.nlm.nih.gov/21407886>.
- [4] A.R. Babaei, M.R. Safarinejad, Penile replantation, science or myth? A systematic review, *Urol. J.* 4 (2007) 62–65 <http://www.ncbi.nlm.nih.gov/pubmed/17701923>.
- [5] R.A. Agha, M.R. Borrelli, R. Farwana, K. Koshy, A.J. Fowler, D.P. Orgill, H. Zhu, A. Alsawadi, A. Noureldin, A. Rao, A. Enam, A. Thoma, M. Bashashati, B. Vasudevan, A. Beamish, B. Challacombe, R.L. De Wilde, D. Machado-Aranda, D. Laskin, D. Muzumdar, A. D'cruz, T. Manning, D. Healy, D. Pagano, P. Goel, P. Ranganathan, P.S. Pai, S. Raja, M.H. Ather, H. Kadioäzlu, I. Nixon, I. Mukherjee, J. Gómez Rivas, K. Raveendran, L. Derbyshire, M. Valmasoni, M. Chalkoo, N. Raison, O. Muensterer, P. Bradley, C. Roberto, R. Affifi, D. Rosin, R. Klappenbach, R. Wynn, S. Giordano, S. Basu, S. Surani, P. Suman, M. Thorat, V. Kasi, The SCARE 2018 statement: Updating consensus Surgical CAse REport (SCARE) guidelines, *Int. J. Surg.* 60 (2018) 132–136, <http://dx.doi.org/10.1016/j.ijsu.2018.10.028>.
- [6] O.A. Raheem, H.S. Mirheydar, N.D. Patel, S.H. Patel, A. Suliman, J.C. Buckley, Surgical management of traumatic penile amputation: a case report and review of the world literature, *Sex. Med.* 3 (2015) 49–53, <http://dx.doi.org/10.1002/sm2.54>.
- [7] J.E. Mensah, L.D. Bray, E. Akpakli, M.Y. Kyei, M. Oyortey, Successful penile replantation and systematic review of world literature, *Afr. J. Urol.* 23 (2017) 253–257, <http://dx.doi.org/10.1016/j.afju.2017.02.003>.
- [8] E.A. Selby, T.W. Bender, K.H. Gordon, M.K. Nock, T.E. Joiner, Non-suicidal self-injury (NSSI) disorder: a preliminary study, *Personal. Disord. Theory Res. Treat.* 3 (2012) 167–175, <http://dx.doi.org/10.1037/a0024405>.
- [9] S. Morrison, A. Shakir, K. Vyas, A. Remington, B. Mogni, S. Wilson, D. Grant, D. Cho, A. Rahneimai-Azar, G. Lee, J. Friedrich, S. Mardini, Penile replantation: a retrospective analysis of outcomes and complications, *J. Reconstr. Microsurg.* 33 (2016) 227–232, <http://dx.doi.org/10.1055/s-0036-1597567>.
- [10] E.E. Moore, M.A. Malangoni, T.H. Cogbill, N.E. Peterson, H.R. Champion, G.J. Jurkovich, S.R. Shackford, Organ injury scaling VII, *J. Trauma Inj. Infect. Crit. Care* 41 (1996) 523–524, <http://dx.doi.org/10.1097/00005373-199609000-00023>.
- [11] F.N. Facio, L.C. Spessoto, P. Arruda, C.S. Paiva, J.G. Arruda, M.F. Facio, Penile replantation after five hours of warm ischemia, *Urol. Case Rep.* 3 (2015) 77–79, <http://dx.doi.org/10.1016/j.eurc.2015.01.012>.
- [12] G. Aggarwal, Klingsor syndrome: a rare surgical emergency, *Turkish J. Trauma Emerg. Surg.* (2017), <http://dx.doi.org/10.5505/tjtes.2016.30346>.
- [13] M.G. Crockett, Complete internal penile auto-amputation, *Biomed. J. Sci. Tech. Res.* 5 (2018), <http://dx.doi.org/10.26717/BJSTR.2018.05.001218>.
- [14] J. Fazi, D. Adkins, J. Knight, A. Luchey, Unusual mechanisms of penile amputation, *Case Rep. Urol.* 2019 (2019), 1582047, <http://dx.doi.org/10.1155/2019/1582047>.

#### Open Access

This article is published Open Access at [sciencedirect.com](https://www.sciencedirect.com). It is distributed under the [IJSCR Supplemental terms and conditions](#), which permits unrestricted non commercial use, distribution, and reproduction in any medium, provided the original authors and source are credited.