



## Case Report

## A case report of secondary spontaneous pneumothorax in acute exacerbation of COPD managed with improvised chest tube drain

Gopal Kumar Yadav<sup>a,\*</sup>, Bibek Keshari<sup>a</sup>, Dipesh Kumar Rohita<sup>b</sup>, Krishna Chandra Mandal<sup>c</sup>, Sunil Bogati<sup>b</sup>, Deebya Raj Mishra<sup>d</sup>

<sup>a</sup> Department of Internal Medicine, Kalaiya District Hospital, Bara, Nepal

<sup>b</sup> Department of Internal Medicine, B. P. Koirala Institute of Health Sciences, Dharan, Nepal

<sup>c</sup> Department of Emergency Medicine, Gaur District Hospital, Rautahat, Nepal

<sup>d</sup> Department of Pulmonary, Critical Care and Sleep Medicine, B. P. Koirala Institute of Health Sciences, Dharan, Nepal



## ARTICLE INFO

## Keywords:

Case report

COPD

Improvised chest drain

Secondary spontaneous pneumothorax

## ABSTRACT

**Introduction:** and importance: We reported a case of secondary spontaneous pneumothorax (SSP) in a 70-years-old male with acute exacerbation of COPD (AE COPD) managed with improvised chest tube drain (ICD).

**Case presentation:** He presented with sudden onset breathlessness and oxygen saturation of 78%. With prolonged expiration on auscultation, he was treated as AE COPD with oxygen therapy, nebulization with albuterol/ipratropium, and injectable antibiotics and steroids. The patient was not improving with treatment on third day, and non-critical respiratory distress continued. Considering the alternative diagnosis, the chest X-ray was done which revealed right sided spontaneous pneumothorax and COPD. Due to his reluctance to go to higher center for chest tube insertion during ongoing COVID-19 pandemic, we inserted ICD (intravenous set put in saline bottle) at our primary care. Following drainage, breathlessness improved and saturation increased. Then inpatient symptomatic treatment for COPD was continued for three more days. He was discharged on inhalers after fifth day and asked for follow up after 10 days. He came after 1 month and on repeat chest X-ray, his right sided pneumothorax resolved completely and COPD was in control with inhaled medications. There was no recurrence of pneumothorax in five months follow up.

**Clinical discussion:** ICD is a safe, and an alternative option in resource limited setting. However, the guidelines recommend chest tube insertion as appropriate treatment.

**Conclusion:** This would remind the physicians to anticipate the alternative possibility, and to re-examine those with AE COPD who are not improving as expected with oxygen and nebulization therapy.

### 1. Introduction

A pneumothorax is an accumulation of air in the pleural space which compromises cardiopulmonary function [1]. There are two types of pneumothorax viz., traumatic and atraumatic/spontaneous. Atraumatic or spontaneous pneumothorax can be further divided into two types—primary spontaneous pneumothorax (PSP) in the absence of known lung disease and secondary spontaneous pneumothorax (SSP) with underlying lung disease [2]. Most of the PSP are managed by observation and/or needle aspiration. And usually, SSP requires a chest tube drain [3].

This article highlights the occurrence of SSP in acute exacerbation of COPD, to remind the physicians of the alternative possibility in those not improving with oxygen and nebulization. This also sheds the light on the

management of secondary spontaneous pneumothorax with improvised chest drain.

### 2. Method

This case report has been reported in line with the SCARE Criteria [4].

### 3. Case presentation

A 70-years-old male with known case of COPD and reformed smoker for last 5 years was brought to the emergency department (ED) of Kalaiya District Hospital, by his wife with increased shortness of breath for 6

\* Corresponding author.

E-mail address: [gopalbpkihs@gmail.com](mailto:gopalbpkihs@gmail.com) (G.K. Yadav).

<https://doi.org/10.1016/j.amsu.2022.104064>

Received 18 May 2022; Received in revised form 19 June 2022; Accepted 21 June 2022

Available online 25 June 2022

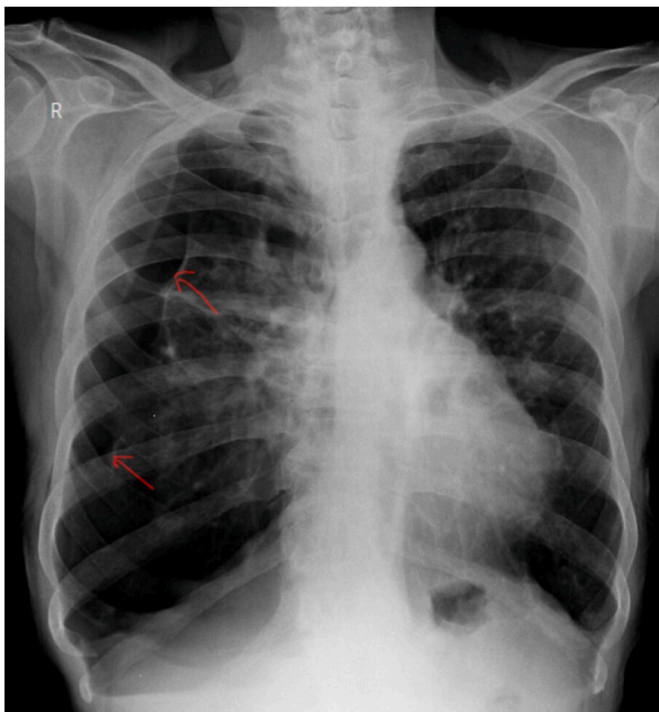
2049-0801/© 2022 The Authors. Published by Elsevier Ltd on behalf of IJS Publishing Group Ltd. This is an open access article under the CC BY-NC-ND license (<http://creativecommons.org/licenses/by-nc-nd/4.0/>).

hours.

On general examination, he was anxious but alert, oriented to time, place, and person with moderate distress. He had two to three-word dyspnea. He had trouble lying down on the bed and was sitting in a tripod posture. His pulse rate was 112 beats/minute, blood pressure was 140/90 mm Hg, respiratory rate was 26 cycles/min, the temperature was 98.8 F, and SpO<sub>2</sub> was 78%. On cardiovascular examination, there were no murmurs. On respiratory examination, he was using his accessory muscles for respiration. The trachea was central. There was a bilateral vesicular breath sound with prolonged expiration as well as expiratory wheeze.

With a provisional diagnosis of acute exacerbation of COPD, oxygen therapy was started via face mask (flow 5–6L/min; FiO<sub>2</sub> 44%), and nebulization with albuterol + ipratropium was done. ECG was done, which revealed right axis deviation. Spo<sub>2</sub> increased to 82% and shortness of did not improve. Blood investigations were sent. His hemoglobin was 13.6 g/dl, total leukocyte count was 8800/mm<sup>3</sup> of blood (N88% L16%), random blood sugar was 124 mg/dl, cardiac troponin test was negative, and ESR was 16mm/1st hour.

He was admitted in inpatient department, and started on treatment with injection ceftriaxone (2 g intravenous/day), tablet azithromycin (500 mg orally/day), nebulization (albuterol + ipratropium + normal saline every six-hourly), injection hydrocortisone (100 mg IV twice a day) and inhaler drugs (rotacapsule formeterol fumarate 6 mcg + budesonide 200 mcg twice a day, and rotacapsule ipratropium bromide 18 mcg once a day via revolizer device). Other supportive measures like intravenous fluids and proton pump inhibitors were given whenever required. Despite these treatments, he continued to have dyspnoea even on the second day. In view of possible alternative diagnosis, chest X-ray was done, and there was an absence of right-sided bronchoalveolar markings, distinct visceral pleural reflection with hyperinflated bilateral lung fields, flattened diaphragm, and narrow heart shadow. We revised our diagnosis to secondary spontaneous pneumothorax (SSP). (Fig. 1).



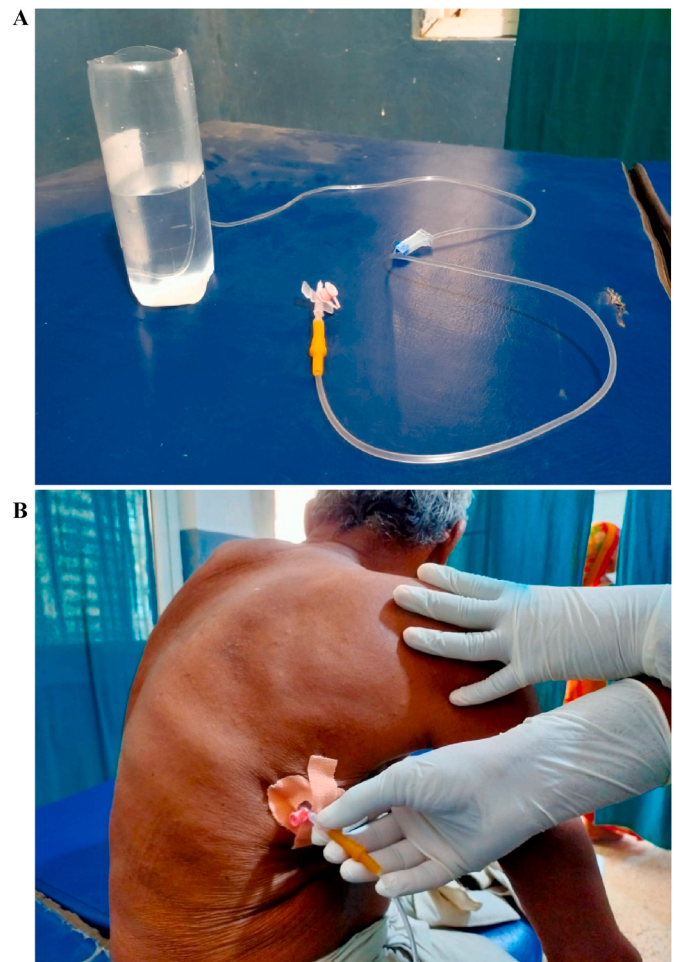
**Fig. 1.** COPD and Right-Sided Secondary Spontaneous Pneumothorax (Before intervention) (Red arrow points to right visceral pleural reflection). (For interpretation of the references to colour in this figure legend, the reader is referred to the Web version of this article.)

Due to his reluctance to go to higher center for chest tube insertion during ongoing COVID-19 pandemic, and resource constraints at admitted hospital, we inserted improvised chest drain on the same day.

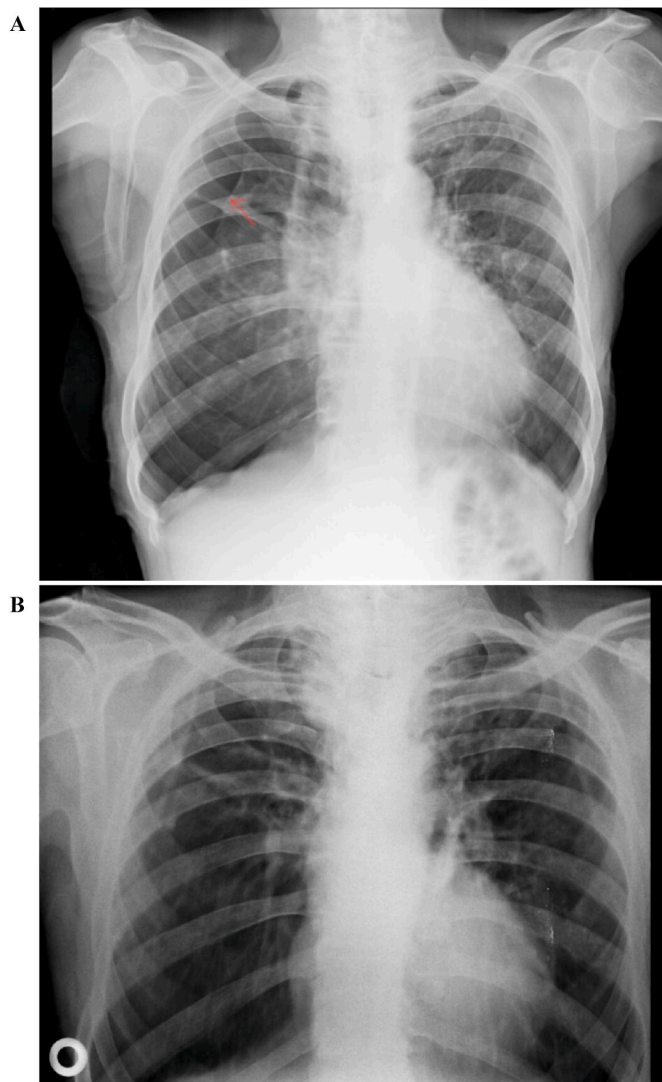
The improvised chest drain was constructed using a 16G IV cannula connected to an IV set drained into a saline bottle filled with water (Fig. 2A). The IV cannula was inserted in the right 5th intercostal space in the mid-axillary line in the triangle of safety (Fig. 2B). Immediately after insertion, oozing of air bubbles from a normal saline bottle was seen. The intrapleural air drained spontaneously for 15 minutes, after which aspiration with a 20 ml syringe was done, and an IV cannula was taken out. A tight seal with surgical tape was applied for the next 24 hours. The patient felt immediate relief after the procedure. He could talk in complete sentences and his oxygen saturation improved to 92% (Fig. 3A).

He was admitted for a total of 5 days and treated for COPD with low flow oxygen delivery (via nasal cannula, flow 2–3 L/min, FiO<sub>2</sub> 28%) and antibiotics and discharged on the 6th day on inhaler drugs (rotacapsule formeterol fumarate 6 mcg + budesonide 200 mcg twice a day and rotacapsule ipratropium bromide 18 mcg once a day via Revolizer device).

The patient was asked to follow up after ten days but came up only after 1 month. He was clinically well, able to walk without shortness of breath and talk in full sentences. The chest was clear on auscultation. In a repeat chest X-ray, the remaining air in the pleural cavity had resolved (Fig. 3B). In follow-up after eight months, the patient had been doing well, and there was no recurrence of pneumothorax.



**Fig. 2.** A. Improvised chest drain preparation  
B. Improvised chest tube drain thoracostomy in right triangle of safety and watchful waiting at the bed side.



**Fig. 3.** A. COPD and Right-Sided Secondary Spontaneous Pneumothorax (After 1 hour of intervention) (Red arrow points to right visceral pleural reflection) B. COPD and resolution of Right-Sided Secondary Spontaneous Pneumothorax (After 1 months of intervention).

#### 4. Discussion

Pneumothorax (collapsed or dropped lung) is an emergency condition when air enters the pleural space, i.e., the distance between the lungs and the chest wall [5]. Patients with PSP (those associated with sub-pleural blebs in the absence of an underlying disorder) are typically in their early 20s. This PSP classically occurs in young, tall, thin, smoking males. In contrast, most cases of SSP (those associated with underlying lung disease) are due to emphysema, and they tend to be older [6–8].

Pneumothorax is typically detected on an erect posterior-anterior chest X-ray image through visual inspection by experienced radiologists [3,9]. The posterior-anterior chest radiograph shows absent lung markings extending from the edge of the visceral pleura to the chest wall. However, it is possible to confuse a pneumothorax with a lung bulla. The mediastinal shift is usually evident in individuals with a tension pneumothorax. Computed tomography (CT) imaging of the chest is occasionally performed when diagnostic uncertainty exists, for example, to distinguish a pneumothorax from a large bulla or when the lung field is obscured by surgical emphysema. It is also often carried out

before a contemplated surgical procedure or when an underlying lung abnormality—such as interstitial lung disease, lymphangioleiomyomatosis, or histiocytosis—is considered a possibility [10]. Ultrasound of the pleura is best utilized when bedside rapid imaging is needed to diagnose pneumothorax (e.g., unstable patients with trauma or patients with suspected tension) [11].

The management of pneumothorax depends on the severity of symptoms, its size, and the presence of underlying lung disease. According to British Society Guidelines 2010, the size between the lung edge and chest wall is used to estimate the size of pneumothorax, i.e., <2 cm for small pneumothorax and  $\geq 2$  cm for large pneumothorax. The treatment of PSP includes initially needle aspiration (NA) with subsequent chest radiography and observation [3]. This contrasts with US guidelines where chest drain is considered more appropriate [12]. The treatment of SSP includes catheter or chest tube insertion and simultaneous treatment of underlying lung disease [10].

Our patient had SSP and was managed with needle thoracostomy and aspiration, although existing guidelines recommend catheter insertion or tube thoracostomy [3,12]. There is a role of needle thoracostomy in tension pneumothorax and early stage of secondary pneumothorax. There is limited data on needle thoracostomy as the primary modality of treatment in SSP. A study by Ganaie et al. showed that there was no particular advantage in using NA as the first intervention over intercostal tube (ICT) in SSP. It should not be included in the SSP treatment algorithm in view of poor, successful lung re-inflation rate, longer hospital stays, and all eventually requiring ICT [13].

Few cases have been reported where an improvised underwater seal drain was used after fixation of the peripheral venous catheter for treatment of pneumothorax in neonates, and the result is conclusive and life-saving with limited resources [14].

So, our patient with SSP was managed with an improvised chest drain and treatment of co-existing lung disease. The COPD was in control and stable with bronchodilator inhalers over eight months with no recurrence of pneumothorax.

The improvised chest tube drain using IV cannula, IV set and IV fluid bottle is an alternative to chest tube. This improvised chest drain has some pros and cons. This improvised chest drain is cheap, can be easily constructed, suitable for resource-limited settings, can be easily inserted without supervision and higher skills, less risk of chest tube related-complications and shorter length of hospital stay. The disadvantage of using this improvised chest drain is that there is high chance of disconnection of IV set and IV cannula and sucking of air back into interpleural space. This is not suitable for hemothorax drainage.

#### 5. Conclusion

There should be the high level of suspicion to anticipate an alternative diagnosis of spontaneous pneumothorax in acute exacerbation of COPD, not improving as expected with oxygen and nebulization. Similarly, the improvised chest drain can be a safe and useful alternative option for treating secondary spontaneous pneumothorax.

#### Ethical approval

Not applicable.

#### Sources of funding

No any funding for our manuscript.

#### Author contribution

Gopal Kumar Yadav, Bibek Keshari, Dipesh Kumar Rohita, Krishna Chandra Mandal, Sunil Bogati and Deebya Raj Mishra were involved in writing, editing and review of the manuscript. Gopal Kumar Yadav and Bibek Keshari were involved in the management of the patient. All



authors read and approved the final manuscript.

### Declaration of competing interest

None.

### Registration of research studies

Name of the registry:

Unique Identifying number or registration ID:

Hyperlink to your specific registration (must be publicly accessible and will be checked):

### Guarantor

Gopal Kumar Yadav, [gopalbpkihs@gmail.com](mailto:gopalbpkihs@gmail.com).

### Consent

Written informed consent was obtained from the patient for publication of this case report and accompanying images. A copy of the written consent is available for review by the Editor-in-Chief of this journal on request.

### Provenance and peer review

Not commissioned, externally peer reviewed.

### Acknowledgements

We would like to thank to Dr. Ashok Raj Devkota, Dr. Saroj Prakash Kandel and Mrs. Sona Gurung.

### Abbreviations

COPD	Chronic Obstructive Pulmonary Disease
ED	Emergency Department
ECG	Electrocardiogram
IV	Intravenous
ICT	Intercostal Tube
NA	Needle aspiration
PSP	Primary Spontaneous Pneumothorax

SSP Secondary Spontaneous Pneumothorax

### Appendix A. Supplementary data

Supplementary data to this article can be found online at <https://doi.org/10.1016/j.amsu.2022.104064>.

### References

- [1] E.D. Vinson, Improvised chest tube drain for decompression of an acute tension pneumothorax, *Mil. Med.* 169 (2004) 403–405, <https://doi.org/10.7205/milmed.169.5.403>.
- [2] P. Zarogoulidis, I. Kioumis, G. Pitsiou, et al., Pneumothorax: from definition to diagnosis and treatment, *J. Thorac. Dis.* 6 (2014) 372–376, <https://doi.org/10.3978/j.issn.2072-1439.2014.09.24>.
- [3] A. MacDuff, A. Arnold, J. Harvey, Bts Pleural Disease Guideline Group, Management of spontaneous pneumothorax: British thoracic society pleural disease, *Guideline 2* (2010) 18–31.
- [4] R.A. Agha, T. Franchi, C. Sohrabi, G. Mathew, A. Kerwan, A. Thoma, et al., The SCARE 2020 guideline: updating consensus surgical Case REport (SCARE) guidelines, *Int. J. Surg.* 84 (2020) 226–230, <https://doi.org/10.1016/j.ijsu.2020.10.034>, dec.
- [5] J.B. Imran, A.L. Eastman, Pneumothorax, *JAMA* 318 (2017), <https://doi.org/10.1001/jama.2017.10476>, 974–974.
- [6] S. Kepka, J.C. Dalphin, A.L. Parmentier, et al., Primary spontaneous pneumothorax admitted in emergency unit: does first episode differ from recurrence? A cross-sectional study, *Cancer Res. J.* (2017), 2729548, <https://doi.org/10.1155/2017/2729548>.
- [7] Noppen M, De Keukeleire T.: Pneumothorax. *Respir Int Rev Thorac Dis.*, 76: 121-127. <https://doi.org/10.1159/000135932>. 2008, 10.1159/000135932.
- [8] T. Onuki, S. Ueda, M. Yamaoka, et al., Primary and secondary spontaneous pneumothorax: prevalence, clinical features, and in-hospital mortality, *Cancer Res. J.* (2017), 6014967, <https://doi.org/10.1155/2017/6014967>.
- [9] A. Sze-To, A. Riasatian, H.R. Tizhoosh, Searching for pneumothorax in x-ray images using autoencoded deep features, *Sci. Rep.* 11 (2021) 9817, <https://doi.org/10.1038/s41598-021-89194-4>.
- [10] G.P. Currie, R. Alluri, G.L. Christie, J.S. Legge, Pneumothorax: an update, *Postgrad. Med.* 83 (2007) 461–465, <https://doi.org/10.1136/pgmj.2007.056978>.
- [11] S. Alrajab, A.M. Youssef, N.I. Akkus, G. Caldito, Pleural ultrasonography versus chest radiography for the diagnosis of pneumothorax: review of the literature and meta-analysis, *Crit Care Lond Engl* 17 (2013) 208, <https://doi.org/10.1186/cc13016>.
- [12] M.H. Baumann, C. Strange, J.E. Heffner, et al., Management of spontaneous pneumothorax: an American college of chest physicians delphi consensus statement, *Chest* 119 (2001) 590–602, <https://doi.org/10.1378/chest.119.2.590>.
- [13] M. Ganaie, S. Bikmalla, M. Khalil, M. Afridi, M. Haris, I. Hussain, Is there a role of needle aspiration in secondary spontaneous pneumothorax requiring intervention? *Chest* 145 (2014) 282A, <https://doi.org/10.1378/chest.1826170>.
- [14] M.B.M. Alves, N. Conté, I.S. Diallo, M. Roth-Kleiner, Clinical presentation and improvised management of neonatal pneumothorax in the setting of a low-resource country: conakry, Guinea, *BMJ Case Rep CP* 14 (2021), 235801, <https://doi.org/10.1136/bcr-2020-235801>.