

Aim of the study: Despite advances in surgical and radiotherapy techniques, the presence of lymph node metastasis drastically decreases the survival rate of patients with primary oral squamous cell carcinoma (OSCC). Thus the accurate pathological staging of the neck is critical. Desmoglein 3 (DSG3), a desmosomal cadherin protein is said to be highly expressed in head and neck squamous cell carcinoma (HNSCC) and in metastatic cervical lymph nodes, but absent in non-invaded nodes. With an aim to improve the sensitivity of tumour cell detection, we investigated the potential of DSG3 as an immunohistochemical marker for the detection of occult lymph node metastasis in patients with primary OSCC.

Material and methods: Forty-seven lymph node specimens from 10 patients who underwent neck dissection for primary OSCC were immunostained with DSG3.

Results: The DSG3 positivity was noted in the six positive lymph nodes. However, when using DSG3 as an immunohistochemical marker, no additional micrometastatic deposits were evident in the histologically negative nodes. Interestingly, tumour marker DSG3-positive macrophages could be identified within the subcapsular sinuses, medullary sinuses, and the interfollicular areas.

Conclusions: Our findings suggest that although DSG3 is overexpressed in HNSCC, it is not specific and may not prove to be a potent immunohistochemical marker to detect micrometastasis. The role of tumour marker-positive macrophages within the lymph nodes needs to be investigated further.

Key words: desmoglein 3, micrometastasis, M2 phenotype, tumour marker-positive macrophages.

Contemp Oncol (Pozn) 2016; 20 (5): 374–380
DOI: 10.5114/wo.2016.64596

Determining the potential of desmoglein 3 as a sensitive and specific immunohistochemical marker for the detection of micrometastasis in patients with primary oral squamous cell carcinoma

Shruti Nagvekar, Anita Spadigam, Anita Dhupar

Department of Oral and Maxillofacial Pathology, Goa Dental College and Hospital, Bambolim-Goa, India

Introduction

Head and neck squamous cell carcinoma (HNSCC) accounts for 6% of all cancer cases and ranks sixth with regards to cancer related deaths [1]. About 40–50% of the cases with advanced disease (stage III and IV) recur, and approximately 80% of recurrences occur within the first two years. One reason for the high mortality associated with late stage HNSCC is the inherent capability of tumour cells to undergo locoregional invasion due to the presence of a rich lymphatic network and the overall high number of lymph nodes in the neck region [2]. Thus early and accurate detection of metastatic disease is of paramount importance.

A good marker for the detection of lymph node metastasis should show marked variation in its expression in the positive and negative lymph nodes [3]. Cytokeratins have been widely used for the detection of nodal metastasis; however, variability in their expression has been observed [4].

Desmoglein 3 (DSG3) is a calcium-binding trans-membrane glycoprotein (130 kDa) component of desmosomes, which forms button-like points of intercellular contacts [5]. Desmosomal cadherins: desmogleins and desmocollins, mediate cell-cell adhesion by coupling to keratin intermediate filaments through the adaptor proteins plakoglobin, plakophilin, and desmoplakin [6]. Desmosomal proteins, including DSG3 serve as signalling centres. Over-expression of DSG2 or DSG3 has also been demonstrated in skin and head neck cancer. The importance of DSG3 as a novel molecular target for the early detection, prevention, and treatment of HNSCC was demonstrated in the higher expression of DSG3 in the proteomic analysis of HNSCC lesions by Patel *et al.* (2008) [7].

The correlation of DSG3 with regional lymph node metastasis may be explained on a cellular level by the role of DSG3 in the regulation of cell migration and invasion. Alteration in desmosome composition results in an alteration in signal transduction, resulting in increased transformation. There is supportive evidence showing that DSG3, as an up-stream regulator of Src activity, helps regulate adherens junction formation [8]. Moreover, overexpression of DSG3 results in the formation of filopodial protrusions and increased cell migration [9].

In 2013, Patel *et al.* identified DSG3, from amongst an array of other markers, to be a squamous-specific protein marker expressed specifically in the

positive lymph nodes and a potential marker for detecting micrometastatic deposits [7]. This study tested the potential of DSG3 for the detection of micrometastasis in the cervical lymph nodes of patients with primary HNSCC.

Material and methods

Patients and samples

Forty-seven archival formalin-fixed paraffin-embedded specimens from 10 patients who underwent ipsilateral lymph node dissection for OSCC from 2011 to 2014 were retrieved from the archives of the Department of Oral and Maxillofacial Pathology, Goa Dental College & Hospital, India. Data on gender, age, stage of disease, and histopathological factors was obtained from the medical records and was analysed.

Haematoxylin & eosin staining and re-evaluation

In order to confirm the diagnosis of the 47 archival tissue specimens, new sections were made for each selected tissue block using a Leica RM2125 RTS soft tissue rotary microtome. Section thickness was kept uniform at 3 µm. The slides were stained with standard Harris haematoxylin and 1% eosin Y staining protocol. The lymph node specimens were re-evaluated to check for the presence of metastatic deposits before the immunohistochemical analysis was performed. On evaluation, 41 out of 47 were confirmed to be negative whereas 6 were positive.

Immunohistochemistry

Forty-seven lymph node specimens along with one positive control (normal oral mucosa) and one negative control (normal oral mucosa not subjected to primary antibody) were subjected to immunohistochemical examination. Immunophenotypical analysis was performed by the standardised EnVision™ method employing 3-µm thick, formalin fixed, paraffin embedded sections using a commercially available mouse monoclonal antibody (Abcam Monoclonal Mouse Anti-Human Desmoglein 3 Antibody Clone ab14416 used at a concentration of 5 µg/ml) directed against the extracellular domain of DSG3. This antibody does not cross-react with desmoglein 1 or desmoglein-2 protein.

Heat-induced epitope retrieval was performed with the help of DAKO PTLINK™ using the '3 in 1 DAKO Target Retrieval Solution' (used at a dilution of 20×). The endogenous peroxidase activity was blocked by using the EnVision™ FLEX Peroxidase Blocking Reagent for 5 minutes. The primary antibody was then incubated for 30 minutes at room temperature after dilution in the DAKO EnVision™ FLEX Antibody Diluent (5 µg/ml), followed by a rinse with DAKO wash buffer solution. 100 µl of EnVision™ FLEX Horseradish Peroxidase (HRP) was then dispensed on each slide and incubated for 10 minutes, followed by a rinse with wash buffer. Finally, 100 µl of DAB chromogen (EnVision™ DAB-Dako Chromogen System) was applied to each section and incubated for 3–10 minutes. Samples were then rinsed with distilled water, counterstained with Mayer's haematoxylin, dehydrated, and mounted. Nega-

tive controls were prepared by substituting wash buffer solution for the primary antibodies.

Reading

Slides (H&E stain and DSG3 stain) were reviewed with light microscopy. The presence of immunoreactive cells, morphologically consistent with cancer cells within the substance of the lymph nodes were evaluated. The term "Micrometastasis" was used to refer to occult metastatic deposits within the lymph nodes, in which the tumour cell aggregate ranged in size between 0.2 mm and 2 mm, and "Isolated tumour cells" referred to tumour deposits < 0.2 mm.

Statistical analysis

Comparison of findings on routine histological and those on immunohistochemical examination was done using McNemar's test. To validate the data, correlation between the incidence of metastasis and the size and level of lymph nodes was confirmed using Fisher's exact χ^2 test (level of validity was determined as $p < 0.05$).

Results

Clinical

The gender distribution was six males and four females (Table 1). The age of patients at the time of surgery ranged from 44 to 73 years, and mean age was found to be 60.10 years. Patients most frequently presented with a lesion in the buccal vestibule.

Pathological features

The size of the primary tumour ranged from 0.5 cm to 6 cm in maximum dimension, with a mean of 3.75 cm and standard deviation of 1.84. Among the 10 cases of OSCC evaluated, seven were of well differentiated type, two cases were of moderately differentiated type, and one case was of poorly differentiated type. Of the total 47 lymph nodes studied on routine histopathology, 41 were negative whereas 6 were positive for metastasis (Figs. 1 and 2). Two of the total 6 cases of metastases occurred in the nodes 20 to 25 mm in size and two in > 25 mm sized lymph nodes.

The relation between metastasis with the size of lymph nodes was evaluated using Fisher's exact χ^2 test (Table 2). A statistically significant difference ($p = 0.003$) in the incidence rate of metastasis due to the size of lymph node was noted in comparison with different sized lymph nodes. In analysing the level of the lymph nodes with metastasis, it was found that two of the total six cases of metastasis occurred in level IB lymph nodes. Fisher's exact χ^2 test showed a statistically significant difference ($p = 0.006$) in the incidence rate of metastasis with the level of the lymph nodes (Table 3). Although a statistical-

Table 1. Gender demographics of OSCC patients

Gender	Frequency	Percentage (%)
Males	6	60.0
Females	4	40.0

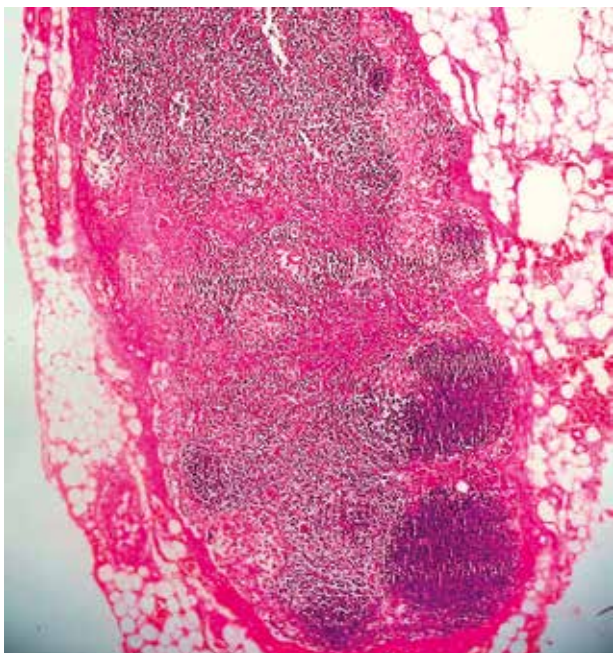


Fig. 1. Haematoxylin and eosin-stained section of a negative lymph node specimen (H&E, original magnification 40×)

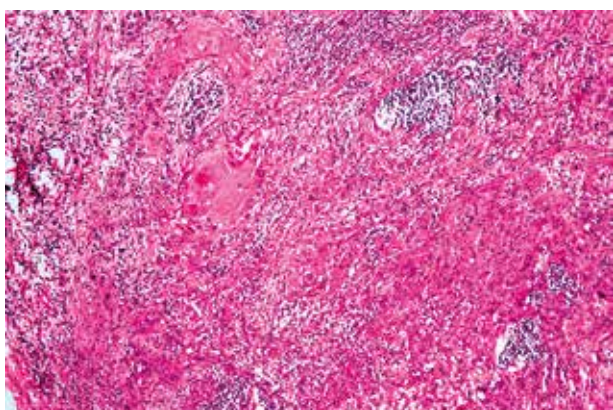


Fig. 2. Haematoxylin and eosin-stained section of a positive lymph node specimen demonstrating tumour deposits (H&E, original magnification 100×)

ly significant difference was observed between the incidence of metastasis and the size and level of lymph nodes, an accurate interpretation of the results would be based on evaluation of a large number of lymph nodes.

A well-defined intercellular staining pattern was observed in the positive control (oral mucosa) (Fig. 3). DSG3 positivity was noted in the metastatic deposits, and no additional micrometastatic deposits could be detected in the histologically proven negative nodes. The data was analysed using McNemar's test and was found to be statistically non-significant ($p = 1.000$). These results are summarised in Table 4.

There was difficulty in identifying additional micrometastatic deposits due to the presence of a substantial number of activated macrophages that exhibited DSG3 immunoreactivity. The DSG3+ macrophages were found in the subcapsular sinuses, interfollicular areas, medullary sinuses, as well as in the lymphoid follicles. To confirm whether the DSG3+ cells were indeed macrophages and to evaluate its polarisation, the specimens were then subjected to the following markers: CD68 (pan macrophage marker) and CD163 (marker for M2 phenotype). The DSG3+ cells were CD68+, thus confirming the macrophage phenotype of the cells. However, a subset of the group were CD163+, confirming the M2 polarisation of the macrophages (Figs. 4–6).

Discussion

The five-year survival rate of patients largely depends on the tumour stage at the time of diagnosis, decreasing from 50% in patients without the presence of lymph node metastasis to 90% with nodal metastasis [10–12]. Approximately 30% of patients with OSCC, who present without any clinical or radiographic evidence of regional disease, in fact harbour occult cervical metastasis, which is detected microscopically – divided into three types: macrometastases (> 2–3 mm in the largest dimension), micrometastases (< 2–3 mm in the largest dimension), and isolated tumour cells (individual or small clusters of tumour cells within the lymph node sinuses < 0.2 mm). The size and type of metastasis may influence the prognostic value of nodal metastases [12, 13]. Thus detection of tumour deposits within the lymph nodes is critical for patient care.

Immunohistochemistry serves as a reasonably good cost-effective alternative over PCR immunoarrays in the detection of occult lymph node metastasis. Although cytokeratins have been consistently used as immunohistochemical markers for detection of nodal metastases, they are not very specific. Reticulum cells, ectopic salivary gland inclusions, mesothelial inclusions, and metastatic thyroid follicles can show cytokeratin positivity [12, 14]. Several studies have also found inconsistencies in the precise cytokeratin to be analysed [7].

Table 2. Distribution of metastasis with the size of lymph nodes

Size (mm)	Number of nodes	Number of positive nodes (H&E)	Percentage of metastasis	Fisher's exact χ^2 test
0–5	3	0	0	$p = 0.003$
5–10	18	0	0	
10–15	17	1	5.9	
15–20	3	1	33.3	
20–25	2	2	100	
> 25	4	2	50	

Table 3. Distribution of metastasis with the level of lymph nodes

Valid	Frequency	Percentage	Valid Percentage	Number of positive nodes (H&E)	Percentage	Fisher's exact χ^2 test
I A	6	12.8	12.8	1	16.7	$p = 0.006$
I B	2	4.3	4.3	2	100	
II A	9	19.1	19.1	1	11.1	
II B	11	23.4	23.4	0	0	
III	17	36.2	36.2	1	5.9	
IV	2	4.3	4.3	1	50	
Total	47	100.0	100.0	6	12.8	

Table 4. Comparison of findings on routine histological examination and those on immunohistochemical evaluation

Method		Detection		Total	McNemar's test
		Negative	Positive		
IHC	Count	41	6	47	$p = 1.000$
	% within method	100%	100.0%		
	% of total	87.2%	12.8%		
H&E	Count	41	6	47	
	% within method	100%	100.0%		
	% of total	87.2%	12.8%		

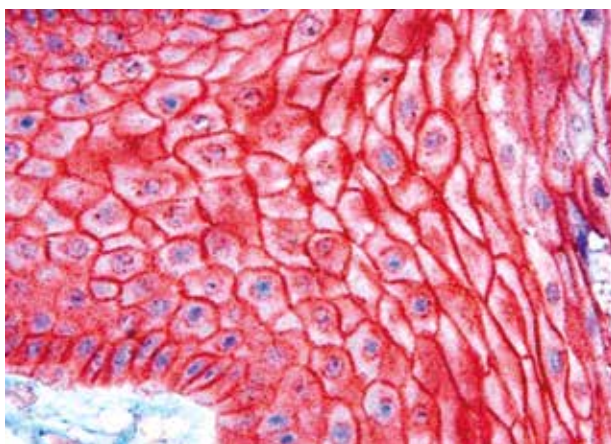


Fig. 3. Positive control: Stratified squamous epithelium of the oral mucosa: DSG3 positivity seen in the intercellular junctions (DSG3, original magnification 400 \times)

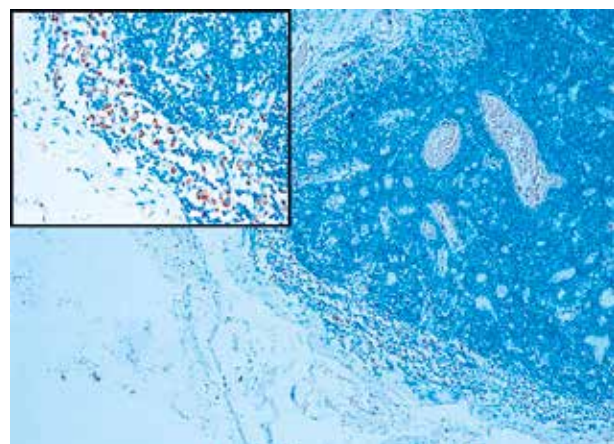


Fig. 4. Photomicrograph revealing CD68 positive cells within the subcapsular sinus indicative of macrophages (CD68, original magnification 100 \times). (Inset: 400 \times)

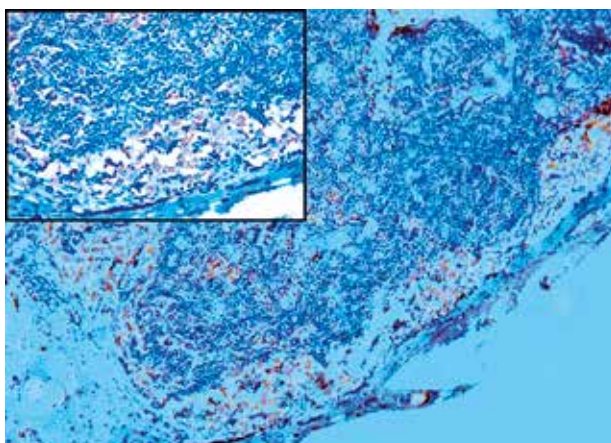


Fig. 5. Photomicrograph revealing DGS3 positive macrophages within the lymph nodes (DSG3, original magnification 100 \times). (Inset: 400 \times)

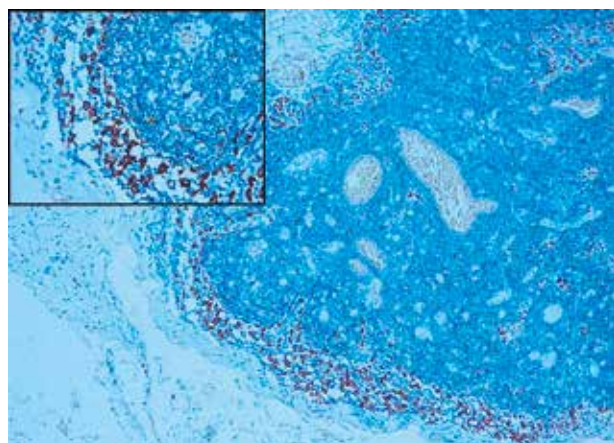


Fig. 6. Photomicrograph revealing CD163 positive macrophages within the lymph nodes (CD163, original magnification 100 \times) (Inset: 400 \times)

Chen *et al.* surveyed and identified several cancer-associated genes using differential display and showed that DSG3 is overexpressed in head and neck cancer, with the degree of overexpression associated with the clinic-pathologic features of the tumour [5].

Several other studies have shown that DSG3 is a squamous specific marker and highly expressed in head and neck carcinoma [6, 15–17]. Thus in a quest to find a single specific and sensitive marker and thus to enhance the detection of micrometastatic disease, we investigated the potential of DSG3 as a marker for the detection of occult metastasis.

In the current study, we could not detect any additional micrometastatic deposits in the 41 histologically evaluated negative nodes. Using cytokeratins as markers of micrometastasis detection in HNSCC cases, various authors have shown that the detection rate varies from 1.3% to 68% [4, 12, 18]. Patel *et al.* [7] evaluated formalin-fixed, paraffin-embedded, anonymised tissue sections of non-metastatic (N0) and metastatic (N+) human cervical lymph node biopsies from patients diagnosed with HNSCC for expression of DSG3 and cytokeratin. Positive lymph nodes ($n = 30$) stained positive for CK+ and DSG3+ whereas negative lymph nodes ($n = 5$) were CK– and DSG3–. They then tested the usefulness of DSG3 to be used as a sensitive marker using the microfluidic immunoarray system. Protein extracts of normal and positive metastatic lymph nodes were used for the same. The negative lymph nodes showed marginal values for DSG3, which was attributed to nonspecific binding, whereas all of the positive, metastatic lymph nodes showed high levels of DSG3 protein expression [7].

This is the only study conducted in subsequence of the study presented by Patel *et al.* evaluating the efficacy of DSG3 as a marker for the detection of micrometastasis in cervical lymph nodes. In contrast to their study, we did not detect any occult metastatic deposits with IHC. Interestingly, a substantial number of activated macrophages showing positivity for DSG3 could be identified within the subcapsular sinuses, interfollicular areas, and medullary sinuses as well as in the lymphoid follicles and exhibited characteristic granular to diffuse cytoplasmic staining patterns. The study of Patel *et al.* [7] did not report this finding. The presence of the DSG3+ cells posed diagnostic difficulty in differentiating the isolated tumour cell deposits from the activated macrophages, thus reducing the specificity of the marker. However, DSG3 characteristically highlighted the macro-metastatic deposits. To further confirm the phenotype of the DSG3+ cells within the histologically negative lymph nodes, the tissue sections were subjected to CD68 and CD163 antibodies/markers. It was seen that these DSG3+ macrophages were CD68+ (confirming the macrophage phenotype), and a subset of these macrophages showed CD163+ positivity (M2 polarisation).

Macrophages are pivotal members of the inflammatory infiltrate and respond to the microenvironment signals [19]. Evidence suggests that macrophages support tumour-associated angiogenesis, promote tumour cell invasion, facilitate tumour metastasis, and suppress anti-tumour immune responses [20]. Recent studies have

further strengthened the idea that through interaction between tumour cells and macrophages, macrophages undergo a process of “education” within the tumour microenvironment [19]. As such they can be polarised into two functionally distinct states: Classically activated (M1) state, which possesses anti-tumour activity; and the alternatively activated (M2) state, which promotes tumour invasion and metastasis [21]. Most tumour associated macrophages (TAMs) are M2 type, which are recognised by CD163 positivity immunohistochemically. CD68 is used as a pan-macrophage marker [21].

Owing to the compromised phagocytic activity, the M2 macrophages contribute to the phenomenon of immune evasion of the tumour cells invading the lymph nodes. Oberg *et al.* (2002) showed that poor patient survival correlates with the number of M2 macrophages [22].

Wehrhan *et al.*, on evaluation of the macrophage polarisation in patients with OSCC, observed that the lymph vessel infiltration at the primary site was associated with M2 polarisation of the macrophages in the regional lymph nodes. These M2 macrophages were thought to contribute to the peripheral immune tolerance [22].

Various other studies on malignant melanoma, colon carcinoma, and prostate carcinoma have demonstrated the presence of tumour marker-positive macrophages in the regional lymph nodes [23, 24]. Japink *et al.* postulated that the activated macrophages are attracted to the tumour stroma and find themselves in close proximity to the damaged tissue. This tumour antigen is then engulfed and concentrated within the TAMs [25]. Direct communication between macrophages and tumour cells is said to prepare the regional lymph nodes for the acceptance and sustenance of metastases [22, 26].

Faber *et al.*, from the assessment of regional lymph nodes from patients with primary colon carcinoma, concluded that tumour marker-containing macrophages travel via the lymphatic system towards the regional lymph nodes [24]. They also found substantial differences between the expression of the various tested tumour markers (CEA showing the greatest expression in comparison to M30 and cytokeratin). They attributed the variable expression of the markers to the following:

The stability of the tested substance. CEA, being an extremely stable molecule, can survive adverse processing conditions, whereas cytokeratins are easily damaged by electrical or chemical agents.

There could be a relation between the presence and the distribution of the investigated substances in the tumour and the possibility of finding loaded macrophages [24].

Desmosomes are highly insoluble structures and can withstand harsh denaturing conditions, thus having a higher probability of being detected within the TAMs [27–29]. Also, the substances a macrophage encounters may depend on the macrophage and its location. The differences described above may explain why not all macrophages of the lymph nodes contain the same substance/antigen and also not the same amount [7, 24, 30].

Pawelek postulated that the fusion of tumour cells with bone marrow-derived cells as a possible explanation for tumour progression and metastasis. Such hybrid cells

have been identified *in vitro* and in sporadic cases *in vivo* [31]. They proposed a simple model to explain a unifying concept of metastasis: “White blood cell + Cancer cell = Cancer cell with metastatic potential” [31].

In one of the first experiments, Pawelek experimentally fused normal mouse or human macrophages with mouse Cloudman S91 melanoma cells that had weak metastatic potential. They observed that the hybrid clones showed markedly enhanced chemotactic motility, and when implanted in mice, these hybrids showed elevated metastatic potential compared to the implanted parental Cloudman S91 melanoma cells [31].

Desmoglein 3 and CD68 positivity within the macrophages might lead us to believe that these cells could represent tumour cell-macrophage hybrid models.

In conclusion, the present study concludes that DSG3 cannot be used as a single and specific immunohistochemical marker for the detection of micrometastasis and may not prove to be a better marker than cytokeratins. DSG3 stains macrophages and does not appear to provide a confident interpretation of metastasis where isolated positive cells or micrometastatic deposits are involved.

However, the most interesting finding of the study was the presence of the tumour marker positive macrophages. Although the concept of tumour marker-positive macrophages has not been studied or investigated in HNSCC, there have been studies done in colon carcinoma, breast cancer, and malignant melanoma cases. The significance of their detection is still under research.

We propose the following theories to explain the presence of tumour marker-positive macrophages within regional lymph nodes. Firstly, it could be that the macrophages have engulfed the tumour antigen and migrated towards the lymph nodes. This could be related to creating an environment conducive for the acceptance of tumour deposits. Desmogleins, being stable structures in comparison to cytokeratins, are better preserved following staining procedures, thus increasing the possibility of their detection within the macrophages. Secondly, the tumour marker-positive macrophages could be a form of tumour cell-macrophage hybrid.

Further investigation into the role of the tumour marker-positive macrophages (especially the M2 polarised type) within the lymph nodes, could help to better devise molecular therapies targeted at restricting the spread of tumour cells at an earlier stage.

The authors declare no conflict of interest.

References

1. Sharma M, Madan M, Manjari M, Bhasin TS, Jain S, Garg S. Prevalence of head and neck squamous cell carcinoma (HNSCC) in our population: The clinico-pathological and morphological description of 198 cases. *IJAR* 2015; 3: 827-33.
2. Polanska H, Raudenska M, Gumulec J, Sztalmachova M, Adam V, Kizek R, Masarik M. Clinical significance of head and neck squamous cell cancer biomarkers. *Oral Oncol* 2014; 50: 168-77.
3. Kim KY, Lee GY, Cha IH. Biomarker detection for the diagnosis of lymph node metastasis from oral squamous cell carcinoma. *Oral Oncol* 2012; 48: 311-9.
4. Thomas J, Jose M. Immunohistochemistry over routine histopathology to trace micrometastasis in lymph nodes in patients with oral squamous cell carcinomas. *Health Sciences* 2013; 4: JS004B.
5. Chen YJ, Chang JT, Lee L, Wang HM, Liao CT, Chiu CC, Chen PJ, Cheng AJ. DSG3 is overexpressed in head neck cancer and is a potential molecular target for inhibition of oncogenesis. *Oncogene* 2007; 26: 467-76.
6. Cirillo N, Boutros S. Fate of desmoglein 3 and E-cadherin in anchorage independent growth and adhesion to substrates of oral squamous carcinoma cells. *J Stomatol Invest* 2008; 2: 41-51.
7. Patel V, Martin D, Malhotra R, et al. DSG3 as a biomarker for the ultrasensitive detection of occult lymph node metastasis in oral cancer using nano-structured immunoarrays. *Oral Oncol* 2013; 49: 93-101.
8. Tsang SM, Liu L, Teh MT, et al. Desmoglein 3, via an interaction with E-cadherin, is associated with activation of Src. *PLoS One* 2010; 5: e14211.
9. Tsang SM, Brown L, Gadmor H, Gammon L, Fortune F, Wheeler A, Wan H. Desmoglein 3 acting as an upstream regulator of Rho GTPases, Rac-1/Cdc42 in the regulation of actin organisation and dynamics. *Exp Cell Res* 2012; 318: 2269-83.
10. Pathology Reporting Of Breast Disease: A Joint Document Incorporating the Third Edition of the NHS Breast Screening Programme's Guidelines for Pathology Reporting in Breast Cancer Screening and the Second Edition of The Royal College of Pathologists' Minimum Dataset for Breast Cancer Histopathology. Public Health England – NHSBSP Publication No 58 January 2005.
11. Schaaïj-Visser TB, Brakenhoff RH, Leemans CR, Heck AJ, Slijper M. Protein biomarker discovery for head and neck cancer. *J Proteomics* 2010; 73: 1790-803.
12. Thakare E, Gawande M, Chaudhary M, Seralathan M, Kannan K. Detection of micrometastasis in lymph nodes of oral squamous cell carcinoma: A comparative study. *J Oral Maxillofac Pathol* 2013; 17: 374-80.
13. Moore KH, Thaler HT, Tan LK, Borgen PI, Cody HS 3rd. Immunohistochemically detected tumor cells in the sentinel lymph nodes of patients with breast carcinoma. biologic metastasis or procedural artifact? *Cancer* 2004; 100: 929-34.
14. Kwon SY, Kim HJ, Woo JS, Jung KY, Kim I. The usefulness of cytokeratin immunohistochemistry in detection of lymph node micrometastasis in neck dissection specimens. *Otolaryngol Head Neck Surg* 2004; 131: 300-6.
15. Donetti E, Gualerzi A, Bedoni M, Volpari T, Sciarabba M, Tartaglia G, Sforza C. Desmoglein 3 and keratin 10 expressions are reduced by chronic exposure to cigarette smoke in human keratinised oral mucosa explants. *Arch Oral Biol* 2010; 55: 815-23.
16. Fang WK, Gu W, Liao LD, et al. Prognostic significance of desmoglein 2 and desmoglein 3 in esophageal squamous cell carcinoma. *Asian Pac J Cancer Prev* 2014; 15: 871-6.
17. Wang L, Liu T, Wang Y, et al. Altered expression of desmocollin 3, desmoglein 3, and beta-catenin in oral squamous cell carcinoma: correlation with lymph node metastasis and cell proliferation. *Virchows Arch* 2007; 451: 959-66.
18. Akhtar S, Ikram M, Ghaffar S. Neck involvement in early carcinoma of tongue. Is elective neck dissection warranted? *J Pak Med Assoc* 2007; 57: 305-7.
19. Yang M, Shao JH, Miao YJ, Cui W, Qi YF, Han JH, Lin X, Du J. Tumor cell-activated CARD9 signaling contributes to metastasis-associated macrophage polarization. *Cell Death Differ* 2014; 21: 1290-302.
20. Shih JY, Yuan A, Chen JJW, Yang PC. Tumor-associated macrophage: its role in cancer invasion and metastasis. *J Cancer Mol* 2006; 2: 101-6.
21. He KF, Zhang L, Huang CF, et al. CD163+ tumor-associated macrophages correlated with poor prognosis and cancer stem cells in oral squamous cell carcinoma. *Biomed Res Int* 2014; 2014: 838632.
22. Wehrhan F, Büttner-Herold M, Hyckel P, et al. Increased malignancy of oral squamous cell carcinomas (OSCC) is associated with mac-

- rophage polarization in regional lymph nodes – an immunohistochemical study. *BMC Cancer* 2014; 14: 522.
23. Leers MP, Nap M, Herwig R, Delaere K, Nauwelaers F. Circulating PSA-containing macrophages as a possible target for the detection of prostate cancer: a three-color/five-parameter flow cytometric study on peripheral blood samples. *Am J Clin Pathol* 2008; 129: 649-56.
 24. Faber TJ, Japink D, Leers MP, Sosef MN, von Meyenfeldt MF, Nap M. Activated macrophages containing tumor marker in colon carcinoma: immunohistochemical proof of a concept. *Tumor Biol* 2012; 33: 435-41.
 25. Japink D, Leers MP, Sosef MN, Nap M. CEA in activated macrophages. New diagnostic possibilities for tumor markers in early colorectal cancer. *Anticancer Res* 2009; 29: 3245-51.
 26. Condeelis J, Pollard JW. Macrophages: obligate partners for tumor cell migration, invasion, and metastasis. *Cell* 2006; 124: 263-6.
 27. Skerrow CJ, Matoltsy AG. Isolation of epidermal desmosomes. *J Cell Biol* 1974; 63: 515-23.
 28. Gorbisky G, Steinberg MS. Isolation of the intercellular glycoproteins of desmosomes. *J Cell Biol* 1981; 90: 243-8.
 29. Jones SM, Jones JCR, Goldman RD. Fractionation of desmosomes and comparison of the polypeptide composition of desmosomes prepared from two bovine epithelial tissues. *J Cell Biochem* 1988; 36: 223-36.
 30. Kowalczyk AP, Bornslaeger EA, Borgwardt JE, Palka HL, Dhaliwal AS, Corcoran CM, Denning MF, Green KJ. The amino-terminal domain of desmoplakin binds to plakoglobin and clusters desmosomal cadherin-plakoglobin complexes. *J Cell Biol* 1997; 139: 773-84.
 31. Pawelek JM. Fusion of bone marrow-derived cells with cancer cells: metastasis as a secondary disease in cancer. *Chin J Cancer* 2014; 33: 133-9.

Address for correspondence**Shruti Nagvekar**

Department of Oral and Maxillofacial Pathology
Goa Dental College and Hospital
Bambolim-Goa, India
e-mail: shrutinagvekar123@gmail.com

Submitted: 23.02.2016

Accepted: 22.06.2016