




Since January 2020 Elsevier has created a COVID-19 resource centre with free information in English and Mandarin on the novel coronavirus COVID-19. The COVID-19 resource centre is hosted on Elsevier Connect, the company's public news and information website.

Elsevier hereby grants permission to make all its COVID-19-related research that is available on the COVID-19 resource centre - including this research content - immediately available in PubMed Central and other publicly funded repositories, such as the WHO COVID database with rights for unrestricted research re-use and analyses in any form or by any means with acknowledgement of the original source. These permissions are granted for free by Elsevier for as long as the COVID-19 resource centre remains active.



## Case Report

## Multisystem inflammatory syndrome following COVID-19 infection mimicking abdominal tuberculosis in Nepal: A case report

Preeti Basnet<sup>a</sup>, Anish Joshi<sup>a</sup>, Surakshya Baral<sup>b,\*</sup>, Saurab Karki<sup>c</sup>, Grishma Sharma<sup>a</sup>, Suhail Sapkota<sup>d</sup>

<sup>a</sup> Kathmandu University School of Medical Sciences, Dhulikhel, Nepal

<sup>b</sup> Manipal College of Medical Sciences, Pokhara, Nepal

<sup>c</sup> Military Hospital Itahari, Sunsari, Nepal

<sup>d</sup> Nepal Cardio Diabetes and Thyroid Center, Kathmandu, Nepal

## ARTICLE INFO

## Keywords:

Abdominal tuberculosis

COVID

Multisystem inflammatory syndrome

## ABSTRACT

**Introduction and importance:** Multisystem Inflammatory Syndrome in Children (MIS-C) is an uncommon condition that can present with a wide range of clinical features and complications. As it can be confused with various diseases, diagnosis is crucial as proper management can improve the patient's condition.

**Case presentation:** 14-year male presented with fever, abdominal pain, and cough on September 2021. On examination, he was febrile with a distended abdomen and enlarged liver. Following investigations, abdominal tuberculosis was suspected but his condition improved with broad-spectrum antibiotics, intravenous immunoglobulins, and high-dose steroids.

**Clinical discussion:** Any children with COVID 19 infection who have fever with multiple systems involved after ruling out other causes of infections should be suspected to have MIS-C. Diagnosis can be challenging as its clinical presentation mimics conditions like Kawasaki disease, rickettsial disease and acute appendicitis, etc. In high prevalence countries, with predominant gastrointestinal features, it can be confused with abdominal tuberculosis as well, hence, proper diagnosis is crucial.

**Conclusion:** The course of MIS-C can be fatal where most children require intensive care units and early institution of immunomodulatory therapy for their recovery. Also, all pediatricians need to have a high degree of suspicion to diagnose MIS-C as it can be confused with different illnesses.

### 1. Introduction

In April 2020, Riphagen et al. first described Multisystem Inflammatory Syndrome in Children (MIS-C) as a new and serious clinical disorder [1]. Out of all affected children with COVID-19, 45% remain asymptomatic [2] and MIS-C, an uncommon condition, affects just 0.6% of SARS COV-2 infected symptomatic patients under the age of 21 [3]. As per Taffarel et al., among detected cases, eight children with COVID-19 had multi-organ involvement, circulatory shock, and systemic inflammation in May 2020 [4]. Fever and other clinical indicators such as rash, conjunctivitis, hands and feet edema, red and/or chapped lips, "strawberry" tongue, myocardial dysfunction, aberrant cardiac conduction, shock, gastrointestinal symptoms, lymphadenopathy, and neurological alterations are common clinical hallmarks of MIS-C [1].

Herein, we report a case of a 14-year-old male who presented with

the potentially fatal disease, MIS-C but the initial differential of the management team was towards abdominal tuberculosis. This study shows that MIS-C can be confused with a variety of diseases and hence diagnosis is crucial as proper management can improve a patient's condition. It also outlines the definition of a case of MIS-C. The case has been reported in line with the SCARE 2020 criteria [5].

### 2. Case

A 14 years male presented to the pediatric OPD on September 2021, with complaints of fever for 4 days, abdominal pain for 3 days, and cough for 1 day. Fever was acute in onset, with a maximum temperature documented of 103F, associated with chills and sweating but no rigors. Fever was associated with abdominal pain for 3 days in the periumbilical region which was severe enough to affect his daily activities, aggravated

\* Corresponding author. Manipal College of Medical Sciences, Pokhara, Nepal.

E-mail address: [Brl.surak014@gmail.com](mailto:Brl.surak014@gmail.com) (S. Baral).

<https://doi.org/10.1016/j.amsu.2022.104919>

Received 18 August 2022; Received in revised form 25 October 2022; Accepted 12 November 2022

Available online 15 November 2022

2049-0801/© 2022 The Authors. Published by Elsevier Ltd on behalf of IJS Publishing Group Ltd. This is an open access article under the CC BY-NC-ND license (<http://creativecommons.org/licenses/by-nc-nd/4.0/>).

with movement, and relieved on rest.

The patient also complains of coughing multiple episodes for one day which was dry in nature and associated with fast breathing. However, there was no history of noisy breathing, chest indrawing, or bluish discoloration of skin while coughing. He had no recent travel or known sick contacts. He was not on any medications for chronic illness and had no known allergies to drugs, dust, and food.

On presentation, the child appeared ill. He was thinly built (weight <3rd centile). He was febrile, tachypneic (respiratory rate-42 breaths/min) with hypotension (blood pressure 90/48 (61) mm Hg) and oxygen saturation maintained with 2L O<sub>2</sub> per minute. Right inguinal lymph nodes were enlarged (1.5 cm) and non-tender. The abdomen was soft and distended with liver palpable 3 cm below the right subcostal margin. Liver span was 12 cm. Fluid thrill was present. There was no splenomegaly. On auscultation of the chest, there was decreased air entry on the right mammary area. No abnormalities were detected on examination of other systems.

A complete blood panel revealed neutrophilia and lymphopenia with thrombocytopenia. The liver function test was deranged with elevated liver enzymes and low serum albumin. (ALT and AST-104 IU/L and 153IU/L, ALP-173U/L, TSB/DSB-2mg/dL and 0.5mg/dL, GGT-90IU/L, total protein -5.4g/dL, serum albumin - 2.5g/dL). The renal function test was normal. Arterial blood gas analysis showed pH:7.43, Pco<sub>2</sub>- 27, Po<sub>2</sub>-135, and HCO<sub>3</sub>-20. Routine examination of urine showed a significant number of pus cells; however, urine culture revealed no growth. The patient tested negative for scrub typhus. Chest X-ray demonstrated subtle diffuse coalescent opacities in bilateral lungs with a decrease in 4–7th intercostal space on the left side suggestive of volume loss as shown in Fig. 1. Ultrasound of the abdomen revealed gross ascites and minimal pleural effusion. Echocardiography suggested minimal pericardial effusion with mild tricuspid regurgitation and mitral regurgitation. Ascitic fluid analysis showed elevated white blood cell count with lymphocytosis and high ADA. (TC-300/mm<sup>3</sup>, N-2%, L-98%, glucose-92mg/dL, protein 4g/dL, ADA-54U/L, LDH-1080IU/L, gram stain - no organism isolated). Ascitic fluid culture and sensitivity showed no growth. Peripheral blood smear showed normal findings. On admission, the troponin marker tested negative and the CK-MB value was 18IU/L.

With this presentation, the patient was then admitted to the pediatric ICU for further management. He was initially treated with intravenous antibiotics (Ceftriaxone and metronidazole). Intravenous fluids along with vasopressors (dobutamine and dopamine at the rate of 12 mcg/kg/min) were used to correct low blood pressure. The patient was also administered albumin given low albumin levels. CT scan of bilateral lung fields demonstrated subpleural reticular opacities (white arrow) and ground glass opacity (blue arrow) (in the left) while abdominal CT

scan showed grossly normal findings with mild hepatomegaly (right) as shown in Fig. 2. The patient tested positive for Covid-antibody following which intravenous immunoglobulin (IVIg) and a high dose of methylprednisolone were started for suspected MIS-C.

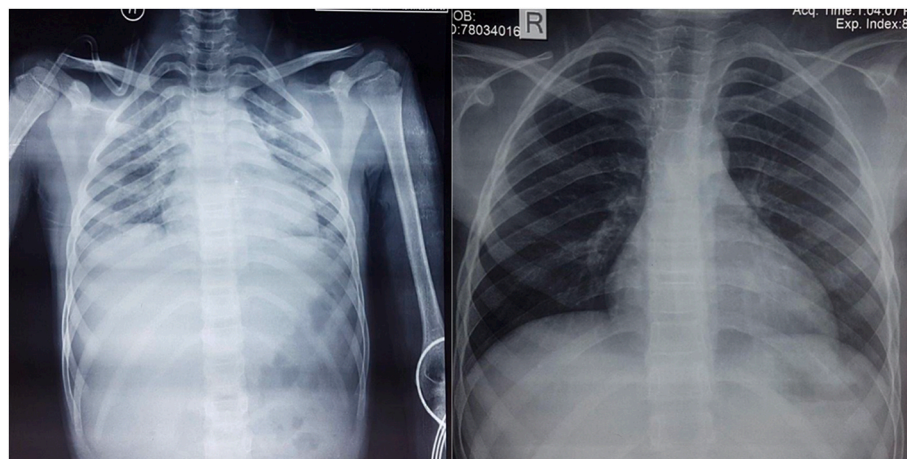
On the second day of admission, diuretics and low molecular weight heparin was added. The patient was kept on BIPAP for respiratory support. Intravenous antibiotics were upgraded to clindamycin and piperacillin-tazobactam on the fourth day of admission. On the fifth day of admission, the troponin marker was tested positive and the CK-MB value was 26 IU/L. After starting IVIg and a high dose of methylprednisolone along with intravenous broad-spectrum antibiotics his condition gradually improved and inotropes were tapered gradually and oxygen was weaned off. On the eighth day of admission, the child was afebrile and oxygen saturation was maintained with oxygen at 3 L per minute. Low molecular heparin and intravenous diuretics were stopped and the patient was kept on oral rivaroxaban and diuretics on the same day. Feeding was also initiated. On the 13th day of admission, he was shifted to the pediatric ward and oxygen saturation was maintained in room air. Repeat echocardiography showed dilated and fixed IVC (1.5 cm), dilated left ventricle, no diastolic dysfunction, minimum pericardial effusion, coronary artery diameter - 3mm, and ejection fraction of 65%. Repeat complete blood panel showed an improvement in the platelet count. On discharge (14th day of admission), the child was afebrile, feeding well, and clinically stable. The child was discharged with oral antibiotics, steroids, anticoagulants, diuretics, and multivitamins. The child was followed up in the pediatric OPD after 2 weeks and was doing fine and his chest x-ray on 8 weeks was normal as shown in Fig. 1.

### 3. Discussion

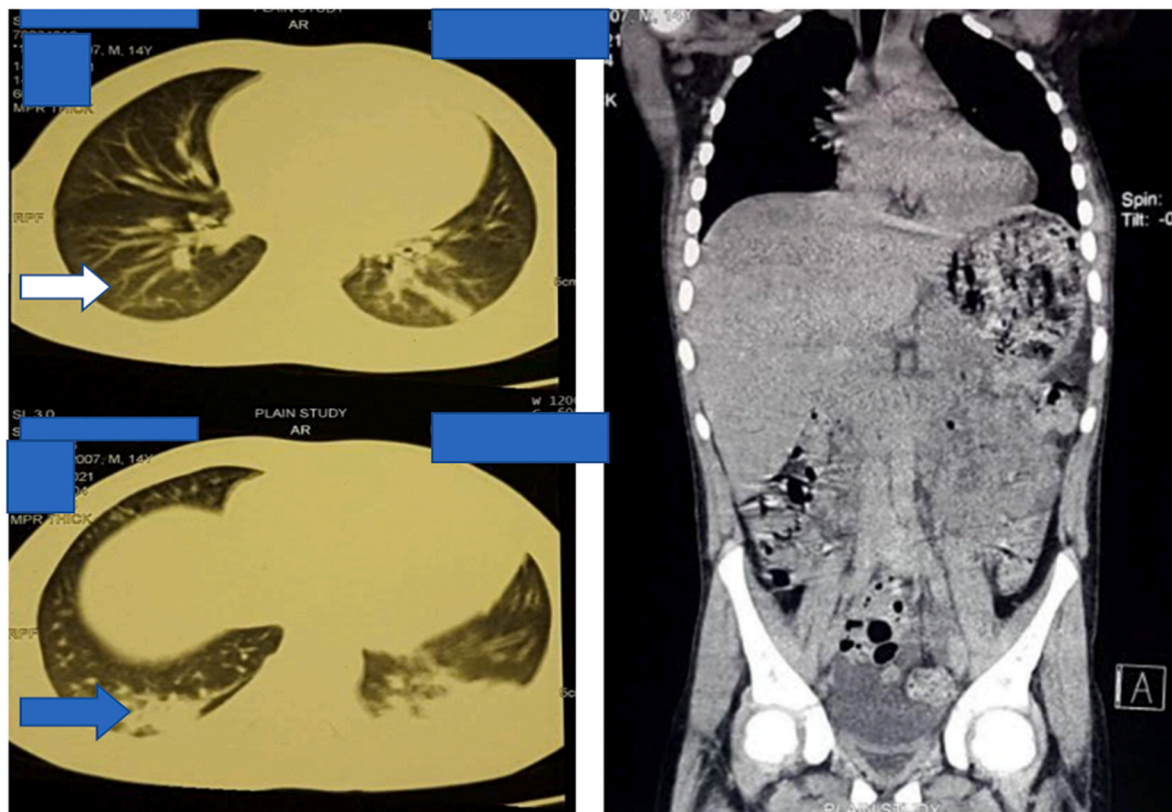
The Centers for Disease Control and Prevention (CDC) issued a Health Alert Network advisory for multisystem inflammatory syndrome in children (MIS-C) related to Covid-19 on May 14, 2020. New York State Department of Health (NYSDOH) also released an interim case definition on May 13, 2020 (6) according to which, the preliminary case definition is children and adolescents of age 0–19 years with fever for ≥3 days.

#### 3.1. And two of the following features

1. Presence of rash or mucocutaneous inflammation signs (oral, hands, or feet) or bilateral non-purulent conjunctivitis.
2. Hypotension or shock.



**Fig. 1.** Initial chest x-ray- Subtle diffuse coalescent opacities in bilateral lung field with a decrease in 4–7th intercostal space in the left side suggestive of volume loss. Subsequent follow-up chest x-ray 8 weeks later was normal as shown on the right side.



**Fig. 2.** CT scan of bilateral lung fields showing sub-pleural reticular opacities (white arrow) and ground glass opacity (blue arrow) (in the left) while abdominal CT scan showed grossly normal findings with mild hepatomegaly (right). (For interpretation of the references to color in this figure legend, the reader is referred to the Web version of this article.)

3. Features of myocardial dysfunction, valvulitis, pericarditis, or coronary abnormalities (including abnormal ECHO findings or elevated levels of Troponin/NT-proBNP),
4. Indication of coagulopathy (deranged PT, PTT, or elevated d-Dimers).
5. Acute gastrointestinal symptoms (vomiting, diarrhea, or abdominal pain).

#### 4. AND

Elevated levels of inflammatory markers like ESR, CRP, or procalcitonin.

#### 5. AND

Other likely microbial reasons for inflammation (including streptococcal or staphylococcal shock syndromes, bacterial sepsis ruled out).

#### 6. AND

Documentation of COVID-19 infection (antigen test, RT-PCR, or positive serology), or possible contact with patients with COVID-19 [6].

MIS-C is often confused with some sort of illness. It can present with gastrointestinal symptoms (abdominal pain, nausea, vomiting, and diarrhea) [7]. Symptoms of acute appendicitis like right lower quadrant pain, fever, nausea, emesis, anorexia, and radiographic evidence of appendicitis, may be the manifestation in patients with MIS-C [8]. The most prevalent juvenile vasculitis, Kawasaki disease (KD), may appear as the clinical symptoms [9]. The syndrome of fever with rash/thrombocytopenia, which can be caused by dengue fever, rickettsial, meningococcal infection, malaria, leptospirosis, and viral exanthems, calls for consideration of MIS-C [10]. Pediatricians should be aware of

such unusual pediatric presentations to start immunomodulatory therapy early [9].

Children's tuberculosis accounts for up to 10% of all tuberculosis cases worldwide. Around 5.5% of cases of overall tuberculosis cases in Nepal are children [11]. Also, abdominal tuberculosis comprises 0.3% of pediatric tuberculosis cases and is not a common presentation of tuberculosis [12]. The most common symptoms of abdominal tuberculosis are pain abdomen, and weight loss followed by fever [13].

As for the analysis of ascitic fluid in abdominal tuberculosis, the peritoneal fluid is exudative and is either clear or straw-colored. The fluid analysis reveals serum albumin ascitic gradient (SAAG) level less than 1.1 g/dL, proteins greater than 3 g/dL, cells greater than 1000/cumm (mainly lymphocytes), ascitic/blood glucose ratio less than 0.96, and cells greater than 1000/cumm. A potential screening procedure for kids with ATB has been thought to be the presence of ADA in the ascitic fluid. With a positive predictive value of 93%, a level greater than 33U/L has a sensitivity and specificity of 93% and 96%, respectively [13]. In our case as well, as Nepal is a tuberculosis endemic region and the child had presented with weight loss with exudative peritoneal fluid along with raised ADA levels, abdominal tuberculosis was suspected initially. However, as the child improved with broad-spectrum antibiotics, IVIg, and high-dose steroids, diagnosis of abdominal tuberculosis was unlikely. Hence, the diagnosis of MIS-C was made and managed accordingly.

#### 7. Conclusion

The multisystem inflammatory syndrome is an uncommon complication of COVID-19 infection. The course of MIS-C can be fatal where most children require intensive care units and early institution of immunomodulatory therapy for their recovery. The diagnosis of MIS-C is challenging as its clinical presentation mimics several other



etiologies (Kawasaki disease, dengue, acute appendicitis). Similarly, in our case, the clinical presentation mimicked abdominal tuberculosis. Therefore, all pediatricians must have high suspicion to diagnose MIS-C.

#### Provenance and peer review

Not commissioned, externally peer reviewed.

#### Ethical approval

Research studies involving patients require ethical approval. Please state whether approval has been given, name the relevant ethics committee and the state the reference number for their judgement.

#### Sources of funding

None.

#### Author contribution

Author 1: Led data collection, the concept of the study, contributed to writing the initial manuscript draft.

Author 2: Literature review, concept of the study, revising, and editing the manuscript.

Author 3: Literature review, revised and edited the rough draft into the final manuscript.

Author 4: Literature review, revised and edited the rough draft into the final manuscript.

Author 5: Literature review and writing case information.

Author 6: Literature review, revising, and editing the manuscript.

All authors were involved in manuscript drafting and revising, and approved the final version.

#### Conflicts of interest

None.

#### Registration of research studies

1. Name of the registry: N/A.
2. Unique Identifying number or registration ID: N/A.
3. Hyperlink to your specific registration (must be publicly accessible and will be checked): N/A.

#### Guarantor

Dr. Surakshya Baral, Manipal College of Medical Sciences, Pokhara, Nepal. Email: [Brl.surak014@gmail.com](mailto:Brl.surak014@gmail.com).

#### Consent

Written informed consent was obtained from the parent of the patient for the publication of this case report and accompanying images. A copy of the written consent is available for review by the Editor-in-Chief of this journal on request.

#### Acknowledgment

None.

#### Appendix A. Supplementary data

Supplementary data to this article can be found online at <https://doi.org/10.1016/j.amsu.2022.104919>.

#### References

- [1] C.A. Nogueira-de-Almeida, L.A. Ciampo, I.S. Ferraz, I.R. Ciampo, A.A. Contini, F. D. Ued, Pediatric multisystem inflammatory syndrome associated with COVID-19: urgent attention required, *Rev. Assoc. Méd. Bras.* 67 (2021 Aug 13) 115–120.
- [2] J.C. McMurray, J.W. May, M.W. Cunningham, O.Y. Jones, Multisystem inflammatory syndrome in children (MIS-C), a post-viral myocarditis and systemic vasculitis—a critical review of its pathogenesis and treatment, *Front. Pediatr.* 8 (2020 Dec 16), 626182.
- [3] S. Jain, S. Sen, S. Lakshmivenkateshiah, P. Bobhate, S. Venkatesh, S. Udani, L. Shobhavat, P. Andankar, T. Karande, S. Kulkarni, Multisystem inflammatory syndrome in children with COVID-19 in Mumbai, India, *Indian Pediatr.* 57 (11) (2020 Nov) 1015–1019.
- [4] P. Taffarel, F.J. Barón, A.P. Rodriguez, J. Widmer, C. Meregaglia, Multisystem inflammatory syndrome in children related to COVID-19: an update regarding the presentation of two critically ill patients, *Arch. Argent. Pediatr.* 119 (2021 Feb 1) e26–e35.
- [5] R.A. Agha, T. Franchi, C. Sohrabi, G. Mathew, for the SCARE Group, The SCARE 2020 guideline: updating consensus surgical Case Report (SCARE) guidelines, *Int. J. Surg.* 84 (2020) 226–230.
- [6] E.M. Dufort, E.H. Koumans, E.J. Chow, E.M. Rosenthal, A. Muse, J. Rowlands, M. A. Barranco, A.M. Maxted, E.S. Rosenberg, D. Easton, T. Udo, Multisystem inflammatory syndrome in children in New York State, *N. Engl. J. Med.* 383 (4) (2020 Jul 23) 347–358.
- [7] Chowdhury SR, Sarkar M, Raychaudhuri D, Datta K, Nandi M. Multisystem inflammatory syndrome in children (MIS-C). *Child N.born.*:4.
- [8] M. Hwang, K. Wilson, L. Wendt, J. Pohlman, E. Densmore, C. Kaeppler, K. Van Arendonk, S. Yale, The Great Gut Mimicker: a case report of MIS-C and appendicitis clinical presentation overlap in a teenage patient, *BMC Pediatr.* 21 (1) (2021 Dec) 1–5.
- [9] A. Gupta, A. Gill, M. Sharma, M. Garg, Multi-system inflammatory syndrome in a child mimicking Kawasaki disease, *J. Trop. Pediatr.* 67 (3) (2021 Jun), fmaa060.
- [10] M. Samprathi, S. Narayanappa, M. Sridhar, P. Ramachandra, P. Vemgal, Multisystem inflammatory syndrome in children: a mimicker of severe dengue, *Indian J. Pediatr.* 88 (5) (2021 May) 486–487.
- [11] R. Gautam, G. Shrestha, P. Phuyal, Childhood tuberculosis: an under prioritized disease in Nepal, *JNMA: J. Nepal Med. Assoc.* JNMA 59 (234) (2021 Feb) 217.
- [12] S.B. Lal, R. Bolia, J.V. Menon, V. Venkatesh, A. Bhatia, K. Vaiphei, R. Yadav, S. Sethi, Abdominal tuberculosis in children: a real-world experience of 218 cases from an endemic region, *JGH Open* 4 (2) (2020 Apr) 215–220.
- [13] D. Narayanappa, C.R. Thirumala, Abdominal tuberculosis, *Pediatr. Infect. Dis.* 1 (1) (2019 Mar 1) 19–22.