

Patellar Fracture Fixation With Cannulated Compression Screws and FiberTape Cerclage



Andrew D. Posner, M.D., Ian Hutchinson, M.D., and Joseph Zimmerman, M.D.

Abstract: Transverse patella fractures with loss of knee extensor mechanism function are a common orthopaedic injury requiring operative fixation. Current accepted surgical options for noncomminuted transverse fractures include open reduction with tension band wiring. Although these procedures result in good clinical outcomes and fracture healing, symptomatic hardware from the historically used metal implants is very common. The purpose of this Technical Note is to describe a technique for treatment of transverse patellar fractures using cannulated compression screws with tensioned high-resistance suture tape functioning as the tension band. This technique provides effective, reproducible fracture fixation while minimizing symptomatic hardware, failure, and reoperation.

Patella fracture is a common injury seen in all age groups and accounts for approximately 1% of all fractures.^{1,2} In total, 70% to 90% of patella fractures are transverse, with most involving the middle third of the patella.^{3,4} Indications for surgical fixation are disruption of the extensor mechanism, >2 to 3 mm of articular step-off or >1 to 4 mm of fracture displacement.^{1,2,4-6} Historically, the most common treatment technique is a modified tension band wiring using longitudinal Kirschner wires (K-wires) traversing the fracture with stainless-steel wires bent in an figure of 8-pattern anterior to the patella.⁵⁻⁸

Symptomatic hardware is a frequent complication following open reduction and often requires reoperation for hardware removal.^{9,10} Loss of reduction and nonunion are also known complications contributing to high reoperation rates.^{5,6} Due to these historical complications associated with metal wiring, techniques using alternative materials such as braided synthetic

suture have been described.^{11,12} In this article, we describe a technique for patella fracture fixation using cannulated compression screws with synthetic high-

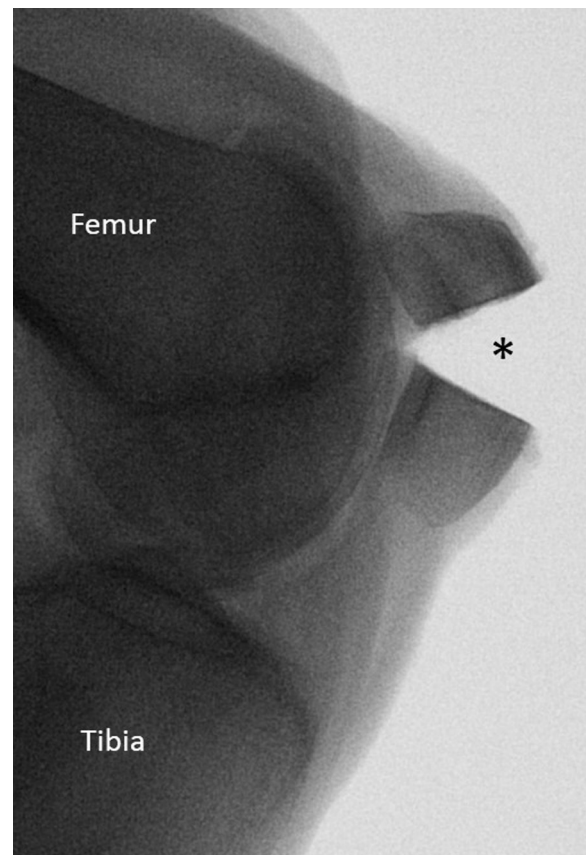


Fig 1. Left knee: preoperative lateral radiograph demonstrating a simple transverse fracture through the middle third of the patella (*).

From the Division of Orthopaedics, Albany Medical Center, Albany, New York, U.S.A.

The authors report that they have no conflicts of interest in the authorship and publication of this article. Full ICMJE author disclosure forms are available for this article online, as [supplementary material](#).

Received December 24, 2020; accepted February 8, 2021.

Address correspondence to Joseph Zimmerman, M.D., Department of Orthopaedic Surgery, Albany Medical College, 1367 Washington Ave., Suite 200, Albany, NY 12206. E-mail: jzimmerman@caportho.com

© 2021 THE AUTHORS. Published by Elsevier Inc. on behalf of the Arthroscopy Association of North America. This is an open access article under the CC BY-NC-ND license (<http://creativecommons.org/licenses/by-nc-nd/4.0/>).

2212-6287/202074

<https://doi.org/10.1016/j.eats.2021.02.008>

Table 1. Operative Technique

Patient positioning	Patient is placed supine on a radiolucent operating table. A tourniquet is placed proximally on the thigh.
Superficial dissection	Midline longitudinal incision is made centered over the patella.
Deep dissection	Dissection is carried through the subcutaneous tissue to the fracture site. Fracture hematoma is debrided.
Fracture reduction	Fracture reduction is attained with 2 large Weber clamps placed medially and laterally. Intraoperative fluoroscopy together manual palpation of the articular surface can confirm appropriate reduction.
Guidewire placement and screw measurement	Two 1.35-mm guidewires are passed through the C-Ring Drill guide in parallel spanning the fracture. They are placed from distal to proximal. C-Ring guide is used to measure screw length. Predrilling with a 2.6-mm cannulated drill bit is performed over the guidewire.
Screw placement	4.0-mm partially threaded, blunt tip cannulated screws are placed over the guidewires, compressing the fracture. The heads are buried into the distal cortex, and the blunt screw tips are left short of the proximal cortex.
FiberTape placement	Guide pins are left in place. The cannulated screwdriver is placed over the lateral guide pin to engage the screw head. The guide pin is removed while the screwdriver is left in place. The Suture Passing Wire is passed into the cannulated screwdriver and through the cannulated screw. The screwdriver is removed, leaving the looped end of the suture passing wire at the distal end of the lateral screw. The leading end of the FiberTape cerclage suture is placed through the loop and shuttled through the lateral screw. That leading end is then looped back over the anterior surface of the patella and shuttled again, using the previously described technique, through the medial screw. The suture is advanced so that 4 to 5 cm of tail, together with the card, remains at the distal end of the lateral screw. This tail and card is then looped over the anterior surface of the patella and brought back to the superior medial aspect of the patella where the leading end of the FiberTape remains.
FiberTape knot-tying	The leading end of the tape is loaded through the suture shuttle (#1 on the card). The card is held at the bullseye (#2 on the card) and the cerclage suture is shuttled through the pretied racking hitch knot by pulling on the opposite loop (#3 on the card). The shuttle suture and card can be discarded. The knot is adjusted so that it sits at the superior medial aspect of the patella.
FiberTape tensioning	The leading end of the FiberTape is cut to reveal two limbs. The suture tape is first tightened by hand to remove slack. The tensioner is used to tension the tapes with up to 80 pound-force of force. One half-hitch knot is tied and again tensioned to a maximum of 80 pound-force with the tensioner. Two additional alternating half-hitches are tied to complete the repair. The remaining tails are cut and the knot is buried in the soft tissue.
Confirmation of reduction	Following placement of all instrumentation, final fluoroscopic images are obtained. AP, lateral, and live fluoroscopic images are obtained to confirm reduction and stability through a range of motion.
Wound closure	The peritoneum and subcutaneous tissue are closed with 2-0 VICRYL. The skin is closed with 3-0 NYLON.

AP, anteroposterior.

strength nonabsorbable sutures functioning as the tension band (FiberTape Cerclage System; Arthrex, Naples, FL). In the authors' experience, use of FiberTape Cerclage, which is secured and tightened with use of the accompanying tensioning device, is a successful alternative to the use of metal wires or manually tensioned sutures and demonstrates excellent strength with minimal hardware irritation.

Surgical Technique (With Video Illustration)

A diagnosis of noncomminuted transverse patellar fracture with loss of extensor mechanism is made (Fig 1). The patient is brought to the operating room, with fluoroscopic imaging available. General or spinal anesthesia is administered, the patient is placed supine on a radiolucent flat-top operating table. A high thigh tourniquet is placed.

The primary steps of the following surgical procedure are summarized in Table 1 and demonstrated in Video 1. A midline longitudinal incision 6 to 10 cm in length is made sharply, centered over the patella. Dissection is continued deep through the subcutaneous tissue to expose the fracture site. Currettes and irrigation are used to clear the fracture hematoma.

Two large Weber clamps are placed medially and laterally to reduce the fracture. Anatomic patella reduction can be confirmed with fluoroscopy and direct palpation of the articular surface. Once satisfactory reduction is confirmed, two 1.35-mm guidewires are passed in parallel from distal to proximal through the C-ring Drill Guide (Arthrex) spanning the fracture (Fig 2). The C-Ring Drill Guide over the guidewire is used to measure screw length. It is crucial to subtract 4 mm from the measured length to prevent prominent hardware following fracture compression. Predrilling

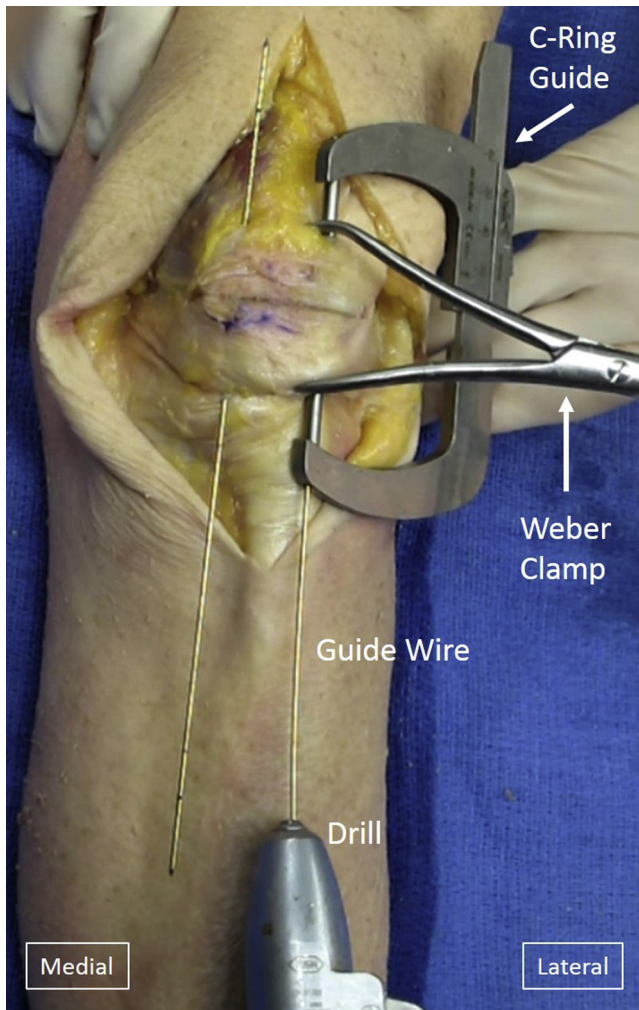


Fig 2. Patella fracture fixation in left knee, supine position. The fracture is reduced with a weber clamp and two 1.35-mm guidewires are passed through the C-Ring Drill guide in parallel spanning the fracture. The C-Ring guide is used to measure screw length.

with a 2.6-mm cannulated drill bit is performed over the guidewires, leaving the guidewires intact. The 4.0-mm partially threaded, blunt tip cannulated screws are then placed over the guidewires from distal to proximal (Fig 3). The screw heads are buried into the distal cortex, and the blunt screw tips are left short of the proximal cortex to decrease suture irritation.

The guide pins are left in place. The cannulated screwdriver is placed over the lateral guide pin and engages the screw head. The guide pin is removed while the screwdriver is left in place. The Suture Passing Wire (Arthrex) is then passed into the cannulated screwdriver and through the cannulated screw. The screwdriver is removed, leaving the looped end of the suture passing wire at the distal end of the lateral screw. The leading end of the FiberTape cerclage suture is placed into the loop and shuttled via the suture passing wire from distal to proximal through the lateral screw

(Fig 4). That leading end is then looped back over the anterior surface of the patella and advanced again, using the previously described technique, through the medial screw. The suture is advanced so that only 4 to 5 cm of tail, together with the card, remains at the distal end of the lateral screw. This tail and card is then looped over the anterior surface of the patella and brought back to the superior medial aspect of the patella where the leading end of the FiberTape remains (Fig 5).

The FiberTape cerclage suture is then tightened in the following manner: The leading end of the tape is loaded through the suture shuttle (#1 on the card). The card is held at the bullseye (#2 on the card) and the cerclage suture is shuttled through the pretied racking hitch knot by pulling on the opposite loop (#3 on the card). The shuttle suture and the card can now be discarded. The knot can be adjusted so that it sits at the superior medial aspect of the patella. The suture tape is first tightened by hand to remove slack (Fig 6 A and B). The leading end of the FiberTape is cut to reveal 2 limbs. The 2 limbs are then loaded into the tensioner (FiberTape Cerclage Tensioner; Arthrex), which is used to

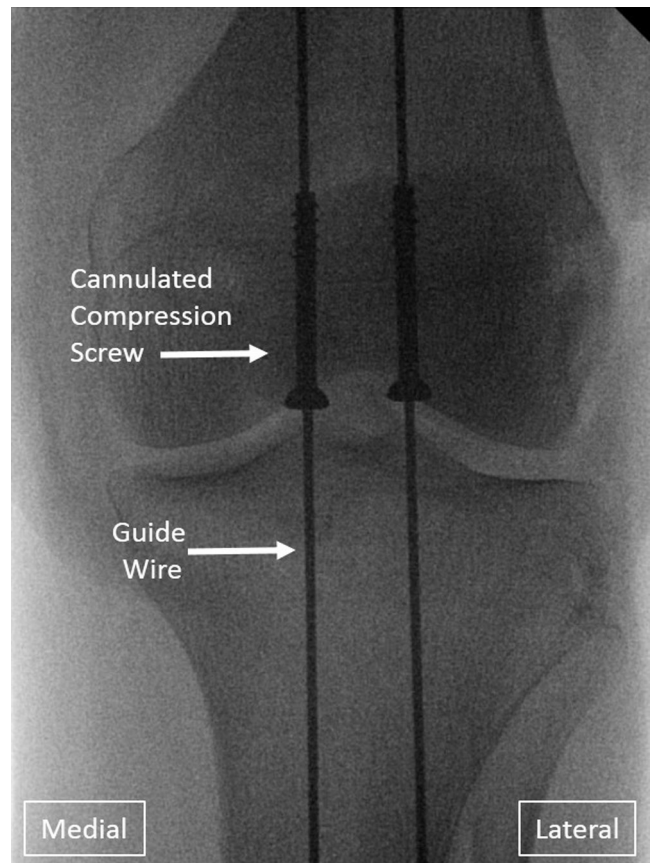


Fig 3. Patella fracture fixation in left knee, intraoperative anteroposterior radiograph. Two 4.0-mm partially threaded, blunt tip cannulated screws are placed over the guidewires. The screw heads are buried into the distal cortex, and the blunt screw tips are left short of the proximal cortex.

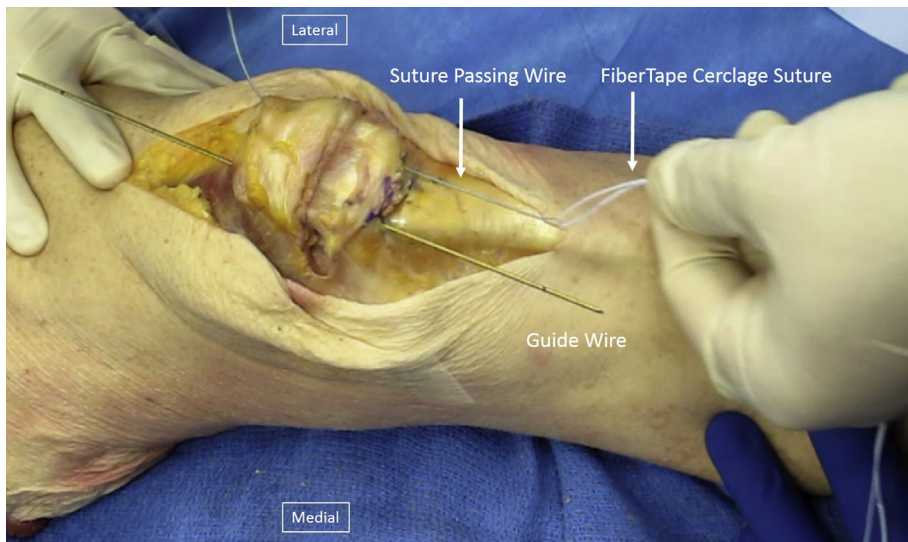


Fig 4. Patella fracture fixation in left knee, supine position. The Suture Passing Wire is used to shuttle the FiberTape Cerclage Suture from distal to proximal through the lateral cannulated screw first, then through the medial cannulated screw.

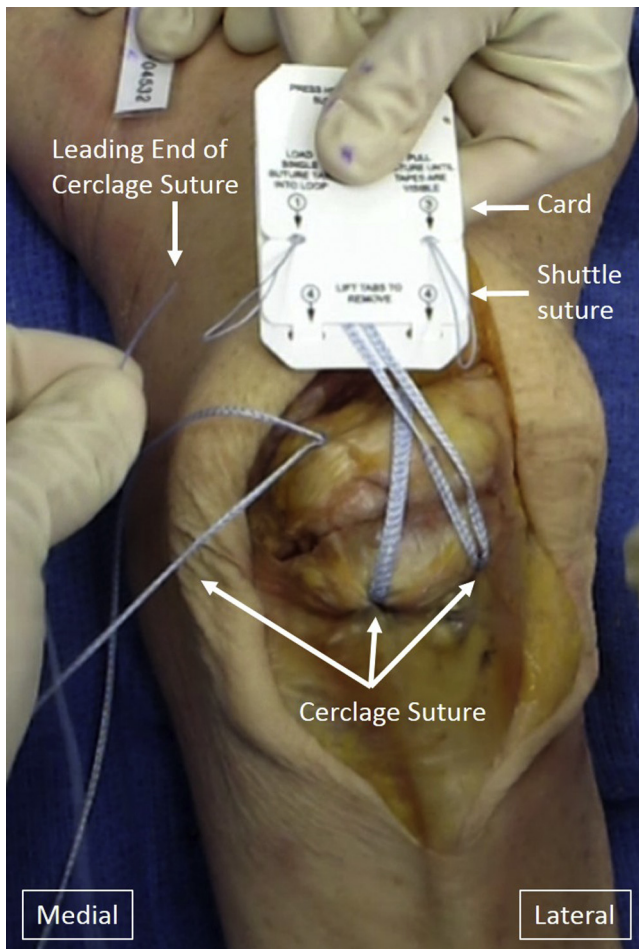


Fig 5. Patella fracture fixation in left knee, supine position. The FiberTape Cerclage Suture is passed through both cannulated screws in a figure-of-eight fashion. The suture is advanced so that only 4 to 5 cm of tail, together with the card, remains at the distal end of the lateral screw. The tail and card is then brought over the anterior surface of the patella to where the leading end of the cerclage suture remains.

tension the tapes with up to 80 pound-force of force (Fig 7). One half-hitch knot is tied and again tensioned to 80 pound-force with the tensioner. Two additional alternating half-hitches are tied to complete the repair. The remaining tails are cut and the knot is buried in the soft tissue (Fig 8). Final fluoroscopic images are obtained to confirm reduction through a range of motion (Fig 9). The tourniquet is released and hemostasis is established. Retinacular tears are repaired and the peritenon and subcutaneous tissue are closed. The skin is sutured and dressing is applied. The advantages and disadvantages of this techniques are summarized in Table 2.

Postoperatively, the patient is immobilized in a hinged knee brace, locked in full extension, to be worn at all times. Immediate weight-bearing as tolerated with the brace is allowed. At 2 weeks postoperatively, skin sutures are removed, knee radiographs are evaluated, and formal physical therapy including progressive and controlled active knee flexion movements can begin. Eight weeks postoperatively, full range of motion and active knee flexion is allowed. The goal of the rehabilitation protocol is to achieve full active range of motion at 12 weeks postoperatively. After this point, the patient is reexamined in the outpatient setting at 6 months, 12 months, and then as needed.

Discussion

This surgical technique of cannulated compression screws with a suture tape tension band provides distinct benefits when compared with traditional patellar fracture fixation via K-wire and a metal tension band. First, buried cannulated compression screws may be advantageous to historical K-wires. Biomechanical cadaver studies comparing cannulated screws with K-wires have found that while both constructs resist fracture

Fig 6. Patella fracture fixation in left knee, supine position. The leading end of the cerclage suture is shuttled through the pre-tied racking hitch (A) and the cerclage assembly is hand tightened (B).

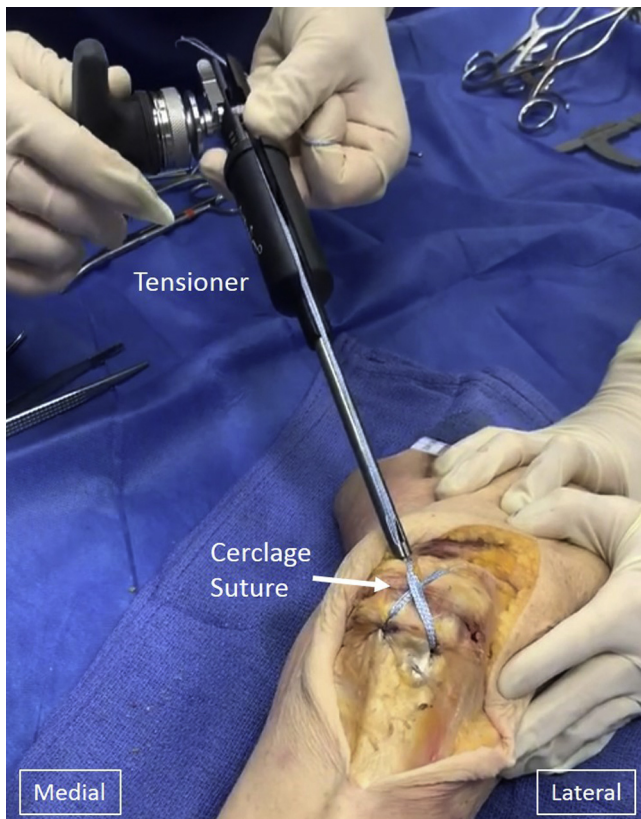
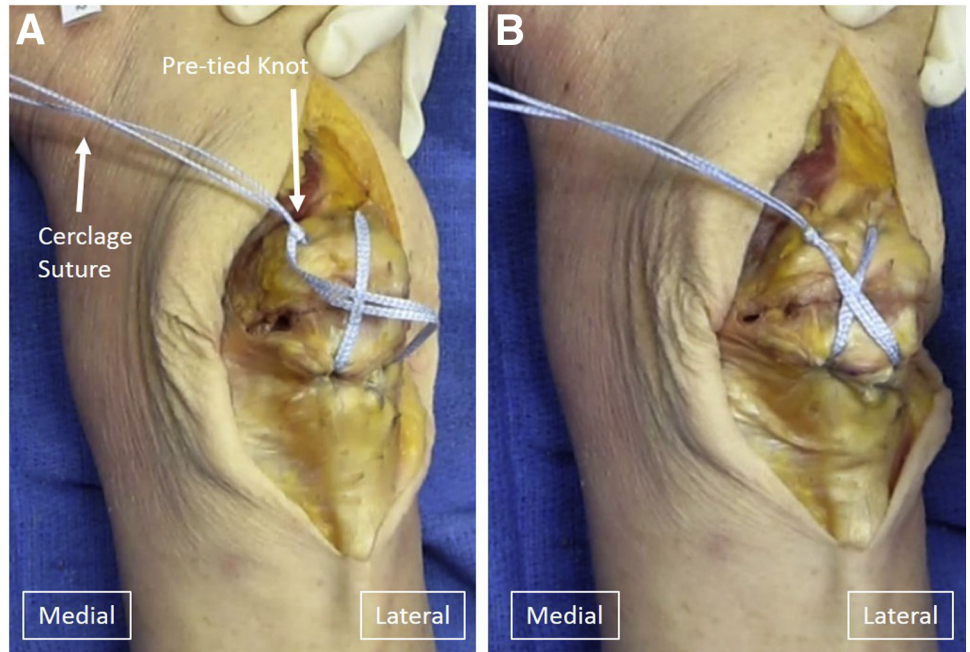


Fig 7. Patella fracture fixation in left knee, supine position. The tensioner is used to tension the tapes with up to 80 pound-force of force. One half-hitch knot is tied and again tensioned to 80 pound-force with the tensioner. Two additional alternating half-hitches are tied to complete the repair.

displacement, cannulated screws provide superior stability and fail at significantly greater loads.¹³ Multiple studies have demonstrated successful patella fracture

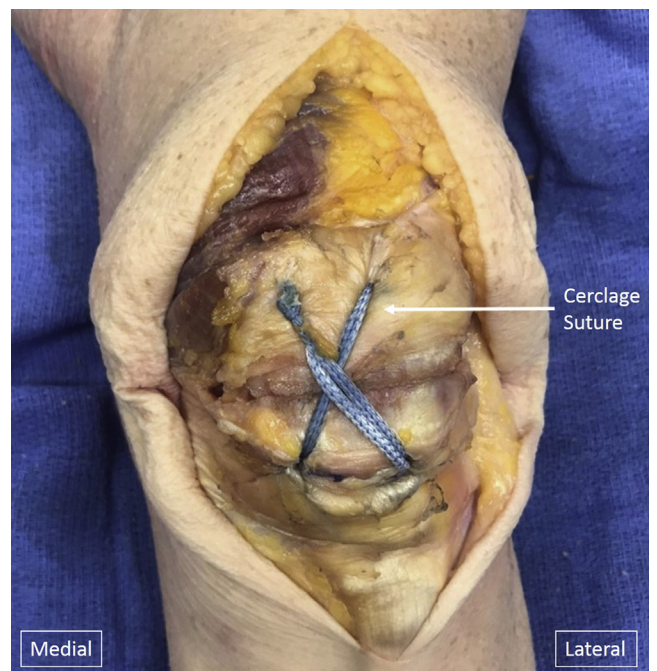

Fig 8. Patella fracture fixation in left knee, supine position. The completed repair with all instrumentation and suture in place before skin closure. The cerclage suture has been passed through both cannulated screws in a figure-of-eight fashion and tensioned.

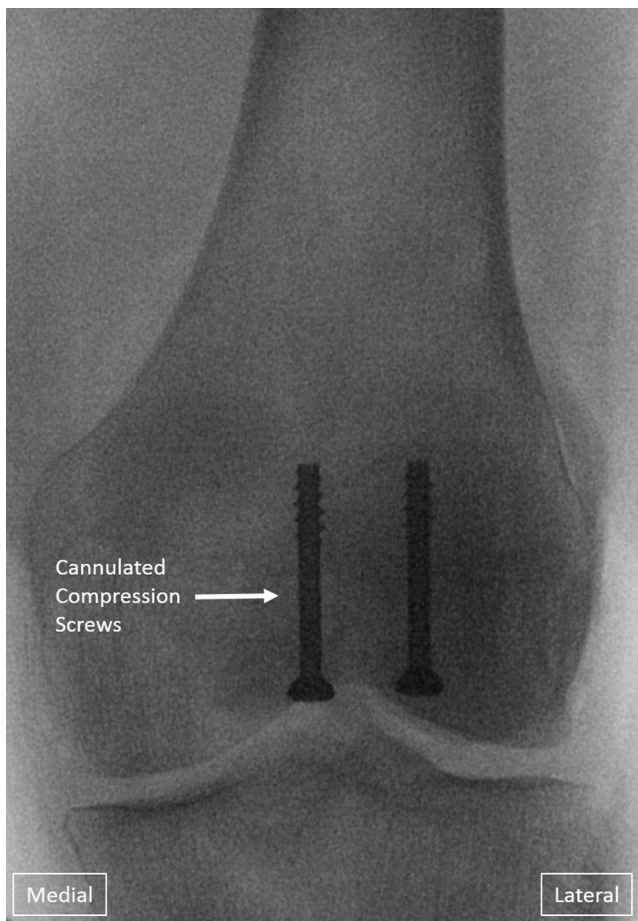


Fig 9. Patella fracture fixation in left knee, final intra-operative anteroposterior radiograph. Radiograph at the completion of the procedure demonstrating compression of simple transverse fracture through the middle third of the patella using 2 cannulated compression screws with tensioned cerclage suture.

fixation with cannulated screws.^{8,14-17} Furthermore, K-wires, which are prominent and may migrate, result in significantly increased rates of symptomatic

hardware requiring hardware removal when compared with cannulated screws, which are buried.^{8,14-17}

A second benefit is that high-strength nonabsorbable sutures may provide a superior tension band construct than traditional metal wires.¹¹ Fracture fixation with suture tension bands have demonstrated high rates of fracture union and excellent outcomes.¹⁸⁻²⁰ Advantages of suture over metal wire include less hardware irritation with lower rates of revision surgery.^{6,7,12} Furthermore, biomechanical studies have demonstrated that FiberWire (Arthrex) has greater failure strength and is superior to stainless steel in maintaining a tension band under force.²¹ Lastly, suture is easier to handle and tighten than metal wire, which can translate to a tighter construct and decreased tourniquet and operating time.^{11,20}

In addition, the FiberTape Cerclage System uses a pre-tied racking hitch knot and the accompanying tensioning system, allowing for precise and reproducible tensioning.²² In comparison, technical errors during hand tying of suture can result in loose knots or knot slippage, which would compromise tension band function.^{20,23} Correct tensioning and knot tightening thus may reduce the risk of subsequent fixation failure and poor outcomes. The FiberTape Cerclage System has been previously described in patella fracture fixation as part of a circumferential cerclage construct²²; however, use of this system has not been described as a technique to provide an anterior tension band while passing through cannulated screws.

There are some potential pitfalls to this technique. Cannulated screws may be difficult to place properly; the screw must be long enough to have threads distal to the fracture to allow for fracture compression; however, if the screws are too long, then the end of the screw may abrade the suture, resulting in suture breakage and failure of the tension band. Use of a blunt-ended screw can decrease risk of suture abrasion. Also, while use of the tensioner is essential for suture tightening, overtensioning can cause suture failure, requiring

Table 2. Pearls and Pitfalls

Criteria	Pearls	Pitfalls
Screw selection	The blunt tip screws decrease abrasion between the suture and the screw tip.	Inappropriate screw length: the screw may be too long, causing the screw head to protrude distally or the tip to protrude proximally. This may cause irritation.
FiberTape placement	Use of guidewire, cannulated screwdriver, and suture passing wire to easily shuttle FiberTape through cannulated screws.	Removal of guidewire may make passage of FiberTape through cannulated screws more difficult and time-consuming.
Tensioning	Use of the tensioner ensures optimal compression and tension band function.	Overtightening with the tensioner to greater than 80 pound-force may cause suture breakage. Half-hitches must be thrown after tensioning to prevent knot slippage.
Fluoroscopy	The suture tape is radiolucent, allowing excellent assessment of fracture reduction. Verify final stability and reduction through knee range of motion.	Fluoroscopy can be used to ensure screws are placed perpendicular to the fracture and parallel to the articular surface to achieve optimal reduction.
Patient tolerance	The suture tape is well tolerated postoperatively.	Failure to bury the knot at the conclusion of the case may lead to irritation.

replacement with another suture. Adhering to tensioning recommendations can minimize this risk. Furthermore, this technique is most effective in simple transverse fractures; patella fractures with significant comminution may be best treated using other methods. Ultimately, randomized controlled clinical trials are needed to fully assess the efficacy of this technique for treating simple transverse patella fractures compared with tension band wiring as a gold standard technique.

References

- Melvin JS, Mehta S. Patellar fractures in adults. *J Am Acad Orthop Surg* 2011;19:198-207.
- Henrichsen JL, Wilhem SK, Siljander MP, Kalma JJ, Karadsheh MS. Treatment of patella fractures. *Orthopedics* 2018;41:e747-e755.
- Byun SE, Sim JA, Joo YB, et al. Changes in patellar fracture characteristics: A multicenter retrospective analysis of 1596 patellar fracture cases between 2003 and 2017. *Injury* 2019;50:2287-2291.
- Gwinner C, Märdian S, Schwabe P, Schaser KD, Krapohl BD, Jung TM. Current concepts review: Fractures of the patella. *GMS Interdiscip Plast Reconstr Surg DGPW* 2016;5:Doc01.
- Bui CN, Learned JR, Scolaro JA. treatment of patellar fractures and injuries to the extensor mechanism of the knee: A critical analysis review. *JBJS Rev* 2018;6:e1.
- Hargett DI, Sanderson BR, Little MTM. Patella fractures: Approach to treatment. *J Am Acad Orthop Surg* 2021;29:244-253.
- Camarda L, Morello S, Balistreri F, D'Arienzo A, D'Arienzo M. Non-metallic implant for patellar fracture fixation: A systematic review. *Injury* 2016;47:1613-1617.
- Meng D, Xu P, Shen D, et al. A clinical comparison study of three different methods for treatment of transverse patellar fractures. *J Orthop Sci* 2019;24:142-146.
- Petrie J, Sassoon A, Langford J. Complications of patellar fracture repair: Treatment and results. *J Knee Surg* 2013;26:309-312.
- Rathi A, Swamy MK, Prasantha I, Consul A, Bansal A, Bahl V. Percutaneous tension band wiring for patellar fractures. *J Orthop Surg (Hong Kong)* 2012;20:166-169.
- Camarda L, La Gattuta A, Butera M, Siragusa F, D'Arienzo M. FiberWire tension band for patellar fractures. *J Orthop Traumatol* 2016;17:75-80.
- Shea GK-H, Hoi-Ting So K, Tam K-W, Yee DK-H, Fang C, Leung F. Comparing 3 different techniques of patella fracture fixation and their complications. *Geriatr Orthop Surg Rehabil* 2019;10:215145931982714.
- Carpenter JE, Kasman RA, Patel N, Lee ML, Goldstein SA. Biomechanical evaluation of current patella fracture fixation techniques. *J Orthop Trauma* 1997;11:351-356.
- Berg EE. Open reduction internal fixation of displaced transverse patella fractures with figure-eight wiring through parallel cannulated compression screws. *J Orthop Trauma* 1997;11:573-576.
- Hoshino CM, Tran W, Tiberi JV, et al. Complications following tension-band fixation of patellar fractures with cannulated screws compared with Kirschner wires. *J Bone Joint Surg Am* 2013;95:653-659.
- Tan H, Dai P, Yuan Y. Clinical results of treatment using a modified K-wire tension band versus a cannulated screw tension band in transverse patella fractures: A strobe-compliant retrospective observational study. *Medicine (Baltimore)* 2016;95, e4992.
- Zhang Y, Xu Z, Zhong W, Liu F, Tang J. Efficacy of K-wire tension band fixation compared with other alternatives for patella fractures: A meta-analysis. *J Orthop Surg Res* 2018;13:1-10.
- Gosal HS, Singh P, Field RE. Clinical experience of patellar fracture fixation using metal wire or non-absorbable polyester: A study of 37 cases. *Injury* 2001;32:129-135.
- Busel G, Barrick B, Auston D, et al. Patella fractures treated with cannulated lag screws and FiberWire have a high union rate and low rate of implant removal. *Injury* 2020;51:473-477.
- Wong AL, Wong KK, Wong KK, Wong WC. The "invisible" wiring technique for displaced fracture patella. *J Orthop Trauma Rehabil* 2020;27:252-257.
- Wright PB, Kosmopoulos V, Cote RE, et al. FiberWire is superior in strength to stainless steel wire for tension band fixation of transverse patellar fractures. *Injury* 2009;40: 1200-1203.
- Monaco E, Bruni G, Daggett M, et al. Patellar fracture fixation using suture tape cerclage. *Arthrosc Tech* 2020;9: e783-e789.
- Meyer DC, Bachmann E, Lädermann A, Lajtai G, Jentsch T. The best knot and suture configurations for high-strength suture material. An in vitro biomechanical study. *Orthop Traumatol Surg Res* 2018;104:1277-1282.