

Combination Therapy With Casirivimab/Imdevimab and Remdesivir for Protracted SARS-CoV-2 Infection in B-cell-Depleted Patients

M. Veronica Diovetti,¹ David C. Gaston,² C. Paul Morris,^{2,3} Carol Ann Huff,⁴ Tania Jain,⁴ Richard Jones,⁴ Viki Anders,⁴ Howard Lederman,^{1,5} Jacqueline Saunders,⁶ Heba H. Mostafa,² and Robin K. Avery^{1,6}

¹Division of Infectious Diseases, Department of Medicine, Johns Hopkins University, Baltimore, Maryland, USA, ²Division of Medical Microbiology, Department of Pathology, Johns Hopkins University, Baltimore, Maryland, USA, ³National Institute of Allergy and Infectious Disease, National Institutes of Health, Bethesda, Maryland, USA, ⁴Division of Hematological Malignancies and Bone Marrow Transplantation, Sidney Kimmel Comprehensive Cancer Center, Johns Hopkins University, Baltimore, Maryland, USA, ⁵Division of Pediatric Allergy, Immunology and Rheumatology, Johns Hopkins University, Baltimore, Maryland, USA, and ⁶Oncology Investigational Drug Service Pharmacy, Johns Hopkins Hospital, Baltimore, Maryland, USA

Profoundly B-cell-depleted patients can have prolonged severe acute respiratory syndrome coronavirus 2 infections with evidence of active viral replication, due to inability to mount an adequate humoral response to clear the virus. We present 3 B-cell-depleted patients with prolonged coronavirus disease 2019 infection who were successfully treated with a combination of casirivimab/imdevimab and remdesivir.

Keywords. B-cell-depleted; monoclonal antibodies; prolonged SARS-CoV-2.

Immunocompromised hosts remain at risk for severe coronavirus disease 2019 (COVID-19) infection, particularly those with B-cell depletion, as impaired antibody response could lead to ineffective viral clearance [1]. These patients can have prolonged infections with severe acute respiratory syndrome coronavirus 2 (SARS-CoV-2), with low cycle threshold (Ct) values with nucleic acid amplification testing (NAAT) and recovery of infectious virus in cell culture [2–5]. These patients are at risk not only for recurrent hospitalizations, but for emergence of escape mutants that can spread to communities.

The antiviral remdesivir has been shown to shorten time to recovery [6]. The combination of monoclonal antibodies (mAb) casirivimab/imdevimab reduces risk of hospitalization

and death and reduces viral load (VL) in upper respiratory tract specimens without emergence of escape mutants [7, 8]. We hypothesized that combination of mAb and remdesivir would be safe and effective in achieving viral clearance and symptom resolution without risking emergence of escape mutants. We present 3 B-cell-depleted patients with prolonged COVID-19 who were treated successfully with combination casirivimab/imdevimab under an emergency Investigational New Drug (E-IND) application with off-label remdesivir. Treatment was a single dose of 1200 mg intravenously of each of casirivimab and imdevimab and a 5-day course of remdesivir (200-mg loading dose intravenously, then 100 mg daily thereafter).

PATIENT CONSENT

Written consent was obtained from each patient.

The design of the work was approved by the Johns Hopkins Institutional Review Board (IRB) and conforms to standards currently applied in the United States. In addition, E-IND approval was obtained from Regeneron Pharmaceuticals and the US Food and Drug Administration (FDA).

Patient #1

A 45-year-old man with multiply treated relapsed/refractory follicular lymphoma, history of nonmyeloablative haploidentical bone marrow transplant (BMT) complicated by graft-vs-host disease (GVHD) on prednisone and ibrutinib, and hypogammaglobulinemia was admitted 1 year after BMT with cough, headache, and loss of taste and smell, but not hypoxemia. He was diagnosed with COVID-19 via NAAT and received convalescent plasma. Two months later, he had persistent cough without fevers or hypoxemia, and a chest computed tomography (CT) scan showed bilateral ground-glass opacities. SARS-CoV-2 via NAAT on nasopharyngeal (NP) swab was persistently positive with low Ct (Table 1). Extensive evaluation was negative for other etiologies.

He received casirivimab/imdevimab on day 70 after diagnosis and off-label remdesivir on days 75–79; SARS-CoV-2 NAAT became negative on day 84 (Table 1), with resolution of cough by 2 weeks and normalization of chest CT by 4 weeks. His preceding leukopenia and neutropenia (absolute neutrophil count 0.79 K/cu mm) normalized by 2 weeks post-treatment. Ten months later, he is clinically well except for baseline GVHD.

Patient #2

A 52-year-old woman with follicular lymphoma (in remission after R-CHOP) and common variable immunodeficiency (CVID) on weekly subcutaneous immunoglobulin G replacement was hospitalized with fever, cough, and headache. She

Received 10 November 2021; editorial decision 31 January 2022; accepted 4 February 2022; published online 26 May 2022.

Correspondence: M. Veronica Diovetti, MD, 600 N Wolfe Street, Carnegie Building 340, Baltimore, MD 21287 (mdiover1@jhmi.edu).

Open Forum Infectious Diseases® 2022

© The Author(s) 2022. Published by Oxford University Press on behalf of Infectious Diseases Society of America. This is an Open Access article distributed under the terms of the Creative Commons Attribution-NonCommercial-NoDerivs licence (<https://creativecommons.org/licenses/by-nc-nd/4.0/>), which permits non-commercial reproduction and distribution of the work, in any medium, provided the original work is not altered or transformed in any way, and that the work is properly cited. For commercial re-use, please contact journals.permissions@oup.com <https://doi.org/10.1093/ofid/ofac064>

Table 1. Timeline of Treatment, Cycle Threshold Values, and AA Substitutions

Patient Number ^a	Day From Diagnosis	Platform	Ct Values	Developed AA Substitutions
Patient #1	0	NeuMoDx	N 13.69, Nsp2 14.37	
	1	Convalescent plasma infusion		
	19	Cepheid (Xpert Xpress SARS-CoV-2/Flu/RSV)	N2/E 14.7	
	57	GenMark ePlex	N/A ^b	NSP8:I156L NS6:E13K
	61	Cepheid (Xpert Xpress SARS-CoV-2/Flu/RSV)	N2/E 19.1	
	70	REGN-COV infusion	–	
	77	Cepheid (Xpert Xpress SARS-CoV-2/Flu/RSV)	N2/E 30.1	
	84	Roche 6800	Negative	
	91	Cepheid (Xpert Xpress SARS-CoV-2/Flu/RSV)	Negative	
	216	NeuMoDx	Negative	
Patient #2	0	NeuMoDx	N 18.62, Nsp2 19.71	
	20	GenMark ePlex	N/A ^b	
	26	NeuMoDx	N 24.10, Nsp2 25.74	
	33	GenMark ePlex	N/A ^b	
	38	BAL; Altona (RealStar 1.0)	N/A ^b	
	103	GenMark ePlex	N 19.27, Nsp2 19.94	NSP2:K534R
	111	REGN-COV infusion	–	–
	117	Cepheid (Xpert Xpress SARS-CoV-2/Flu/RSV)	N2/E 26.2	NSP13:D56G S:N334K S:S939F
	126	Cepheid (Xpert Xpress SARS-CoV-2/Flu/RSV)	N2/E 31.6	
	132	Cepheid (Xpert Xpress SARS-CoV-2/Flu/RSV)	N2/E 37.7	
	139	Cepheid (Xpert Xpress SARS-CoV-2/Flu/RSV)	N2/E 37.2	
	147	NeuMoDx	Negative	
	Patient #3	0	GenMark ePlex	N/A ^b
1		Bamlanivimab infusion		
23		Cepheid (Xpert Xpress SARS-CoV-2/Flu/RSV)	N2/E 23.3	S:E484K
38		Cepheid (Xpert Xpress SARS-CoV-2/Flu/RSV)	N2/E 21.9	
39		Cepheid (Xpert Xpress SARS-CoV-2/Flu/RSV)	N2/E 22.2	
45		NeuMoDx	N 21.11, Nsp2 22.43	
47		REGN-COV infusion	–	
50		NeuMoDx	N 28.69, Nsp2 30.01	NSP6:L37F
57		Cepheid (Xpert Xpress SARS-CoV-2/Flu/RSV)	N2/E 29.1	
64	Roche 6800	Negative		

Abbreviations: AA, amino acid; Ct, cycle threshold.

^aClade/lineages: patient 1, 20A/B.1.409; patient 2, 20B/B.1.1.434; patient 3, 20G/B.1.2.

^bN/A represents positive results; Ct values are not reported by this assay.

tested positive for SARS-CoV-2 NAAT on NP swab with chest CT showing bilateral ground-glass opacities and received a 10-day course of dexamethasone. Attempts to wean dexamethasone were unsuccessful and led to extensive evaluation revealing only persistent SARS-CoV-2 NAAT with low Ct values (Table 1). She received casirivimab/imdevimab on day 111 and remdesivir on days 115–119. Her Ct values on SARS-CoV-2 NAAT increased until NAAT became negative on day 146. She is clinically well 10 months after treatment.

Patient #3

A 62-year-old woman with refractory diffuse large B-cell lymphoma received chimeric antigen receptor (CAR) T-cell therapy (after fludarabine and cyclophosphamide), complicated by cytokine release syndrome. Three weeks after

CAR T cells, she was diagnosed with mild COVID-19 via NAAT, with cough and fatigue, and received bamlanivimab under Emergency Use Authorization. She continued with intermittent fevers and developed hypoxemia with persistently positive SARS-CoV-2 NAAT with low Ct. She received casirivimab/imdevimab on day 47 and remdesivir on days 46–50; repeat SARS-CoV-2 NAAT Ct slowly increased until NAAT was negative on day 64. She is clinically well 8 months after treatment.

SAFETY

After baseline physical exam, weekly symptom assessments, CBC with differential (CBC), complete metabolic panel (CMP), and NP swab for SARS-CoV-2 NAAT were obtained on all

patients for 4 weeks post-treatment. Daily CBCs and CMPs were obtained during the 5 days of remdesivir. There were no infusion-related reactions, no early discontinuations, no serious adverse events, and no evidence of hematologic, renal, hepatic, gastrointestinal, or other toxicities. At 8–10 months after treatment, no patient has had recurrent COVID-19.

IMMUNOLOGIC PARAMETERS

B Cells

Patient #1 did not have lymphocyte subsets performed before casirivimab/imdevimab, but had an absolute lymphocyte count (ALC) of 0.16 K/cu mm. One month later, he had a CD19+ lymphocyte count and percentage of 0, which was considered to have been baseline. Patient #2 had lymphocyte subsets 3 months before casirivimab/imdevimab, with CD19+ count and percentage of 0, and ALC of 0.12 K/cu mm. Patient #3 did not have lymphocyte subsets, but had an ALC of 0.19 K/cu mm before casirivimab/imdevimab. Normal ranges are ALC 1.1–4.8 K/cu mm, CD19+ lymphocyte total number 12–645/ μ L, and CD19+ lymphocyte percentage 6%–19%.

Immunoglobulins

Patient #1 had a total immunoglobulin G (IgG) level of 179 mg/dL (normal, 610–1616 mg/dL), immunoglobulin A (IgA) 16 mg/dL (normal, 61–348 mg/dL), and immunoglobulin M (IgM) <10 mg/dL (normal, 35–242 mg/dL) before casirivimab/imdevimab. Patient #2 was receiving subcutaneous immunoglobulin replacement (6 g weekly), with an IgG level of 417 mg/

dL, IgA 27 mg/dL, and IgM <10 mg/dL. Patient #3 had an IgG level of 525 mg/dL, IgA 50 mg/dL, and IgM <10 mg/dL. Thus, all 3 had low baseline Ig levels, including all with IgM below the limit of quantitation.

Anti-SARS-CoV-2 Antibodies

Before casirivimab/imdevimab, Patient #1 had an anti-S1-subunit IgG of 0.03 arbitrary units (arb'U) on the Euroimmun assay (positive >1.24 arb'U) (Figure 1). One week after casirivimab/imdevimab, this rose to 171.60 arb'U. Patient #2 had an anti-SARS-CoV-2 S1 spike subunit IgG of 0.09 arb'U before casirivimab/imdevimab. Patient #3 had a positive anti-S1-subunit IgG antibody of 8.50 arb'U 5 weeks after bamlamivimab but before casirivimab/imdevimab.

DISCUSSION

These 3 cases highlight protracted COVID-19 courses in B-cell-depleted immunocompromised patients. These patients have absent adaptive humoral responses, which are crucial to controlling viral infection, as shown by the inverse correlation between NAAT positivity and antibody seroconversion [9, 10]. This is further supported by reductions in VL seen after treatment with casirivimab/imdevimab [8]. It is now known that persistent NAAT positivity can represent replication-competent virus in viral cultures, and prolonged shedding could result in emergence of variants [2, 3].

Antibody-mediated neutralization is virus-specific, as demonstrated by lack of cross-reactivity between neutralizing

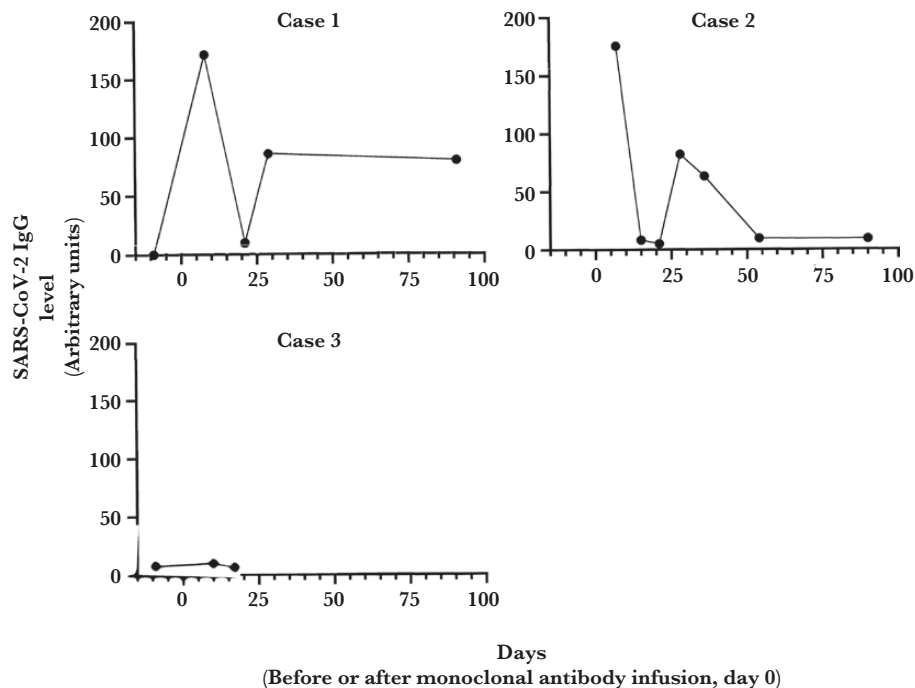


Figure 1. Subunit IgG values over time for all cases (Euroimmun SARS-CoV-2 S1 subunit ELISA kits assay, semiquantitative values). Abbreviations: ELISA, enzyme-linked immunosorbent assay; IgG, immunoglobulin G; SARS-CoV-2, severe acute respiratory syndrome coronavirus 2.

antibodies against the SARS-CoV-2 receptor binding domain (RBD) and those for SARS-CoV-1 and MERS-CoV [9]. Patients lacking circulating B-cells and/or with profound hypogammaglobulinemia are unable to mount neutralizing antibody responses, can have persistent symptoms [5] but still retain effective virus-specific T-cell responses [5].

When choosing therapy for these patients, a significant concern is preventing emergence of resistance. Remdesivir shortens duration of symptoms, likely by inhibiting viral proliferation [6]. Monoclonal antibody therapy with casirivimab/imdevimab could enhance clearance in patients without endogenous immune response or with high VL, without emergence of escape mutants [7]. We hypothesized that combination mAb would prevent escape mutants by binding to 2 distinct and nonoverlapping regions of the receptor binding domain [11], while addition of adjunctive remdesivir would help reduce viral burden [7].

Sequencing was done on the majority of samples from each patient. In this limited set, 12 amino acid substitutions were noted (Table 1); the most common mutations were in the spike protein. Patients #1 and #3 had received CP and bamlanivimab, respectively, before development of mutations, but the role of these therapies in selecting for mutations is unclear. Patient #3 received bamlanivimab before the development of S:E484K in lineage B.1.2, a lineage with a relative paucity of spike protein substitutions. This substitution has been associated with mAb escape when using monotherapy and with infections in vaccinated individuals [12]. Although some novel mutations were noted during or immediately after treatment in Patient #2 (Table 1), this did not translate into treatment and/or clinical failure. Of note, Patients #1 and #2 originally presented before the availability of monoclonal antibodies for early treatment.

Poor outcomes from COVID-19 have been reported in patients treated with anti-CD20 antibody therapy [1]. Predicting which patients might have severe complications is important; for example, SARS-CoV-2 RNAemia is being investigated as a marker of severity [1]. Of note, leukopenia/neutropenia in our first patient was attributed to viral suppression from persistent SARS-CoV-2, given its resolution shortly after casirivimab/imdevimab; SARS-CoV-2 has been found in bone marrow biopsies by real-time reverse transcription polymerase chain reaction, suggesting a potential role [5].

Emerging data show low antibody responses to COVID-19 mRNA vaccines in patients with CLL (39.5%) and those receiving anti-CD20 therapies within 12 months before vaccination [13]. This population will remain highly vulnerable, and more research is needed to define the best preventive and therapeutic approaches [14–16]. This case series, as well as other emerging reports of the utility of monoclonal antibody therapy in prolonged COVID-19 infection [17], highlights a potential role for passive immunotherapy, with or without an antiviral agent.

In conclusion, a combination of monoclonal antibodies and remdesivir was effective and well tolerated in 3 B-cell-depleted patients with protracted COVID-19 infection. It is possible that this regimen may have prevented emergence of escape mutants, although further study is needed to confirm this. Additional studies are needed to evaluate this treatment option in a larger population.

Acknowledgments

This study was possible with the unique efforts of the Johns Hopkins Clinical Microbiology Laboratory faculty and staff. H.H.M. is supported by the HIV Prevention Trials Network (HPTN) sponsored by the National Institute of Allergy and Infectious Diseases (NIAID), National Institute on Drug Abuse, National Institute of Mental Health, and Office of AIDS Research, of the NIH, DHHS (UM1 AI068613), the NIH RADx-Tech program (3U54HL143541-02S2), National Institute of Health RADx-UP initiative (Grant R01 DA045556-04S1), National Institute of Allergy and Infectious Diseases (Johns Hopkins Center of Excellence in Influenza Research and Surveillance HHSN272201400007C), Johns Hopkins University President's Fund Research Response, the Johns Hopkins Department of Pathology, the Maryland Department of Health, and the CDC. The views expressed in this manuscript are those of the authors and do not necessarily represent the views of the National Institute of Biomedical Imaging and Bioengineering; the National Heart, Lung, and Blood Institute; the National Institutes of Health, or the US Department of Health and Human Services.

REGEN-COV™ (casirivimab and imdevimab) was provided by Regeneron Pharmaceuticals, Inc., for the purpose of emergency compassionate use treatment.

Financial support. None.

Potential conflicts of interest. All authors: no reported conflicts of interest. All authors have submitted the ICMJE Form for Disclosure of Potential Conflicts of Interest. Conflicts that the editors consider relevant to the content of the manuscript have been disclosed.

References

1. Tepaspe PR, Hafezi W, Lutz M, et al. Persisting SARS-CoV-2 viraemia after rituximab therapy: two cases with fatal outcome and a review of the literature. *Br J Haematol* 2020; 190:185–8.
2. Baang JH, Smith C, Mirabelli C, et al. Prolonged severe acute respiratory syndrome coronavirus 2 replication in an immunocompromised patient. *J Infect Dis* 2021; 223:23–7.
3. Aydillo T, Gonzalez-Reiche AS, Aslam S, et al. Shedding of viable SARS-CoV-2 after immunosuppressive therapy for cancer. *N Engl J Med* 2020; 383:2586–8.
4. Choi B, Choudhary MC, Sparks JA, et al. Persistence and evolution of SARS-CoV-2 in an immunocompromised host. *N Engl J Med* 2020; 383:2291–3.
5. Hueso T, Poudereux C, Pere H, et al. Convalescent plasma therapy for B-cell-depleted patients with protracted COVID-19. *Blood* 2020; 136:2290–5.
6. Beigel JH, Tomashek KM, Dodd LE, et al. Remdesivir for the treatment of Covid-19 - final report. *N Engl J Med* 2020; 383:1813–26.
7. Copin R, Baum A, Wloga E, et al. The monoclonal antibody combination REGEN-COV protects against SARS-CoV-2 mutational escape in preclinical and human studies. *Cell* 2021; 184:3949–61.e11.
8. Weinreich DM, Sivapalasingam S, Norton T, et al. REGN-COV2, a neutralizing antibody cocktail, in outpatients with Covid-19. *N Engl J Med* 2021; 384:238–51.
9. Ju B, Zhang Q, Ge J, et al. Human neutralizing antibodies elicited by SARS-CoV-2 infection. *Nature* 2020; 584:115–9.
10. Zhao J, Yuan Q, Wang H, et al. Antibody responses to SARS-CoV-2 in patients with novel coronavirus disease 2019. *Clin Infect Dis* 2020; 71:2027–34.
11. Baum A, Fulton BO, Wloga E, et al. Antibody cocktail to SARS-CoV-2 spike protein prevents rapid mutational escape seen with individual antibodies. *Science* 2020; 369:1014–8.
12. Wang P, Casner RG, Nair MS, et al. Increased resistance of SARS-CoV-2 variant P. 1 to antibody neutralization. *Cell Host & Microbe* 2021; 29:747–51.e4.
13. Herishanu Y, Avivi I, Aharon A, et al. Efficacy of the BNT162b2 mRNA COVID-19 vaccine in patients with chronic lymphocytic leukemia. *Blood* 2021; 137:3165–73.

14. Furlan A, Forner G, Cipriani L, et al. COVID-19 in B cell-depleted patients after rituximab: a diagnostic and therapeutic challenge. *Front Immunol* **2021**; 12:763412.
15. Jones JM, Faruqi AJ, Sullivan JK, Calabrese C, Calabrese LH. COVID-19 outcomes in patients undergoing B cell depletion therapy and those with humoral immunodeficiency states: a scoping review. *Pathog Immun* **2021**; 6:76–103.
16. Gaitzsch E, Passerini V, Khatamzas E, et al. COVID-19 in patients receiving CD20-depleting immunochemotherapy for B-cell Lymphoma. *Hemasphere* **2021**; 5:e603.
17. D'Abramo A, Vita S, Maffongelli G, et al. Prolonged and severe SARS-CoV-2 infection in patients under B-cell-depleting drug successfully treated: a tailored approach. *Int J Infect Dis* **2021**; 107:247–50.