

Refractory Anti-NMDA Receptor Encephalitis in Early Pregnancy

A Case Report of Treatment Course and Pregnancy Outcomes

Sarah Fredrich, MD, Cynthia Wang, MD, Ram Narayan, MD, Lauren Tardo, MD, Kyle M. Blackburn, MD, and Steven Vernino, MD, PhD

Correspondence

Dr. Fredrich
sfredrich@som.umaryland.edu

Neurol Neuroimmunol Neuroinflamm 2022;9:e200007. doi:10.1212/NXL.0000000000200007

Abstract

Background and Objectives

Anti-N-methyl D-aspartate receptor (NMDAR) encephalitis classically affects women of childbearing age, producing a disproportionate number of pregnant women with anti-NMDAR encephalitis. The typical presentation includes progressive neuropsychiatric symptoms, seizures, and alterations in consciousness, all of which present potential risks to the fetus. First-line and second-line treatments similarly pose teratogenic potential; therefore, randomized studies with supportive data on pregnancy and fetal outcomes are lacking.

Methods

We present a case of refractory anti-NMDAR encephalitis during the first and second trimesters of pregnancy with the successful use of rituximab and cyclophosphamide and resultant healthy pregnancy.

Results

The patient was treated with an escalating immunotherapy regimen from 11 to 15 weeks of gestation, including steroids, plasma exchange, IV immunoglobulins, and rituximab, with no clinical response. At 16 weeks of gestation, she received cyclophosphamide with clinical improvement after 4 weeks. She subsequently gave birth to a healthy, term baby boy, who continued to do well at the follow-up.

Discussion

This case illustrates the effective use of cyclophosphamide in the second trimester of pregnancy for anti-NMDAR encephalitis. The use of second-line therapies remains an individualized decision because the relative risk-to-benefit ratio in pregnant women is incompletely understood.

From the Department of Neurology (S.F., C.W., L.T., K.M.B., S.V.), University of Texas Southwestern Medical Center, Dallas, TX; and Department of Neurology (R.N.), Barrow Neurological Institute, Phoenix, AZ.

Go to [Neurology.org/NN](https://www.neurology.org/NN) for full disclosures. Funding information is provided at the end of the article.

This is an open access article distributed under the terms of the Creative Commons Attribution-NonCommercial-NoDerivatives License 4.0 (CC BY-NC-ND), which permits downloading and sharing the work provided it is properly cited. The work cannot be changed in any way or used commercially without permission from the journal.

Glossary

ASM = antiseizure medication; NMDAR = N-methyl d-aspartate receptor.

Case

A 19-year-old woman presented with status epilepticus at 11 weeks of pregnancy. Her symptoms began 4 weeks earlier with increasing psychotic behaviors and seizures. Her anti-seizure medication (ASM) regimen at presentation included lacosamide, lamotrigine, levetiracetam, and clonazepam. On admission, her examination was notable for global hyper-reflexia and left Babinski and with propofol wean, continuous right upper extremity twitching, and oral automatisms, during which time EEG revealed multifocal epileptiform spikes. On admission, MRI of the brain was unremarkable. CSF studies showed a lymphocytic pleocytosis with normal glucose and protein. Owing to the persistence of focal motor status despite ASM escalation, suspicion for an immune-mediated process arose leading to empiric treatment with steroids (Figure). She was subsequently treated with plasma exchange, followed by rituximab with decreasing seizure frequency on EEG, although no clinical improvement.

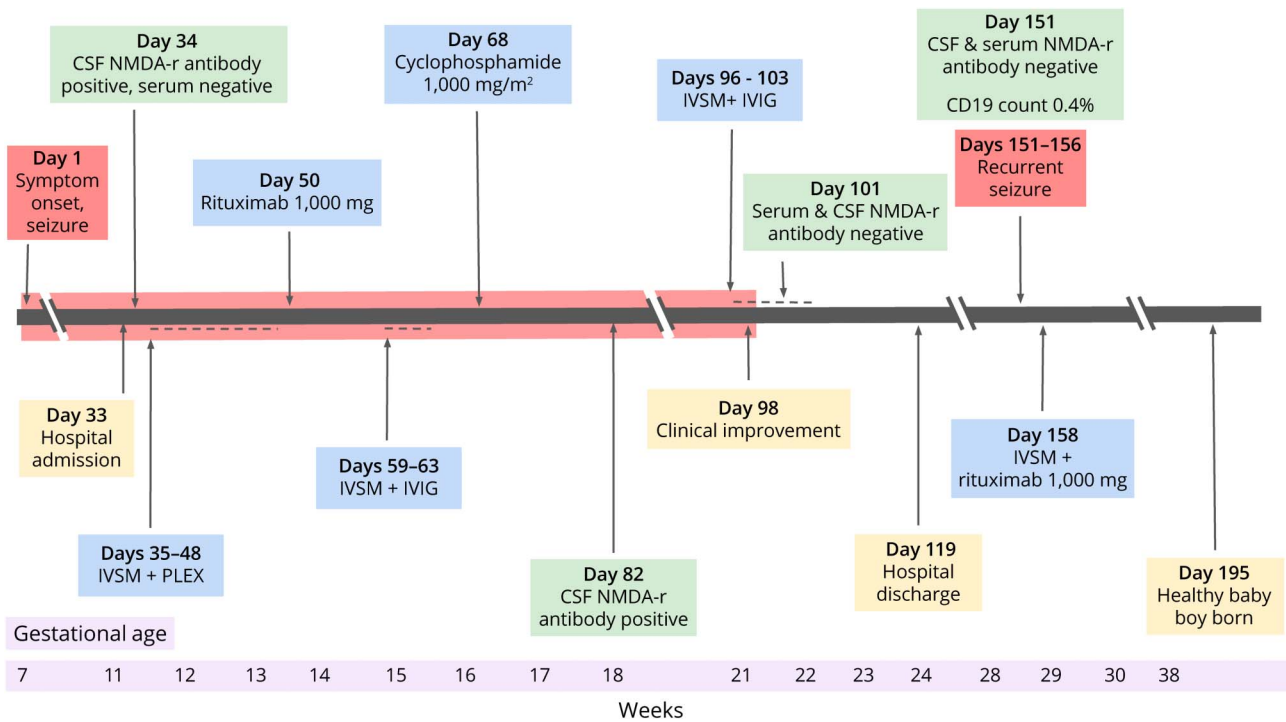
During this time, NMDAR antibodies were detected in the CSF. Serum NMDAR antibodies were negative. Screening for

an ovarian teratoma was unrevealing. Clinically she remained unchanged and thus received IV immunoglobulin and a second steroid course. CSF NMDAR antibodies remained positive. With the consent of her surrogate decision maker, she received cyclophosphamide at an estimated 16 weeks of gestation, followed by a third course of steroids.

Four weeks after cyclophosphamide administration, she began to show improvement in her mental status correlating with the absence of epileptogenic activity on EEG and undetectable CSF NMDAR antibodies. Maternofetal medicine confirmed normal progression of pregnancy at 23 weeks of gestation. She transitioned to a floor bed after 24 days in the intensive care unit; by the time of discharge to inpatient rehabilitation, the patient was alert, oriented, and conversant, requiring 2-person assistance for ambulation.

While at inpatient rehabilitation, her examination improved to fully ambulatory with mild cognitive deficits. She had recurrent seizures in the setting of levetiracetam wean at 29 weeks of gestation. Serum and CSF NMDAR antibodies remained undetectable; B-cell counts were suppressed. She was redosed with rituximab at this time and has continued

Figure Timeline of Clinical Events and Treatment



Timeline showing major clinical events (yellow), seizure activity (red), immunotherapy (blue), and NMDA-r antibody status (green) of the patient from symptom onset to delivery of baby. Red bar = seizure activity; purple bar = gestational age; dashed line = ongoing immunotherapy; CSF = cerebrospinal fluid; IVIG = IV immunoglobulin; IVSM = intravenous solumedrol; NMDA-r = NMDA receptor; PLEX = plasma exchange.

Table 1 Teratogenic Potential of Medications Commonly Used to Treat Anti-NMDAR Encephalitis

Drug Name	Category	Comments
Methylprednisolone (IV)	—	Associations with cleft-palate, increased risk for premature rupture of membranes (PROM), intrauterine growth restriction (IUGR), gestational hypertension, gestational diabetes.
Intravenous immunoglobulin	C	Case reports of hemolytic disease of newborn, transmission of hepatitis C.
Plasma exchange	—	Limited literature on safety or risk. Overall presumed to be safe.
Cyclophosphamide (CYC) (intravenous)	D	Normal offspring have been born to mothers treated with CYC during pregnancy. CYC embryopathy has been described with multiple fetal anomalies. High rates of miscarriage.
Rituximab	C	Neonatal lymphopenia has been reported, with normalization of cell counts within 6 mo. No definitive increase in neonatal infections noted during the lymphopenic period.
Mycophenolate mofetil	D	Mycophenolate embryopathy characterized by major fetal malformations and spontaneous miscarriages have been reported.

twice yearly infusions since with infrequent, self-limited seizures. She gave birth to a healthy, term baby boy at 38 weeks and 6 days with appearance, pulse, grimace, activity, and respiration (APGAR) scores of 9 at 1 and 5 minutes. He continues to do well at the 3-year follow-up.

Discussion

Fetal health was favorable throughout pregnancy despite the protracted illness course and use of highly teratogenic medications (Table 1). Although the acute phase of anti-NMDAR encephalitis averages 16 weeks, this is one of the longest illnesses reported in early pregnancy. The gestational age at which disease onset occurs is of particular significance because placental transfer of maternal antibodies begins at weeks 12–13 of pregnancy; it has been postulated that fetal exposure to NMDAR antibodies may cause harm; however, recent case series have found most infants exposed to NMDAR antibodies are healthy at birth with normal development.¹ Despite the duration and severity of disease in this patient, there were no adverse obstetrical outcomes; up to one-third of reported cases displays pathologic pregnancies, with spontaneous abortion and preterm birth occurring most frequently.¹

This case additionally reinforces the superior sensitivity of CSF over serum anti-NMDAR antibody testing. In refractory cases, following the CSF antibody titer may help guide therapy, with CSF titer changes more accurately reflecting relapse potential than serum titers.² In our case, the persistence of NMDAR CSF antibodies prompted additional therapy, despite prior aggressive immunosuppression.

Most notably, the use of cyclophosphamide during the second trimester for the treatment of anti-NMDAR encephalitis has yet to be reported. To date, cyclophosphamide use in pregnancy has been reported scarcely, with greatest frequency in malignancies and rheumatologic conditions. The literature presents conflicting data; many case reports reflect adverse pregnancy outcomes including preterm birth and fetal loss, whereas others mirror our experience with normal fetal development and birth.^{3,4} This likely reflects a myriad of factors, including underlying disease process, gestational age at exposure, and dose of or prior exposure to cyclophosphamide. Rituximab exposure in pregnancy is more frequently reported, with no significant increase in obstetric complications or fetal malformations compared with normative data.^{1,5} Neonatal lymphopenia may occur at birth; however, cell counts recover within 6 months, and no infectious complications are cited.⁶ Ultimately, the use of second-line therapies during pregnancy for the treatment of anti-NMDAR encephalitis remains an individualized decision with significant potential risk. Although the generally accepted standard of care for second-line therapy in nonpregnant individuals includes rituximab and cyclophosphamide, the relative risk-to-benefit ratio in pregnant women is incompletely understood and requires further study.

Study Funding

The authors report no targeted funding.

Disclosure

S. Fredrich's fellowship was funded by the National Multiple Sclerosis Society. She has served as a consultant to EMD Serono. C. Wang and R. Narayan report no disclosures. L. Tardo's fellowship was funded by the National MS Society. K. Blackburn's fellowship was funded by the Siegel Rare Neuroimmune Association. S. Vernino has served as a consultant to Alterity, Genentech, Catalyst and Sage Therapeutics. He has received research support from Dysautonomia International, BioHaven, Grifols, and Quest Diagnostics (through a licensing contract). Go to Neurology.org/NN for full disclosures.

Publication History

Received by *Neurology: Neuroimmunology & Neuroinflammation* February 9, 2022. Accepted in final form April 25, 2022. Submitted and externally peer reviewed. The handling editor was Josep O. Dalmau, MD, PhD, FAAN.

Appendix Authors

Name	Location	Contribution
Sarah Fredrich, MD	Department of Neurology, University of Texas Southwestern Medical Center, Dallas, TX	Drafting/revision of the manuscript for content, including medical writing for content; Analysis or interpretation of data
Cynthia Wang, MD	Department of Neurology, University of Texas Southwestern Medical Center, Dallas, TX	Drafting/revision of the manuscript for content, including medical writing for content; Major role in the acquisition of data

Continued

Appendix (continued)

Name	Location	Contribution
Ram Narayan, MD	Department of Neurology, Barrow Neurological Institute, Phoenix, AZ	Major role in the acquisition of data
Lauren Tardo, MD	Department of Neurology, University of Texas Southwestern Medical Center, Dallas, TX	Drafting/revision of the manuscript for content, including medical writing for content; Major role in the acquisition of vdata
Kyle M. Blackburn, MD	Department of Neurology, University of Texas Southwestern Medical Center, Dallas, TX	Drafting/revision of the manuscript for content, including medical writing for content; Major role in the acquisition of data; Study concept or design; Analysis or interpretation of data

Appendix (continued)

Name	Location	Contribution
Steven Vernino, MD, PhD	Department of Neurology, University of Texas Southwestern Medical Center, Dallas, TX	Drafting/revision of the manuscript for content, including medical writing for content; Study concept or design

References

1. Joubert B, Garcia-Serra A, Planagumà J, et al. Pregnancy outcomes in anti-NMDA receptor encephalitis: case series. *Neurol Neuroimmunol Neuroinflamm*. 2020;7(3):e668.
2. Gresa-Arribas N, Titulaer MJ, Torrents A, et al. Antibody titres at diagnosis and during follow-up of anti-NMDA receptor encephalitis: a retrospective study. *Lancet Neurol*. 2014;13(2):167-177.
3. Lannes G, Elias FR, Cunha B, et al. Successful pregnancy after cyclophosphamide therapy for lupus nephritis. *Arch Gynecol Obstet*. 2011;283(1):61-65.
4. Clowse ME, Magder L, Petri M. Cyclophosphamide for lupus during pregnancy. *Lupus*. 2005;14(8):593-597.
5. Maddow-Zimet I, Kost K. *Pregnancies, Births and Abortions in the United States, 1973-2017: National and State Trends by Age*. Guttmacher Institute, 2021. doi: <https://doi.org/10.1363/2020.31952>.
6. Klink DT, Van Elburg RM, Schreurs MWJ, van Well GTJ. Rituximab administration in third trimester of pregnancy suppresses neonatal B-cell development. *Clin Dev Immunol*. 2008;2008:271363.