

Optimizing indications and technique in osteotomies around the knee

Andrea Ferrera¹ and Jacques Menetrey^{2,3}

¹Department of Orthopaedic and Traumatology, Orthopaedic and Trauma Centre, Turin, Italy

²Centre de Médecine du Sport et de l'Exercice (CMSE), Swiss Olympic Medical Center, Hirslanden Clinique La Colline, Geneva, Switzerland

³Division of Orthopaedic Surgery, University Hospital of Geneva, Geneva, Switzerland

Correspondence should be addressed to A Ferrera

Email
aferrera.orthotrauma@gmail.com

- Osteotomies around the knee represent a valid surgical treatment in young active patients affected by unicompartmental osteoarthritis and/or knee ligament instability.
- This review article describes the main osteotomies performed around the knee and their optimization, with particular attention to indications and surgical technique in light of the most recent literature and author experience.
- Further developments have to be expected from technological advances, focusing particularly on surgical planning and the control of intraoperative deformity correction by pre-shaped cutting blocks.

Keywords

- ▶ instructional lecture
- ▶ osteotomies
- ▶ knee

EFORT Open Reviews
(2022) 7, 396–403

Introduction

The history of osteotomies starts in the 16th century, but the real development of these techniques has improved between the 19th and 21st centuries, to become the gold standard treatment for the unicompartmental osteoarthritis of the knee. The growth of arthroplasty surgery and the subsequent technologic development of new, reliable and better performing prostheses, mostly implanted in elderly patients with low function, led to a progressive loss of interest for osteotomies. However, over the years, studies (1) underlined unsatisfactory clinical results for knee arthroplasties in more active and sportive patients. In this setting, osteotomies made their comeback in the therapeutic arsenal of unicompartmental osteoarthritis. Indications were better tailored to patients (Fig. 1 and Table 1), and techniques were furthermore developed and making the degree of correction more reliable. Advanced development of fixation plates and modern postoperative rehabilitation protocols have made osteotomies more attractive.

The purpose of this review article is to describe the main osteotomies around the knee and how to optimize their indications and surgical techniques in light of the most recent literature and authors' experience.

Proximal tibial osteotomies

Proximal tibial osteotomy (PTO) is a cornerstone procedure in the treatment of medial compartment osteoarthritis in

a varus knee, in which weight-bearing forces are mostly transmitted across the medial tibiofemoral compartment, leading to eventual and progressive damage to the articular cartilage and the subchondral bone. The aim of this procedure is to shift the mechanic axis of the knee, leading to a decreased area of contact and progressive unloading of the affected compartment. Finally, the objectives are to reduce pain for the patients, increase their function, delay the progression of medial arthrosis and the need for knee replacement surgery.

Indications

The ideal candidate for PTO is a young patient (<65 years), moderately active, with medial isolated osteoarthritis, malalignment <15°, tibial bone varus angle >5° and a minimum range of motion >90° of flexion on the affected knee. Relative contraindications are age >65 years, impaired range of motion with <90° of flexion and ≥15° of flexion contracture, ≥20° of correction and rheumatoid or inflammatory arthritis. PTO should be considered on an individual basis. Non-suitable patients are obese (BMI >30) and patients with bicompartamental arthritis or with previous lateral meniscectomy (2). Smoking plays a negative role especially as it may interfere with bone healing in open-wedge PTO and may cause nonunion.

Instability used to be a contraindication in PTO, but nowadays sagittal and coronal alignment modification through this surgical technique may represent a useful solution in a patient with anterior cruciate ligament (ACL)

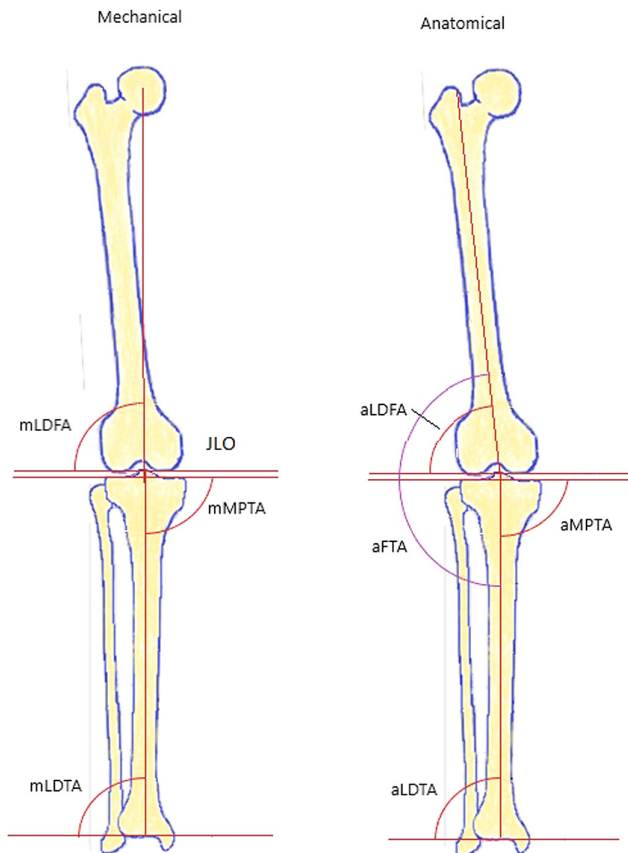


Figure 1
Lower limb angles.

rupture and posterolateral corner injuries (PLC). Varus deformity results in the tensile force on ACL to increase, and a varus alignment $>5^\circ$ is recognized as a risk factor for failure of ACL reconstruction. Nowadays, PTO might be performed, if degenerative changes occur, in patients with varus knee plus ACL rupture in the absence of dynamic instability on weight-bearing lateral radiographs. ACL reconstruction may be combined with PTO or performed as a second surgical stage, usually in patients with painful instability combined with medial degenerative changes in a varus knee (3).

Table 1 Physiological joint angles.

Joint angles	Acronym	Standard values
Anatomical femorotibial angle	aFTA	173–175°
Anatomical mechanical femoral angle	aMDFA	6 ± 1°
Anatomical lateral distal femoral angle	aLDFA	81 ± 2°
Mechanical lateral distal femoral angle	mLDFA	87 ± 3°
Anatomical medial proximal tibial angle	aMPTA	87 ± 3°
Mechanical medial proximal tibial angle	mMPTA	87 ± 3°
Anatomical lateral distal tibial angle	aLDTA	89 ± 3°
Mechanical lateral distal tibial angle	mLDTA	89 ± 3°
Joint line obliquity	JLO	0–4°
Posterior tibial slope	PTS	5–7°

Chronic PLC laxity leads to a decreased ability for withstanding a loading stress applied to the knee and varus alignment worsens this situation. Therefore, according to Arthur *et al.* (4), correction of the varus alignment through PTO alone can result in better knee stability and good clinical outcomes, while only 38% of their cohort needed a second stage procedure consisting of ligament reconstruction.

Techniques

Many PTO techniques have been developed and used in history, but today, opening- and closing-wedge osteotomy are the most commonly used (see Table 2). In the lateral closing-wedge technique, correction is achieved by removing a bone wedge from the lateral tibia, retaining the hinge and closing the gap. It has been widely used in the past for its high rate of consolidation, but progressively lost part of its popularity due to some disadvantages, such as shortening of the leg, the need for fibular osteotomy, the interruption of proximal tibiofibular joint and the risk of peroneal nerve injury. On the other hand, in the medial open-wedge technique, a single line osteotomy is performed respecting a lateral hinge and a progressive opening is realized until the planned wedge and degree of correction are reached. The site is then fixed with a plate and might be filled with a bone graft. This technique preserves the bone stock, but it affects the position of the patella and it carries the disadvantage of a possible nonunion. Besides, the open-wedge technique might be performed in multiple planes: biplanar osteotomies are performed when an additional cut is made at the anterior third of the tibia behind the anterior tibial tubercle (ATT) at about 110° of the horizontal osteotomy. With this method, the tibia is prevented from rotating around the vertical axis and it creates an anterior buttress against sagittal movements. Moreover, this results in a higher surface of bone contact, enhancing the possibility of a good and rapid consolidation.

In the planning of a PTO, patellar height and eventual leg length discrepancy should be critically determined, since the biplanar open-wedge technique results in a distalization of the patella and an increase in the leg length. We know that the patella height will decrease approximately 2 mm per 10° of valgus correction (2). One solution would be to orient the oblique osteotomy cut distally to the ATT, and fix it with one or two bicortical screws. This may be indicated in patients requiring a correction of more than 10° and/or in patients with a preexisting patella infera. Regarding leg length discrepancy, a close-wedge osteotomy may be better indicated in patients with a discrepancy of more than 1.5 cm in favor of the operated leg.

Triplanar osteotomy might be suitable for patients with a posterior cruciate ligament (PCL) injury associated

Table 2 Advantages and disadvantages of opening-wedge and closing-wedge PTO.

Opening-wedge osteotomy	Closing-wedge osteotomy
<p>Advantages</p> <ul style="list-style-type: none"> Accurate procedure, precise deformity correction Preservation of proximal tibiofibular anatomy Avoid peroneal nerve damage Preservation of proximal tibia bone stock Easier conversion to TKR Multiplanar correction No leg shortening <p>Disadvantages</p> <ul style="list-style-type: none"> Usually require bone grafting Slower consolidation Nonunion risk Changes in tibial slope and patella height 	<ul style="list-style-type: none"> Faster consolidation No bone graft required <ul style="list-style-type: none"> Disruption of proximal tibiofibular anatomy Reduced proximal tibial bone stock Difficult to adjust precisely deformity correction Peroneal nerve damage risk Shortening of the leg Monoplanar correction

with a varus knee, with a tibial slope of less than 9° (5). Indeed, an increase of the tibial slope may easily be performed concomitantly to an open-wedge PTO. Likewise, an ACL-deficient knee with a varus deformity and high tibial slope (9–12°) may benefit from a close-wedge osteotomy since the tibial slope tends to decrease in this technique (6). In case of a combined ACL+PTO procedure, the osteotomy must be performed first, positioning of the anterior proximal screws should be done after drilling of the tibial tunnel and passage of the graft. However, it’s still unclear if an advantage in a combined HTO+ACL reconstruction exists, compared to HTO alone (7).

Finally, the postoperative degree of correction is still a matter of debate. In the recent literature, an individualized postoperative correction is suggested, rather than a correction to the Fujisawa area (62–68% of the lateral tibia width). For example, some authors proposed a correction to 55% tibial width (1.7–2° mechanical valgus) (8) to balance medial and lateral loading stress, while others suggest a hypercorrection to a mechanical axis of 4.5° in valgus, to better distribute stress among the two compartments (9). The authors usually pursue a tailor-made correction, in patients with osteoarthritis, the postoperative axis should be in the Fujisawa area, while for PTO associated with cartilage or meniscus procedures, we usually plan for a mechanical axis of 0–3° valgus.

There is still a large opportunity for improvement in osteotomies including further development in navigation systems, especially to navigate the tibial slope, control the joint line obliquity and the precision of the correction in double level osteotomies. Preoperative 3D-CT scan planning resulting in individualized cutting blocks and customized plates may improve the reliability and the precision of the osteotomy, as well as facilitate its realization. Those techniques are still in development and their performances are still under investigation.

Distal femur osteotomies

Distal femur osteotomy (DFO) is a well-known surgical procedure used to correct the valgus deformity, that might be also post-traumatic or due to growth disorders, in young active patients with lateral compartment arthrosis or cartilage damage. In this case, the goals are to unload the lateral compartment in order to decrease pain and osteoarthritis progression. Valgus deformity is less frequent than varus, so not so many papers are published on DFO postoperative outcomes. However, surgeons must keep in mind that valgus malalignment is not only represented by a femoral-based deformity. In fact, recent studies highlighted that the malalignment may be due to a tibial-based or a combined femoral and tibial deformity (10).

Indications

Ideal candidate for a DFO procedure should be younger than 65 years, active, with a valgus deformity, affected by isolated lateral compartment osteoarthritis. Candidates should have a preoperative extension/flexion 0–120° range of motion with a normal BMI. Poor postoperative outcomes are related to BMI >30, nicotine abuse and severe patellofemoral osteoarthritis, which some authors consider a relative contraindication for the DFO procedure. Other contraindications to this procedure are severe lateral compartment involvement (Ahlback >III), medial compartment or tricompartmental osteoarthritis, as well as poorly controlled chronic inflammatory arthritis and osteoporosis. Valgus deformity greater than 20° are considered a contraindication to DFO as it can be associated with severe ligamentous instability (11).

DFO can be indicated in patients affected by chondral lesions of the lateral compartment in a valgus knee, in order to achieve correction of the malalignment and protection of the chondral repair. Cartilage treatment can be combined at the same time as the correction of the deformity, whereas deformities due to growth disorders

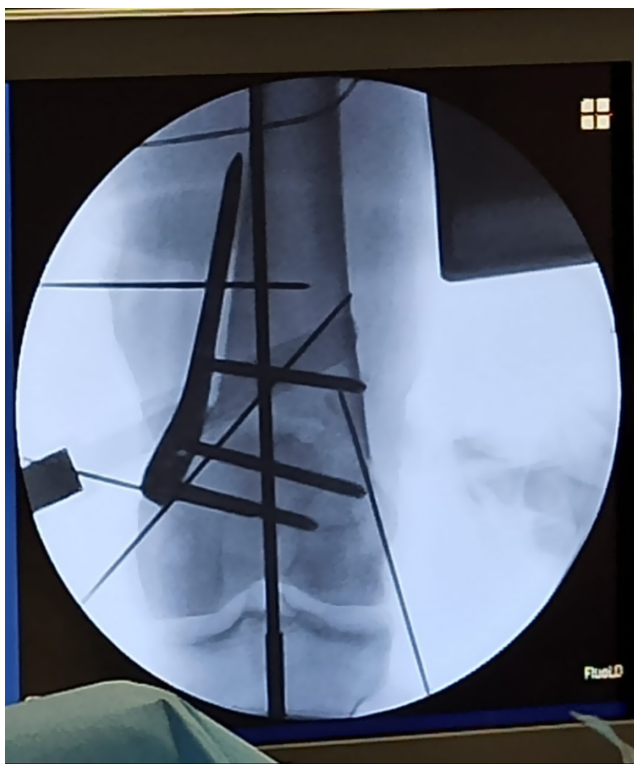

Figure 2
Medial open-wedge distal femoral osteotomy.

or post-traumatic must be addressed, if possible, before the onset of the arthrosis. DFO might also be beneficial in young, sportive patients, even with initial stage of osteoarthritis, who need a concomitant lateral meniscus allograft transplantation, in order to offload the lateral compartment and the freshly implanted allograft.

In case of ligamentous instability, DFO can be performed as a standalone procedure or combined with a concomitant or staged ligament reconstruction. For example, some studies have analyzed the outcomes after lateral open-wedge DFO alone performed on valgus knee with MCL deficiency, showing a decrease of the medial opening at 30° of flexion. This could be considered in low-demand patients (12).

Techniques

DFO can be performed as a lateral open-wedge technique or as a medial close-wedge one (Fig. 2). In the first one, osteotomy is performed with an inclination of 20° from two to three fingers proximal to lateral epicondyle aiming at a point few millimeters proximal to the medial epicondyle, in order to remove a bony wedge of predefined dimension and gently opening the site in varus until the desired degree of correction is reached. The site is then fixed with plates and might be filled with bone graft. The medial hinge should be preserved by advancing the oscillating

saw no more than 1 cm away from the medial cortex, as it is more fragile and prone to fracture, resulting in collapsing of the osteotomy site and great difficulty in controlling the rotational stability (13). This procedure is technically more demanding, but allows an accurate correction and the restoration of the femoral height, especially in those patients requiring mild to large correction. On the other hand, the disadvantages of this procedure are represented by the danger of hinge fracture and the incidence of delayed union or nonunion of the osteotomy site. A study analyzed the biomechanics result of the femoral osteotomies, highlighting how the lateral open-wedge technique resulted in inferior stability and in lower stiffness compared to the close-wedge one. Therefore, a bone graft or substitute should be mandatory in order to enhance the biological healing. In the close-wedge technique, parallel pins are then driven in the cortex from the medial supracondylar area to the lateral condyle and the proximal part of the osteotomy is performed through the antero-posterior cortex, preserving the lateral one. The bone wedge is removed and the osteotomy site is closed and fixed, compressing the medial cortex. The conventional single plan osteotomy has been replaced by the biplanar technique, in which the osteotomies are performed in the posterior three-quarters of the femur and completed with an ascending cut performed on the anterior surface of the femur. This technique allows for a more distal positioning of the lateral hinge point, a wider contact of surface and more accurate control of the rotational stability. Finally, it enhances biological bone healing. Furthermore, studies reported no loss of correction in the follow-up examination and low incidence of nonunion. However, there is still an active debate about the indication to open- versus close-wedge surgical techniques. A recent systematic review (14) showed similar outcomes for the two procedures, with no difference in radiographic correction, bony healing or patient-reported outcomes.

Finally, postoperative correction is still a matter of debate, as many authors recommend a correction to the neutral alignment (50% WBL), but recent biomechanics studies (15) showed that a 5° of overcorrection restores near-normal contact pressure and contact area in the lateral compartment. In our experience, in single DFO, we usually favor biplanar medial closing-wedge osteotomy, unless there is a hypoplasia of the lateral condyle. In this situation, we rather go for a lateral opening-wedge osteotomy. Both osteotomies are fixed with a rigid plate and locked screws.

Double level osteotomies

Generally, PTO alone is the preferred surgical procedure for varus deformity correction, and good outcomes are

reported in the literature, but varus malalignment might be the result of a deformity located on the tibia, the femur or a combination of the two. Nowadays, more awareness has been raised in addressing surgery, especially in patients with severe varus deformity. In fact, it was reported that isolated PTO in severe varus deformity, which require a large correction, might result in an excessive lateral obliquity of the joint line (JLO) (Fig. 3), creating a new deformity (16). This may lead to increased shear contact on cartilages, potential femoral subluxation and subsequent difficulties in total knee replacement conversion. In this setting, double level osteotomy (DLO) became very popular as it gathers the advantages to unload the affected compartment without causing non-physiologic joint line angles. Still, the patellofemoral involvement is a matter of discussion as there is a lack of information about changes that DLO causes on patella height and patellofemoral alignment.

Indications

The ideal candidates for a DLO are patients affected by a varus axial deformity, which correction at one level, would create a non-physiological deviation of the joint line. If during preoperative PTO planning the Mechanical medial proximal tibial angle (mMPTA) is more than 95°, lateral distal femoral angle >90° and the planned bone wedge size is >15 mm, then DLO should be considered. Those indications come from studies that highlighted how a postoperative mMPTA greater than 95° leads to inferior

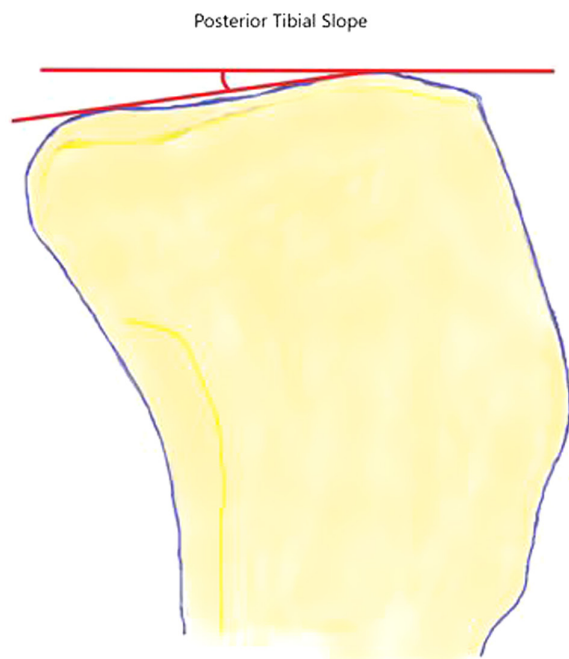


Figure 3
Posterior tibial slope.

clinical outcomes, increased medial joint stress and higher failure rates. Other good candidates are patients with deformity both in the femur and in the tibia with mMPTA <85° and mechanical lateral distal femoral angle >90°, affected by medial compartment osteoarthritis (16). Furthermore, patients with pre-existent joint line obliquity, such as a patient who underwent epiphysiodesis or previous osteotomy, could be addressed with this procedure.

Techniques

In order to treat a varus deformity with a DLO, a lateral close-wedge femoral osteotomy has to be combined with a medial open-wedge tibial osteotomy. The surgical techniques performed are the same as aforementioned for open-wedge PTO and closed-wedge DFO. Surgery should start from the DFO close-wedge procedure, in order to save a bony wedge that could be used as a filling graft in the PTO open-wedge procedure, and thus enhance bone healing. A further potential advantage of performing the open-wedge as a second step is that surgeons can perform a refined intraoperative adjustment of the leg axis (17). This is possible by correcting the deformity on the femoral side in order to reach a horizontal JLO and then addressing the varus deformity with the tibial osteotomy. The combination of close-wedge femoral osteotomy and open-wedge tibial osteotomy prevents leg length discrepancy as well. Nowadays, no consensus has been reached over the ideal postoperative alignment and joint line orientation. Some authors perform a slight overcorrection with a mean mTFA postoperative of 0.8°, while others aim for a 2–3° of mTFA (18). In our experience, we suggest correcting the deformity present on the distal femur, followed by the correction of the constitutional varus +3 to 5° according to the global correction to be planned.

Slope-changing osteotomies

ACL or PCL reconstruction might fail due to extrinsic factors, related to surgical technique errors or inadequate rehabilitation, and intrinsic factors related to patient anatomy and ligament structures. Surgeons must identify and address the causes of ACL or PCL primary reconstruction failure in order to plan a successful revision surgery. Among these factors, particular attention must be paid to the posterior tibial slope (PTS). Studies underlined that an excessive PTS is likely to increase the anterior translation of the tibia while weight bearing, causing anterior instability and therefore increasing the stress tensile forces on the ACL graft. In the literature, some authors have shown that patients with a PTS greater than 12° had five times higher odds of ACL injury and a 59% incidence of graft re-tear (19). On the other hand,

a reduced PTS increases the posterior tibial translation in both flexion and extension, leading again to high-stress tensile forces across native or reconstructed PCL that might result in graft failure. A decreased PTS has been identified as the predominant cause of genu recurvatum as well.

Indications

Anterior closed-wedge osteotomy (ACWO) can be performed in patients with recurrent ACL reconstruction failures associated with a PTS greater than 12° . Contraindications to this procedure are severe malalignment of more than 10° varus, more than 10° knee hyperextension and evidence of grade IV Kellgren–Lawrence osteoarthritis. Relative contraindications involve obese patients and heavy smokers.

Anterior open-wedge osteotomy (AOWO) can be performed in patients with symptomatic PCL deficiency and an evident sagittal tibial malalignment caused by decreased PTS. A recent article (20) suggests considering AOWO in patients undergoing PCL reconstruction with a PTS $<5^\circ$ and a PTS $<7^\circ$ in patients undergoing PCL revision. In the case of genu recurvatum, Dejour *et al.* (21) stated that an absolute indication is represented by the combination of bony and soft tissue recurvatum which might be addressed by osteotomy alone or by soft tissue reconstructive procedures. AOWO might be indicated if the recurvatum is due to a decreased PTS and if the patient complains of pain or instability, and it can only be performed in skeletally mature individuals. AOWO is contraindicated in patients with deformity secondary to poliomyelitis, as this would create more knee instability, and in patients with pure soft tissue recurvatum.

Techniques

ACWO is a surgical procedure in which an anterior bony wedge is removed by the tibia in order to decrease the PTS by closing the osteotomy site. It might be performed with different techniques and different osteotomy positions, below, above or at the same level of the ATT. Dejour *et al.* and Walker *et al.* (22) described an osteotomy technique above the ATT, starting from the superior margin of patellar tendon and securing the osteotomy site with two staples. This technique should not be performed in a patient with patella alta, as it might worsen the patella tracking biomechanics. Sonnery-Cottet *et al.* first described an osteotomy technique below the ATT, involving a 6-cm ATT osteotomy and subsequent synthesis with two cortical screws (23), while Hees and Petersen modified the technique, avoiding the ATT detachment (24). All techniques require a good exposure on both sides of the tibia and perfect symmetry in the closing-wedge osteotomy, which may be checked by ensuring that two guide wires lie parallel to the joint line. The two converging guide wires, which define the

osteotomy limits, should be driven aiming at the posterior cortex, just 1 cm below the PCL tibial insertion, without violating the posterior hinge. If a combination of ACWO and ACL revision is planned, the autograft harvesting must be performed as a first step and the fixation system should not interfere with the creation of the tibial tunnel. Studies (24) demonstrated good outcomes with postoperative PTS less than $<10^\circ$, authors suggest that postoperative correction should be ideally in the $6\text{--}8^\circ$ range.

In AOWO, an anterior tibial bony line is cut and progressively opened in order to achieve an increased PTS. As ACWO, osteotomies might be performed above, below or at the same level as the ATT (25). The most used surgical technique is the one described by Lecuire *et al.* (26) in which a prior 6–8 cm tangential ATT osteotomy is performed, followed by the cut of the osteotomy line under the ATT, then the opening of the wedge at the planned correction is made. The guide pins must be positioned at the tibial insertion of the PCL and the posterior hinge should not be damaged. Surgeons must pay attention to be perfectly symmetrical in the opening of the wedge, the osteotomy site can be filled with bony graft and the ATT should be proximalized based on the correction achieved to avoid a patella infera. Posterior knee laxity should be then reassessed after the fixation in order to address the need for PCL reconstruction or not.

Anterior tibial tubercle osteotomies

Transposition of the ATT is performed alone or in combination with other surgical procedures in a wide range of patellofemoral pathologies, such as patellar instability, osteoarthritis and overload syndromes. Patellofemoral joint kinematics and stability depend on both soft tissue restraints and bone morphology. For example, important varus or valgus deformity will affect the tracking and the patellar stress contact area, leading, for example, to overload syndromes.

Indications

In the case of patella instability, surgical procedures are indicated when the instability becomes persistent and the patient has suffered from two to three episodes of dislocation. In this setting, the surgeons must assess and recognize all the potential factors that caused or facilitated the dislocation. Amongst the four risk factors described by Dejour *et al.* (27), abnormal tibial tubercle-trochlear groove index (TT-TG) should be systematically appreciated and corrected through an osteotomy of the ATT. Increase TT-TG might also be caused by excessive tibial rotation, femoral anteversion, valgus and recurvatum deformity. It is therefore important to define the greater TT-TG in a reliable manner to prevent the creation of an iatrogenic

painful overload of the medial compartment consecutive to the osteotomy. Osteotomy of the ATT might also be helpful in asymmetrical patellofemoral osteoarthritis with an abnormal TT-TG. This osteotomy is usually associated with a facetectomy of the lateral portion of the patella.

Techniques

If the TT-TG value is >20 mm measured on CT or >13 mm on MRI, a tibial tubercle medialization is suggested, as it decreases the valgus force exerted by the extensor mechanism. The aim should be the restoration of a TT-TG between 10 and 15 mm. In the case of patella alta (Caton-Deschamps >1.2) with a short patellar tendon, a tibial tubercle distalization is advised, aiming to restore the normal value and to obtain a better patellar tracking. In the case of a hypoplastic medial facet of the trochlea (type C), a tibial tubercle distalization of 5 mm and an optional medialization could be performed to enhance the patellar tracking. Surgeons must take into account that during ATT distalization of 1 cm, a subsequent 4 mm medialization will occur. Lateral retinaculum lengthening should be performed only if the tightness of lateral restraints causes a negative patellar tilt test. Medial patellofemoral ligament (MPFL) reconstruction should be frequently added to reduce the failure rate of the aforementioned procedures.

Conclusions

- Osteotomies around the knee represent a highly reliable and reproducing treatment option for knee pathology with very successful postoperative outcomes.
- Surgeons must be aware of the appropriate indications, accurate planning and use of reproducible surgical techniques.
- Further development in software, 3D-based technology and navigation systems might be promising in order to improve the accuracy of planning and intraoperative correction.

ICMJE Conflict of Interest Statement

The authors declare that there is no conflict of interest that could be perceived as prejudicing the impartiality of the research reported.

Funding Statement

This work did not receive any specific grant from any funding agency in the public, commercial or not-for-profit sector.

References

1. Belsey J, Yassen SK, Jobson S, Faulkner J & Wilson AJ. Return to physical activity after high tibial osteotomy or unicompartmental knee arthroplasty: a systematic review and pooling data analysis. *American Journal of Sports Medicine* 2021 **49** 1372–1380. (<https://doi.org/10.1177/0363546520948861>)

2. Gao L, Madry H, Chugaev DV, Denti M, Frolov A, Burtsev M, Magnitskaya N, Mukhanov V, Neyret P, Solomin LN, et al. Advances in modern osteotomies around the knee: report on the Association of Sports Traumatology, Arthroscopy, Orthopaedic Surgery, Rehabilitation (ASTAOR) Moscow International Osteotomy Congress 2017. *Journal of Experimental Orthopaedics* 2019 **6** 9. (<https://doi.org/10.1186/s40634-019-0177-5>)

3. Snow M, Jermain P, Mandalia V, Murray J, Khakha R, McNicholas M, Dawson M & UK Knee Osteotomy consensus Group. A 2021 consensus statement on osteotomies around the knee by the UK Knee Osteotomy Consensus Group (KOG). *Knee* 2021 **33** 73–83. (<https://doi.org/10.1016/j.knee.2021.08.034>)

4. Arthur A, LaPrade RF & Agel J. Proximal tibial opening wedge osteotomy as the initial treatment for chronic posterolateral corner deficiency in the varus knee: a prospective clinical study. *American Journal of Sports Medicine* 2007 **35** 1844–1850. (<https://doi.org/10.1177/0363546507304717>)

5. LaPrade CM, Civitaresse DM, Rasmussen MT & LaPrade RF. Emerging updates on the posterior cruciate ligament: a review of the current literature. *American Journal of Sports Medicine* 2015 **43** 3077–3092. (<https://doi.org/10.1177/0363546515572770>)

6. Ducat A, Sariali E, Lebel B, Mertl P, Hermigou P, Flecher X, Zayni R, Bonnin M, Jalil R, Amzallag J, et al. Posterior tibial slope changes after opening- and closing-wedge high tibial osteotomy: a comparative prospective multicenter study. *Orthopaedics and Traumatology, Surgery and Research* 2012 **98** 68–74. (<https://doi.org/10.1016/j.otsr.2011.08.013>)

7. Klek M & Dhawan A. The role of high tibial osteotomy in ACL reconstruction in knees with coronal and sagittal plane deformity. *Current Reviews in Musculoskeletal Medicine* 2019 **12** 466–471. (<https://doi.org/10.1007/s12178-019-09589-9>)

8. Fujisawa Y, Masuhara K & Shiomi S. The effect of high tibial osteotomy on osteoarthritis of the knee. An arthroscopic study of 54 knee joints. *Orthopedic Clinics of North America* 1979 **10** 585–608. ([https://doi.org/10.1016/S0030-5898\(20\)30753-7](https://doi.org/10.1016/S0030-5898(20)30753-7))

9. Trad Z, Barkaoui A, Chafra M & Tavares JMR. Finite element analysis of the effect of high tibial osteotomy correction angle on articular cartilage loading. *Proceedings of the Institution of Mechanical Engineers, Part H* 2018 **232** 553–564. (<https://doi.org/10.1177/0954411918770706>)

10. Eberbach H, Mehl J, Feuch MJ, Bode G, Südkamp NP & Niemeyer P. Geometry of the valgus knee: contradicting the dogma of a femoral-based deformity. *American Journal of Sports Medicine* 2017 **45** 909–914. (<https://doi.org/10.1177/0363546516676266>)

11. Rosso F & Margheritini F. Distal femoral osteotomy. *Current Reviews in Musculoskeletal Medicine* 2014 **7** 302–311. (<https://doi.org/10.1007/s12178-014-9233-z>)

12. Hetsroni I, Lyman S, Pearle AD & Marx RG. The effect of lateral opening wedge distal femoral osteotomy on medial knee opening: clinical and biomechanical factors. *Knee Surgery, Sports Traumatology, Arthroscopy* 2014 **22** 1659–1665. (<https://doi.org/10.1007/s00167-013-2405-3>)

13. Winkler PW, Rupp MC, Lutz PM, Geyer S, Forkel P, Imhoff AB & Feucht MJ. A hinge position distal to the adductor tubercle minimizes the risk of hinge fractures in lateral open wedge distal femoral osteotomy. *Knee Surgery, Sports Traumatology, Arthroscopy* 2021 **29** 3382–3391. (<https://doi.org/10.1007/s00167-020-06244-6>)

14. Wylie JD, Jones DL, Hartley MK, Kapron AL, Krych AJ & Aoki SK. Distal femoral osteotomy for the valgus knee: medial closing wedge versus lateral opening wedge: a systematic review arthroscopy. *Arthroscopy: Journal of Arthroscopic and Related Surgery* 2016 **32** 2141–2147.

15. Quirno M, Campbell KA, Singh B, Hasan S, Jazrawi L, Kummer F & Strauss EJ. Distal femoral varus osteotomy for unloading valgus knee malalignment: a

biomechanical analysis. *Knee Surgery, Sports Traumatology, Arthroscopy* 2017 **25** 863–868. (<https://doi.org/10.1007/s00167-015-3602-z>)

16. Feucht MJ, Winkler PW, Mehl J, Bode G, Forkel P, Imhof AB & Lutz PM. Isolated high tibial osteotomy is appropriate in less than two-thirds of varus knees if excessive overcorrection of the medial proximal tibial angle should be avoided. *Knee Surgery, Sports Traumatology, Arthroscopy* 2021 **29** 3299–3309. (<https://doi.org/10.1007/s00167-020-06166-3>)

17. Iseki T, Onishi S, Kanto M, Kanto R, Kambara S, Yoshiya S, Tachibana T & Nakayama H. Double-level osteotomy for severe varus osteoarthritic knees can prevent change in leg length and restore physiological joint geometry. *Knee* 2021 **31** 136–143. (<https://doi.org/10.1016/j.knee.2021.04.011>)

18. Alves P, van Rooij F, Kuratle T, Safarini M & Miozzari H. Consistent indications, targets and techniques for double-level osteotomy of the knee: a systematic review. *Knee Surgery, Sports Traumatology, Arthroscopy* 2022 In press. (<https://doi.org/10.1007/s00167-022-06915-6>)

19. Klek M & Dhawan A. The role of high tibial osteotomy in ACL reconstruction in knees with coronal and sagittal plane deformity. *Current Reviews in Musculoskeletal Medicine* 2019 **12** 466–471. (<https://doi.org/10.1007/s12178-019-09589-9>)

20. Kanakamedala AC, Gipsman A, Lowe DT, Strauss EJ & Alaia MJ. Combined anterior opening-wedge high tibial osteotomy and tibial tubercle osteotomy with posterior cruciate ligament reconstruction. *Arthroscopy Techniques* 2022 **11** e601–e608.

21. Dejour D, Bonin N & Locatelli E. Tibial antirecurvatum osteotomies. *Operative Techniques in Sports Medicine* 2000 **8** 67–70. ([https://doi.org/10.1016/S1060-1872\(00\)80028-3](https://doi.org/10.1016/S1060-1872(00)80028-3))

22. Dejour D, Saffarini M, Demey G & Baverel L. Tibial slope correction combined with second revision ACL produces good knee stability and prevents graft rupture. *Knee Surgery, Sports Traumatology, Arthroscopy* 2015 **23** 2846–2852. (<https://doi.org/10.1007/s00167-015-3758-6>)

23. Sonnery-Cottet B, Mogos S, Thaunat M, Archbold P, Fayard JM, Freychet B, Clechet J & Chambat P. Proximal tibial anterior closing wedge osteotomy in repeat revision of anterior cruciate ligament reconstruction. *American Journal of Sports Medicine* 2014 **42** 1873–1880. (<https://doi.org/10.1177/0363546514534938>)

24. Hees T & Petersen W. Anterior closing-wedge osteotomy for posterior slope correction. *Arthroscopy Techniques* 2018 **7** e1079–e1087. (<https://doi.org/10.1016/j.eats.2018.07.003>)

25. Vadhera AS, Knapik DM, Gursoy S, Farviar D, Perry AK, Cole BJ & Chahla J. Current concepts in anterior tibial closing wedge osteotomies for anterior cruciate ligament deficient knees. *Current Reviews in Musculoskeletal Medicine* 2021 **14** 485–492. (<https://doi.org/10.1007/s12178-021-09729-0>)

26. Lecuire F, Lerat JL, Bousquet G, Dejour H & Trillat A. The treatment of genu recurvatum (author's transl). *Revue de Chirurgie Orthopédique et Réparatrice de l'Appareil Moteur* 1980 **66** 95–103.

27. Dejour DH, Giovannetti de Sanctis GME & Giovannetti de Sanctis E. Updated treatment guidelines for patellar instability: 'un menu à la carte'. *Journal of Experimental Orthopaedics* 2021 **8** 109. (<https://doi.org/10.1186/s40634-021-00430-2>)