



Since January 2020 Elsevier has created a COVID-19 resource centre with free information in English and Mandarin on the novel coronavirus COVID-19. The COVID-19 resource centre is hosted on Elsevier Connect, the company's public news and information website.

Elsevier hereby grants permission to make all its COVID-19-related research that is available on the COVID-19 resource centre - including this research content - immediately available in PubMed Central and other publicly funded repositories, such as the WHO COVID database with rights for unrestricted research re-use and analyses in any form or by any means with acknowledgement of the original source. These permissions are granted for free by Elsevier for as long as the COVID-19 resource centre remains active.



Case Report

Coronavirus disease (COVID-19) associated delayed-onset fulminant myocarditis in patient with a history of severe acute respiratory syndrome coronavirus 2 (SARS-CoV-2) infection

Hiroyasu Ishikura^{a,*}, Junichi Maruyama^a, Kota Hoshino^a, Yuta Matsuoka^a, Masaya Yano^a, Tadaaki Arimura^b, Harutaka Katano^c, Seiya Kato^d, Taisuke Kitamura^a, Yoshihiko Nakamura^a

^a Department of Emergency and Critical Care Medicine, Fukuoka University Hospital, 7-45-1 Nanakuma, Jonan-ku, Fukuoka, 814-0180, Japan

^b Department of Internal Medicine, Cardiology, Fukuoka University Hospital, 7-45-1 Nanakuma, Jonan-ku, Fukuoka, 814-0180, Japan

^c Department of Pathology, National Institute of Infectious Diseases, 1-23-1 Toyama, Shinjuku-ku, Tokyo, 162-8640, Japan

^d Division of Pathology, Saiseikai Fukuoka General Hospital, 1-3-46 Tenjin, Chuo-ku, Fukuoka, 810-0001, Japan



ARTICLE INFO

Keywords:

COVID-19

SARS-CoV-2

Fulminant myocarditis

Delayed-onset

Late-onset

ABSTRACT

A healthy 35-year-old man was admitted to a rural hospital with coronavirus disease (COVID-19). During 14 days of hospitalization, he had no symptoms and was not given supplemental oxygen. About 3 weeks after discharge, he was re-admitted to the same hospital with new-onset continuous fever and general weakness. At the time of his second admission, severe acute respiratory syndrome coronavirus-2 (SARS-CoV-2) RT-PCR was performed on a retro-nasal swab and the result was negative. Four days after admission, the patient was transferred to our intensive care unit (ICU) following deterioration of his respiratory and haemodynamic conditions, where he received mechanical ventilation, intra-aortic balloon pumping, and veno-arterial extracorporeal membrane oxygenation. A nasopharyngeal swab was obtained again at ICU admission, but RT-PCR was negative for SARS-CoV-2. All antibody titres measured against other viruses were low. Blood cultures were negative, and no bacteria were observed in sputum samples. However, SARS-CoV-2 RNA was detected by RT-PCR from sections obtained by myocardial biopsy. The patient's final diagnosis was delayed-onset SARS-CoV-2-induced fulminant myocarditis (FM). We strongly suggested that one of the proposed mechanisms of COVID-19-related myocardial injury will be the direct invasion of SARS-CoV-2 into cardiomyocytes even if delayed-onset. And this is the first case of delayed-onset FM in which diagnosis of active myocarditis was proven by pathological examination following endomyocardial biopsy and SARS-CoV-2 was detected in the myocardium by RT-PCR.

Authorship statement

All authors meet the ICMJE authorship criteria.

1. Introduction

At the end of 2019, an outbreak of pneumonia caused by severe acute respiratory syndrome coronavirus 2 (SARS-CoV-2) occurred in Wuhan, China. The outbreak rapidly spread across China and subsequently became a worldwide pandemic. The World Health Organization named the pandemic syndrome caused by SARS-CoV-2 coronavirus disease

2019 (COVID-19) [1].

It is now well established that many COVID-19 patients, especially those with severe disease, experience complications including acute respiratory distress syndrome (ARDS), shock, coagulation/fibrinolysis abnormalities, stroke, acute kidney injury, and acute cardiac injury [2]. And cardiovascular complications occur in 7.2% [2]. Thus, cardiovascular complications are not infrequent in COVID-19 patients. However, to date only elevated cardiac troponin I (TropI) levels and arrhythmia have been reported in COVID-19 patients, and no specific investigations of the effects of SARS-CoV-2 infection on the cardiovascular system have been conducted [3].

* Corresponding author.

E-mail addresses: ishikurah@fukuoka-u.ac.jp (H. Ishikura), marujun1025@icloud.com (J. Maruyama), hoshinoqq@yahoo.co.jp (K. Hoshino), ma20ka.yuta2017@gmail.com (Y. Matsuoka), masayano528@yahoo.co.jp (M. Yano), kirinnwine@yahoo.co.jp (T. Arimura), katano@nih.go.jp (H. Katano), seikato1014@gmail.com (S. Kato), taisukekitamura@gmail.com (T. Kitamura), pdmxy827@yahoo.co.jp (Y. Nakamura).

<https://doi.org/10.1016/j.jiac.2021.08.007>

Received 16 March 2021; Received in revised form 4 August 2021; Accepted 6 August 2021

Available online 12 August 2021

1341-321X/© 2021 Japanese Society of Chemotherapy and The Japanese Association for Infectious Diseases. Published by Elsevier Ltd. This is an open access

article under the CC BY-NC-ND license (<http://creativecommons.org/licenses/by-nc-nd/4.0/>).

Here, we describe the first case of delayed-onset fulminant myocarditis (FM) in which diagnosis of active myocarditis was proven by pathological examination following endomyocardial biopsy and SARS-CoV-2 was detected in the myocardium by RT-PCR over 3 weeks after complete recovery from COVID-19.

2. Case report

Seven days after onset of upper respiratory tract symptoms, a healthy 35-year-old man was consulted at a rural hospital. He had no medical history of cardiovascular disease or cardiovascular risk factors. He was diagnosed with COVID-19 after SARS-CoV-2 was detected by RT-PCR from a nasopharyngeal swab sample. He was admitted to the rural hospital. During admission, he denied chest pain, dyspnoea, and other symptoms, and was not given supplemental oxygen. He was discharged and returned home on the 14th day after admission.

About 3 weeks after discharge, he was re-admitted to the same hospital with new-onset continuous fever and general weakness. At his second admission, SARS-CoV-2 RT-PCR was performed on a retro-nasal swab and the result was negative. Four days after admission, he was transferred to our intensive care unit following a sudden deterioration in respiratory and hemodynamic conditions. On arrival to the ICU under mechanical ventilation, physical examination revealed a blood pressure of 73/34 mmHg (during administration of 0.3 μ g of noradrenaline and 2 units/hour of vasopressin by continuous intravenous injection), a heart rate of 147 bpm, and a body temperature of 36.6 °C. Arterial blood gas analysis showed oxygen partial pressure of 82 mmHg, carbon dioxide partial pressure of 32 mmHg, and a PaO₂/FiO₂ ratio of 166 (Fig. 1).

An electrocardiogram (Fig. 2A) revealed sinus tachycardia of 160 bpm and no ST-segment elevation in any leads. A transthoracic echocardiogram (Fig. 2B) revealed diffuse severe hypokinesia, severe left ventricular dysfunction (left ventricular ejection fraction of 7.4%) (Fig. 3A), and no evidence of valvular heart disease. Thoracic computed tomography (Fig. 2C) revealed no signs of SARS-CoV-2 pneumonia such as ground-glass changes, but dense opacity on both dorsal surfaces caused by compressive atelectasis. His blood leukocyte count was 18,600/ μ L (neutrophils 94.8%, eosinophils 0.1%, and lymphocytes 3.0%). Levels of blood cardiac biomarkers were elevated including creatine kinase (2254 U/L, normal range 59–248 U/L) (Fig. 3B), cardiac high-sensitivity troponin I (31,516 pg/mL, normal level \leq 30 pg/mL) (Fig. 3C), and brain-type natriuretic peptide (3905 pg/mL, normal level \leq 18.4 pg/mL). Blood levels of interleukin (IL)-6 were elevated at 533.3 pg/mL (normal level \leq 4.0 pg/mL); the highest level of IL-6 observed during his ICU stay was 593.3 pg/mL (Fig. 3D). In addition, creatinine (5.47 mg/dL), total bilirubin (1.7 mg/dL), and C-reactive protein (57.5

mg/dL) were elevated. Immediately after admission a percutaneous coronary intervention was performed and confirmed that the coronary arteries were normal, with no significant stenosis observed by coronary angiogram. Myocardial biopsy demonstrated diffuse lymphocyte infiltration in the interstitium of the myocardial tissue (Fig. 4A) as well as atrophy and shedding degeneration of myofibrils (Fig. 4B). No myocardial necrosis, giant cells, or eosinophilic infiltrates were observed by light microscopy. Finally, the patient was diagnosed with acute lymphocytic FM. Because of the ongoing COVID-19 pandemic, a nasopharyngeal swab was obtained but tested negative by RT-PCR for SARS-CoV-2. Antibody tests in the blood were performed using a rapid qualitative test kit (One Step Novel Coronavirus (COVID-19) IgM/IgG Antibody Test Kit, Artron Laboratories Inc., Burnaby, Canada). The result was positive for SARS-CoV-2 IgG but negative for IgM. All antibody titers measured against other viruses, including influenza A and B, mumps virus, herpes simplex virus, varicella-zoster virus, cytomegalovirus, Epstein-Barr virus, adenovirus, and coxsackie virus, were low. SARS-CoV-2 spike and nucleocapsid protein transcripts were detected by RT-PCR from sections obtained by myocardial biopsy (spike: 731 copies, nucleocapsid: 4026 copies, and human glyceraldehyde 3-phosphate dehydrogenase: 410 copies per 1 ng total RNA).

Given the severity of his cardiogenic shock, the patient underwent intra-aortic balloon pumping (IABP) and veno-arterial extracorporeal membrane oxygenation (V-A ECMO). He was also treated with intravenous immunoglobulin, steroids, continuous renal replacement therapy (CRRT) and antiviral therapy (intravenous injection of nafamostat mesylate [4,5] as an anticoagulant for CRRT) (Fig. 1).

The patient ultimately recovered ventricular function and withdrew from V-A ECMO, IABP, mechanical ventilation, and CRRT 1–2 weeks after admission.

The final diagnosis was delayed SARS-CoV-2-induced FM based on the detection of SARS-CoV-2 in pathological specimens of the myocardium by RT-PCR. The patient was transferred to the previous hospital for rehabilitation on the 24th day after admission.

3. Discussion

In nearly all previously published cases, acute heart failure and/or left ventricular dysfunction occurred within the first week following the initial symptoms of COVID-19 [6]. Only two cases had delays of approximately 4 and 6 weeks, respectively, from initial COVID-19-related symptoms to the onset of acute heart failure [6,7]. Our case had a delay of over 3 weeks from initial COVID-19 symptoms to onset of FM.

A few case reports of acute heart failure and/or left ventricular

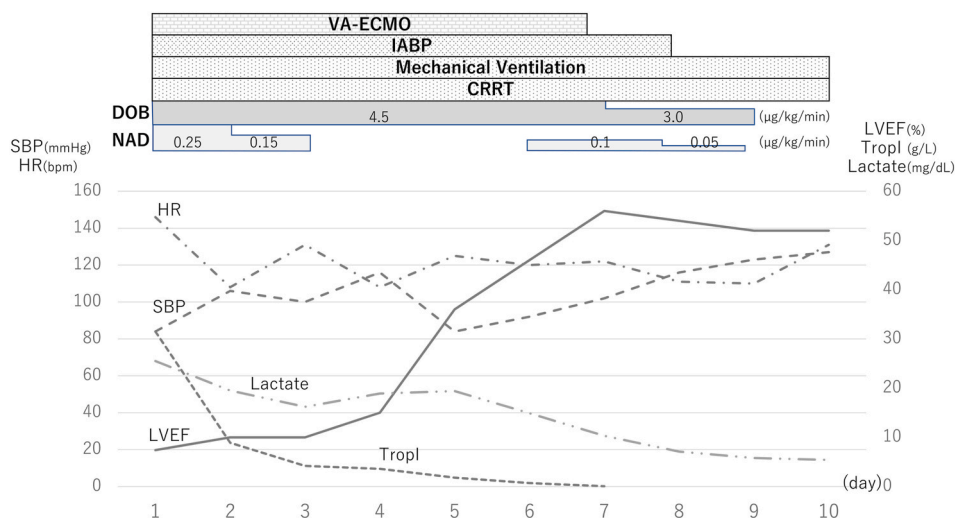


Fig. 1. Clinical course of the patient in intensive care unit.

On arrival to the ICU, his respiratory and hemodynamic conditions were extremely severe. VA-ECMO, venoarterial-extracorporeal membrane oxygenation; IABP, intra aortic balloon pumping; CRRT, continuous renal replacement therapy; DOB, dobutamine; NAD, noradrenaline; HR, heart rate; SBP, systolic blood pressure; LVEF, left ventricular ejection fraction; Tropl, Troponin I.

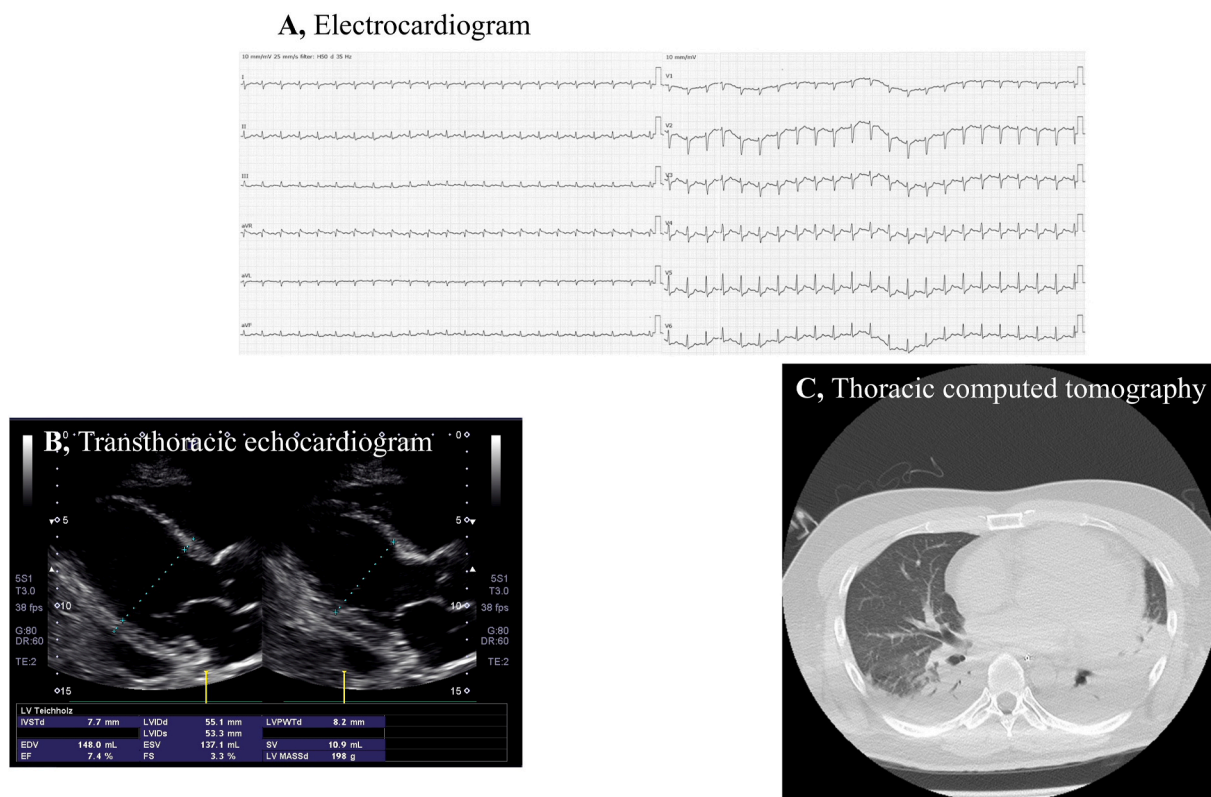


Fig. 2. Electrocardiographic, Transthoracic echocardiogram, and Thoracic computerized tomography findings on the day of admission. **A,** Electrocardiogram showing sinus tachycardia and no ST-segment elevation. **B,** Transthoracic echocardiogram showing diffuse severe hypokinesis, left ventricle with severely reduced systolic function, ejection fraction of 7.4%, no valvular heart disease, and a small pericardial effusion in the posterior opposite. **C,** Thoracic computerized tomography scan showing absence of typical ground-glass changes and ARDS on both sides of the back.

dysfunction with abnormalities on cardiac magnetic resonance imaging suggestive of myocarditis have been published in the setting of acute SARS-CoV-2 infection; however, diagnosis of active myocarditis was proven by pathological examination following endomyocardial biopsy in only two cases [6,8]. In our case, diagnosis of active myocarditis was made by pathological examination following endocardial myocardial biopsy.

For the previous two patients who developed acute heart failure more than a month after the first COVID-19-related symptoms, one case reported by Nicol et al. [6], RT-PCR was performed using frozen myocardial fragments to exhaustively search for viruses. SARS-CoV-2 was not detected. The other case reported by Spano et al. [7], RT-PCR was not performed for the purpose of detecting SARS-CoV-2. We detected SARS-CoV-2 by RT-PCR in pathological specimens of the myocardium from our patient. For the above reasons, we concluded that ours was the first case of laboratory-confirmed FM. However, the mechanism of delayed FM in COVID-19 patients remains unclear at this time.

FM is a rare clinical syndrome with features of cardiac inflammation, and has a high mortality rate of approximately 30% at 60 days [9]. Acute myocarditis is an inflammatory disease of the myocardium most often resulting from viral infections or autoimmune disorders [10]. Since Zing et al. reported the first case of COVID-19 with FM [11], several additional cases of COVID-19-associated FM have been reported including in a healthy young patient [12] and an infant [13]. Some authors have argued that up to 7% of COVID-19-related deaths were attributable to myocarditis [14]. The case reported here had a sudden disease onset, obvious symptoms of viral infection, rapid emergence of severe hemodynamic disorders, severe myocardial injury, and diffuse decreased ventricular wall movement. These features are all in accordance with the diagnostic criteria for FM [10]. The pathophysiological mechanisms

underlying the myocardial injuries caused by COVID-19 are not well understood so far. We suggested the mechanisms of cardiovascular complications associated with COVID-19 as follow: (i) direct SARS-CoV-2 invasion of the myocardium, (ii) systemic inflammation mediated by acute systemic inflammatory responses and cytokine storms, (iii) altered myocardial demand supply ratio, plaque rupture, and coronary thrombosis, (iv) adverse effects of various therapies, and/or (v) electrolyte imbalances. In general, viral infections are the most common causes of myocarditis [15,16]. Therefore, we suspected that one potential mechanism of SARS-CoV-2-induced myocardial injury in our patient was direct SARS-CoV-2 invasion of the myocardium. SARS-CoV-2 is an enveloped RNA betacoronavirus in the same family as SARS-CoV. In humans, SARS-CoV infection of the myocardium is dependent on expression of ACE2 receptors. Oudit et al. [17] reported that SARS-CoV viral RNA was detected in autopsied human heart samples, suggesting direct viral invasion of myocytes. The authors hypothesized that interaction between SARS-CoV and ACE2 in the heart contributed to SARS-mediated myocardial inflammation. On the basis of these results, we suspected that direct invasion of the myocardium by SARS-CoV-2, mediated by interactions between SARS-CoV-2 and ACE2, contributes to myocardial injury. This pathophysiological mechanism of myocardial injury following COVID-19 may be a characteristic of SARS-CoV-2-induced FM.

IL-6 levels in this case reported here never exceeded 600 pg/mL during his ICU stay. These values are not high enough to be called a cytokine storm. Leisman et al. [18]. Proposed that IL-6 concentrations in patients with severe or critical COVID-19 were significantly lower than in patients with sepsis or ARDS unrelated to COVID-19. Thus, the role of a cytokine storm in COVID-19-induced FM may be questionable.

Previously, SARS-CoV RNA was detected in 35% (7/20) of autopsied human heart samples, and a marked increase in macrophage infiltration

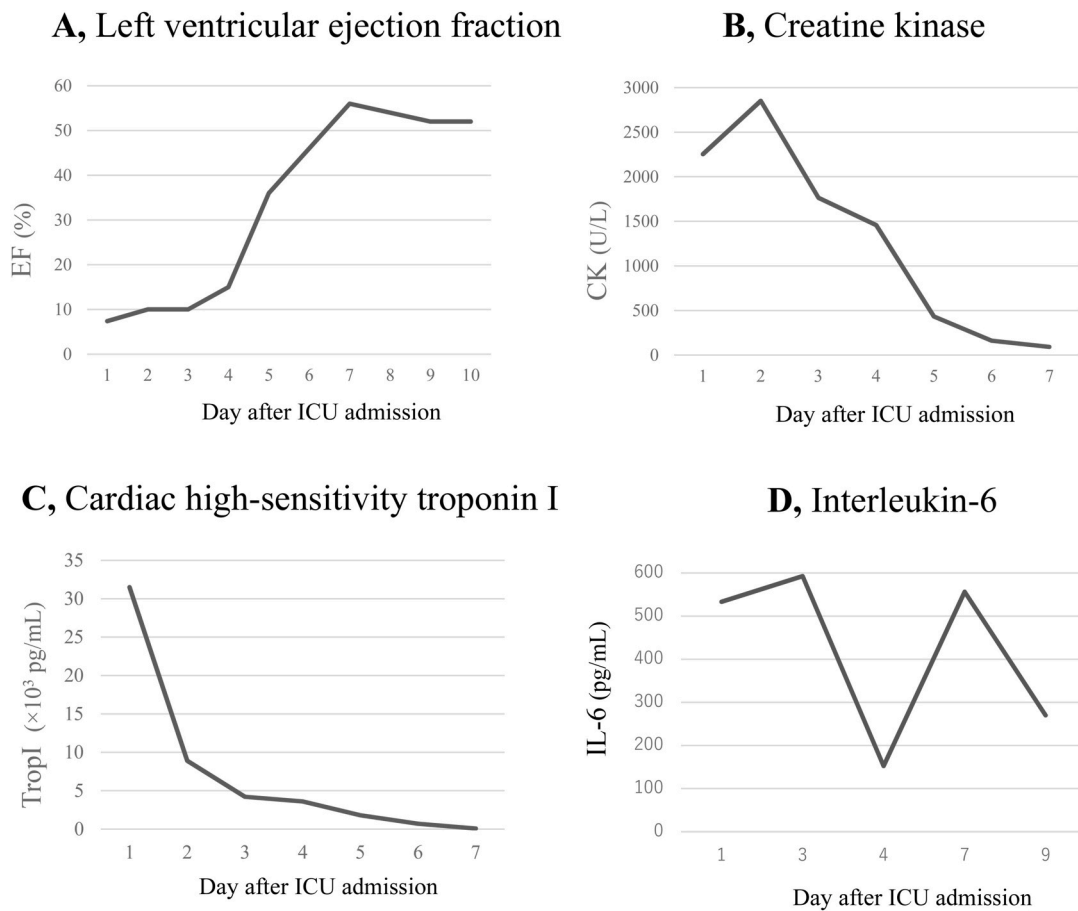


Fig. 3. Assessment of markers of myocardial injury and ejection fraction in the patient over time. An increase in ejection fraction was observed (A), while CK (B) and TropI (C) decreased gradually. Blood levels of IL-6 were elevated at 533.3 pg/mL (D); the highest value of IL-6 observed during the patient’s ICU stay was 593 pg/mL. CK; creatine kinase, TropI; troponin I, IL-6; interleukin-6.

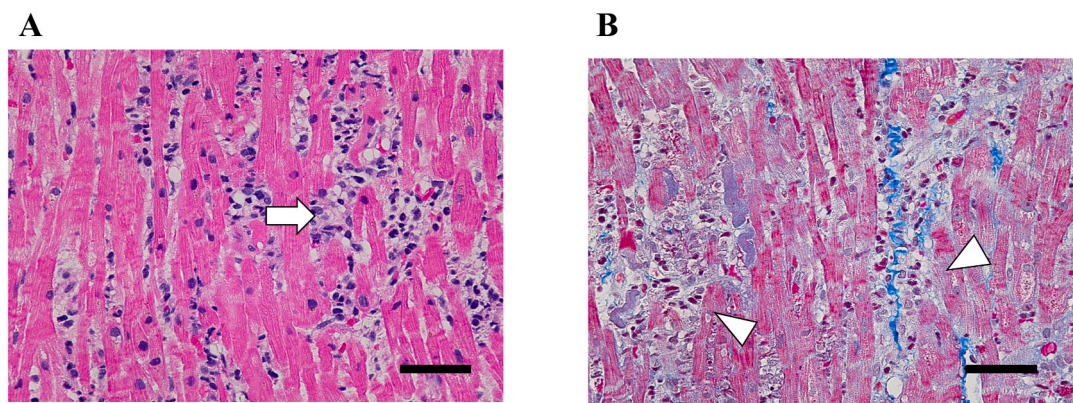


Fig. 4. Myocardial pathological specimen findings. Myocardial pathological specimen demonstrating diffuse lymphocyte infiltration in the interstitium of the myocardial tissue (A; white arrow) as well as atrophy and shedding degeneration of myofibrils (B; white arrowhead). Scale bar, 50 μ m.

with evidence of myocardial damage was observed in patients with detectable SARS-CoV RNA [19]. Diagnosis of FM can be aided through use of biomarkers and cardiac imaging. However, endocardial biopsy remains the gold standard, although its sensitivity may be limited by patchy distribution of inflammatory infiltrates [20]. In this case we performed endocardial biopsy, and SARS-CoV-2 RNA was detected by RT-PCR. Kesici et al. [13]. Previously reported that SARS-CoV-2 RT-PCR was positive in the myocardium from a patient with COVID-19-related FM.

In conclusion, we suggest that a potential mechanism of FM in

COVID-19 patients may be direct SARS-CoV-2 invasion of the myocardium. Therefore, clinicians should remain vigilant for delayed-onset COVID-19-associated FM even after patients have completely recovered from COVID-19.

Funding

This case report did not receive any specific grant from funding agencies in the public, commercial, or not-for-profit sectors.

Consent for publication

Because of the unique and potentially identifiable characteristics of COVID-19, we obtained signed informed consent from the patient in accordance with the Declaration of Helsinki for publication of this case report. A copy of the informed consent document can be provided upon request.

Authors' contributions

HI contributed to the study design, interpretation of the results, drafting of the manuscript, and critical revision of the manuscript for intellectual content. JM and YN contributed to the interpretation of the results. All authors were involved in the diagnosis, management, and/or care of the patient. And all authors have read and approved the final manuscript.

Declaration of interest

None.

Acknowledgements

We would like to thank the nursing staff involved in this patient's care, members of the Infection Prevention and Control team, and members of the Cardiovascular Catheter team.

We also thank Edanz Group (<https://en-author-services.edanz.com/ac>) for editing a draft of this manuscript.

References

- [1] Ge H, Wang X, Yuan X, Xiao G, Wang C, Deng T, et al. The epidemiology and clinical information about COVID-19. *Eur J Clin Microbiol Infect Dis* 2020. <https://doi.org/10.1007/s10096-020-03874-z>.
- [2] Wang D, Hu B, Hu C, Zhu F, Liu X, Zhang J, et al. Clinical characteristics of 138 hospitalized patients with 2019 novel coronavirus-infected pneumonia in Wuhan, China. *J Am Med Assoc* 2020. <https://doi.org/10.1001/jama.2020.1585>.
- [3] Chen C, Zhou Y, Wang DW. SARS-CoV-2: a potential novel etiology of fulminant myocarditis. *Herz* 2020. <https://doi.org/10.1007/s00059-020-04909-z>.
- [4] Hoffmann M, Schroeder S, Kleine-Weber H, Müller MA, Drosten C, Pöhlmann S. Nafamostat mesylate blocks activation of SARS-CoV-2: new treatment option for COVID-19. *Antimicrob Agents Chemother* 2020. <https://doi.org/10.1128/AAC.00754-20>.
- [5] Yamamoto M, Kiso M, Sakai-Tagawa Y, Iwatsuki-Horimoto K, Imai M, Takeda M, et al. The anticoagulant nafamostat potently inhibits SARS-CoV-2 S protein-mediated fusion in a cell fusion assay system and viral infection in vitro in a cell-type-dependent manner. <https://doi.org/10.3390/v12060629>; 2020.
- [6] Nicol M, Cacoub L, Baudet M, Nahmani Y, Cacoub P, Cohen-Solal A, et al. Delayed acute myocarditis and COVID-19-related multisystem inflammatory syndrome. *ESC Heart Fail* 2020. <https://doi.org/10.1002/ehf2.13047>.
- [7] Spano G, Fischer K, Maillat C, Vicario G, Huber AT, Gräni C. Int J Cardiovasc. Delayed isolated peri-myocarditis in a Covid-19 patient with respiratory symptoms but without lung involvement. *Imaging* 2020. <https://doi.org/10.1007/s10554-020-01943-0>.
- [8] Sala S, Peretto G, Gramegna M, Palmisano A, Villatore A, Vignale D, et al. Acute myocarditis presenting as a reverse Tako-Tsubo syndrome in a patient with SARS-CoV-2 respiratory infection. *Eur Heart J* 2020. <https://doi.org/10.1093/eurheartj/ehaa286>.
- [9] Ammirati E, Veronese G, Brambatti M, Merlo M, Cipriani M, Potena L, et al. Fulminant versus acute nonfulminant myocarditis in patients with left ventricular systolic dysfunction. *J Am Coll Cardiol Actions* 2019. <https://doi.org/10.1016/j.jacc.2019.04.063>.
- [10] Caforio AL, Pankuweit S, Arbustini E, Basso C, Gimeno-Blanes J, Felix SB, et al. Current state of knowledge on aetiology, diagnosis, management, and therapy of myocarditis: a position statement of the European Society of Cardiology Working Group on Myocardial and Pericardial Diseases. *Eur Heart J* 2013. <https://doi.org/10.1093/eurheartj/ehs210>.
- [11] Zeng JH, Liu YX, Yuan J, Wang FX, Wu WB, Li JX, et al. First case of COVID-19 complicated with fulminant myocarditis: a case report and insights. *Infection* 2020; 48(5):773–7. <https://doi.org/10.1007/s15010-020-01424-5>.
- [12] Paul JF, Charles P, Richaud C, Caussin C, Diakov C. Myocarditis revealing COVID-19 infection in a young patient. *Eur Heart J Cardiovasc Imaging* 2020. <https://doi.org/10.1093/ehjci/jeaa107>.
- [13] Kesici S, Aykan HH, Orhan D, Bayrakci B. Fulminant COVID-19-related myocarditis in an infant. *Eur Heart J* 2020. <https://doi.org/10.1093/eurheartj/ehaa515>.
- [14] Driggin E, Madhavan MV, Bikdeli B, Chuich T, Laracy J, Biondi-Zoccai G, et al. Cardiovascular considerations for patients, health care workers, and health systems during the COVID-19 pandemic. *J Am Coll Cardiol* 2020. <https://doi.org/10.1016/j.jacc.2020.03.031>.
- [15] Kēuhl U, Pauschinger M, Noutsias M, Seeberg B, Bock T, Lassner D, et al. High prevalence of viral genomes and multiple viral infections in the myocardium of adults with "idiopathic" left ventricular dysfunction. *Circulation* 2005. <https://doi.org/10.1161/01.CIR.0000155616.07901.35>.
- [16] Kindermann I, Kindermann M, Kandolf R, Klingel K, Bēultmann B, Mēuller T, et al. Predictors of outcome in patients with suspected myocarditis. *Circulation* 2008. <https://doi.org/10.1161/CIRCULATIONAHA.108.769489>.
- [17] Oudit GY, Kassiri Z, Jiang C, Liu PP, Poutanen SM, Penninger JM, et al. SARS-coronavirus modulation of myocardial ACE2 expression and inflammation in patients with SARS. *Eur. J. Clin. Investig* 2009. <https://doi.org/10.1111/j.1365-2362.2009.02153.x>.
- [18] Leisman DE, Ronner L, Pinotti R, Taylor MD, Sinha P, Calfee CS, et al. Cytokine elevation in severe and critical COVID-19: a rapid systematic review, meta-analysis, and comparison with other inflammatory syndromes. *Lancet Respir Med* 2020. [https://doi.org/10.1016/S2213-2600\(20\)30404-5](https://doi.org/10.1016/S2213-2600(20)30404-5).
- [19] Booth CM, Matukas LM, Tomlinson GA, Rachlis AR, Rose DB, Dwosh HA, et al. Clinical features and short-term outcomes of 144 patients with SARS in the greater Toronto area. *J Am Med Assoc* 2003. <https://doi.org/10.1001/jama.289.21.JOC30885>.
- [20] Sharma AN, Stultz JR, Bellamkonda N, Amsterdam EA. Fulminant myocarditis: epidemiology, pathogenesis, diagnosis, and management. *Am J Cardiol* 2019. <https://doi.org/10.1016/j.amjcard.2019.09.017>.