

Clinical Article

Quantitative Analysis of Factors Affecting Cobalt Alloy Clip Artifacts in Computed Tomography

Sook Young Sim, M.D., Ph.D.,¹ Chi Hoon Choi, M.D., Ph.D.²

Department of Neurosurgery,¹ Inje University Seoul Paik Hospital, Seoul, Korea

Department of Radiology,² National Medical Center, Seoul, Korea

Objective : Clip artifacts limit the visualization of intracranial structures in CT scans from patients after aneurysmal clipping with cobalt alloy clips. This study is to analyze the parameters influencing the degree of clip artifacts.

Methods : Postoperative CT scans of 60 patients with straight cobalt alloy-clipped aneurysms were analyzed for the maximal diameter of white artifacts and the angle and number of streak artifacts in axial images, and the maximal diameter of artifacts in three-dimensional (3-D) volume-rendered images. The correlation coefficient (CC) was determined between each clip artifact type and the clip blade length and clip orientation to the CT scan (angle *a*, lateral clip inclination in axial images; angle *b*, clip gradient to scan plane in lateral scout images).

Results : Angle *b* correlated negatively with white artifacts ($r=-0.589$, $p<0.001$) and positively with the angle ($r=0.636$, $p<0.001$) and number ($r=0.505$, $p<0.001$) of streak artifacts. Artifacts in 3-D images correlated with clip blade length ($r=0.454$, $p=0.004$). Multiple linear regression analysis revealed that angle *b* was the major parameter influencing white artifacts and the angle and number of streak artifacts in axial images ($p<0.001$), whereas clip blade length was a major factor in 3-D images ($p=0.034$).

Conclusion : Use of a clip orientation perpendicular to the scan gantry angle decreased the amount of white artifacts and allowed better visualization of the clip site.

Key Words : Artifacts · Clip · Intracranial aneurysm · Multidetector computed tomography.

INTRODUCTION

After craniotomy for aneurysmal clipping, the intracranial vessels are examined for any residual neck, parent artery compromise, vasospasm, or aneurysmal regrowth. As the standard tool for intracranial vascular examination, digital subtraction angiography is a time-consuming method that carries risks of thromboembolic and puncture-site complications. In comparison, computerized tomographic angiography (CTA) has several advantages, including low-contrast dose, low radiation exposure, short acquisition time, and low invasiveness. Moreover, CTA can be used to obtain parenchymal structural information that cannot be determined by catheter angiography. These advantages make CTA an attractive alternative to catheter angiography, and its diagnostic use has increased with improvements in multidetector computerized angiography (CT) techniques^{4,9,12}.

However, clip artifacts limit the visualization of the vessels in the vicinity of the clip, particularly in patients in whom cobalt al-

loy clips have been used^{11-13,16}. Several CT acquisition settings and modes have been proposed to reduce clip artifacts^{5-7,12}. However, from a clinical perspective, switching to an artifact-reducing acquisition mode might not always be possible because aneurysmal clipping is frequently performed on an emergent basis.

In our daily clinical practice, we have observed that clip artifacts vary, even under the same imaging acquisition settings, according to clip orientation. These findings have been verified by van der Schaaf et al.¹² and Pechlivanis et al.¹⁰ using CT scans in a phantom model. Those studies were performed *in vitro* using discrete numeric variables. To substantiate the effect of clip orientation and other factors on the degree of clip artifacts *in vivo*, we applied mathematical analysis using continuous numeric variables to retrospectively analyze the quantitative relationship between clip artifacts and related factors in real patients with cobalt alloy clips.

• Received : May 13, 2014 • Revised : August 7, 2014 • Accepted : August 13, 2014

• Address for reprints : Sook Young Sim, M.D., Ph.D.

Department of Neurosurgery, Inje University Seoul Paik Hospital, 9 Mareunnae-ro, Jung-gu, Seoul 100-032, Korea
Tel : +82-2-2270-0032, Fax : +82-2-2270-0573, E-mail : lessordi@naver.com

• This is an Open Access article distributed under the terms of the Creative Commons Attribution Non-Commercial License (<http://creativecommons.org/licenses/by-nc/3.0>) which permits unrestricted non-commercial use, distribution, and reproduction in any medium, provided the original work is properly cited.

MATERIALS AND METHODS

Patients and image acquisition

Postoperative CT images of 60 patients who had undergone aneurysmal clipping surgery with a single straight cobalt alloy clip (Sugita Clip, Mizuho Ikkogyo Co., Tokyo, Japan) were retrospectively reviewed. The clipped aneurysms included 15 anterior cerebral artery aneurysms (anterior communicating artery, $n=10$; pericallosal artery, $n=3$; A2, $n=1$; and A1, $n=1$), 21 middle cerebral artery aneurysms (middle cerebral artery bifurcation, $n=17$; M1, $n=2$; and M2, $n=2$), 22 internal carotid artery aneurysms (posterior communicating artery, $n=11$; anterior choroidal artery, $n=8$; and internal carotid artery bifurcation, $n=3$), and 2 posterior circulation aneurysms (posterior cerebral artery, $n=1$; and basilar artery, $n=1$).

All patients underwent routine postoperative axial CT imaging. Of the 60 patients, 39 also underwent CTA by helical scan. All CT images were acquired using a 64-detector Lightspeed volume multidetector CT (GE Healthcare, Milwaukee, WI, USA). The CT image acquisition protocol was as follows: for axial scans ($n=60$), 120 kilovoltage peak (kVp), 200 mA, 5-mm section; for helical scans ($n=39$), 120 kVp, 300 mA, 0.625-mm section collimation, 0.96 pitch, and 0.4-second rotation speed.

Measurement and analysis of clip artifacts

To determine the degree of clip artifacts, various factors were measured from the CT images. Independent variables for the degree of clip artifacts included the clip blade length and clip orientation. The clip blade length was determined as the total length of the clip minus the length of the clip spring portion. The clip orientation was determined as: 1) the lateral inclination of the clip blade to axial images (angle a), and 2) the gradient of the clip blade to the scan gantry angle on lateral scout images (angle b). The degree of lateral inclination of the clip blade to the CT axial scan (angle a) was measured as the angle between the clip blade

and an imaginary midline from forehead toinion. Each angle was measured on the basis of minor and acute angles rather than major and obtuse angles from each fiducial line. Fig. 1 illustrates the detailed measurement methods, marking minor and acute angles in each image. The dependent variables were the maximal diameter (d_{\max}) of white artifacts and the number and angle of visible streak artifacts on axial CT images, and the d_{\max} of artifacts around the clip on three-dimensional (3-D) volume-rendered images in CTA. White artifacts were defined as white round artifacts around the clip in axial images. Streak artifacts were defined as black straight lines radiating from each side of the clip. The angle of visible streak artifacts on the axial CT images was the sum of each angle between the measured streak artifacts.

CTA images were reconstructed manually at the workstation from source images obtained from a helical scan. The amount of clip artifacts in 3-D volume-rendered images was measured as the d_{\max} of clip artifacts in the vicinity of the clip in a 360° rotational view. All measurements were made at the same window length/width/z-value setting (axial scan: 40/100/133.40%, volume-rendered scan: 127/255/96.06%). One author manually measured the artifacts and the other author performed the statistical analysis.

Initially, descriptive statistics were used to calculate the means and standard deviations of the clip blade length, angle degree to the CT scan according to clip orientation, and the d_{\max} of each type of clip artifact. A correlation analysis using Pearson's correlation coefficients was performed between the independent variables and the degree of each type of artifact. Subsequently, all of the variables were assessed by univariate analysis with regression methods. For multiple linear regression analysis, backward-selection model buildup was used to determine which factor was more predictive of clip artifacts. A value of $p < 0.05$ was considered significant for all analyses. Statistical analyses were performed with SPSS (SPSS Version 19.0 for Windows, SPSS Inc., Chicago, IL, USA).

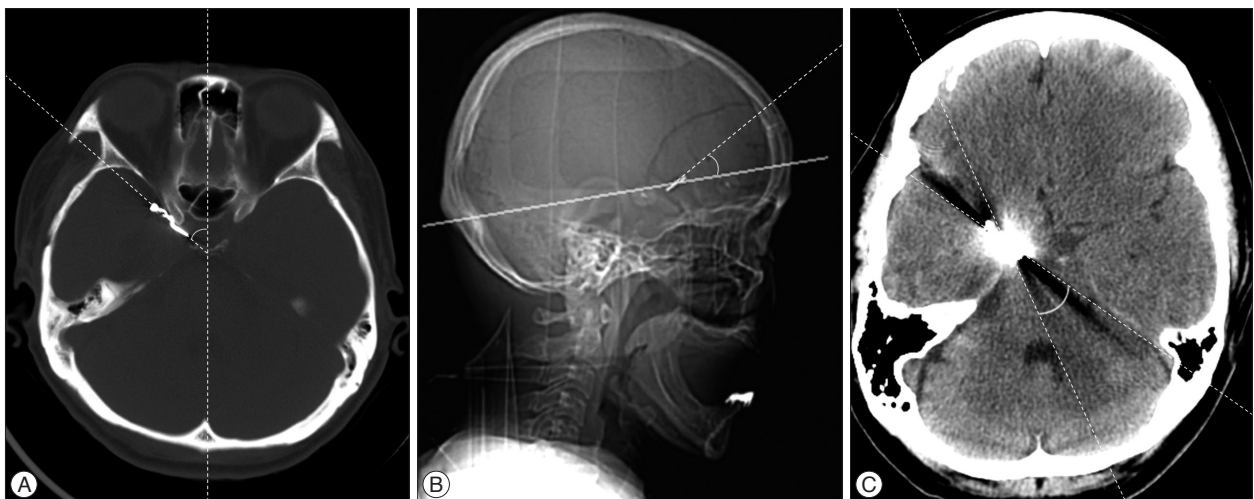


Fig. 1. Measurement of influencing factors and clip artifacts. Degree of lateral inclination of clip blade to CT axial scan (angle a) (A), degree of gradient of clip blade to scan gantry angle in lateral scout view (angle b) (B), and angle of streak artifacts (C) are measured as shown in the pictures.

RESULTS

The mean (\pm standard deviation, range) of the clip blade length was 10.79 mm (\pm 2.41, 5–16). The means of angles *a* and *b* were 41.65° (\pm 19.83, 0–90) and 19.75° (\pm 21.62, 0–80), respectively. The average d_{max} value of the white artifacts was 13.2 mm (\pm 5.47, 1–29). The average angle and number of streak artifacts were 73.92° (\pm 89.99, 5–360) and 3.83 (\pm 2.39, 2–12), respectively. The average d_{max} of the artifacts in 3-D volume-rendered images was 15.80 mm (\pm 13.14, 0–44).

In correlation analysis, angle *b* was negatively correlated with

the d_{max} of the white artifacts ($r=-0.589, p<0.001$) and positively correlated with the angle ($r=0.636, p<0.001$) and number of streak artifacts ($r=0.505, p<0.001$). The clip blade length was positively correlated with the diameter of clip artifacts in the 3-D volume-rendered images ($r=0.454, p=0.004$) (Fig. 2). Angle *a* had no statistically significant relationship with the clip artifacts (data not shown).

Linear regression analysis revealed that angle *b* was positively correlated to the d_{max} of the white artifacts ($\beta=-0.108, p=0.005$), the angle of the streak artifacts ($\beta=2.745, p<0.001$) and the number of streak artifacts ($\beta=0.070, p<0.001$). The clip blade length

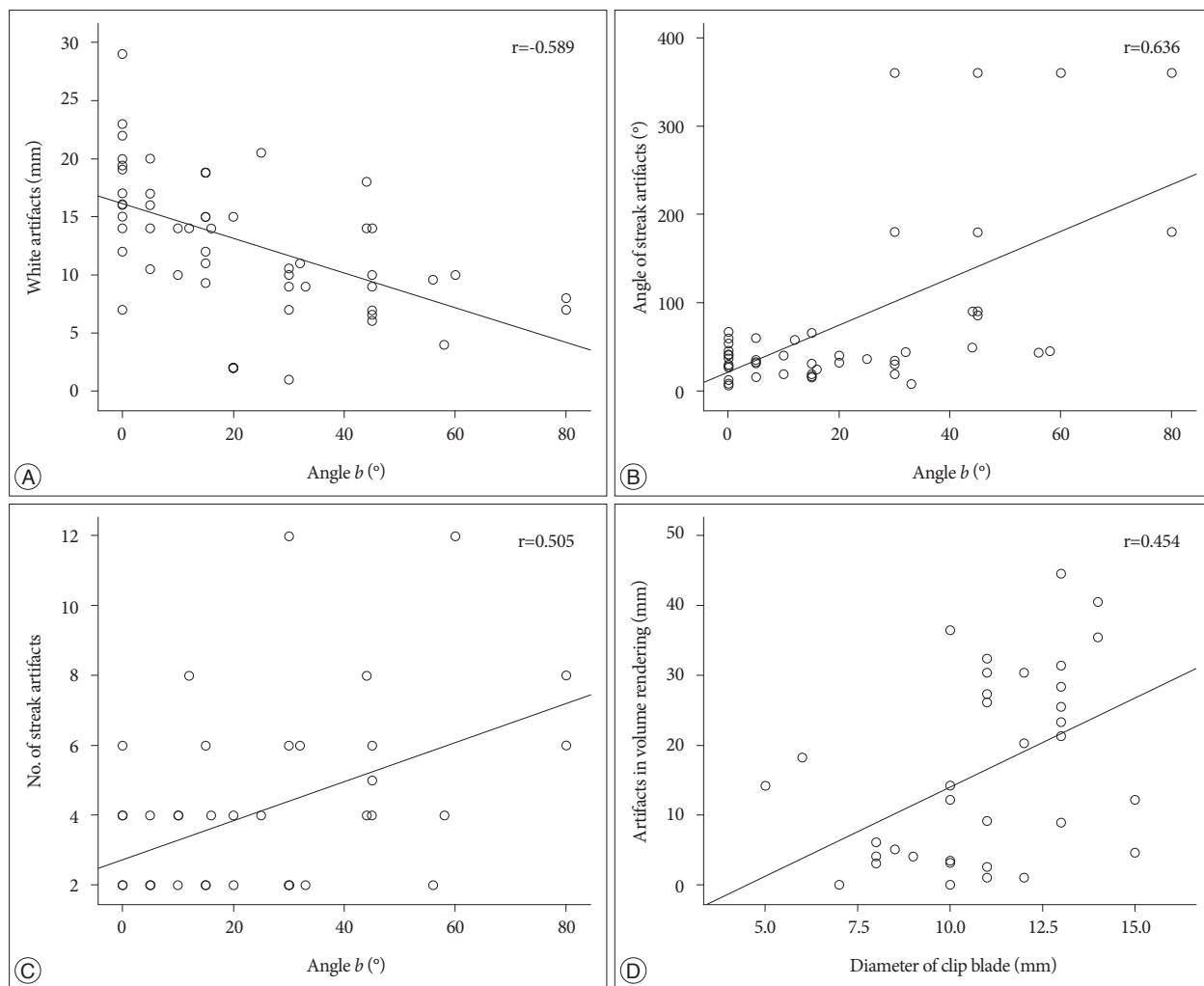


Fig. 2. Correlation analysis between each type of clip artifacts and influencing factors. White artifacts in axial images and angle *b* (A). Angle of streak artifacts and angle *b* (B). Number of streak artifacts and angle *b* (C). Artifacts in volume-rendered images and diameter of the clip blade (D).

Table 1. Association of clip blade length and clip orientation to each type of clip artifact by univariate linear regression analyses

Variable	White artifacts		Angle of streak artifacts		No. of streak artifacts		Artifacts in 3-D images	
	$\beta \pm SE$	<i>p</i>	$\beta \pm SE$	<i>p</i>	$\beta \pm SE$	<i>p</i>	$\beta \pm SE$	<i>p</i>
Clip blade length	0.016 \pm 0.253	0.950	3.933 \pm 4.129	0.345	0.069 \pm 0.120	0.568	1.918 \pm 0.859	0.033
Angle <i>a</i>	-0.033 \pm 0.202	0.870	-2.712 \pm 3.285	0.413	0.015 \pm 0.096	0.880	-0.866 \pm 1.201	0.476
Angle <i>b</i>	-0.108 \pm 0.037	0.005	2.745 \pm 0.606	<0.001	0.070 \pm 0.018	<0.001	0.046 \pm 0.140	0.743

3-D : 3-dimensional, SE : standard error

Table 2. Association of clip blade length and clip orientation to each clip artifact type by multiple linear regression analyses

Variable	White artifact		Angle of streak artifact		No. of streak artifacts		Artifact in 3-D images	
	$\beta \pm SE$	<i>p</i>	$\beta \pm SE$	<i>p</i>	$\beta \pm SE$	<i>p</i>	$\beta \pm SE$	<i>p</i>
Clip blade length							1.750 \pm 0.793	0.034
Angle <i>b</i>	-0.110 \pm 0.029	<0.001	2.648 \pm 0.422	<0.001	0.071 \pm 0.014	<0.001		

No. : number; SE : standard error

was linearly associated with the number of artifacts in the 3-D volume-rendered images ($\beta=1.918$, $p=0.033$) (Table 1). In the multiple linear regression analysis, both angle *b* and the clip blade length were positive predictors of the degree of each clip artifact in the axial scan (white artifacts, and angle and number of streak artifacts) and in the 3-D volume-rendered images, respectively (Table 2).

DISCUSSION

Since 1937 when Dandy²⁾ first introduced the V-shaped silver clip, various materials have been used for intracranial aneurysmal clips. However, cranial metallic implants, particularly cobalt alloy clips, interfere with CT evaluation in the same anatomic location due to clip-induced artifacts. Since the introduction of titanium alloy clips, the occurrence of metallic artifacts adjacent to the clip has greatly decreased, resulting in widespread usage of titanium alloy clips. Although clips made from titanium alloy permit better visualization in the clip vicinity than those made from cobalt alloy^{3,11,12,14,16)}, the latter still play a large clinical role due to several advantages, including high tensile strength, high closing force, and extra-large and variously fenestrated clip profiles⁸⁾. Therefore, we wanted to determine whether there were factors other than the clip property itself influencing the cobalt clip artifacts that could be easily managed.

Previous researchers have investigated various approaches for minimizing clip artifacts in post-aneurysmal clipping CT scans from patients. Some authors have proposed the use of ideal image acquisition parameters, such as pitch, kVp, reconstruction algorithm, and type or concentration of contrast material^{6,12,13)}. Others have suggested the use of ideal acquisition modes, including nonhelical^{6,7)}, gated multidetector CT⁵⁾, and the orbital synchronized helical scan technique¹⁵⁾. These previous studies have several limitations. For example, many were performed in phantom models^{6,7)}. The environment in the human brain after aneurysmal clipping is significantly different from the phantom environment due to the presence of bony structures, blood, brain, and soft tissues adjacent to the clip. Finally, the studies that have analyzed clip artifacts in patients had very small sample sizes^{1,5)} or were not quantitative^{1,11,12,16)}. In 1999, Brown et al.¹⁾ first reported the effect of clip orientation on the number of clip artifacts. In their report on four patients, they proposed that lateral tilting of the head during CT acquisition could reduce the number of clip artifacts by projecting the aneurysm clip away from the remainder of the circle of Willis. In 2006, van der Schaaf et al.¹²⁾ used a phantom model to evaluate different clip orientations and their

effect on artifact volume, showing that positioning of the clip perpendicular to the scan plane led to significantly fewer artifacts. Those findings were quite in agreement with the findings of the present study, although the previous study dealt with the observation regarding clip orientation in a comparatively simpler fashion with selected clip-gantry angles of 0 degree, 45 degrees, and 90 degrees. To the best of our knowledge, this study is the first to demonstrate a clear linear relationship between clip artifacts and the CT scan gantry angle *in vivo*. In addition to clip orientation, the authors attempted to use statistical analyses of clip blade length as a variable for clip artifacts based on the hypothesis that the amount of metallic component might influence the amount of clip artifacts. The study by van der Schaaf et al.¹²⁾ dealt with the correlation between clip artifacts and kVp/pitch and proposed that 140 kVp and less than 0.6 pitch was an ideal setting for the reduction of metallic artifacts. Our study was conducted in a fixed setting of 120 kVp and 0.96 pitch, focusing on the clip orientation and clip property itself.

In summary, all clip artifacts that could be measured in a routine axial scan (white artifacts, and the angle and number of streak artifacts) were linearly correlated with the degree of angle *b*, whereas the artifacts in 3-D volume-rendered images were influenced by the clip blade length.

Of these factors, the scanning gantry angle is the only factor that can be modified during postoperative scanning. Indeed, the physician and technician could easily modulate this angle by altering the patient's head positioning (i.e., through head flexion or extension), or by altering the scan angle according to the CT lateral scout view in which the clip orientation is clearly visible. White artifacts interfere with the visualization of adjacent structures more than streak artifacts. The diameter of white artifacts in the CT scan could be reduced by changing the patient's head position or the gantry angle, with the clip blade being placed as perpendicularly as possible to the scan plane on the lateral scout view.

This study has several limitations. Unfortunately, the correlation between the clip artifacts and clip orientation in the frontal scout view could not be analyzed because of the limitation of this retrospective analysis. Although the clip orientation on the lateral view is the most important contributing factor for the degree of clip artifacts in axial CT images, this is not the case with CTA reconstruction images. Three dimensional CTA might be associated with various technical factors, including patient motion and timing of contrast injection, thus it might be difficult to determine the mechanism underlying the amount of clip artifacts in these images. Compared with measuring artifacts in axial CT conducted under a constant two-dimensional field, measuring

artifacts in CTA is more inconstant in 3-D space. Moreover, artifacts in 3-D CTA with a large d_{max} but small volume might be oversized in the measurements, because the artifacts are measured by diameter rather than volume. Because the use of a complex clip type, including a fenestrated or angled blade, might interfere with the results, we attempted to avoid this issue by including only cases with a straight clip blade. In spite of this effort, there is still a possibility that the clip spring portion might influence the pattern or amount of clip artifacts. Multiple clips or those with a complex shape preclude the clinical implication of artifact-reducing strategies based on clip orientation.

CONCLUSION

Clip artifacts generated by a cobalt alloy clip in a 64-channel CT scan may be influenced by the clip length and the angle between the clip and the scan plane. The number of white artifacts increased when the orientation of the angle between the clip blade and the scan plane was parallel. These findings suggest that clip artifacts after aneurysmal clipping could be minimized by simple maneuvers, such as minimal changes in the scan gantry angle on the lateral scout view if the clip blade is located parallel to the scan plane.

• Acknowledgements

This work was supported by the 2013 Inje University research grant.

References

1. Brown JH, Lustrin ES, Lev MH, Ogilvy CS, Taveras JM : Reduction of aneurysm clip artifacts on CT angiograms : a technical note. *AJNR Am J Neuroradiol* 20 : 694-696, 1999
2. Dandy WE : Intracranial aneurysm of the internal carotid artery : cured by operation. *Ann Surg* 107 : 654-659, 1938
3. Kato Y, Sano H, Katada K, Ogura Y, Ninomiya T, Okuma I, et al. : Effects of new titanium cerebral aneurysm clips on MRI and CT images. *Minim Invasive Neurosurg* 39 : 82-85, 1996
4. Klingebiel R, Busch M, Bohner G, Zimmer C, Hoffmann O, Masuhr F : Multi-slice CT angiography in the evaluation of patients with acute cerebrovascular disease--a promising new diagnostic tool. *J Neurol* 249 : 43-49, 2002
5. Kovács A, Flacke S, Tschampa H, Hadizadeh D, Greschus S, Clusmann H, et al. : Gated multidetector computed tomography. A technique to reduce intracranial aneurysm clip and coil artifacts. *Clin Neuroradiol* 20 : 99-107, 2010
6. Mamourian AC, Erkmen K, Pluta DJ : Nonhelical acquisition CT angiogram after aneurysmal clipping : in vitro testing shows diminished artifact. *AJNR Am J Neuroradiol* 29 : 660-662, 2008
7. Mamourian AC, Pluta DJ, Eskey CJ, Merlis AL : Optimizing computed tomography to reduce artifacts from titanium aneurysm clips : an in vitro study. Technical note. *J Neurosurg* 107 : 1238-1243, 2007
8. Nagatani T, Shibuya M, Ooka K, Suzuki Y, Takayasu M, Yoshida J : Titanium aneurysm clips : mechanical characteristics and clinical trial. *Neurol Med Chir (Tokyo)* 38 Suppl : 39-44, 1998
9. Otawara Y, Ogasawara K, Ogawa A, Sasaki M, Takahashi K : Evaluation of vasospasm after subarachnoid hemorrhage by use of multislice computed tomographic angiography. *Neurosurgery* 51 : 939-942; discussion 942-943, 2002
10. Pechlivanis I, König M, Engelhardt M, Scholz M, Heuser L, Harders A, et al. : Evaluation of clip artefacts in three-dimensional computed tomography. *Cent Eur Neurosurg* 70 : 9-14, 2009
11. Sagara Y, Kiyosue H, Hori Y, Sainoo M, Nagatomi H, Mori H : Limitations of three-dimensional reconstructed computerized tomography angiography after clip placement for intracranial aneurysms. *J Neurosurg* 103 : 656-661, 2005
12. van der Schaaf I, van Leeuwen M, Vlassenbroek A, Velthuis B : Minimizing clip artifacts in multi CT angiography of clipped patients. *AJNR Am J Neuroradiol* 27 : 60-66, 2006
13. Vannier MW, Hildebolt CF, Conover G, Knapp RH, Yokoyama-Crothers N, Wang G : Three-dimensional dental imaging by spiral CT. A progress report. *Oral Surg Oral Med Oral Pathol Oral Radiol Endod* 84 : 561-570, 1997
14. von Holst H, Bergström M, Möller A, Steiner L, Ribbe T : Titanium clips in neurosurgery for elimination of artefacts in computer tomography (CT) a technical note. *Acta Neurochir (Wien)* 38 : 101-109, 1977
15. Watanabe Y, Kashiwagi N, Yamada N, Higashi M, Fukuda T, Morikawa S, et al. : Subtraction 3D CT angiography with the orbital synchronized helical scan technique for the evaluation of postoperative cerebral aneurysms treated with cobalt-alloy clips. *AJNR Am J Neuroradiol* 29 : 1071-1075, 2008
16. Zachenhofer I, Cejna M, Schuster A, Donat M, Roessler K : Image quality and artefact generation post-cerebral aneurysm clipping using a 64-row multislice computer tomography angiography (MSCTA) technology : a retrospective study and review of the literature. *Clin Neurol Neurosurg* 112 : 386-391, 2010