



CrossMark

Non-parasitic Splenic Cyst

Anahita Sadeghi¹, Zeinab Naderpour², Mahbube Ebrahimpur^{2,*}, Hiva Saffar³

1. Assistant Professor of Internal Medicine, Digestive Disease Research Center, Digestive Disease Research Institute, Tehran University of Medical Sciences, Tehran, Iran
2. Assistant Professor of Internal Medicine, Department of Internal Medicine, Shariati Hospital, Tehran University of Medical Sciences, Tehran, Iran
3. Associate Professor of Anatomical and Clinical Pathology, Department of Pathology, Shariati Hospital, Tehran University of Medical Sciences, Tehran, Iran

Please cite this paper as:

Sadeghi A, Naderpour Z, Ebrahimpur M, Saffar H. Non-parasitic Splenic Cyst. *Middle East J Dig Dis* 2017;**9**:242-243. doi: 10.15171/mejdd.2017.81.

A 19-year-old woman presented to our outpatient clinic with localized left upper quadrant (LUQ) pain since 5 months earlier. Intermittent attacks of abdominal pain that progressed to a constant pain and eventually led to shortness of breath were reported.

She had no complaints of fever, weight loss, dyspnea, nausea, vomiting, and altered bowel habits. There was no history of abdominal trauma or surgery. Her medical history was negative and physical examination was unremarkable. All laboratory tests were normal and serological test had no evidence of parasitic infection with *echinococcusgranulosus*.

Plain abdominal radiography was normal. Ultrasound examination showed splenomegaly and hypoechoic well defined intrasplenic cystic lesion.

Computed tomography revealed a cystic mass-like lesion measuring about 25×13×12cm with internal septa in the spleen with a rim of remaining splenic parenchyma, which displaced pancreatic tail and body to the right side with mild pressure effect on the stomach (figure 1).

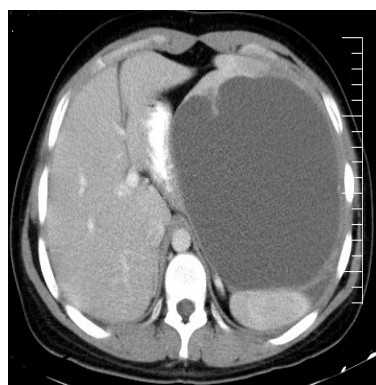


Fig.1: Computed tomogram shows a large cystic lesion in the spleen (axial view)

What is your diagnosis?

Answer:

Epithelial (mesothelial) cyst

The diagnosis of a splenic cyst was confirmed and after pneumococcal vaccination, laparotomy-splenectomy was performed. A large cystic mass was detected with displacement of total remaining splenic parenchyma. Spleen with the cyst was sent for pathological examination. On gross exam the cyst was filled with yellowish clear fluid. In microscopic evaluation (figure 2), fibrous cyst wall was partially lined by flat to cuboidal bland looking cells. In immunohistochemical evaluation, the cells were positive for cytokeratin and calretinin. The surrounding spleen showed sinus dilation, fibrosis of red pulp and accumulation

*** Corresponding Author:**

Mahbube Ebrahimpur, MD
Department of Internal Medicine, Shariati Hospital, Tehran University of Medical Sciences, Kargar Shomali Avenue, Tehran, Iran
Tel: + 98 21 84902152
Fax: + 98 21 84902366
Email: mahbube10183@gmail.com

Received: 22 Jun. 2017

Accepted: 08 Sep. 2017

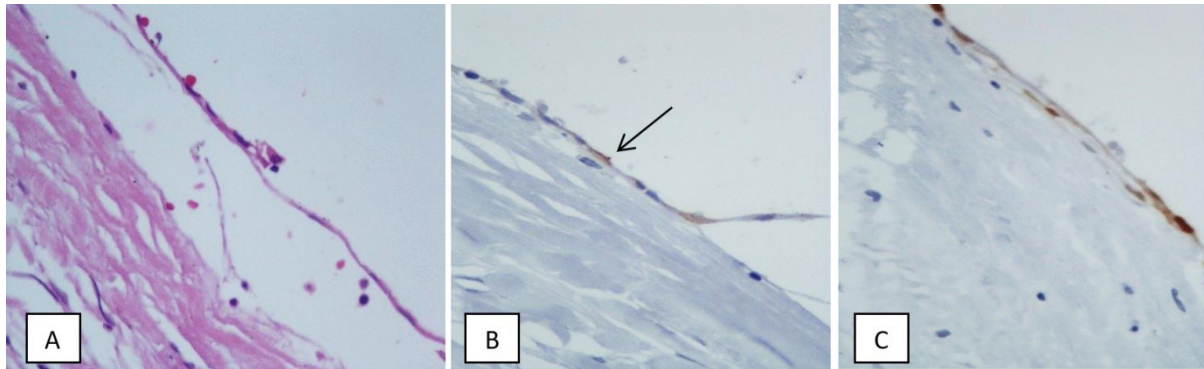


Fig.2: (A) Fibrous cyst wall lined by flat epithelial cells. (B) Positive reaction for cytokeratin (arrow). (C) Positive reaction of flat lining cells for calretinin

of hemosiderin laden macrophages. Lymphoid follicles were rather inconspicuous. The final pathological diagnosis was epithelial (mesothelial) cyst of spleen. During admission, no complication occurred.

DISCUSSION

Splenic cysts are rare findings (incidence is 0.75 per 100,000) and usually asymptomatic. They are incidentally found during ultrasonography or other imaging modalities.¹ They can be classified as true or false cysts depending on whether they have an epithelial lining layer. True cysts can be either congenital or acquired. False cysts or pseudocysts of the spleen originate from traumatic injury, hemorrhage, infection, and infarction.^{2,3}

The main differential diagnoses of acquired splenic cyst are parasitic disease, epidermoid/epithelial cyst, dermoid cyst, hemangioma, and/or lymphangioma. Congenital splenic cysts are called epithelial or epidermoid.³ They are mainly primary non-parasitic splenic cysts (PNSC), and constitute approximately 10% of the total cysts. These lesions occur most commonly in children and young female patients, and have a good prognosis.² Most of the cysts are asymptomatic and diagnosed incidentally. The symptoms are related to the size of the cyst and its complications such as infection, rupture, and/or bleeding. Patients with large splenic cysts may complain of early satiety, and LUQ discomfort or pain. Sometimes large cysts lead to splenomegaly, which causes dyspnea, shoulder pain, and constipation due to pressure effect on adjacent visceral organs. The most serious complication of large splenic cyst is spontaneous or traumatic rupture leading to life threatening intra-abdominal hemorrhage.⁴ The patient's history (age, sex, history of trauma, and duration of symptoms) may be

helpful in some cases to determine the etiology of the cyst.⁵

The indication for treatment is not clear and depends on the size and nature of the cyst and symptoms. Large cysts have tendency to develop serious complications such as rupture, so they are candidate for surgery.

Cysts larger than 5 cm are at risk of rupture and have a low probability of spontaneous recovery. Therefore, their treatment is absolutely necessary and laparoscopy/laparotomy splenectomy is the method of choice.⁶⁻⁸

CONFLICT OF INTEREST

The authors declare no conflict of interest related to this work.

REFERENCES

1. Belekara D, Desai A, Dewoolkar A, Dewoolkar V, Bhutala U. Splenic epithelial cyst: A rare entity. *Int J Surg* 2010;**22**:1-8.
2. Cianci P, Tartaglia N, Altamura A, Fersini A, Vovola F, Sanguedolce F, et al. A recurrent epidermoid cyst of the spleen: report of a case and literature review. *World J Surg oncology* 2016;**14**:1. doi:10.1186/s12957-016-0857-x.
3. Mirilas P, Mentessidou A, Skandalakis JE. Splenic cysts: are there so many types? *J Am Coll Surg* 2007;**204**:459-65. doi: 10.1016/j.jamcollsurg.2006.12.012.
4. Fragandreas G, Papadopoulos S, Gerogiannis I, Spyridis C, Tsantilas D, Venizelos I, et al. Epithelial splenic cysts and life-threatening splenic rupture. *Chirurgia (Bucur)* 2011;**106**:519-22.
5. Morgenstern L. Nonparasitic splenic cysts: pathogenesis, classification, and treatment. *J Am Coll Surg* 2002;**194**:306-14. doi:10.1016/S1072-7515(01)01178-4.
6. Şurlin V, Georgescu E, Râmboiu S, Dumitrescu C, Bratiloveanu T, Georgescu I. Large splenic cysts at the upper pole of the spleen—laparoscopic management. *J De Chirurgie* 2011;**7**:93-100.
7. Macheras A, Misiakos EP, Liakakos T, Mpistarakis D, Fotiadis C, Karatzas G. Non-parasitic splenic cysts: a report of three cases. *World J Gastroenterol* 2005;**11**:6884-7. doi: 10.3748/wjg.v11.i43.6884.
8. Palmieri I, Natale E, Crafa F, Cavallaro A, Mingazzini PL. Epithelial splenic cysts. *Anticancer Res* 2005;**25**:515-21.