



Letters to the Editor

Successful rapid drug desensitization to methotrexate in a patient with primary central nervous system lymphoma

TO THE EDITOR: Anaphylactic reaction to methotrexate (MTX) due to hypersensitivity to the drug is rare but can be fatal [1]; thus, prompt and adequate management is critical, particularly in cases of primary central nervous system lymphoma (PCNSL) in which MTX is a key therapeutic agent [2]. We herein report the first case of a successful 12-step desensitization to high-dose methotrexate (HD-MTX) in a patient with PCNSL who had recurrent episodes of anaphylaxis to HD-MTX.

A 49-year-old man with intermittent headache was diagnosed with PCNSL via stereotactic surgical biopsy of lesions in the left frontal lobe. The patient had no previous history of hypersensitivity or allergic reactions to any drugs or foods. We initially planned a total of 6 cycles of chemotherapy—4 cycles of HD-MTX (3.5 g/m^2) followed by 2

cycles of high-dose cytarabine (HD-AraC) (3 g/m^2) combined with HD-MTX. In the first cycle, intravenous (IV) HD-MTX infusion is usually given to patients over 2 hours on the first day; however, when the patient had received approximately 1.5 g of MTX after 30 minutes from starting the infusion, urticarial rashes with pruritus suddenly developed at the face, neck, and anterior chest area (Fig. 1). Throat tightness soon followed with a decrease in oxygen saturation level to 92% as measured via pulse oximetry, which prompted immediate cessation of HD-MTX infusion.

After administration of 4 mg IV chlorpheniramine and 100 mg hydrocortisone, the symptoms gradually improved without the need for epinephrine injection. On the following day, the same dose of HD-MTX was administered again but with premedication of IV chlorpheniramine and hydrocortisone. Nevertheless, identical symptoms and signs of hypersensitivity were immediately evident, and HD-MTX infusion was again halted. After the second episode of anaphylaxis, the serum level of creatinine was elevated from 0.91 mg/dL to 1.72 mg/dL. Moreover, serum level of MTX was markedly elevated at $2.74 \mu\text{mol/L}$ at 48 hours after the first infusion, which necessitated a rescue regimen using high-dose leucovorin. Once renal function was normalized,

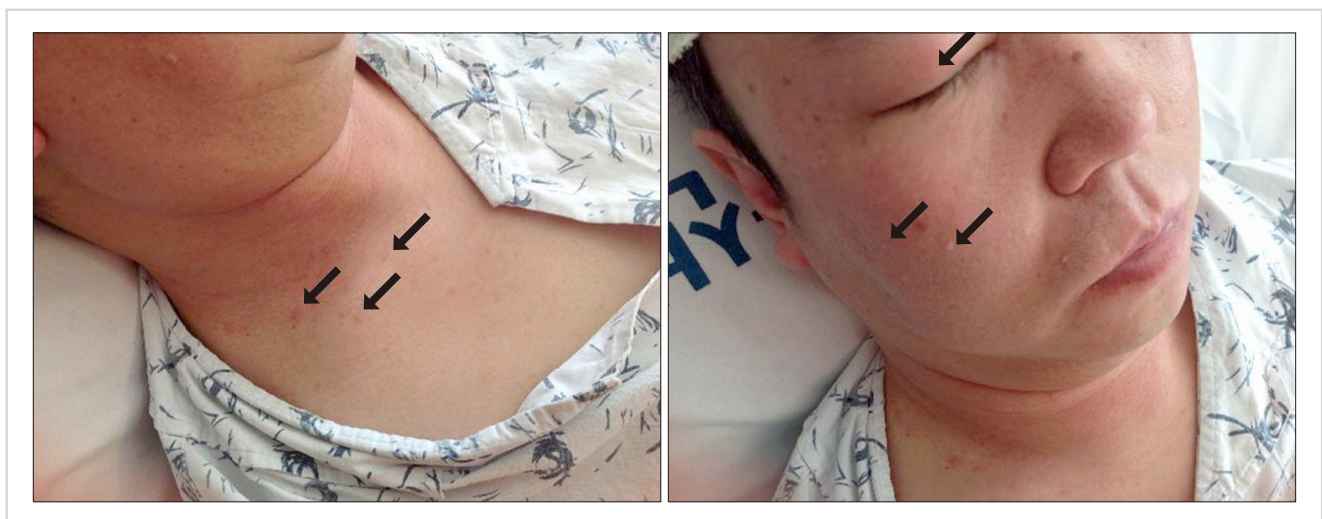


Fig. 1. Hypersensitivity skin reaction after methotrexate infusion. After 30 minutes of methotrexate infusion, urticarial rashes developed in the face, neck, and anterior chest area.

Table 1. Rapid intravenous desensitization to 7 g of methotrexate in a patient with CNS lymphoma.

Full dose	7,000.0 mg	Total dose to be injected in each bottle (mg)			
Solution A	100 mL of 0.14 mg/mL	14			
Solution B	100 mL of 1.40 mg/mL	140			
Solution C	500 mL of 14 mg/mL	7,000			
Step	Solution	Rate (mL/h)	Time (min)	Administered dose (mg)	Cumulative dose (mg)
1	A	2	15	0.07	0.07
2	A	5	15	0.18	0.25
3	A	10	15	0.35	0.6
4	A	20	15	0.7	1.3
5	B	5	15	1.75	3.05
6	B	10	15	3.5	6.55
7	B	20	15	7	13.55
8	B	40	15	14	27.55
9	C	10	15	35	62.55
10	C	20	15	70	132.55
11	C	40	15	140	272.55
12	C	80	360.40	6,727.47	7,000.02
Total time=525.40					

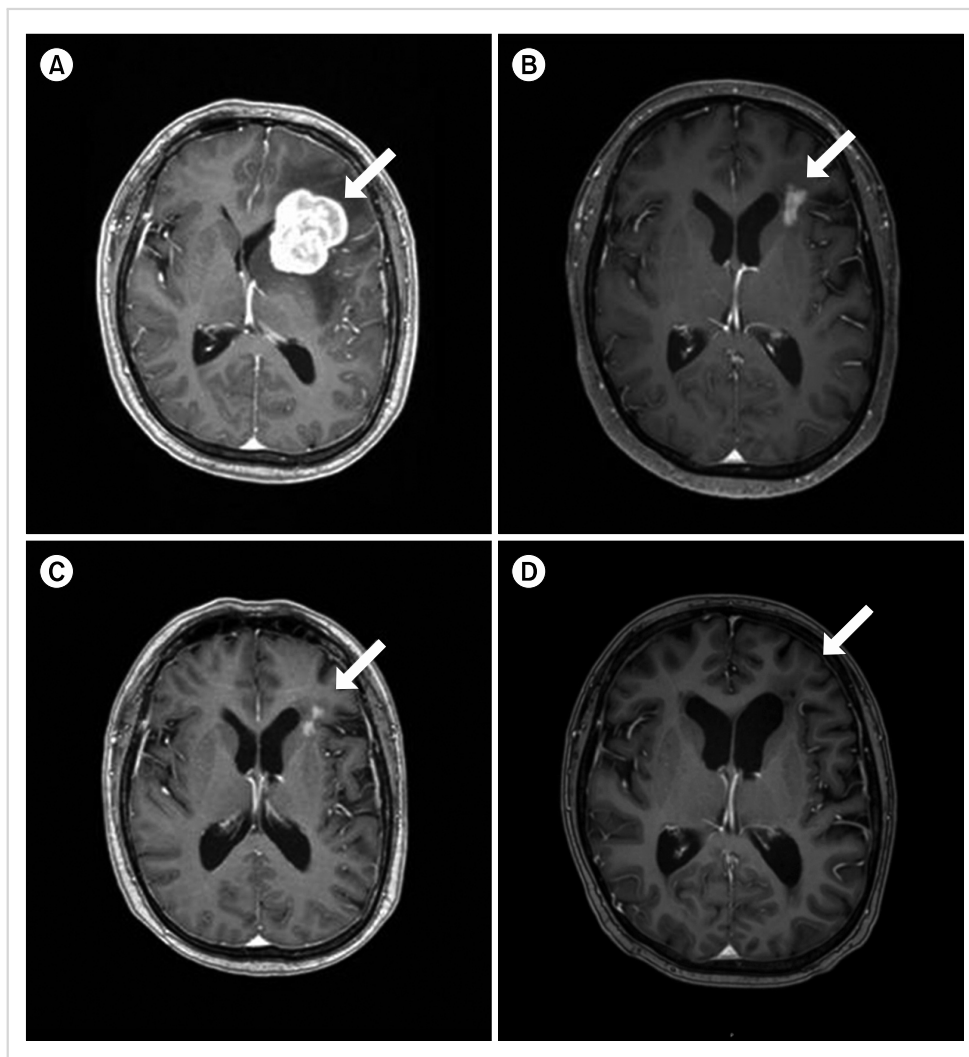


Fig. 2. MRI changes in the lymphoma lesion during chemotherapy. Prior to receiving chemotherapy, the size of the frontal lesion was approximately 4.1 cm with perilesional edema and midline shifting to the right side (A). After the fourth cycle of chemotherapy, partial remission was achieved, with decrease in tumor size to approximately 2.1 cm with perilesional edema as well as disappearance of midline shifting (B). After the sixth cycle of chemotherapy, the tumor further decreased to 1.8 cm with perilesional edema (C). After undergoing ASCT, the patient achieved CR (D).

HD-MTX was re-administered in the second cycle according to the desensitization protocol following the instruction of the Allergy Department of our institution. The total dose of MTX was lowered from 7.0 g to 3.5 g.

During desensitization, the patient's vital signs were closely monitored via pulse oximetry and electric monitors, and resuscitation equipment and medications were prepared at the bedside. A total of 20 mg of dexamethasone was administered as premedication at 12, 6, and 1 hour before starting desensitization, and 4 mg chlorpheniramine and 20 mg famotidine were also administered 1 hour before. After premedication, the dose of MTX was gradually increased in 12 steps using three serially diluted solutions—solution A: 1:100 dilution; solution B: 1:10 dilution; solution C: final concentration (no dilution). Each step took 15 minutes except for the final step, which lasted for 6 hours, and the infusion rates were generally doubled every step. Details of the desensitization protocol are summarized in [Table 1](#). No hypersensitivity reaction during and after infusion was noted.

Leucovorin rescue therapy was started 24 hours after the completion of MTX infusion and was administered every 6 hours until the serum level of MTX reached below 0.1 $\mu\text{mol/L}$. The full MTX dose (7 g) was administered in the third cycle, and while the doses in each solution were increased, other schemes of infusion remained the same as previous cycles. Three additional cycles of HD-MTX were successfully administered following this protocol, and partial remission was achieved after the fourth cycle of desensitized HD-MTX. After six cycles of chemotherapy, the size of the frontal lesion was further decreased ([Fig. 2](#)). Subsequently, the patient received high-dose conditioning chemotherapy with thiotepa, busulfan, and cyclophosphamide followed by autologous stem cell transplantation (ASCT). The patient achieved complete response (CR) of PCNSL and did not experience recurrence for 9 months after the ASCT.

Discussion

Anaphylaxis is a fatal hypersensitivity reaction that does not necessarily need prior exposure or sensitization [3, 4].

In our case, the patient with PCNSL experienced recurrent episodes of anaphylaxis to HD-MTX, which has been rarely reported in patients with PCNSL. Although we did not perform either skin test for MTX hypersensitivity or blood test to measure the serum level of tryptase, this was defined as an anaphylaxis because the hypersensitivity reaction occurred immediately after the first exposure to HD-MTX.

PCNSL is a rare subtype of B-cell lymphoma that generally presents with an aggressive natural course and unsatisfactory outcomes [5]. MTX became the most widely used single agent for patients with PCNSL because it was shown to markedly improve the survival outcomes [2, 5]. Therefore, even in the case of anaphylaxis, desensitizing the patient to MTX seems a more favorable course of treatment rather than switching to an alternative chemotherapy agent. Because the infusion time of MTX is prolonged as the concentration is lowered during the desensitization process, potential risks of relatively high toxicities and low anti-neoplastic effect should not be overlooked when considering desensitization [6].

Several reports have suggested various protocols of MTX desensitization ([Table 2](#)). Davis *et al.* [7] started the infusion with 0.2 mg/mL of MTX and approximately doubled the dose every hour until it reached 12 mg/mL. The dose was then increased to 18.05 mg/mL, which was infused for 4 hours. MacGinnitie *et al.* [8] applied a three-week step-up protocol in which the starting dose was increased by 10-fold every week for three weeks. Bouchireb *et al.* [9] progressively increased the MTX dose that started at 1:1,000 and 1:100 dilution of the planned dose infused for 90 minutes to 1:10 dilution infused for 6 hours and the remaining dose for 18 hours. In our case, rapid drug desensitization (RDD) protocol was used, which is a more recently established protocol developed at Brigham and Women's Hospital (Boston, MA, USA). RDD is considered the safest and most effective protocol thus far based on several hundred cases [10]. Concurrently, RDD is very efficient in that it takes a shorter infusion time than other protocols.

In summary, a patient with anaphylaxis to HD-MTX was safely and successfully desensitized without any toxicity or additional hypersensitivity event. The patient finally ach-

Table 2. Reported cases of MTX desensitization.

Age (yr)/ Gender	Diagnosis	Desensitization protocol			References
		Initial dose of MTX	Total dose of MTX	Steps	
22/M	Osteosarcoma	1/90 of total dose	24 g	Gradually increased through 8 steps	Davis <i>et al.</i> [7]
15/M	Acute lymphoblastic leukemia	1st week 1/10 ⁵ mg/mL 2nd week 1/10 ⁴ mg/mL 3rd week 1/10 ³ mg/mL	30 mg/m ²	Every step, increased 10-fold until reaching 1 mg/mL. And then maintaining 1 mg/mL Every week, starting dose was increased 10-fold for 3 weeks	MacGinnitie <i>et al.</i> [8]
9/F	Osteosarcoma	1/10 ³ of total dose	12 g/m ²	Every step, infusion rate increased 10-fold in total 4 steps	Bouchireb <i>et al.</i> [9]
12/F	Osteosarcoma	1/10 ³ of total dose	8 g/m ²	Every step, infusion rate increased 10-fold in total 4 steps	Oulego-Erroz <i>et al.</i> [6]

ieved CR after receiving the planned chemotherapy followed by ASCT. Collectively, our results show that the RDD protocol is a safe and effective treatment option for PCNSL patients with anaphylaxis to HD-MTX.

Kyung Mee Song^{1#}, Junghwan Lee^{1#}, Ji Hyun Park^{2#},
So-Young Park³, Tae-Bum Kim³, Cheolwon Suh²

Departments of ¹Internal Medicine, ²Oncology,
³Allergy and Clinical Immunology, Asan Medical Center,
University of Ulsan College of Medicine, Seoul, Korea

Correspondence to: Cheolwon Suh

Department of Oncology, Asan Medical Center, University
of Ulsan College of Medicine, 88 Olympic-ro 43-gil,
Songpa-gu, Seoul 05505, Korea
E-mail: csuh@amc.seoul.kr

Received on Mar. 30, 2017; Accepted on May 27, 2017

<https://doi.org/10.5045/br.2018.53.1.71>

[#]KM Song, J Lee, and JH Park contributed equally to this work.

Authors' Disclosures of Potential Conflicts of Interest

No potential conflicts of interest relevant to this article were reported.

REFERENCES

1. Pugi A, Benemei S, Vietri M, et al. Anaphylaxis during the first course of high-dose methotrexate: a case report and literature review. *J Clin Pharm Ther* 2012;37:245-8.
2. Ferreri AJ. How I treat primary CNS lymphoma. *Blood* 2011;118:510-22.
3. Ring J, Behrendt H. Anaphylaxis and anaphylactoid reactions. Classification and pathophysiology. *Clin Rev Allergy Immunol* 1999;17:387-99.
4. Ring J, Behrendt H, de Weck A. History and classification of anaphylaxis. *Chem Immunol Allergy* 2010;95:1-11.
5. Hoang-Xuan K, Bessell E, Bromberg J, et al. Diagnosis and treatment of primary CNS lymphoma in immunocompetent patients: guidelines from the European Association for Neuro-Oncology. *Lancet Oncol* 2015;16:e322-32.
6. Oulego-Erroz I, Maneiro-Freire M, Bouzón-Alejandro M, Vázquez-Donsión M, Couselo JM. Anaphylactoid reaction to high-dose methotrexate and successful desensitization. *Pediatr Blood Cancer* 2010;55:557-9.
7. Davis KA, Williams P, Walker JC. Successful desensitization to high-dose methotrexate after systemic anaphylaxis. *Ann Allergy Asthma Immunol* 2003;90:87-9.
8. MacGinnitie AJ, Walensky LD, Turvey SE, et al. Management of an anaphylactoid reaction to methotrexate with a stepwise graded challenge. *Pediatr Allergy Immunol* 2003;14:409-11.
9. Bouchireb K, Dodille A, Ponvert C, Gouraud F, Dubrel M, Brugières L. Management and successful desensitization in methotrexate-induced anaphylaxis. *Pediatr Blood Cancer* 2009;52:295-7.
10. del Carmen Sancho M, Breslow R, Sloane D, Castells M. Desensitization for hypersensitivity reactions to medications. *Chem Immunol Allergy* 2012;97:217-33.

A rare case of splenic diffuse red pulp small B-cell lymphoma (SDRPL): a review of the literature on primary splenic lymphoma with hairy cells

TO THE EDITOR: Lymphomas with villous morphology are uncommon, and the rarest type is the splenic diffuse red pulp small B-cell lymphoma (SDRPL). Few SDRPL cases have been reported in the literature. There is considerable overlap with lymphomas that display villous lymphocytes in blood and splenomegaly, such as the rare variant hairy-cell leukemia, and splenic marginal zone lymphoma. Nonetheless, recent studies have produced clear, differentiating features regarding clinical, morphological, and immunophenotypical data. We highlight the case of a middle-aged male patient with massive splenomegaly and villous lymphocytes, diagnosed with SDRPL based on splenic histology and a characteristic immunoprofile. Diagnosis of SDRPL rests mainly on the exclusion of other lymphomas and on a correlation of bone marrow and spleen histology, and immunophenotyping. Our experience provides further support in considering this enigmatic lymphoma as a distinct entity within the WHO classification of lymphoid neoplasms.

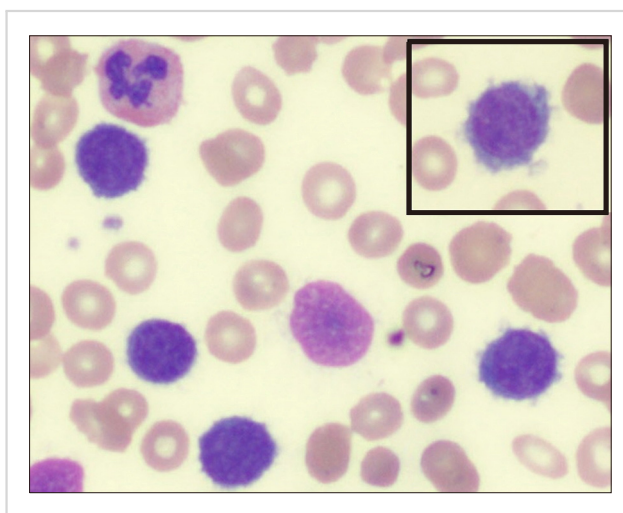


Fig. 1. Peripheral blood smear showed the presence of atypical lymphoid cells with numerous circumferential hair-like processes and inconspicuous nucleoli. Inset shows a neoplastic lymphocyte with appreciable villous processes.