

Pathophysiology and Treatment Options in Trigeminal Meningoceles

Matthias Preuss¹ Alexander Steinhoff² Constantin J. Zühlke³ Dirk Schulz¹ Marco Stein¹
Ulf Nestler¹ Petros Christophis¹

¹ Department of Neurosurgery, Justus-Liebig-University, Giessen, Germany

² Department of Neurosurgery, University Leipzig, Leipzig, Germany

³ Department of Neuroradiology, Justus-Liebig-University, Giessen, Germany

Address for correspondence Matthias Preuss, MD, Department of Neurosurgery, Pediatric Neurosurgery, University Hospital Leipzig, Liebigstrasse 20, D-04103 Leipzig, Germany (e-mail: preuss@kinderneurochirurgie-leipzig.de).

J Neurol Surg Rep 2013;74:81–87.

Abstract

Trigeminal meningoceles, lateral to the maxillary nerve (V2), have seldom been reported as underlying pathology for spontaneous rhinoliqorrhoea. In contrast to sphenoid meningoceles arising from a persistent lateral craniopharyngeal canal (Sternberg–Cruveilhier, medial to V2), their occurrence seems to be generated by addition of erosive processes to the constitutively thin bony shell underneath the semilunar ganglion, lateral to the round foramen (and V2).

The developmental and anatomical relationships of trigeminal meningoceles to the sphenoid bone are depicted, and in a review of the literature we present the different surgical approaches employed for sealing the dura leak. In view of these techniques we discuss an unusual case of therapy-resistant rhinoliqorrhoea with left-sided trigeminal meningocele involving the Meckel cave at the lateral sphenoid and reaching the superior orbital fissure and the medial orbital space.

In contrast to patients who have lateral sphenoidal meningoceles with a persistent lateral craniopharyngeal canal (Sternberg–Cruveilhier), who can be treated successfully using an endoscopic transsphenoidal approach (recurrence rate 13.7%), the recurrence rate of cerebrospinal fluid (CSF) efflux for trigeminal meningoceles lies much higher (endoscopically 66%, open craniotomy 33%). The surgical strategy thus has to be chosen individually, taking into account specific anatomical situations and eventually preceding operations.

Keywords

- ▶ cerebrospinal fluid (CSF)
- ▶ trigeminal meningocele
- ▶ spontaneous rhinoliqorrhoea
- ▶ Sternberg–Cruveilhier canal
- ▶ lateral craniopharyngeal canal

Introduction

Among the different entities causing rhinoliqorrhoea in closest proximity to the sphenoid bone, trigeminal meningoceles (TMs), lateral sphenoidal meningoceles (LSMs), and the persistence of the lateral craniopharyngeal canal (Sternberg–Cruveilhier canal, SC) have been described.

TMs have only been reported several times in the literature, and nomenclature is still heterogeneous. In general,

reports cover various mass lesions in the Meckel cave, ranging from lipoma and meningioma to schwannoma. Only a few deal with meningoceles in the pterygopalatine region, such as in patients with typical stigmata of neurofibromatosis Type 1 (NF 1).^{1,2}

TMs are localized in the lateral sphenoid wing lateral to V2 and the foramen rotundum underneath the semilunar ganglion, reaching to the superior orbital fissure, pterygopalatine fossa, and medial orbital space, mostly emerging from an

received
December 14, 2012
accepted after revision
April 13, 2013
published online
July 12, 2013

DOI <http://dx.doi.org/10.1055/s-0033-1348955>.
ISSN 2193-6358.

© 2013 Georg Thieme Verlag KG
Stuttgart · New York

License terms



enlarged Meckel cave and giving rise to osseous erosion of the sphenoid wing.

As a different and more frequent reason for rhinoliquorrhea, LSMs have been described. They lie medially to V2 near the base of the sphenoidal bone³⁻⁸ and can be distinguished from TMs by the absence of orbital or pterygopalatine fossa involvement.

The third dura leak-associated pathology of this region is the developmental anomaly of a persistent SC embryonal canal (lateral craniopharyngeal canal). Still controversially discussed in literature, it has been found in some cases as an underlying condition for LSMs.⁹⁻¹¹ The canal lies medially to the foramen rotundum and extends from the maxillary nerve root (V2) to a recess of the lateral sphenoid wall, opening into the sphenoid sinus.

Anatomical Considerations

From an anatomical point of view, there are several “weak spots” in the embryonic development of the sphenoidal bone, which can explain the occurrence of meningoceles or spontaneous rhinoliquorrhea, especially in the area of the trigeminal ganglion and the carotid artery.

The cartilage precursor of the skull base has to form around the cranial nerves, arteries, and veins while respecting their lumen. This can lead to thinned cranial base structures that might be eroded during a lifetime by inflammatory processes or increased intracranial pressure.¹²

The bone formation itself is inhomogeneous. The collision zone between endochondral ossification (lesser wing) and intramembranous ossification (greater wing) lies laterally to the foramen rotundum, extending to the region of the foramen ovale (►Fig. 1). In a computed tomographic (CT) study, 25 patients with lateral sphenoidal cerebrospinal fluid (CSF) leaks were all shown to have the bony defects in this area, lateral to the foramen rotundum.⁸

The sutures between the ossification centers can leave small basal clefts, such as the lateral craniopharyngeal canal

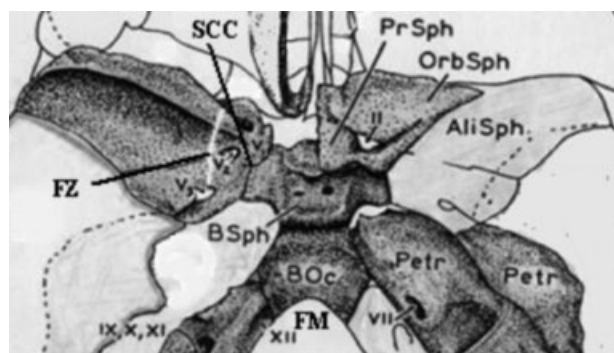


Fig. 1 Cranial base in a 6-month-old embryo shown from above (modified from Fenart and Landouzy) depicting the four main parts forming the sphenoid bone. Cranial nerves: II, V₁, V₂, V₃, VII, IX, X, XI, XII. AliSph, alisphenoid; BOc, basioccipitale; BSph, basisphenoid; FM, foramen magnum; FZ, fusion zone between (lateral) and endochondral (medial) ossification; OrbSph, orbitosphenoid; Petr, petrous bone; PrSph, petrosphenoid; SCC, site of the Sternberg-Cruveilhier canal.

(SC). The canal represents a remnant of the fusion zone between the alisphenoid (greater wing) and the basisphenoid (►Fig. 1).¹³

Development of the sphenoid bone is crucial for the whole cranial base.¹⁴⁻¹⁶ Distorted midline structure development can result in encephaloceles and palate cleft malformations,¹⁷⁻¹⁹ and midline basal encephaloceles are known as very rare malformations.^{11,20} Lateral sphenoid malformations give rise to lateral sphenoid meningoceles, as well as to meningoceles of the trigeminal nerve. The meningoceles seem to be associated with sphenoid bone malformations, increased intracranial CSF pressure, and accompanying erosive processes. As shown in the following case description, TMs can result in rhinoliquorrhea and CSF leakage to the pterygopalatine fossa and periorbital fatty tissue, followed by exophthalmos and conjunctivitis together with conjunctival edema.

Nomenclature

In literature, many different terms have been employed to describe the pathology of a TM. *Arachnoid cyst of Meckel's cavity* appears to be imprecise, because LSMs also arise from it. The terms *transalar sphenoid meningocele* and *transsphenoidal and transtethmoidal meningoceles* have been used synonymously in literature.^{19,20}

We suggest the term *lateral sphenoidal meningocele* to describe pathologies medial to V2 and the term *trigeminal meningoceles* as anatomically more precise for lesions lateral to the foramen rotundum and V2.

Illustrative Case

A 29-year-old woman presented to the outpatient clinic for rhinoliquorrhea. She also reported a left-sided orbital swelling, especially when bending forward or in prone position. The patient experienced headaches, intermittent rhinoliquorrhea, vomiting, and chronic conjunctivitis. Her first meningitis had been at the age of 17 years, a second occurred a few years later, and both had been treated successfully with antibiotics. A former traumatic head injury was denied and basal cranial fractures had been ruled out with multiple imaging techniques.

Extended neuroradiological imaging included cisternographic magnetic resonance (MR) scan after intrathecal gadolinium-application in prone position. It revealed a left-sided CSF leak along a CSF-containing enlargement of the temporal fossa that extended into the pterygopalatine fossa. CSF was seen in the periorbital fatty tissue and the temporal muscle (►Fig. 2a). Origin of the fistula was suspected in the temporopolar parasellar region in close proximity to the cavernous sinus and to the Meckel cavity. The clivus, sellar area, and ethmoidal cells appeared to be anatomically altered in the CT-scan (►Fig. 2b-d).

The surgical strategy was discussed in the multidisciplinary skull-base board and under suspicion of a temporomedial meningocele of the maxillary nerve, a pterional craniotomy with transsylvian approach and closure of the parasellar

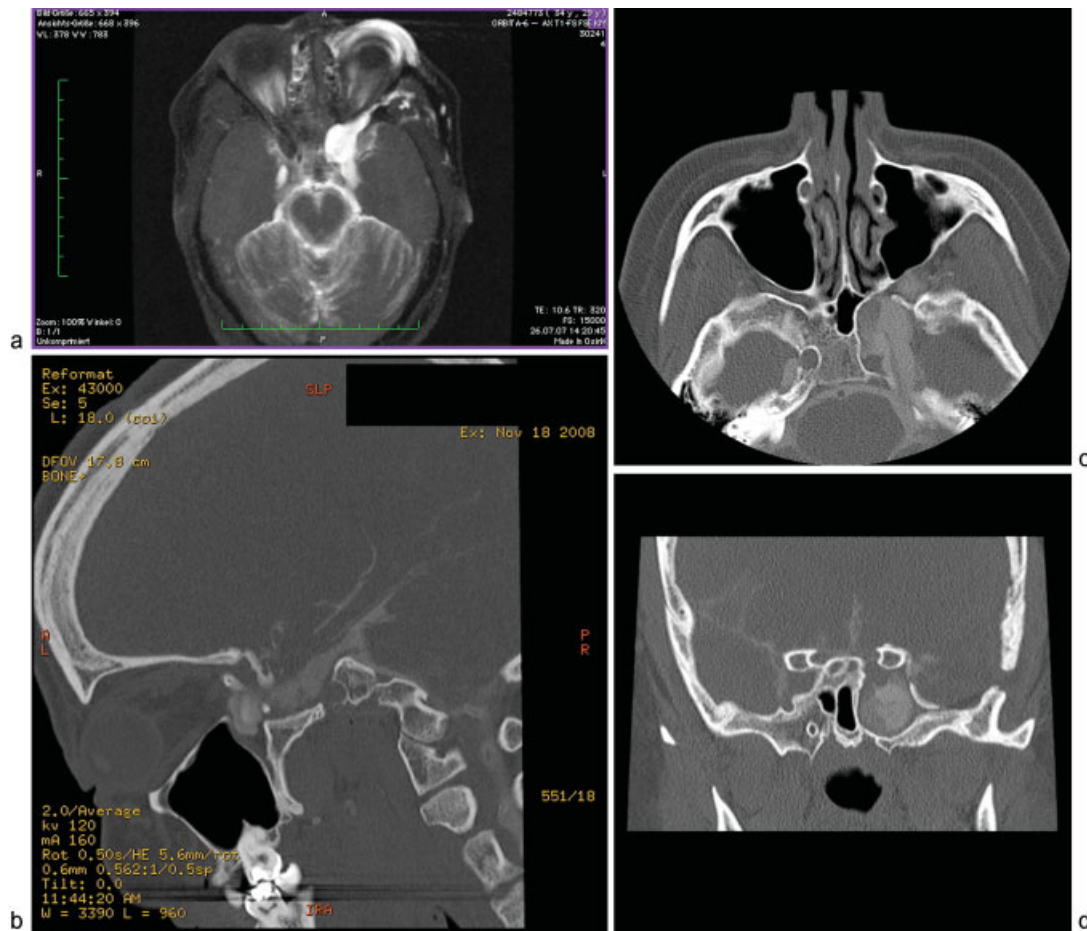


Fig. 2 (a) Preoperative magnetic resonance (MR) T1-weighted axial images enhanced by cisternography. Computed tomography enhanced by cisternography. (b) Oblique reconstruction parallel to the optic canal, (c) axial and (d) coronal reconstruction.

entry point of the meningocele was advised. In a first operation, the suspected entry point of the fistula was closed using multiple layers of subgaleal tissue. The efflux of CSF was stopped but reappeared after several months. The patient then decided to be treated in another neurosurgical department, where a second pterional operation was performed without relieving the symptoms.

About 2 years after first surgery, the patient decided to restart treatment in our institution. Intrathecal contrast-enhanced CT revealed the refilled fistula and an enlarged, CSF-containing space in the paraclival region, close to the maxillary nerve and the Meckel cave. A third pterional exploration was proposed, but the patient opted for conservative therapy. Only after increasing orbital swelling and reappearance of rhinoliquorrhea did the patient agree to another intervention.

After this intervention, an oculomotor palsy prompted surgical revision. Fusion of the CT dataset with neuronavigation pictures allowed identification of the entrance of the Meckel cavity. This was covered by dura mater and could be punctured for aspiration of CSF. The wall of the cavity showed a cisternlike arachnoid covering in which the nerve fibers crossing the cavity were partly adhering to the basal arachnoid layer of the cyst and were spread apart. Two walls of the

cavity were found, corresponding to arachnoid cystic structures and dural tissue, thus displaying typical criteria for meningoceles. To close the fistula, abdominal fat and muscle tissue were harvested and the periarachnoid space of the Meckel cave was filled in proximal and distal direction. Hereafter, fat tissue was positioned in the remaining arachnoid space rostrally. Between fat and muscle tissue, liquid dura glue (DuraSeal Xact, Covidien, Mansfield, Massachusetts, USA) was injected into the cavity along the maxillary nerve. Additional muscle was placed on top and covered with fibrin glue. The opening of the cavity was sealed with TachoSil (Takeda Pharmaceuticals; Zurich, Switzerland) and Surgicel (Ethicon, Somerville, New Jersey, USA).

After this intervention, rhinoliquorrhea and orbital swelling disappeared and the third nerve palsy nearly completely recovered within 3 months.

However, about 4 months postoperatively the patient experienced an intermittent CSF leak. Shortly thereafter, orbital swelling and conjunctivitis reoccurred. T2- and CISS 3D T2-scans revealed a partly occluded, yet CSF-containing, meningocele. The patient refused any further interventions, especially implantation of a ventriculoperitoneal (VP) shunt to reduce the intracranial CSF pressure, and she was lost to follow-up.

Table 1 Overview of reported cases of trigeminal meningoceles, Sternberg canals, and lateral sphenoid meningoceles

| Patient | Age/ Gender | Symptoms | Diagnosis | Radiological findings | Therapy | Complications | f/u |
|-----------------------------------|------------------------------|---|-----------|---|---|---|--------------------|
| Present case | 30/f | Orbital swelling, rhinorrhea, cephalgia | TM, SC | Dysplasia of left sphenoid | Pterional craniotomy (3×) | Recurrent leakage, temporary third nerve palsy | 24 months |
| Schick et al (1999) | 29/f | Rhinoliquorrhea | TM, SC | Bony destruction of pterygoid base, intrasphenoidal meningocele | Frontotemporal craniotomy | None | n.d. |
| Chapman et al (2000) | 8/m | Meningitis, rhinosinusitis | TM | Enlargement of Meckel cave, enlargement of SOF | Middle fossa approach | CSF collection temporal left | 18 months |
| Blaivie et al (2006) | 73/f | Rhinoliquorrhea, meningitis | TM | Paramedial left lacuna in sphenoidal sinus | Transsphenoidal endoscopic surgery | Died during follow-up from cardiac failure | 4 months |
| Castelnuovo et al (2007) 15 cases | 60.3 ± 6.3, 9 female, 6 male | Rhinoliquorrhea (x = 15), headache and meningitis | SC | Sphenoidal dysplasia | Paraseptal direct transsphenoidal approach (×7), transethmoidal-pterygoid-sphenoidal approach | No major complications, no recurrences | 37.6 ± 21.7 months |
| Tomazic et al (2009) 5 cases | 44 ± 2, 4 female, 1 male | rhinoliquorrhea (x = 5), cephalgia (x = 2) | SC | 3xright, 2xleft-sided dysplasia of sphenoid with SC | 3× transethmoidal-sphenoidal-pterygoid approach, 2× transethmoidal-sphenoidal approach | 1× maxillary nerve irritation, 2× recurring liquorrhea, 1× bacterial meningitis | Up to 4 months |
| Tabaee et al (2010) case 1 | 61/f | Rhinoliquorrhea, cephalgia | LSM, SC | Sphenoidal dysplasia | Transnasal endoscopic surgery | None | 11.3 years |
| Tabaee et al (2010) case 2 | 37/f | Rhinoliquorrhea, cephalgia | LSM, SC | Sphenoidal dysplasia | Transnasal endoscopic surgery | Perioperative meningitis | 12.1 years |
| Tabaee et al (2010) case 3 | 78/f | Cephalgia, meningitis | LSM, SC | Sphenoidal dysplasia | Transnasal endoscopic surgery | None | 0.7 years |
| Tabaee et al (2010) case 4 | 44/f | Rhinoliquorrhea, cephalgia | LSM, SC | Sphenoidal dysplasia | Frontotemporal craniotomy | None | 5.0 years |
| Tabaee et al (2010) case 5 | 36/f | Rhinoliquorrhea, cephalgia | LSM, SC | Sphenoidal dysplasia | Frontotemporal craniotomy | None | 5.7 years |
| Tabaee et al (2010) case 6 | 66/f | Cephalgia, meningitis | LSM, SC | Sphenoidal dysplasia | Frontotemporal craniotomy | Facial paresthesia | 3.0 years |
| Tabaee et al (2010) case 7 | 73/f | Rhinoliquorrhea, cephalgia, meningitis | LSM, SC | Sphenoidal dysplasia | Transethmoidal endoscopic surgery | None | 3.2 years |

Table 1 (Continued)

| Patient | Age/ Gender | Symptoms | Diagnosis | Radiological findings | Therapy | Complications | f/u |
|-----------------------------|-------------|-----------------------------|-----------|--|--|--|-----------|
| Tabaee et al (2010) case 8 | 44/f | Rhinoliquorrhea, cephalgia | LSM, SC | Sphenoidal dysplasia | Transethmoidal endoscopic surgery | Persistent leak requiring revision, endoscopic closure | 3.6 years |
| Tabaee et al (2010) case 9 | 59/m | Rhinoliquorrhea | LSM, SC | Sphenoidal dysplasia | Transethmoidal endoscopic surgery | None | 2.9 years |
| Tabaee et al (2010) case 10 | 56/m | Rhinoliquorrhea | LSM, SC | Sphenoidal dysplasia | Transethmoidal endoscopic surgery | Persistent leak that closed spontaneously | 3.2 years |
| Tabaee et al (2010) case 11 | 73/m | Rhinoliquorrhea | LSM, SC | Sphenoidal dysplasia | Transethmoidal endoscopic surgery | None | 3.3 years |
| Tabaee et al (2010) case 12 | 47/m | Rhinoliquorrhea, cephalgia | LSM, SC | Sphenoidal dysplasia | Transnasal endoscopic surgery | None | 4.3 years |
| Tabaee et al (2010) case 13 | 68/m | Rhinoliquorrhea, cephalgia | LSM, SC | Sphenoidal dysplasia | Transnasal endoscopic surgery | None | 3.2 years |
| Bendersky et al (2011) | 46/f | Rhinoliquorrhea, meningitis | TM, SC | Herniated temporal lobe into sinus sphenoidalis, bony defect related to SC | Transsphenoidal surgery, fronto-temporal craniotomy | Recurrence of CSF leak 2 months after transsphenoidal approach | 3 years |
| Bendersky et al (2011) | 73/f | Rhinoliquorrhea | TM, SC | Intrasphenoidal encephalocele, SC right | Transnasal endoscopic surgery (3x), fronto-temporal craniotomy | after fourth intervention no recurrence? | 2 years |

Abbreviations: CSF, cerebrospinal fluid; LSM, lateral sphenoid meningocele; SC, Sternberg-Cruveilhier canal; SOF, superior orbital fissure; TM, trigeminal meningocele.

Review of the Literature

Review of the literature was performed in the Medline database using the search terms *trigeminal, encephalocele, Meckel's cave, sphenoid, pterygopalatine, CSF fistula*, and *Sternberg* in all combinations of two keywords.

Search resulted in 38 relevant cases from 23 reports, ranging from 1888 to 2011 (► **Table 1**). Within these 38 reports, female predominance was found (gender ratio 1.92:1 f:m). Mean age was 52.9 years (age range 8 to 78 years). Patients presented with rhinoliquorrhea in 92.1% (35 patients), headaches in 34.2% (13 patients), and meningitis in 15.7% (6 patients).

Out of 38 patients, 6 had a TM, whereas a persistent SC or LSM was found in 32 patients.

One patient did not receive surgery, leading to persistence of symptoms. A total of 29 patients underwent endoscopic surgery for LSMs, whereas in 3 cases the transcranial approach was preferred. In two cases⁴ transcranial reoperation was performed after endoscopic surgery due to recurrence of CSF leaks.⁴ Recurrence rate was 13.7% (4 of 29 cases).

From the six TMs, three were treated by an endoscopic transsphenoidal approach, with recurrence of CSF leaks in two of them (66%). A third case died perioperatively due to cardiac failure during follow-up. One of three patients undergoing craniotomy and open repair experienced recurrent therapy-resistant CSF leakage (present case, 33%).

Apart from persistent rhinoliquorrhea, the most common complications in the endoscopic group were meningitis (6.3%) and maxillary nerve irritation (3.1%). In the craniotomy group, facial paresthesia (3.1%) and transient diplopia (3.1%) were encountered.

Discussion

The case presented here illustrates a rare TM extending from an enlarged Meckel cave into the medial cranial and pterygopalatine fossa, causing therapy-resistant CSF leakage and orbital affection with an unusual collection of CSF in the temporal muscle (► **Fig. 2**). Although the predominant symptoms of CSF leaks such as rhinoliquorrhea, headache, and meningitis do not help in localizing the dural defect, clinical appearance may vary with the localization of the specific arachnoidal cyst, meningocele, or encephalocele. For example, arachnoid cysts of the region of the Meckel cavity often become symptomatic with facial numbness or pain due to their relation to the trigeminal nerve.²¹

The therapeutic difficulties of that unusual entity have not been solved. In contrast to the far lateral TMs, LSMs and persistent SC can be treated successfully with a transsphenoidal approach. This may be caused by their more medial localization, medially to the foramen rotundum and V2 at the sphenoid base.

Patients with TMs are likely to have a greater benefit from a transcranial approach, which provides better access to the lateral aspects of the Meckel cave and the semilunar ganglion. This is underlined by the higher recurrence rate when using the transsphenoidal approach (► **Table 1**). Alternatively,

transmaxillary transpterygoid approaches may be employed for TMs with a limited pterygoid fossa leakage.¹

CSF leaks associated with TMs can be assumed to be of idiopathic origin with an elevated intracranial pressure (ICP) as an additional factor. Thus, ICP recording and ICP normalization should be taken into account, and routine use of lumbar drainage as a diagnostic and therapeutic measure has been proposed in lateral sphenoid CSF leaks.²²

In light of the reviewed literature, together with the presented therapy-resistant case, alternative strategies such as implantation of a VP shunt or temporary lumbar drainage to reduce CSF pressure have to be discussed. The occurrence of the spontaneous CSF leak as part of an idiopathic hydrocephalus syndrome should be considered, with acetazolamide or furosemide being a treatment option.²² However, the one case treated conservatively experienced persistence of symptoms, similar to our patient, who experienced recurrence after deciding for nonsurgical follow-up (► **Table 1**). Midfacial degloving has been suggested as approach to the pterygopalatine fossa meningoceles and remains an option for recurrence.²¹

A staged treatment algorithm using lumbar CSF drainage, ICP recording, and invasive location of the skull base defect with intrathecal administration of contrast medium seems to be most promising. Depending on the location and anatomical shape of the TM, open craniotomy or endoscopic transpterygoid approach can be selected.^{6-8,22} Whereas for medial pathologies (SC, LSM) endoscopic transsphenoidal approaches appear to be advantageous, TMs should be primarily considered for an open craniotomy. Alternatively to transcranial approaches, transfacial or transmaxillary/transpterygoid approaches have to be considered as treatment for recurrent, extended TMs involving the pterygopalatine fossa, in which transsphenoidal endoscopic techniques have limited success rates.

In case of therapy-refractory CSF leaks and marked elevation of ICP, VP shunt placement and/or medical treatment should be considered before reintervention.²²

Conclusion

Compared with the spontaneous rhinoliquorrhea caused by a persistent SC or LSMs, the point of leakage in TMs lies laterally to V2 and cannot always clearly be visualized, even by sophisticated neuroradiological techniques. This can result in considerable technical difficulties and therefore therapeutic decisions should follow the advice of a multidisciplinary skull base team after taking into account the individual anatomic situation of a patient, preceding operations, and specific risk factors for elevated ICP.

References

- 1 Chapman PH, Curtin HD, Cunningham MJ. An unusual pterygopalatine meningocele associated with neurofibromatosis type 1. Case report. *J Neurosurg* 2000;93(3):480-483
- 2 de Vries J, Freihofer HPM, Menovsky T, Cruysberg JRM. Successful surgical repair of progressive exophthalmos caused by a

- meningocele in a patient with neurofibromatosis Type 1. Case report. *J Neurosurg* 1998;89(6):1032–1035
- 3 Barañano CF, Curé J, Palmer JN, Woodworth BA. Sternberg's canal: fact or fiction? *Am J Rhinol Allergy* 2009;23(2):167–171
 - 4 Bendersky DC, Landriel FA, Ajler PM, Hem SM, Carrizo AG. Sternberg's canal as a cause of encephalocele within the lateral recess of the sphenoid sinus: A report of two cases. *Surg Neurol Int* 2011;2:171
 - 5 Blaivie C, Lequeux T, Kampouridis S, Louryan S, Saussez S. Congenital transsphenoidal meningocele: case report and review of the literature. *Am J Otolaryngol* 2006;27(6):422–424
 - 6 Castelnuovo P, Dallan I, Pistochini A, Battaglia P, Locatelli D, Bignami M. Endonasal endoscopic repair of Sternberg's canal cerebrospinal fluid leaks. *Laryngoscope* 2007;117(2):345–349
 - 7 Tabae A, Anand VK, Cappabianca P, Stamm A, Esposito F, Schwartz TH. Endoscopic management of spontaneous meningoencephalocele of the lateral sphenoid sinus. *J Neurosurg* 2010;112(5):1070–1077
 - 8 Tomazic PV, Stammberger H. Spontaneous CSF-leaks and meningoencephaloceles in sphenoid sinus by persisting Sternberg's canal. *Rhinology* 2009;47(4):369–374
 - 9 Sternberg M. Ein bisher nicht beschriebener Kanal im Keilbein des Menschen. *Anat Anz* 1888;3:784–785
 - 10 Radoievitch S, Jovanovitch S. [Cruveilhier-Sternberg embryonal canal (lateral craniopharyngeal canal) and its vestiges in the adult human]. *Rev Laryngol Otol Rhinol (Bord)* 1956;77(3–4):223–232
 - 11 Schick B, Brors D, Prescher A. Sternberg's canal—cause of congenital sphenoidal meningocele. *Eur Arch Otorhinolaryngol* 2000;257(8):430–432
 - 12 Wang EW, Vandergrift WA III, Schlosser RJ. Spontaneous CSF Leaks. *Otolaryngol Clin North Am* 2011;44(4):845–856, vii
 - 13 Sperber GH. *Craniofacial Embryology*. Boston: Wright PSG; 1981
 - 14 Michejda M. The role of basicranial synchondroses in flexure processes and ontogenetic development of the skull base. *Am J Phys Anthropol* 1972;37(1):143–150
 - 15 Laitman JT, Heimbuch RC, Crelin ES. Developmental change in a basicranial line and its relationship to the upper respiratory system in living primates. *Am J Anat* 1978;152(4):467–482
 - 16 Lieberman DE, McBratney BM, Krovitz G. The evolution and development of cranial form in *Homo sapiens*. *Proc Natl Acad Sci U S A* 2002;99(3):1134–1139
 - 17 Jeffery N, Spoor F. Brain size and the human cranial base: a prenatal perspective. *Am J Phys Anthropol* 2002;118(4):324–340
 - 18 Jeffery N, Spoor F. Ossification and midline shape changes of the human fetal cranial base. *Am J Phys Anthropol* 2004;123(1):78–90
 - 19 Pollock JA, Newton TH, Hoyt WF. Transsphenoidal and transethmoidal encephaloceles. A review of clinical and roentgen features in 8 cases. *Radiology* 1968;90(3):442–453
 - 20 Soyer P, Dobbelaere P, Reizine D, Ferquel C. Transalar sphenoidal meningoencephalocele associated with buccal angiomatosis. One case. *J Neuroradiol* 1990;17(3):222–226
 - 21 Kantas I, Tzindros G, Papadopoulou A, Marangos N. Midfacial Degloving: The Best Alternative for Treatment of Trans-sphenoidal Meningocele of the Pterygopalatine Fossa. *Skull Base* 2006;16(2):117–122
 - 22 Alexander NS, Chaaban MR, Riley KO, Woodworth BA. Treatment strategies for lateral sphenoid sinus recess cerebrospinal fluid leaks. *Arch Otolaryngol Head Neck Surg* 2012;138(5):471–478