



Since January 2020 Elsevier has created a COVID-19 resource centre with free information in English and Mandarin on the novel coronavirus COVID-19. The COVID-19 resource centre is hosted on Elsevier Connect, the company's public news and information website.

Elsevier hereby grants permission to make all its COVID-19-related research that is available on the COVID-19 resource centre - including this research content - immediately available in PubMed Central and other publicly funded repositories, such as the WHO COVID database with rights for unrestricted research re-use and analyses in any form or by any means with acknowledgement of the original source. These permissions are granted for free by Elsevier for as long as the COVID-19 resource centre remains active.



NEOPLASTIC DISEASE

CD56⁺ B-cell Neurolymphomatosis in a Cat

C.-S. Hsueh^{*}, C.-Y. Tsai[†], J. C.-S. Lee[†], C.-L. Kao[†], F.-I. Wang^{*,‡},
C.-R. Jeng^{*,‡}, H.-W. Chang^{*,‡}, V. F. Pang^{*,‡} and C.-H. Liu^{*,‡}

^{*}Graduate Institute of Molecular and Comparative Pathobiology, School of Veterinary Medicine, [†]National Taiwan University Veterinary Hospital, College of Bioresources and Agriculture and [‡]School of Veterinary Medicine, National Taiwan University, Taipei, Taiwan

Summary

A 16-year-old male Russian blue cat was presented with acute onset of paraparesis of the forelimbs that progressed to tetraparesis. Neurological examination revealed non-ambulatory tetraparesis with decreased postural reactions in all four limbs. Magnetic resonance imaging revealed multifocal nerve root swelling on the right at C6/C7 and C7/T1, while ultrasonography demonstrated swelling of the right brachial plexus. To understand the cause of the nerve swelling, the right musculocutaneous nerve arising from the brachial plexus and the pectoralis muscle were biopsied. Histologically, there was evidence of neurolymphomatosis (neurotropic lymphoma) with Wallerian degeneration and denervation atrophy of myofibres. The neoplastic lymphoid cells expressed CD79a, CD20 and CD56. Based on these findings, a diagnosis of B-cell neurolymphomatosis was made. Expression of CD56, synonymous with neural cell adhesion molecule, is rare in B-cell lymphomas and has not been reported in feline B-cell lymphomas or feline neurolymphomatosis. CD56 expression was suspected to have played an important role in neurotropism of the neoplastic cells in this case.

© 2019 Elsevier Ltd. All rights reserved.

Keywords: B-cell lymphoma; cat; neurolymphomatosis; peripheral neuropathy

Most lymphomas in the nervous system of domestic animals arise as part of generalized metastatic lymphoma (Higgins *et al.*, 2016). In cats, lymphoma is the most common neoplasm affecting the spinal cord and second most common neoplasm in the brain (Mandara *et al.*, 2016), but the overall prevalence of primary nervous system lymphoma is low. Lymphoma of the nervous system can manifest as intraparenchymal brain lymphoma; lymphomatosis cerebri; intravascular lymphoma; lymphomatous choroiditis and meningitis; extradural, intradural–extramedullary or intramedullary lymphoma in the spinal cord; or neurolymphomatosis in the peripheral nerves (Guil-Luna *et al.*, 2013). Amongst these, neurolymphomatosis is defined as an infiltration of peripheral nerves or nerve roots by a neurotropic B- or T-cell lymphoma or with concur-

rent leukaemia (Higgins *et al.*, 2016). Neural cell adhesion molecule (also called CD56) is a key molecule responsible for mediating cell-to-cell adhesion and is typically expressed by neurons, glia, natural killer (NK) cells or T cells (Weisberger *et al.*, 2006). In man, CD56 positivity is a rare event in B-cell lymphoma and is usually recognized in neoplastic B cells derived from extranodal sites (Weisberger *et al.*, 2006). Aberrant expression of CD56 by the neoplastic lymphoid cells is considered as a possible factor in infiltration of neoplastic cells into peripheral nerves (Misdraji *et al.*, 2000; Weisberger *et al.*, 2006). Here, we report the clinical, imaging and pathological findings of a primary, neurotropic, CD56⁺ B-cell lymphoma (neurolymphomatosis) in a cat.

A 16-year-old male Russian blue cat was presented to a local animal hospital for nystagmus of the left eye and acute onset of paresis of the left forelimb that progressed to paraparesis of both forelimbs in 2 days.

Correspondence to: C.-H. Liu (e-mail: chhsuliu@ntu.edu.tw).

Radiographic and orthopaedic examination revealed no abnormality and the cat was treated with dexamethasone and mannitol. Five days later, the cat's neurological status deteriorated and progressed to tetraparesis. The cat was referred to the National Taiwan University Veterinary Hospital. Neurological examination revealed non-ambulatory tetraparesis with decreased postural reactions in all four limbs and decreased withdrawal reflex in the right hindlimb. Several subtle cranial nerve deficits were also detected, including pendular nystagmus, slightly delayed vestibular eye movement when the cat was turned towards the right, slightly decreased facial sensation on the left side and bilateral mydriasis with absent pupillary light reflex. According to the clinical examination, neurolocalization to the C6-T2 spinal cord segments was made. On the same day, complete blood cell count and serum biochemical analyses showed neutrophilia ($31.42 \times 10^9/l$; reference interval $1.48\text{--}10.29 \times 10^9/l$), mild monocytosis ($1.55 \times 10^9/l$; reference interval $0.05\text{--}0.67 \times 10^9/l$), mildly elevated liver enzymes (alanine aminotransferase 262 U/l; reference interval 12–130 U/l; aspartate amino transferase 112 U/l; reference interval 0–48 U/l) and hyperglycaemia (16.11 mmol/l; reference interval 4.11–8.83 mmol/l). These results could possibly have been related to recent administration of glucocorticoids. Magnetic resonance imaging (MRI) revealed multifocal nerve root swelling and hyperintensity at C6/C7 and C7/T1 under short- and medium-T1 sequence (Fig. 1), while ultrasonography revealed swelling of the right brachial plexus. Cerebrospinal fluid (CSF) analysis revealed medium to large sized lymphocytes with high cellularity ($24 \times 10^6/l$; reference interval $0\text{--}5 \times 10^6/l$) and increased protein concentration

(0.07 g/l; reference interval 0.01–0.04 g/l). CSF bacterial culture and polymerase chain reaction of CSF to detect *Toxoplasma gondii*, feline leukaemia virus, feline immunodeficiency virus and feline corona virus were all negative. After 8 days of glucocorticoid therapy, surgical biopsy of the right musculocutaneous nerve and pectoralis muscle was performed and samples submitted for histological evaluation. However, the cat died of cardiorespiratory failure postoperatively, probably due to unclassified cardiomyopathy. Permission was not granted to perform a necropsy examination.

The specimens collected were fixed in 10% neutral buffered formalin, processed routinely and embedded in paraffin wax. Sections were stained with haematoxylin and eosin (HE). Serial sections were subjected to immunohistochemistry (IHC) with a mouse anti-human monoclonal CD3 (clone F7.2.38, 1 in 200 dilution; Dako, Glostrup, Denmark), CD56 (clone RCD56, 1 in 200 dilution; Zytomed, Berlin, Germany), CD20 (polyclone catalogue number RB-9013-P0, 1 in 100 dilution; Thermo Fisher Scientific, Carlsbad, California, USA) and CD79a (clone JCB117, 1 in 200 dilution; Dako) detected using a REAL™ Envision kit (Dako) with 3, 3' diaminobenzidine as chromogen. Internal and external controls were obtained from feline tissues and negative controls were created by replacing the primary antibodies with non-immune serum.

Microscopically, within the epineurium, the nerve fascicles were interrupted multifocally by coalescing infiltrates of neoplastic cells, resulting in swelling, dissolution and fragmentation of the axons (Fig. 2). Blood vessels were surrounded by neoplastic cells in densely packed sheets. Neoplastic cells were round and contained single intermediate sized nuclei

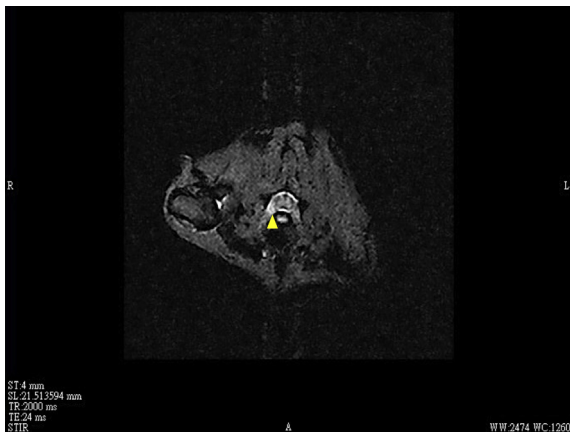


Fig. 1. Magnetic resonance imaging shows nerve root swelling and hyperintensity at C6/C7 (arrowhead) under short- and medium-T1 sequence.

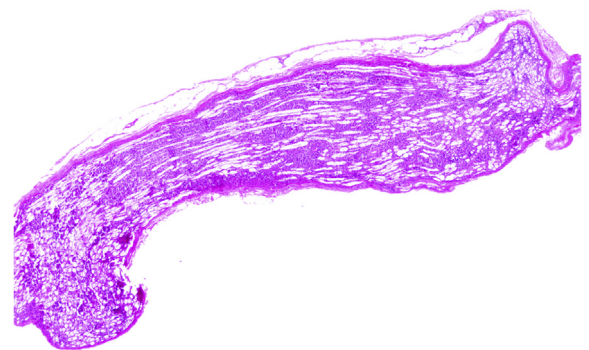


Fig. 2. Within the epineurium, the nerve fascicles are multifocally disrupted by coalescing neoplastic infiltrates, resulting in swelling, dissolution and fragmentation of the axons. HE. Bar, 500 μ m.

(approximately 1.5–2 times as large as red blood cells) with sparse cytoplasm. The nuclei were smudged and showed clumping of chromatin with one or several distinct nucleoli (Fig. 3). Mitosis averaged 1–2 per high-power ($\times 400$) field. The muscle showed that myocytes were individualized, reduced in size and surrounded by hypertrophic reserve cells, consistent with those of denervated myofibres.

Based on the histological appearance a diagnosis of a neurotropic lymphoma/neurolymphomatosis was made. The neoplastic cells showed immunoreactivity for CD20 and CD79a, but tested negative for CD3 (Fig. 4), indicative of a B-cell origin. Based on the location, histopathology and IHC, large B-cell neurolymphomatosis was diagnosed. Although central nervous system (CNS) lymphoma and stage IV lymphoma/lymphoid leukaemia could readily metastasize to the peripheral nerves, there was no evidence of CNS lymphoma in this case from the imaging findings; furthermore, polyneuropathy was the only observed clinical sign, highly indicative of primary lymphoma of the peripheral nerves.

Neurolymphomatosis is often associated with neurological deficits related to the affected spinal cord roots, nerve or trunk (Linzmann *et al.*, 2009). Since neoplastic lymphocytes heavily infiltrate peripheral nerves, causing Wallerian degeneration of the nerves while preserving axons, patients with neurolymphomatosis usually present with progressive peripheral neuropathy including mononeuropathy, asymmetrical regional neuropathies in the forelimb or hindlimb, plexopathy, polyradiculopathies or cauda equina syndrome (Kelly and Karcher, 2005;

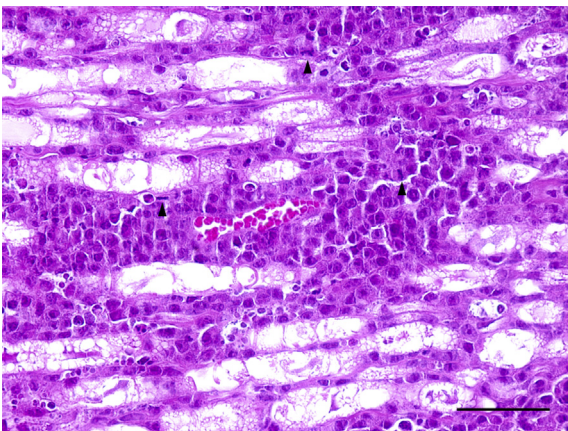


Fig. 3. Neoplastic cells are round and contain single intermediate sized (approximately 1.5–2 times as large as red blood cells) nuclei. The nuclei have smudged and clumped chromatin patterns and contain one to several nucleoli. Mitosis averages 1–3 per high-power field (arrowheads). HE. Bar, 50 μm .

Mandara *et al.*, 2016; Sakurai *et al.*, 2016). In cats, immune-mediated and infectious polyradiculoneuritis should be considered in the differential diagnoses (Flecknell and Lucke, 1978; Henke *et al.*, 2009; Mandara *et al.*, 2016). Immune-mediated disorders include feline acute idiopathic polyneuropathy, which is clinically identical to Guillain-Barré syndrome in man and usually causes an acute onset of neuropathy. The other immune-mediated disorder is its chronic counterpart, chronic inflammatory demyelinating polyneuropathy (CIDP), or feline chronic relapsing polyneuropathy, which progresses slowly and tends to be associated with spontaneous recovery and relapse (Mari *et al.*, 2016). Infectious agents that cause peripheral neuropathy in cats include rabies or pseudorabies viruses (Hagemoser *et al.*, 1980), feline leukaemia virus (Lappin, 2003) and *T. gondii* (Mari *et al.*, 2016). Molecular and serological tests and immunolabelling can help identify infectious aetiologies.

In this case, neoplastic B cells in peripheral nerves expressed CD56 (Fig. 4), which could play a critical role in the pathogenesis of neurolymphomatosis, because neurotropism (nerve invasion) of neoplastic cells has been presumed to result from the adhesion of CD56 molecules to the nerve processes (Kern *et al.*, 1992). Unfortunately, the expression of CD56 with respect to neoplastic B-cell ontogeny has not been fully investigated. In previous studies, human B-cell lymphomas with CD56 positivity were reportedly associated with a propensity for extranodal involvement and assumed to preferentially arise from the germinal centre stage, where B cells undergo neoplastic transformation with aberrant expression of CD56 (Weisberger *et al.*, 2006; Isobe *et al.*, 2007). To date, CD56 has not been detected in human primary B-cell neurolymphomatosis and further insight into the pathogenesis of primary B-cell neurolymphomatosis is required (Baehring *et al.*, 2003). With respect to the biological importance of CD56, the previous studies of T- or NK-cell lymphomas and acute myeloid leukaemia with expression of CD56 indicate a highly aggressive clinical course and poor prognosis (Weisberger *et al.*, 2006). In veterinary medicine, the diagnostic and prognostic significances of CD56 expression in B-cell neurolymphomatosis or in other neoplasms needs documentation in more cases in the future.

In animals, neurolymphomatosis is common in chickens suffering from Marek's disease, which is caused by Gallid herpesvirus 2 (serotype 1) infection (Calnek, 2001). Infected chickens manifest unilateral enlargement of the sciatic plexus with histopathological findings of marked cellular infiltration of lymphoblastic T cells (Calnek, 2001). For further

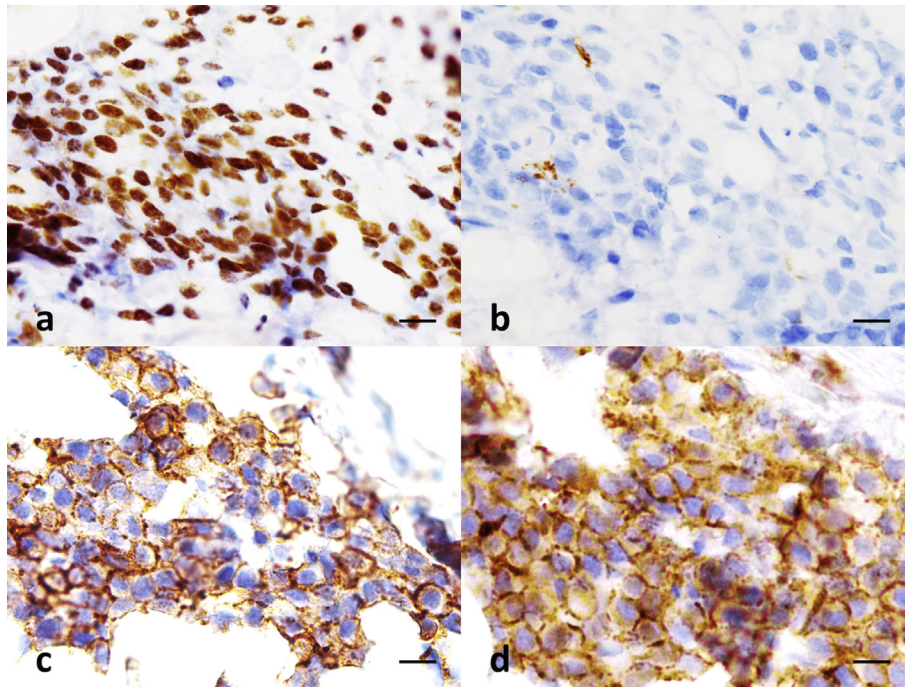


Fig. 4. Neoplastic cells express (a) CD79a, (c) CD20 and (d) CD56. They are negative for (b) CD3. IHC. Bar, 10 μ m.

investigation of the pathogenesis in neurolymphomatosis, the chicken is believed to be an ideal experimental animal model.

Diagnosis of neurolymphomatosis relies mainly on the clinical presentation and on the computed tomography scan combined with myelography and MRI. This allows excellent soft tissue delineation and is a gold standard in the diagnosis of nervous tumours (Dernell *et al.*, 2000). Nevertheless, neurolymphomatosis cannot be differentiated from other neoplastic or inflammatory diseases of the peripheral nerves (Linzmann *et al.*, 2009). Additionally, concurrent CSF examination might be useful in demonstrating a lymphocytic pleocytosis, which could provide the prospective evidence for neurolymphomatosis. For definite diagnosis, nerve biopsies directed by imaging techniques with IHC studies should be performed in suspected cases (Kelly and Karcher, 2005).

Currently, only seven cases of feline neurolymphomatosis have been reported (Zaki and Hurvitz, 1976; Mellanby *et al.*, 2003; Higgins *et al.*, 2008; Linzmann *et al.*, 2009; Mandrioli *et al.*, 2012; Sakurai *et al.*, 2016). The comparison between previously reported cases of feline neurolymphomatosis and the present case is shown in Supplementary Table 1. The disease developed in cats with a mean age of 8.8 years (range 4–16 years), but had no sex predilection. The most commonly affected nerves were the C5 to T2 spinal nerve roots (7/8) and their descending brachial plex-

uses (6/8), which often led to the clinical sign of weight-bearing or non-weight-bearing lameness of the forelimbs. Only one case showed enlargement of the brachial plexus and sciatic nerve without involvement of the spinal nerve roots (Higgins *et al.*, 2008). Multiple cranial nerves (III, V and VIII) were involved in two cases and led to the absence of ocular reflexes. Half of these cases (4/8) were of the B-cell lineage, one was of T-cell lineage, one was non-B and non-T cell in origin, while the others remained unknown. Most of the cats were humanely destroyed following the deterioration of neurological signs and poor response to therapy. One cat received dexamethasone, mannitol, furosemide and diazepam for treating seizures and survived for 10 months (Sakurai *et al.*, 2016). In man, primary lymphoma of the peripheral nervous system appears to be aggressive, but may respond to therapy (Misdraji *et al.*, 2000). The overall survival time is similar to that of large B-cell lymphoma of nodal sites and may be better than that of primary CNS lymphoma (Misdraji *et al.*, 2000).

Acknowledgments

The authors appreciate the technical help provided by Ms. H. Tseng and Ms. P.-T. Chen. This research did not receive any specific grant from funding agencies in the public, commercial or not-for-profit sectors.

Conflict of Interest Statement

The authors declare no conflict of interest with respect to the publication of this manuscript.

Supplementary data

Supplementary data to this article can be found online at <https://doi.org/10.1016/j.jcpc.2019.03.004>.

References

- Baehring JM, Damek D, Martin EC, Betensky RA, Hochberg FH (2003) Neurolymphomatosis. *Neuro-Oncology*, **5**, 104–115.
- Calnek B (2001) Pathogenesis of Marek's disease virus infection. In: *Marek's Disease*, 1st Edit., K Hirai, Ed., Springer, Heidelberg, pp. 25–55.
- Dernell WS, Van Vechten BJ, Straw RC, LaRue SM, Powers BE *et al.* (2000) Outcome following treatment of vertebral tumors in 20 dogs (1986–1995). *Journal of the American Animal Hospital Association*, **36**, 245–251.
- Flecknell P, Lucke VM (1978) Chronic relapsing polyradiculoneuritis in a cat. *Acta Neuropathologica*, **41**, 81–84.
- Guil-Luna S, Carrasco L, Gómez-Laguna J, Hilbe M, Mínguez JJ *et al.* (2013) Primary central nervous system T-cell lymphoma mimicking meningoencephalomyelitis in a cat. *Canadian Veterinary Journal*, **54**, 602–605.
- Hagemoser W, Kluge J, Hill H (1980) Studies on the pathogenesis of pseudorabies in domestic cats following oral inoculation. *Canadian Journal of Comparative Medicine*, **44**, 192–202.
- Henke D, Vandeveld M, Oevermann A (2009) Polyganglioradiculoneuritis in a young cat: clinical and histopathological findings. *Journal of Small Animal Practice*, **50**, 246–250.
- Higgins M, Rossmeisl J Jr., Saunders G, Hayes S, Kiupel M (2008) B-cell lymphoma in the peripheral nerves of a cat. *Veterinary Pathology*, **45**, 54–57.
- Higgins RJ, Bollen AW, Dickinson PJ, Sisó-Llonch S (2016) Tumors of the nervous system. In: *Tumors in Domestic Animals*, 5th Edit., D Meuten, Ed., John Wiley & Sons, New Jersey, pp. 872–876.
- Isobe Y, Sugimoto K, Takeuchi K, Ando J, Masuda A *et al.* (2007) Neural cell adhesion molecule (CD56)-positive B-cell lymphoma. *European Journal of Haematology*, **79**, 166–169.
- Kelly JJ, Karcher DS (2005) Lymphoma and peripheral neuropathy: a clinical review. *Muscle & Nerve*, **31**, 301–313.
- Kern W, Spier C, Hanneman E, Miller T, Matzner M *et al.* (1992) Neural cell adhesion molecule-positive peripheral T-cell lymphoma: a rare variant with a propensity for unusual sites of involvement. *Blood*, **79**, 2432–2437.
- Lappin MR (2003) Infectious diseases. In: *Small Animal Internal Medicine*, 5th Edit., R Nelson, CG Couto, Eds., Mosby, Missouri, pp. 1281–1286.
- Linzmann H, Brunnberg L, Gruber AD, Klopffleisch R (2009) A neurotropic lymphoma in the brachial plexus of a cat. *Journal of Feline Medicine & Surgery*, **11**, 522–524.
- Mandara MT, Motta L, Calò P (2016) Distribution of feline lymphoma in the central and peripheral nervous systems. *Veterinary Journal*, **216**, 109–116.
- Mandrioli L, Morini M, Biserni R, Gentilini F, Turba ME (2012) A case of feline neurolymphomatosis: pathological and molecular investigations. *Journal of Veterinary Diagnostic Investigation*, **24**, 1083–1086.
- Mari L, Shelton GD, De Risio L (2016) Distal polyneuropathy in an adult Birman cat with toxoplasmosis. *Journal of Feline Medicine and Surgery Open Reports*, **2**, 2055116916630335.
- Mellanby R, Jeffery N, Baines E, Woodger N, Herrtage M (2003) Magnetic resonance imaging in the diagnosis of lymphoma involving the brachial plexus in a cat. *Veterinary Radiology & Ultrasound*, **44**, 522–525.
- Misdráji J, Ino Y, Louis DN, Rosenberg AE, Chiozza EA *et al.* (2000) Primary lymphoma of peripheral nerve: report of four cases. *American Journal of Surgical Pathology*, **24**, 1257–1265.
- Sakurai M, Azuma K, Nagai A, Fujioka T, Sunden Y *et al.* (2016) Neurolymphomatosis in a cat. *Journal of Veterinary Medical Science*, **78**, 1063–1066.
- Weisberger J, Gorczyca W, Kinney M (2006) CD56-positive large B-cell lymphoma. *Applied Immunohistochemistry and Molecular Morphology*, **14**, 369–374.
- Zaki FA, Hurvitz AI (1976) Spontaneous neoplasms of the central nervous system of the cat. *Journal of Small Animal Practice*, **17**, 773–782.

[Received, February 18th, 2019]
 [Accepted, March 15th, 2019]