

# Long-term follow-up and outcomes of percutaneous nephron-sparing surgery for upper tract urothelial carcinoma

Piyush Bhargav Sarmah\*, Syed Ali Ehsanullah, Bhupendra Dev Sarmah

Department of Urology, Birmingham Heartlands Hospital, University Hospitals of Birmingham, Birmingham, UK

\*E-mail: piyushbsarmah@doctors.org.uk

## ABSTRACT

**Introduction:** Upper tract urothelial carcinoma (UTUC) is uncommon, accounting for 5%–10% of all urothelial carcinomas. Current standard of care for localized disease consists of radical nephroureterectomy (RNU) which leads to loss of half the patient's functioning nephrons. Percutaneous nephron-sparing surgery (PCNSS) is an alternative minimally-invasive approach in selected cases where nephron preservation is desired. The long-term outcomes of this procedure at a single center are described.

**Methods:** All patients undergoing PCNSS, with the operation carried out by a single surgeon, were included. Equipment used was a standard 26Ch resectoscope through a 30Ch Amplatz sheath, with all patients receiving postoperative intrapelvic Mitomycin. Data for each patient were collected on patient age; tumor size at diagnosis; grade; stage; oncological recurrence; requirement for subsequent RNU; and overall survival. Primary outcomes were disease recurrence and overall mortality, and secondary outcome was rate of subsequent RNU.


**Results:** Fifteen patients in total underwent PCNSS, 14 were diagnosed with UTUC; benign leiomyoma was proven in one patient and excluded from final analysis. Overall survival at 5 and 10 years was 92.9% and 78.6%, respectively, with disease-specific mortality at 10 years of 7.1% (one patient who developed metastatic carcinoma); 21.4% of patients had recurrent ipsilateral UTUC and all required subsequent RNU for this indication. No patients had seeding of the percutaneous tract.

**Conclusion:** PCNSS for UTUC is a feasible approach to consider in carefully selected patients who agree to intensive follow-up, even for higher grade tumors. Where recurrent UTUC occurs, further management options still exist for disease treatment.

## INTRODUCTION

Upper tract urothelial carcinoma (UTUC) is relatively uncommon, accounting for up to 10% of all urothelial carcinomas.<sup>[1,2]</sup> Definitive surgical management in many centers is in the form of radical nephroureterectomy (RNU), clearing all of the urothelium of the upper urinary tract that could also potentially be affected by recurrent tumor, and is considered as “standard of care”.<sup>[3]</sup>

This however is a major procedure conferring morbidity, including the loss of up to half of the patient's functioning nephrons (presuming preoperatively that they have both normally functioning renal units) which could then lead to long-term cardiovascular complications.<sup>[4,5]</sup> It may also be considered inappropriate or challenging in certain cases, for example significant renal insufficiency, or anatomically or functionally solitary kidneys.<sup>[6,7]</sup>

Access this article online	
Quick Response Code:	Website: www.indianjurol.com
	DOI: 10.4103/iju.IJU_93_20

This is an open access journal, and articles are distributed under the terms of the Creative Commons Attribution-NonCommercial-ShareAlike 4.0 License, which allows others to remix, tweak, and build upon the work non-commercially, as long as appropriate credit is given and the new creations are licensed under the identical terms.

**For reprints contact:** reprints@medknow.com

**Received:** 21.03.2020, **Revised:** 18.06.2020

**Accepted:** 16.07.2020, **Published:** 01.10.2020

**Financial support and sponsorship:** Nil.

**Conflicts of interest:** There are no conflicts of interest.

Advances in urological technology have made it possible to explore the noninferiority of more minimally-invasive operative techniques to treat UTUC, and the European Association of Urology (EAU) guidelines advise discussing “kidney-sparing surgery” (KSS) in all low-risk cases.<sup>[3]</sup> Ureterorenoscopic laser fulguration of upper urinary tract tumors is one such recommended approach, but with the risk of under-staging and under-grading which can then negatively influence future management decisions.<sup>[8,9]</sup> Percutaneous nephron-sparing surgery (PCNSS) was first reported in 1986,<sup>[10]</sup> and is also recommended in these guidelines for low risk tumors in the lower calyceal system that are inaccessible or difficult to manage through flexible ureterorenoscopy (FURS), albeit with a theoretical risk of tumor seeding in the percutaneous tract.<sup>[3]</sup> Limited data however exist in the medical literature on the outcomes of this approach. We present our experience with this surgical modality to treat UTUC in our institution, describing the long-term outcomes of PCNSS for suspected UTUC as performed at a single center, by a single surgeon, over a total period of 18 years.

## METHODS

The study period was from 1994 to 2012. The procedure was approved by the local Novel Therapeutics Committee in 1994. All subjects provided written, informed consent to undergo the procedure, which adhered to the ethical guidelines of the Declaration of Helsinki and its amendments. All original data reported were available to access.

All patients had suspected UTUC discovered on either intravenous urography, or computed tomography (CT) urography, as part of investigations for new onset hematuria; preexisting follow-up for previously diagnosed bladder urothelial carcinoma (BUC); or were incidentally discovered. All cases were discussed at a urology multi-disciplinary team (MDT) meeting consisting of urologists, oncologists and radiologists, with their images reviewed and suitability for PCNSS. The inclusion criteria for patients to be considered for PCNSS included imaging features of a solitary tumor, located within the renal pelvis or lower pole calyx, <2 cm in size; patients with the American Society of Anesthesiologists (ASA) Grade 2 or below, and ASA Grade 3 for patients with solitary kidney. Those cases that did not meet these criteria were not considered for PCNSS. Patients were then seen in an outpatient clinic and thoroughly counseled about the available management options (either PCNSS or RNU), their risks and benefits, and follow-up; those who expressed a desire to proceed with PCNSS provided valid, written, informed consent. Prospective data were collected for all adult patients over the age of 18 years who underwent PCNSS for suspected UTUC, specifically on patient age; ASA grade; final tumor size at diagnosis as determined at the time of surgery; grade; stage; oncological recurrence; requirement for RNU either as

conversion at the time of PCNSS or performed subsequently; further oncological upper urinary tract surgery other than PCNSS and RNU; and overall survival. Primary outcomes were defined as disease recurrence (within the ipsilateral upper urinary tract following complete resection, or within the lower urinary tract) and overall mortality. Secondary outcome was defined as the rate of patients requiring subsequent RNU. Kaplan–Meier curves for disease recurrence and disease-specific survival were devised using IBM SPSS Statistics for Windows (IBM Corp. Released 2011. IBM SPSS Statistics for Window, Version 20.0. Armonk, NY: IBM Corp).

All patients followed the exact same operative protocol for PCNSS, as undertaken by a single surgeon. They underwent surgery in a prone position, with access to the pelvicalyceal system obtained by an interventional radiologist, and retrograde placement of a ureteric balloon catheter. A 26 French standard resectoscope through a 30 French Amplatz sheath was used to resect the tumors. Distilled water was instilled into the renal pelvis postresection. A percutaneous 20 French Malecot nephrostomy tube was placed postoperatively, and a nephrostogram performed at 5–7 days confirming absence of leakage of contrast from the pelvicalyceal system. Patients maintained their nephrostomy tubes and subsequently received a monthly dose of intrapelvic Mitomycin through this for 3 months, at a dose of 40 mg in 500 mL of normal saline through a slow infusion through an IVAC® pump over 24 h at each administration; the nephrostomy was clamped after each administration. A repeat nephrostogram was performed after the final dose of Mitomycin, prior to removal of nephrostomy tube which was subject to satisfactory drainage and appearances of the pelvicalyceal system.

Follow-up adhered to a strict protocol for up to 10 years:-

- Check rigid cystoscopy at 4 months with ipsilateral retrograde pyelogram (if abnormalities were detected then FURS was performed at the same sitting), followed by six monthly check flexible cystoscopy
- CT intravenous urogram at 12 months, then 3 yearly thereafter during follow-up period
- Annual ipsilateral FURS.

Patients with suspected recurrent disease on imaging underwent FURS with biopsy of suspicious lesions, with further MDT discussion held after histological results were known.

## RESULTS

Fifteen patients in total underwent PCNSS for suspected UTUC; one patient was proven histologically to have benign leiomyoma and was excluded from final analysis. Table 1 demonstrates patient demographics. The age range was from 53 to 89 years, with an average age of 64.4 years. Follow-up

ranged from 60 to 120 months, with a median time of 120 months. All but one patient had an ASA grade of 2, with the remaining patient being assessed as ASA 3 at the time of surgery.

Table 2 demonstrates the operative and postoperative characteristics of the resected tumors, which ranged in surgical size from 1.5 to 4 cm. Two tumors were located in the renal pelvis but encroaching on the pelvi-ureteric junction on operative imaging, and this location was confirmed through on-table cystoscopy and retrograde pyelogram, with a decision made to proceed with PCNSS; for both of these cases, the ureteric balloon catheter was placed slightly more distal compared to the other cases. Complex preoperative anatomy occurred in one patient with a solitary kidney following previous radical nephrectomy for renal cell carcinoma; one who previously underwent radical cystoprostatectomy and ileal conduit formation due to muscle-invasive BUC; and another with bilateral synchronous UTUC at diagnosis, with one tumor in the renal pelvis, and another in the contralateral mid-ureter (managed

via segmental ureterectomy at a later date). Three patients had a prior history of BUC. All proven carcinomas in this series were urothelial in origin, with the majority of these (10/14) exhibiting Grade 2 changes. There was no synchronous BUC in any of the patients that required resection at the same time as PCNSS.

Table 3 demonstrates the characteristics of patients who developed recurrent urothelial carcinoma. Three patients (21.4%) had ipsilateral local recurrent high-grade UTUC or local lymph node metastasis occurring at 3–60 months following PCNSS [Figure 1; median 18 months]; all required subsequent RNU. Four patients developed recurrent BUC, including all three of the patients who underwent subsequent RNU as described above; all recurrent BUC was high-risk superficial disease, including one patient with carcinoma *in-situ*.

Overall mortality was 7.1% and 21.4% at 5 and 10 years, respectively, with disease-specific mortality of 7.1% (one patient) at 10 years [Figure 2]; this patient had developed metastatic disease at the time of death.

Two patients (14.3%) developed postoperative complications – one had sepsis and pulmonary embolism, both of which were successfully treated, and the other a ureteric stricture successfully treated with balloon dilatation. No patients were reported to have developed tumor implantation of the percutaneous tract. There were no adverse events reported with intrapelvic Mitomycin instillation.

**Table 1: Patient demographics of final analysis**

Patient characteristics	n
Total (n)	14
Age (years)	
Range	53-89
Median	64.4
Gender	
Male	12
Female	2
ASA grade	
2	13
3	1

ASA=American Society of Anesthesiologists

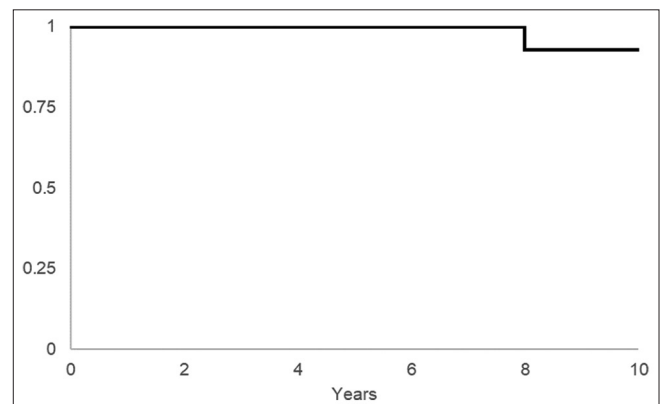
**Table 2: Tumor characteristics at primary diagnosis**

Anatomical and histological characteristics	n
Size (cm)	
1	3
1.5	3
2	4
2.5	1
3	1
3.5	1
4	1
Location	
RP	12
PUJ	2
Number of tumors	
Solitary	13
Multifocal	1
Histology	
UC	14
Histological grade of carcinomas	
Low (G1 and G2)	11
High (G3)	3
Histological stage of carcinomas	
pTa	11
pT1	3

RP=Renal pelvis, PUJ= Pelvi-ureteric junction, UC=Urothelial carcinoma

**DISCUSSION**

RNU as definitive management of UTUC has become the gold standard in many centers. Although it is carried out with the intention of oncological cure, it can lead to chronic kidney disease and further complications arising from that condition, including long-term dialysis, renal transplantation and death.<sup>[4,11,12]</sup> Such potential adverse effects of radical treatment has led to great advances in the field of urology in developing minimally-invasive,

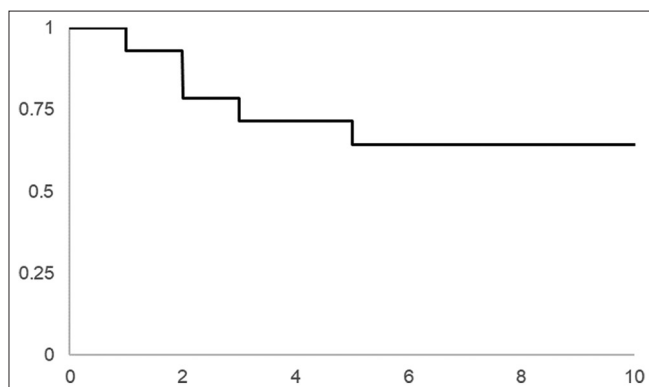


**Figure 1:** Kaplan-Meier curve demonstrating overall disease-specific survival

**Table 3: Characteristics of recurrent carcinoma requiring further surgical intervention**

Anatomical and histological characteristics	Number of patients
Location of recurrent carcinoma	
Upper urinary tract	2
Bladder	4
Local lymph node metastases	1
Histological characteristics of recurrent carcinoma (including metastases)	
Grade of recurrent UTUC	
Low (G1 and G2)	0
High (G3)	3
Grade of recurrent UC in bladder	
Low (G1 and G2)	1
High (G3)	3
Further oncological upper urinary tract surgery for recurrent carcinoma	Number of procedures in the cohort
Subsequent RNU	3
Further oncological upper urinary tract surgery other than RNU	
Ureterorenoscopic laser fulguration	1
Segmental ureterectomy	1

UTUC=Upper tract urothelial carcinoma, UC=Urothelial carcinoma, RNU=Radical nephro-ureterectomy



**Figure 2:** Kaplan-Meier curve demonstrating recurrence-free survival

organ-sparing approaches, such as PNCSS. Our series adds to the small volume of preexisting literature on this procedure, demonstrating that it can be considered as an alternative to RNU in carefully selected cases. When performed, PCNSS, confers excellent long-term oncological outcomes.

It is imperative that PCNSS is carried out by a surgeon skilled not only in transurethral resection of bladder tumors (TURBT), but also percutaneous nephrolithotomy (PCNL). It was reassuring that none of our patients developed seeding of the percutaneous tract; we hypothesize that this was a result of all patients receiving distilled water into the renal pelvis immediately postoperatively, leading to lysing of any residual tumor cells. This in itself is a rare complication that has been limited to case reports,<sup>[13,14]</sup> with a very low incidence of such occurrence demonstrated from published data.<sup>[15]</sup>

PCNSS requires very careful patient selection; we had strict inclusion criteria based on imaging, considering only those patients with solitary tumors, located within the renal pelvis or lower pole calyx and <2 cm in size. The development of the EAU guidelines toward the end of our study period

reinforced these criteria, with the further inclusion of low grade tumor based on cytology and ureterorenoscopic biopsy.<sup>[3]</sup> KSS is recommended in all low risk cases, as well as “imperative cases,” for example, solitary kidney or renal insufficiency.<sup>[3]</sup> In our series, all tumors were two centimeters or less on imaging, but some tumors were discovered to be larger at the time of surgery. Patients should of course be fit to undergo general anaesthesia, and this was implied in our strict follow-up protocol for up to 10 years. Psychologically, it is also very important that clinically suitable patients must agree to the intensive follow-up regime. This regime has similarities to that for patients following RNU with check flexible cystoscopies and regular cross-sectional imaging, with the the addition of annual FURS. All patients in our cohort maintained a nephrostomy tube for up to 3 months to receive chemotherapy.

All of the patients in this series were operated on without the availability of prior histology, given that during this period techniques for FURS and biopsy had not yet been developed to the extent that they are carried out today to further investigate upper urinary tract abnormalities detected on imaging. In many centers, FURS and laser fulguration are the first choice of KSS carried out due to its wider availability. Biopsy however does provide an additional diagnostic tool in the risk stratification of UTUC through grading of the disease, further determining patient suitability for PCNSS. Indeed, the single patient who was eventually proven to have a leiomyoma may not have even undergone PCNSS had prior histology obtained through FURS proven this. There have however been concerns raised about the introduction of FURS into the diagnostic pathway leading to delay before patients undergo definitive treatment,<sup>[16]</sup> although this has been shown to not impact subsequent oncological outcomes.<sup>[17]</sup> Furthermore, in units where FURS may not be available PCNSS can be considered as an option to treat UTUC, but only after very careful patient selection as described in our detailed inclusion criteria.

We compared our outcomes to preexisting series in the medical literature around PCNSS. The rate of local UTUC recurrence was comparable,<sup>[18,19]</sup> lower than the largest series of patients undergoing PCNSS, where even 37% of patients with low-grade disease developed it.<sup>[20]</sup> The relatively small patient numbers in our series may have impacted recurrence rates. A particular patient, who continued heavy tobacco consumption in the post-operative period, had primary radical cystoprostatectomy with ileal conduit formation for muscle-invasive bladder cancer, followed by UTUC dealt with by PCNSS (twice at an interval of two years), and then further multiple recurrences requiring ipsilateral RNU, and contralateral segmental ureterectomy. Another patient was found to have more extensive tumor than evident on preoperative imaging when PCNSS was performed, and was therefore converted to RNU; both of these patients subsequently developed metastatic disease which they died from. However, only one of the recurrent tumors was high grade, contradicting previous studies where this is a predictive factor for recurrence; again, this may be explained by our small patient numbers, which likely remained low because of our strict inclusion criteria. In addition, the recurrence rate also occurred despite all patients receiving intrapelvic Mitomycin both intraoperatively and as a course post operatively. Other authors who used this,<sup>[21,22]</sup> and bacillus Calmette–Guêrin,<sup>[19,20]</sup> in the postoperative phase demonstrated no significant benefit in reducing recurrence rates, and this further emphasizes the importance of the rigorous follow-up regime following PCNSS, to allow for early identification and treatment. Further definitive management in the form of radical surgery can then be taken where recurrence occurs. For those patients, who are unfit for such major surgery, further nephron-sparing procedure through FURS and laser fulguration exists too, although this approach is more for control of the disease rather than definitive cure.

The small numbers also reflect local and global factors impacting on the management of patients with UTUC; there was a more intense selection of patients in our unit for PCNSS, one example of this being that only one patient with multifocal disease underwent the procedure, as opposed to other authors who operated on a larger proportion of patients with multifocal tumor.<sup>[19,21]</sup> There was a rapid progression in urological surgical technology seen during the study, especially with regards to the development of laparoscopic surgery, thus making RNU more widely practiced. There was an improvement in distal tip deflection mechanism for ureterorenoscopes,<sup>[23]</sup> making this a more preferred option for nephron-sparing surgery compared to the percutaneous approach, especially as it was more widely practiced within our department.

## CONCLUSION

In our experience, PCNSS for UTUC is a minimally-invasive surgical approach that confers excellent long-term

oncological outcomes, and spares severe morbidity resulting from radical surgery. This technique is best carried out by urologists with knowledge of TURBT and PCNL. Very careful patient selection and counseling is required, especially with intensive surveillance and robust patient compliance with proposed follow-up regime. Where recurrence does occur, RNU does remain as a further definitive management option.

## REFERENCES

1. Siegel R, Naishadham DJ. Cancer statistics, 2012. *CA Cancer J Clin* 2012;62:10-29.
2. Munoz JJ, Ellison LM. Upper tract urothelial neoplasms: Incidence and survival during the last 2 decades. *J Urol* 2000;164:1523-5.
3. Rouprêt M, Babjuk M, Böhle A, Burger M, Compéerat E, Cowan N, *et al.* EAU guidelines on urothelial carcinomas of the upper urinary tract. *Eur Urol* 2018;73:111-22.
4. Meyer JP, Delves GH, Sullivan ME, Keoghane SR. The effect of nephroureterectomy on glomerular filtration rate. *BJU Int* 2006;98:845-8.
5. Weight CJ, Larson BT, Fergany AF, Gao T, Lane BR, Campbell SC, *et al.* Nephrectomy induced chronic renal insufficiency is associated with increased risk of cardiovascular death and death from any cause in patients with localized cT1b renal masses. *J Urol* 2010;183:1317-23.
6. Seisen T, Peyronnet B, Dominguez-Escrig JL, Yuan CY, Babjuk M, Böhle A, *et al.* Oncologic outcomes of kidney-sparing surgery versus radical nephroureterectomy for upper tract urothelial carcinoma: A systematic review by the EAU Non-muscle Invasive Bladder Cancer Guidelines Panel. *Eur Urol* 2016;70:1052-68.
7. Moore K, Khastgir J, Ghei M. Endoscopic management of upper tract urothelial carcinoma. *Adv Urol* 2009;620604.
8. Daneshmand S, Quek ML, Huffman JL. Endoscopic management of upper urinary tract transitional cell carcinoma: Long-term experience. *Cancer* 2003;98:55-60.
9. Park BH, Jeon SS. Endoscopic management of upper urinary tract urothelial carcinoma. *Korean J Urol* 2013;54:426-32.
10. Stroom SB, Pontes EJ. Percutaneous management of upper tract transitional cell carcinoma. *J Urol* 1986;135:773-5.
11. Huang WC, Levey AS, Serio AM, Snyder M, Vickers AJ, Raj GV, *et al.* Chronic kidney disease after nephrectomy in patients with renal cortical tumours: A retrospective cohort study. *Lancet Oncol* 2006;7:735-40.
12. Go AS, Chertow GM, Fan D, McCulloch CE, Hsu CY. Chronic kidney disease and the risks of death, cardiovascular events, and hospitalization. *N Engl J Med* 2004;351:1296-305.
13. Yamada Y, Kobayashi Y, Yao A, Yamanaka K, Takechi Y, Umezu K. Nephrostomy tract tumor seeding following percutaneous manipulation of a renal pelvic carcinoma. *Hinyokika Kyo* 2002;48:415-8.
14. Treuthardt C, Danuser H, Studer UE. Tumor seeding following percutaneous antegrade treatment of transitional cell carcinoma in the renal pelvis. *Eur Urol* 2004;46:442-3.
15. Serrano Pascual A, Fernández González I, González-Peramato P, García González R, Lovaco Castellano F. Is there a risk of carcinoma dissemination in the percutaneous access for endoscopic treatment of upper urinary tract urothelial tumors? *Arch Esp Urol* 2004;57:283-90.
16. Taylor WS, Ingamells N, Morris S, Subramonian K. Delays to diagnosis and management of upper tract urothelial carcinoma: The need for a new pathway. *J EJU* 2019;2:5-11.
17. Nison L, Rouprêt M, Bozzini G, Ouzzane A, Audenet F, Pignot G, *et al.* The oncologic impact of a delay between diagnosis and radical nephroureterectomy due to diagnostic ureteroscopy in upper urinary tract urothelial carcinomas: Results from a large collaborative database. *World J Urol* 2013;31:69-76.
18. Patel A, Soonawalla P, Shepherd SF, Dearnaley DP, Kellett MJ,

- Woodhouse CR. Long-term outcome after percutaneous treatment of transitional cell carcinoma of the renal pelvis. *J Urol* 1996;155:868-74.
19. Rastinehad AR, Ost MC, Vanderbrink BA, Greenberg KL, El-Hakim A, Marcovich R, *et al.* A 20-year experience with percutaneous resection of upper tract transitional carcinoma: Is there an oncologic benefit with adjuvant bacillus Calmette Guérin therapy? *Urology* 2009;73:27-31.
  20. Motamedinia P, Keheila M, Leavitt DA, Rastinehad AR, Okeke Z, Smith AD. The expanded use of percutaneous resection for upper tract urothelial carcinoma: A 30-year comprehensive experience. *J Endourol* 2016;30:262-7.
  21. Palou J, Piovesan LF, Hugué J, Salvador J, Vicente J, Villavicencio H. Percutaneous nephroscopic management of upper urinary tract transitional cell carcinoma: Recurrence and long-term followup. *J Urol* 2004;172:66-9.
  22. Rouprêt M, Traxer O, Tligui M, Conort P, Chartier-Kastler E, Richard F, *et al.* Upper urinary tract transitional cell carcinoma: Recurrence rate after percutaneous endoscopic resection. *Eur Urol* 2007;51:709-13.
  23. Cornu JN, Rouprêt M, Carpentier X, Geavlete B, de Medina SG, Cussenot O, *et al.* Oncologic control obtained after exclusive flexible ureteroscopic management of upper urinary tract urothelial cell carcinoma. *World J Urol* 2010;28:151-6.

How to cite this article: Sarmah PB, Ehsanullah SA, Sarmah BD. Long-term follow-up and outcomes of percutaneous nephron-sparing surgery for upper tract urothelial carcinoma. *Indian J Urol* 2020;36:276-81.