

Pelizaeus–Merzbacher Disease: the First Genetically Approved Case Report from Iran

Mahmoud-Reza Ashrafi^{1,2}, MD; Mahmoud Mohammadi^{1,2}, MD; Hooman Alizadeh³, MD, and Ali Nikkhah^{*2}, MD

1. Department of Pediatrics, Tehran University of Medical Sciences, Tehran, Iran
2. Division of Pediatric Neurology, Pediatrics Center of Excellence, Children's Medical Center, Tehran, Iran
3. Department Radiology, Tehran University of Medical Sciences, Tehran, Iran

Received: Aug 13, 2010; Final Revision: Mar 11, 2011; Accepted: Apr 19, 2011

Abstract

Background: Classic Pelizaeus-Merzbacher disease is a rare x-linked disorder of proteolipid protein expression first described clinically in 1885. This disease is characterized by abnormal eye movements, very slow motor development and involuntary movements. The causative gene is PLP1.

Case Presentation: A 1-year-old boy was referred to our clinic due to abnormal eye movements. He had horizontal and flickering eye oscillation, psychomotor retardation, hypotonia and head nodding. We found hypomyelination in brain MRI.

Conclusion: The possibility of Pelizaeus-Merzbacher disease should be considered in boys with abnormal eye movements, psychomotor retardation and hypotonia.

Iranian Journal of Pediatrics, Volume 21 (Number 3), September 2011, Pages: 395-398

Key Words: Pelizaeus-Merzbacher Disease; Eye Movements; Hypotonia; Head Nodding

Introduction

Classic Pelizaeus-Merzbacher disease is a rare x-linked disorder of proteolipid protein expression that was described clinically by Pelizaeus in 1885 and later in 1910 the clinical and pathologic features of the same family were documented by Merzbacher [1].

The clinical features of this disease are slowly progressive and consist of peculiar pendular eye

movements, head nodding, hypotonia, mental retardation, abnormal movements (dystonia, chorea) and pyramidal signs. Also, optic atrophy and seizures may occur in this disease.

Typically, the progression of the disease slows towards the middle or end of the first decade, with death occurring in the early adult ages [2].

This disease results from point mutations that result in amino acid substitutions or complete deletion/duplication of the PLP1 gene. These gene

*** Corresponding Author;**

Address: Division of Pediatric Neurology, Children's Medical Center, No 62, Dr Gharib St, Keshavarz Blvd, Tehran, Iran

E-mail: alinik52@yahoo.com

products play a major role in the development of oligodendrocytes for myelination [3]. The PLP gene is linked to the Xq21-22 region [4].

Brainstem auditory-evoked responses and somatosensory-evoked potentials are consistently abnormal [5]. In some cases, visual-evoked potentials are abnormal [6]. Brain MRI is helpful in demonstrating the hypomyelination that is characteristic of this disorder [6].

Case Presentation

This 1-year-old boy is the first child of non-consanguineous parents. He was born at term following an unremarkable pregnancy and delivered by cesarean section. Apgar score at 5 minute was 9. Birth weight 2900 gram, head circumference 34 centimeter. At birth, he had axial hypotonia and limbs hypertonicity. At 2 months, binocular nystagmus was noted, which stabilized by 6 months of age. At 8 months of age, he presented with head nodding and at times, he was noted to have markedly increased tone of both lower extremities. At present time, he has global developmental delay and progressive limbs

spasticity with abnormal eye movements and axial hypotonia.

Visual and brainstem evoked potentials are abnormal.

MR study reveals poor myelination and dysmyelination of periventricular and sub cortical white matter in T1W and T2W images comparing normal myelination process for the patient's age. Similar finding in infra-tentorial white matter is also seen (Fig. 1 and 2).

DNA investigated for mutations and deletion/duplication by sequencing revealed duplication in the PLP1. This confirmed the diagnosis Pelizaeus-Merzbacher disease.

Discussion

Pelizaeus-Merzbacher Disease (PMD) is a rare x-linked inherited disorder characterized by hypomyelination. In fact this disease is a hypomyelinating leukoencephalopathy. In PMD, normal myelination either never occurs or is incomplete.

In 1885, Pelizaeus and later in 1910, Merzbacher described this disorder for the first time [7].

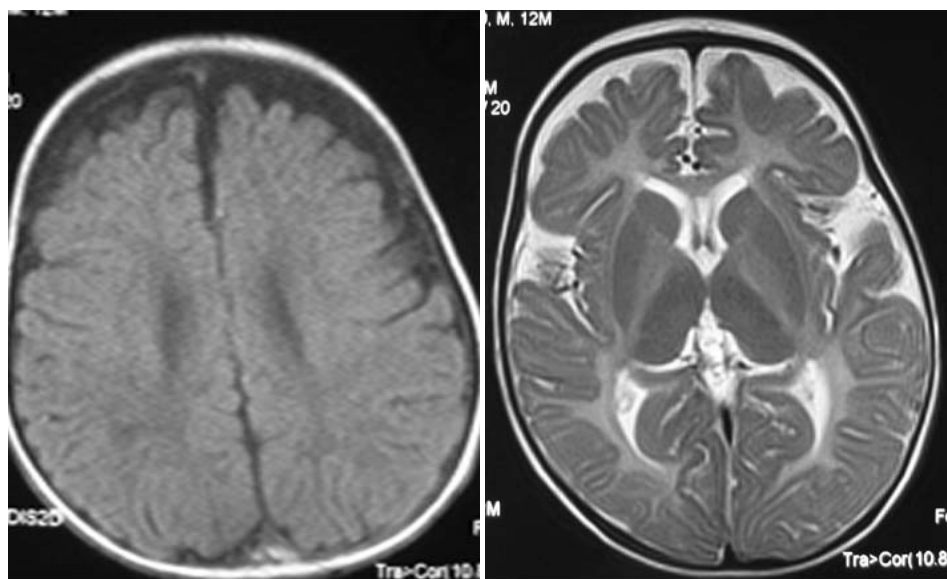


Fig. 1: Axial brain MRI. T2W image shows abnormal high signal periventricular and sub cortical white matter of centrum semiovale, which is low signal in T1W image (left).

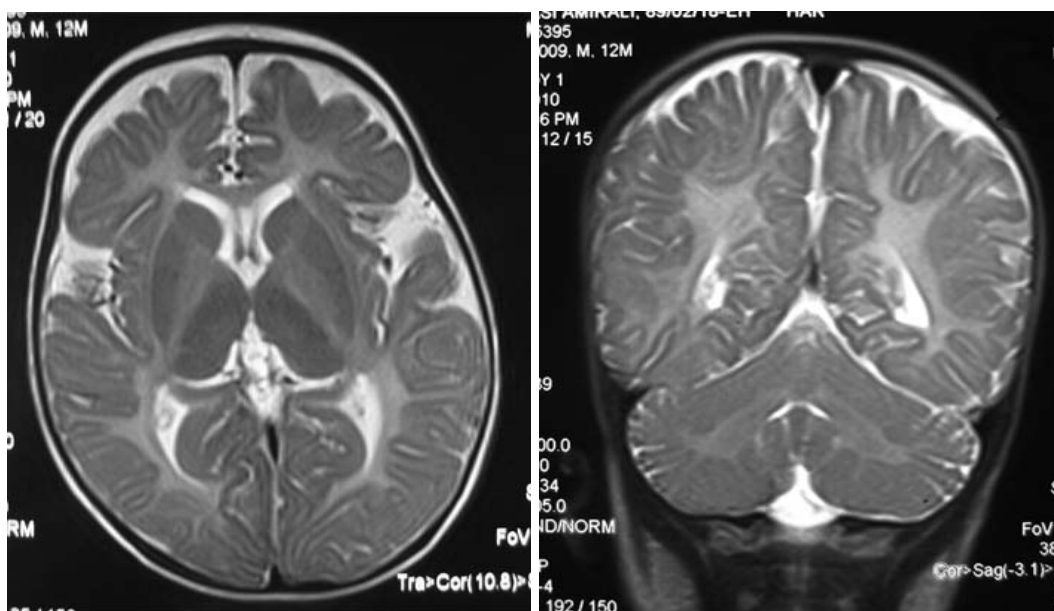


Fig. 2: Brain MRI in patient with Pelizaeus-Merzbacher Disease:

Left: Axial brain MRI. T2W image at the level of basal ganglia; note abnormal high signal internal capsule due to dysmyelination of white matter.

Right: Coronal brain MRI. T2W image shows relatively high signal white matter of the cerebellum.

PMD has traditionally been divided into four categories: classic, congenital, transitional and adult form (spastic paraplegia)^[7].

The most common form is classic PMD (our case). Symptoms in classic PMD are usually manifest during infancy. These patients present with nystagmus, head nodding, hypotonia, dystonia, ataxia and cognitive delay. Hypotonia typically evolves into spastic paraparesis over time. Prior to the progressive phase, the disease is often misdiagnosed as cerebral palsy^[7].

Proteolipid protein 1 gene (PLP1) mutations are responsible for PMD. This gene encodes the major myelin components in the CNS, the two proteolipid proteins, PLP and its spliced isoform, DM20. PLP is produced by mature oligodendrocytes while DM20 is produced earlier in myelin development^[8].

The most common mutation of PLP1 gene is duplication (70%) and the most common clinical phenotype of PMD caused by PLP1 duplication corresponds to the classic form of PMD (our case)^[9]. More than 60 point mutations in the PLP1 gene coding region have been identified^[9].

Brain MRI images in PMD typically demonstrate a pattern of hypomyelination with a reversal or

discordance of white matter signal intensity on T2 weighted images. T1 weighted images demonstrate normal or isointense white matter^[10].

In patients with PLP1 duplication, the brain MRI had some degree of myelination, while no myelination was noted in most patients with PLP1 point mutations^[11].

In this study, our case suffered from manifestations of classic PMD and had no new or unusual signs or symptoms. He had global developmental delay and progressive spasticity with abnormal eye movements and axial hypotonia with increased peripheral hypertonicity.

Conclusion

The possibility of PMD should be considered in boys with abnormal eye movements and hypotonia in early infancy. Also with early diagnosis, we can determine prognosis based on genetic study

References

1. Bouloche J, Aicardi J. Pelizaeus-Merzbacher disease: clinical and nosological study. *J Child Neurol* 1986;1(3):233-9.
2. Clarke JTR. Inherited Metabolic Disease. In: Adams R, Lyon G, Kolodny E (eds). *Neurologic Syndrome*. New York: McGraw-Hill. 1996; Pp: 2-52.
3. Nave KA, Boespflug-Tanguy O. X-linked developmental defects of myelination: from mouse mutants to human genetic disease. *Neuroscientist* 1996;2(1):33-43.
4. Mattei MG, Alliel PM, Dautigny A, et al. The gene encoding for the major brain PLP maps to the q-22 band of the human X chromosome. *Hum Genet* 1986;72(4):352-3.
5. Shy ME, Hobson G, Jain M, et al. Schwann cell expression of PLP1 but not DM20 is necessary to prevent neuropathy. *Ann Neurol* 2003;53(3):354.
6. Kendall BE. Inborn errors and demyelination: MRI and the diagnosis of white matter disease. *J Inherit Metab Dis* 1993;15(4):771-86.
7. Garbern JY. Pelizaeus-Merzbacher disease: genetic and cellular pathogenesis. *Cell Mol Life Sci* 2007;64(1):50-65.
8. Seitelberg F. Neuropathology and genetics of Pelizaeus-Merzbacher disease. *Brain Pathol* 1995;5(3):267-73.
9. Woodward KJ. The molecular and cellular defects underlying Pelizaeus-Merzbacher disease. *Expert Rev Mol Med* 2008;10:e14.
10. Kibe T, Miyahara J, Yokochi K, et al. et al. A novel PLP mutation in a Japanese patient with mild Pelizaeus-Merzbacher disease. *Brain Dev* 2009; 31(3):248-51.
11. Van der Knapp MS, Valk J. The reflection of histology in MR Imaging of Pelizaeus-Merzbacher disease. *AJNR AMJ Neuroradiol* 1989;10(1):99-103.