

Cervical Scoliosis: Clinical and Radiographic Outcomes

Addisu Mesfin¹ Wajeeh R. Bakhsh² Tapanut Chuntarapas² K. Daniel Riew²

¹Department of Orthopaedic Surgery, University of Rochester, Rochester, New York, United States

²Center for Cervical Spine, Washington University Orthopedics, Washington University in St. Louis, Saint Louis, Missouri, United States

Address for correspondence Addisu Mesfin, MD, Department of Orthopaedic Surgery and Cancer Center, University of Rochester School of Medicine, 601 Elmwood Avenue, Box 665, Rochester, NY 14642, United States (e-mail: addisu_mesfin@urmc.rochester.edu).

Global Spine J 2016;6:7–13.

Abstract

Study Design Retrospective study.

Objective Cervical scoliosis is a rare condition that can arise from various etiologies. Few reports on the surgical management of cervical scoliosis exist. Our objective was to evaluate clinical and radiographic outcomes following surgical management of cervical scoliosis.

Methods We evaluated our cervical spine surgical database for patients with cervical scoliosis (Cobb angle > 10 degrees) from 2005 to 2010. Demographic data including age, gender, diagnoses, and primary versus revision surgery was collected. Surgical data including procedure (anterior versus posterior), estimated blood loss (EBL), length of surgery, length of hospitalization, and complications was recorded. Preoperative and postoperative Cobb angle measurements and Neck Disability Index (NDI) scores were recorded.

Results Cervical scoliosis was identified in 18 patients. We excluded 5, leaving 5 men and 8 women with an average age of 50.7 (median 52, range 25 to 65). The average follow-up was 40 months (median 36.5, range 5 to 87). An anterior-only approach was used in 6 cases (average 4 levels fused), 5 cases were posterior-only approach (average 8.7 levels fused), and 2 cases were combined anterior-posterior approach. The EBL was an average of 286 mL (median 150, range 50 to 900), the average surgical time was 266 minutes (median 239, range 136 to 508), and the average hospital stay was 2.7 days (median 2, range 1 to 7). Complications occurred in 7 patients, and 2 developed adjacent segment pathology. The average coronal Cobb angle preoperatively was 35.1 degrees (median 31, range 13 to 63) and corrected was 15.7 degrees (median 10.5, range 2 to 59) postoperatively ($p < 0.005$). The average NDI preoperatively was 24.9 (median 26, range 6 to 37) and was reduced to 17.8 (median 18, range 7 to 30) postoperatively ($p < 0.02$).

Conclusion Surgical management of cervical scoliosis can result in deformity correction and improvement in patient outcomes. Higher rates of complications may be encountered.

Keywords

- ▶ scoliosis
- ▶ cervical deformity
- ▶ Klippel-Feil syndrome
- ▶ neurofibromatosis type I
- ▶ Neck Disability Index
- ▶ complications
- ▶ torticollis

received
January 29, 2015
accepted after revision
March 20, 2015
published online
June 5, 2015

DOI <http://dx.doi.org/10.1055/s-0035-1554776>.
ISSN 2192-5682.

© 2016 Georg Thieme Verlag KG
Stuttgart · New York

License terms



Introduction

Cervical scoliosis is a rare condition that to date has not been well defined. The few reports of cervical scoliosis discuss the condition in relation to Klippel-Feil syndrome (KFS), congenital scoliosis, and neurofibromatosis type 1 (NF-1).¹⁻⁸ Neglected cases of congenital torticollis, a soft tissue cause of cervical coronal deformity, can also present in adulthood.^{9,10} To our knowledge, the previous literature concerning operative treatment of cervical scoliosis has been limited to case reports and case series. Our objective was to evaluate clinical and radiographic outcomes following surgical management of cervical scoliosis.

Materials and Methods

After obtaining Institutional Review Board approval, we evaluated a prospectively maintained surgical database for patients with a diagnosis of cervical scoliosis. All patients were operated on by one surgeon at a single academic, tertiary care institution. The study design was retrospective. We evaluated our cervical spine surgery database for surgeries over a 5-year period from January 1, 2005, to December 31, 2010. Our inclusion criteria were the presence of cervical scoliosis (Cobb angle > 10 degrees) and complete preoperative and postoperative radiographs. We excluded patients with traumatic deformities, tumors, and primary sagittal deformities. We also excluded patients lost to follow-up. Spine surgeons not involved in the clinical and surgical management of these patients collected and analyzed the data.

Demographic data including age, sex, diagnoses, and primary versus revision surgery was collected. Surgical data including type of procedure (anterior, posterior, circumferential), use of osteotomies, estimated blood loss (EBL), length of surgery, length of hospitalization, and complications was

recorded. Preoperative and postoperative Cobb angle measurements were performed. Preoperative and postoperative Neck Disability Index (NDI) values were calculated.

Student *t* test and Fischer exact test were used to test continuous and categorical variables. Significance was set at $p < 0.05$.

Results

Cervical scoliosis was initially identified in 18 patients; however, 5 did not meet our inclusion criteria and were excluded. Overall, 13 patients, 5 men and 8 women with an average age of 50.7 years (median 52, range 25 to 65), were enrolled. Average follow-up was 40 months (median 36, range 5 to 87). Surgery was primary in 6 cases, and 7 were revisions.

Diagnosis

Overall, 4 patients with cervical scoliosis presented with radiculopathy and 1 presented with cervical spondylosis-myelopathy. KFS was diagnosed in 2 patients, and 1 patient had a diagnosis of NF-1. There was 1 patient each with torticollis, postlaminectomy kyphosis, postsurgical coronal deformity, and rheumatoid arthritis-associated cervical deformity.

Surgical Data

All patients underwent instrumentation and fusion. An anterior-only approach was used in 6 cases, with an average of 4 levels fused (range 2 to 6). Posterior-only instrumented fusions were performed in 5 cases, with an average of 8.7 levels fused (range 5 to 10). Combined anterior-posterior instrumented fusion was used in 2 cases. Corpectomies were performed in 6 patients and posterior osteotomies in 3 (► Fig. 1). A combination of local autograft and allograft was used to supplement the fusion. The average EBL was 286 mL

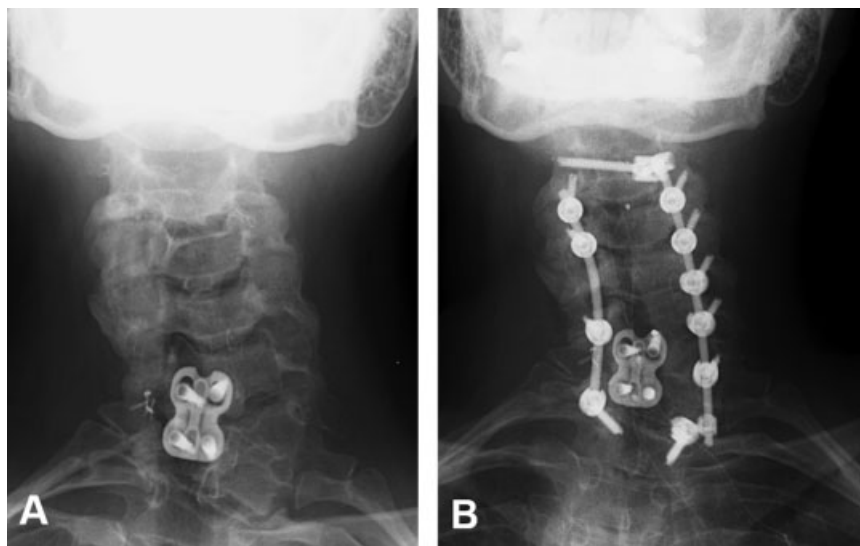


Fig. 1 A 53-year-old woman with Klippel-Feil syndrome and C7 hemivertebrae. (A) She had C6–T1 anterior cervical discectomy and fusion at an outside institution complicated by vertebral artery injury. (B) She presented with radicular symptoms and underwent C3–C6 laminectomy and C2–T2 posterior cervical fusion. She is doing well at 30 months postoperatively.

(median 150, range 50 to 900), the average surgical time was 266 minutes (median 239, range 136 to 508), and the average hospital stay was 2.7 days (median 2, range 1 to 7). The patients having a posterior-only approach had significantly higher rates of EBL (370 mL) as compared with the patients having an anterior-only approach (112.5 mL; $p < 0.002$). The surgical time was also significantly higher for the patients having a posterior-only approach (310 minutes) compared

with the patients having an anterior-only approach (193 minutes; $p < 0.0017$). There were no differences in the hospital length of stay between the two groups (2 days versus 2.8 days, $p = 0.16$).

Osteotomies

An osteotomy was required in 4 of the 13 patients with a rigid deformity, and 3 cases had posterior-only osteotomies

Table 1 Patient diagnoses, management, and complications

Patient ID	Diagnoses (in addition to cervical scoliosis)	Management	Complications	Adjacent segment pathology	Length of follow up (mo)
1	CSM	C5 corpectomy, C6–C7 ACDF	None	None	41
2	Radiculopathy	T1–T2 osteotomy, C5–T2 PSF	None	None	5
3	Radiculopathy	C4 corpectomy, C5–C6 ACDF	Pseudarthrosis (managed via PCF at postoperative 13 mo)	None	37
4	NF-1	C4–T1 ACDF	None	Managed via C2–C4 PCF at postoperative 24 mo	39
5	Torticollis	C2–T2 PSF	(1) Return to OR for rod revision; (2) Occ–C4 fusion 2nd to Occ–cervical deformity; (3) revision Occ–C4 fusion, SCM release	None	52
6	Posttraumatic deformity	(1) C6 corpectomy, C3–T1 ACDF; (2) C2–T1 PSF	C5 palsy requiring return to OR for revision of instrumentation (C5 palsy resolved at postoperative 3 mo)	None	87
7	Rheumatoid arthritis	(1) C4 corpectomy, C2–T3 ACDF; (2) C2–T1 PSF	(1) C2 graft dislodgment requiring revision; (2) syncopal episode requiring readmission perioperatively (resolved)	None	36
8	Postlaminectomy deformity	C5 corpectomy, C3–T1 ACDF	Pneumonia, UTI (resolved after antibiotics treatment)	None	49
9	Klippel-Feil syndrome	C2–T2 PSF	None	Nonoperative management	30
10	Radiculopathy	C5–T1 ACDF	None	None	47
11	Radiculopathy	C5 corpectomy, ACDF C4–C7	Neck swelling requiring readmission perioperatively (resolved)	None	29
12	Klippel-Feil syndrome	C3 and C7 PSO, C2–T4 PSF	Radicular symptoms managed with (1) right C6, C7 decompression/C6 pedicle resection; (2) right T1–T2 foraminotomy	None	23
13	Postsurgical coronal deformity	C3, C7 PSO, Occ–T4 fusion	None	None	50

Abbreviations: ACDF, anterior cervical discectomy and fusion; CSM, cervical spondylotic myelopathy; NF-1, neurofibromatosis type 1; Occ, occipital; OR, operating room; PCF, posterior cervical fusion; PSF, posterior spinal fusion; PSO, pedicle subtraction osteotomy; SCM, sternocleidomastoid; UTI, urinary tract infection.

Note: *Perioperative* denotes 0 to 90 days postoperative.

consisting of pedicle subtraction osteotomies and Smith-Petersen osteotomy. A combined anterior cervical osteotomy and posterior osteotomy was performed in 1 patient. Our technique of anterior cervical osteotomy has been described elsewhere.¹¹

Complications

Complications developed in 7 patients, and 2 had clinical adjacent segment pathology (►Table 1). Surgical complications included a return to the operating room during the index procedure for a rod revision in a patient with torticollis who initially underwent a C2–T2 posterior spinal fusion. This same patient had a recalcitrant deformity and underwent an occiput-to-C4 fusion due to occipitocervical deformity at 4 years postoperatively. Then she underwent further revision occiput-to-C4 fusion with sternocleidomastoid release at 5 years postoperatively (►Fig. 2). Other surgical complications included a C5 palsy requiring a secondary procedure, pseudarthrosis requiring treatment, graft dislodgment requiring a revision, postoperative neck swelling requiring readmission for monitoring, and a decompression procedure 3 months postoperatively in one patient due to progressive neurologic symptoms and a return to the operating room 1 year postoperatively for instrumentation revision.

Medical complications included a syncopal episode requiring readmission in the perioperative period (up to 90 days postoperatively) and urinary tract infection and pneumonia in one patient.

Radiographic Data

When available, radiographs at the 6-week, 12-week, 6-month, 1-year, and 2-year points were reviewed. The average preoperative coronal Cobb angle was 35.1 degrees (median 31, range 13 to 63) and was corrected to 15.7 degrees (median 10.5, range 2 to 59) postoperatively ($p < 0.005$).

Patient-Reported Outcomes

The average preoperative NDI score was 24.9 (median 26, range 6 to 37) and was reduced to 17.8 (median 18, range 7 to 30) at the latest follow-up ($p < 0.02$). Lower scores indicate better outcomes on the NDI.

Discussion

To our knowledge, ours is the largest series focused on the surgical management of cervical scoliosis. In the cervical spine, sagittal deformities are more common than coronal deformities. Sagittal deformities can be associated with trauma, rheumatoid arthritis, ankylosing spondylitis, and numerous other causes. In our series, the diagnoses leading to cervical scoliosis were heterogeneous. KFS and NF-1 contributed to 3 of the 13 cases of cervical scoliosis. Outcomes of surgical management of cervical scoliosis have been limited to case reports and small case series, which prompted us to report our experience.

We found a significant improvement in patient-reported outcomes (NDI, $p < 0.02$) postoperatively. The 7.1-point improvement in the NDI approached the minimal clinically

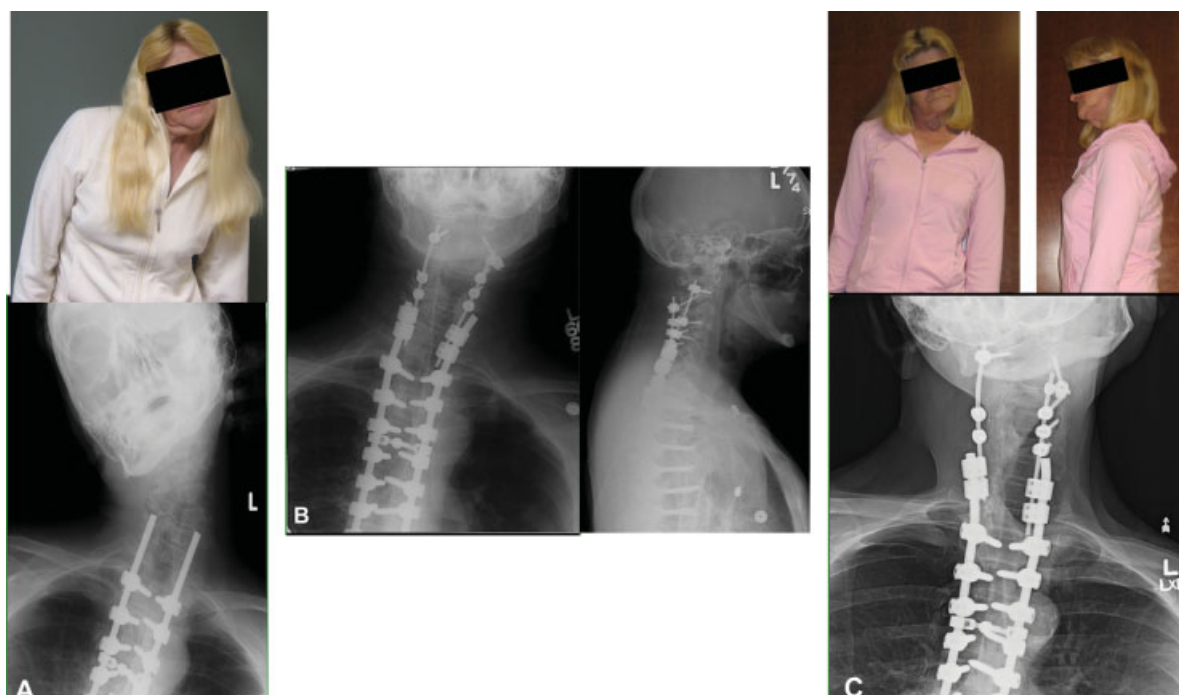


Fig. 2 (A) A 54-year-old woman with cervicothoracic scoliosis and torticollis. She had a thoracic scoliosis of 60 degrees as well. She underwent a first stage T2 to L2 posterior spinal fusion. The rods were left intentionally long to allow for cervicothoracic reconstruction. (B) Correction of the cervical deformity was performed via a C2–T3 posterior cervical fusion with instrumentation. On postoperative day 2, the patient returned to the OR for recontouring of the cervical rod due to ongoing deformity. (C) Four years postoperatively, the patient presented with occipitocervical coronal deformity. (D) She underwent an occipitocervical fusion and sternocleidomastoid release. (E) Two months later, she had a recurrence of the cervical deformity managed with revision occipitocervical fusion and sternocleidomastoid release. The patient has been symptom free at latest follow-up of 52 months.

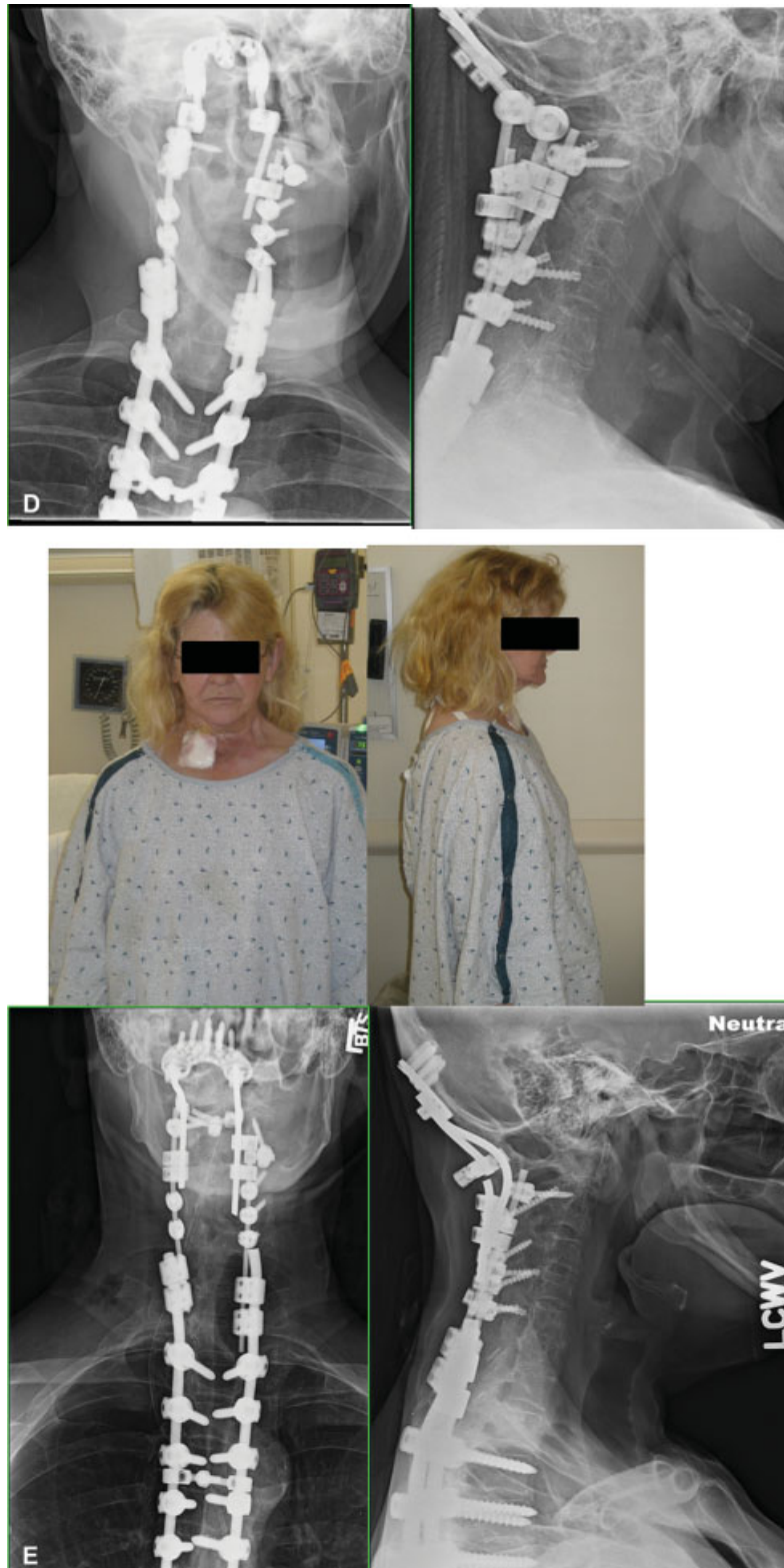

Fig. 2 Continued.

important difference for the NDI (change of 7.5).¹² Cobb angle measurements also demonstrated significant improvement from preoperative levels (35.1 to 15.7 degrees, $p < 0.005$). Complications occurred in 7 of the 13 (53.8%) patients. Most of the complications were surgical, and 3 were medical. The

complication rate for the management of cervical scoliosis has not been clearly defined. However, 3 patients required a return to the operating room during the same admission for the management of instrumentation failure and neurologic deficits. Although this complication rate is higher than

nondeformity cases for radiculopathy or myelopathy, no patient had permanent neurologic deficits and there were no deaths.

Adult spinal deformity (thoracic and lumbar) surgery is associated with surgical and medical complication rates of 36 to 76%.¹³⁻¹⁶ It is not surprising that cervical scoliosis has a similar complication rate as adult spinal deformity. Extensive surgery is performed to address the deformity and concurrent neurologic symptoms. Similar to health-related outcome questionnaires for adult spinal deformity patients, the NDI scores for patients with cervical scoliosis demonstrated significant improvements following surgical management.

Our surgical management was dictated by the presenting pathology. For patients who had a compensated deformity demonstrated in a radiographic finding with minimal clinical impact, minimal to no correction was needed. For symptoms of cervical radiculopathy, in 3 of the 4 cases, an anterior-based decompression and fusion was chosen. The 2 patients with KFS and the 1 patient with torticollis had a posterior-only based instrumentation and fusion because their primary pathology was the coronal deformity. For the patients with concurrent kyphosis (rheumatoid arthritis and postlaminectomy kyphosis), a combined anterior-posterior approach was performed. When addressing the cervical deformity and concurrent radicular or myelopathic symptoms, our goals were to correct the coronal deformity while ensuring adequate nerve root decompression. There are cases where a patient may have a cervical coronal deformity but the neurologic symptoms may not be at the apex of the curvature. In these situations, we recommend managing the symptomatic level without addressing the deformity because it is asymptomatic. If the cervical scoliosis is only a radiographic finding and the patient is asymptomatic, then we do not recommend surgical intervention. In cases where the patient has a clinically obvious cervical deformity without neurologic symptoms and would like to have the deformity corrected, then we would proceed with the deformity correction.

Two of our patients had KFS, which is characterized by a short neck, low hairline, and two or more congenitally fused vertebrae in the cervical spine. A 53.3% prevalence of cervical scoliosis has been noted in 30 patients with KFS.¹ In another series of 57 KFS patients, a 70% prevalence of scoliosis was noted throughout the mobile spine.⁴ Although KFS has been associated with cervical scoliosis, the prevalence of surgery for cervical spine symptoms in patients with KFS is variable. Theis et al evaluated 32 patients with KFS and congenital scoliosis with a minimum follow-up of 10 years and noted 22% (7/32) had cervical spine symptoms.¹⁷ In 2 of the 7 patients with KFS (6.3%, 2/32), surgical management was required for their cervical spine symptoms. Other investigators have noted 33% (19/57) of KFS patients required surgery for cervical spine symptoms.¹⁸ However, it is not clear how many of these patients had scoliosis.¹⁸

In addition to KFS, another condition associated with cervical vertebrae anomalies is Goldenhar syndrome.¹⁹ This syndrome is also known as oculoauricular vertebral

dysplasia. In a series of 8 patients with Goldenhar syndrome, 6 had cervical spine anomalies including hemivertebrae, failure of segmentation (2 patients), hypoplastic odontoid, multilevel cervical fusion, and C3-C4 bony bar.¹⁹ Goldenhar syndrome is diagnosed early in the pediatric population, and in our cohort of adult patients, none had this diagnosis.

We did have one patient with NF-1. NF-1 is associated with kyphosis of the cervical spine but scoliosis or kyphoscoliosis can also occur.^{3,5,6} NF-1 is a multisystem disease associated with a mutation of the NF-1 gene. The inheritance is autosomal dominant. Clinical findings are based on the National Institutes of Health Consensus conference of 1987 with 2 of 7 findings being necessary for a diagnosis. In the cervical spine, kyphosis is more common in NF-1 than scoliosis.³ Dysplastic curvatures of the thoracic spine causing the rib penciling are commonly associated with cervical spine anomalies.⁵ Cervical scoliosis associated with NF-1 usually starts in the lower subaxial spine and extends into the thoracic spine.⁶

Two of our patients developed adjacent segment pathology (2/13, 15.3%). One patient initially had a four-level anterior cervical fusion and required posterior-based fusion to address the adjacent segment pathology. The second patient had prior anterior fusion at an outside institution, and we subsequently performed a posterior cervical fusion. He developed adjacent segment pathology that was responsive to nonoperative management. Adjacent segment pathology is part of the natural history of multilevel cervical or lumbar spine fusions.^{20,21} Ten years following an anterior cervical fusion, a 25% risk of adjacent segment pathology has been reported.²⁰ Moreover, an incidence of 2.9% of adjacent segment pathology following anterior cervical fusion was noted. In the lumbar spine, at 10 years, a 36% prevalence of adjacent segment pathology requiring surgery has been noted.²¹

There were some limitations to our study. We had a small sample size due to the rarity of cervical scoliosis. A multicenter study would be beneficial to yield more patients with this condition. We also had a heterogeneous diagnosis leading to cervical scoliosis. Unlike the more common idiopathic scoliosis of the thoracic spine, cervical scoliosis can be caused by a variety of conditions, and it can be challenging to enroll a homogenous diagnostic group. Our study serves as a start point for further multi-institutional studies on the outcomes following surgical management of cervical scoliosis.

Conclusion

In our series of 13 patients with cervical scoliosis, significant improvements in patient-reported outcomes and Cobb angle measurements were noted postoperatively. The diagnoses leading to cervical scoliosis were heterogeneous; however, similar to other studies, we had patients with diagnoses of KFS and NF-1. Our patients had a 53.8% rate of medical and surgical complications. Surgeons managing patients with cervical scoliosis should perform meticulous preoperative planning and counsel the patient on the high rate of complications, which is balanced by the long-term improvement in outcomes.

Disclosures

Addisu Mesfin, none

Wajeeh R. Bakhsh, none

Tapanut Chuntarapas, none

K. Daniel Riew, Board membership: CSRS, KASS, NASS, AOSpine; Royalties: Osprey, Biomet, Medtronic Sofamor Danek; Stock/stock options: Amedica, Benvenue, Expanding Orthopedics, Nexgen Spine, Osprey, Paradigm Spine, Spinal Kinetics, Spineology, Vertiflex, PSD

References

- 1 Samartzis D, Kalluri P, Herman J, Lubicky JP, Shen FH. Cervical scoliosis in the Klippel-Feil patient. *Spine (Phila Pa 1976)* 2011; 36(23):E1501–E1508
- 2 Ruf M, Jensen R, Harms J. Hemivertebra resection in the cervical spine. *Spine (Phila Pa 1976)* 2005;30(4):380–385
- 3 Taleb FS, Guha A, Arnold PM, Fehlings MG, Massicotte EM. Surgical management of cervical spine manifestations of neurofibromatosis type 1: long-term clinical and radiological follow-up in 22 cases. *J Neurosurg Spine* 2011;14(3):356–366
- 4 Thomsen MN, Schneider U, Weber M, Johannisson R, Niethard FU. Scoliosis and congenital anomalies associated with Klippel-Feil syndrome types I–III. *Spine (Phila Pa 1976)* 1997;22(4):396–401
- 5 Winter RB, Moe JH, Bradford DS, Lonstein JE, Pedras CV, Weber AH. Spine deformity in neurofibromatosis. A review of one hundred and two patients. *J Bone Joint Surg Am* 1979;61(5):677–694
- 6 Yong-Hing K, Kalamchi A, MacEwen GD. Cervical spine abnormalities in neurofibromatosis. *J Bone Joint Surg Am* 1979;61(5): 695–699
- 7 Winter RB, House JH. Congenital cervical scoliosis with unilateral congenital nerve deficit in the upper extremity. Report of two cases. *Spine (Phila Pa 1976)* 1981;6(4):341–346
- 8 Graziano GP, Herzenberg JE, Hensinger RN. The halo-Ilizarov distraction cast for correction of cervical deformity. Report of six cases. *J Bone Joint Surg Am* 1993;75(7):996–1003
- 9 Lim KS, Shim JS, Lee YS. Is sternocleidomastoid muscle release effective in adults with neglected congenital muscular torticollis? *Clin Orthop Relat Res* 2014;472(4):1271–1278
- 10 Patwardhan S, Shyam AK, Sancheti P, Arora P, Nagda T, Naik P. Adult presentation of congenital muscular torticollis: a series of 12 patients treated with a bipolar release of sternocleidomastoid and Z-lengthening. *J Bone Joint Surg Br* 2011;93(6):828–832
- 11 Kim HJ, Piyaskulkaew C, Riew KD. Anterior cervical osteotomy for fixed cervical deformities. *Spine (Phila Pa 1976)* 2014;39(21): 1751–1757
- 12 Carreon LY, Glassman SD, Campbell MJ, Anderson PA. Neck Disability Index, short form-36 physical component summary, and pain scales for neck and arm pain: the minimum clinically important difference and substantial clinical benefit after cervical spine fusion. *Spine J* 2010;10(6):469–474
- 13 Zimmerman RM, Mohamed AS, Skolasky RL, Robinson MD, Keblish KM. Functional outcomes and complications after primary spinal surgery for scoliosis in adults aged forty years or older: a prospective study with minimum two-year follow-up. *Spine (Phila Pa 1976)* 2010;35(20):1861–1866
- 14 Cho SK, Bridwell KH, Lenke LG, et al. Major complications in revision adult deformity surgery: risk factors and clinical outcomes with 2- to 7-year follow-up. *Spine (Phila Pa 1976)* 2012; 37(6):489–500
- 15 Hassanzadeh H, Jain A, El Dafrawy MH, et al. Clinical results and functional outcomes of primary and revision spinal deformity surgery in adults. *J Bone Joint Surg Am* 2013;95(15): 1413–1419
- 16 Mesfin A, Buchowski JM, Zebala LP, et al. High-dose rhBMP-2 for adults: major and minor complications: a study of 502 spine cases. *J Bone Joint Surg Am* 2013;95(17):1546–1553
- 17 Theiss SM, Smith MD, Winter RB. The long-term follow-up of patients with Klippel-Feil syndrome and congenital scoliosis. *Spine (Phila Pa 1976)* 1997;22(11):1219–1222
- 18 Baba H, Maezawa Y, Furusawa N, Chen Q, Imura S, Tomita K. The cervical spine in the Klippel-Feil syndrome. A report of 57 cases. *Int Orthop* 1995;19(4):204–208
- 19 Al Kaissi A, Ben Chehida F, Ganger R, Klaushofer K, Grill F. Distinctive spine abnormalities in patients with Goldenhar syndrome: tomographic assessment. *Eur Spine J* 2015;24(3): 594–599
- 20 Hilibrand AS, Carlson GD, Palumbo MA, Jones PK, Bohlman HH. Radiculopathy and myelopathy at segments adjacent to the site of a previous anterior cervical arthrodesis. *J Bone Joint Surg Am* 1999;81(4):519–528
- 21 Ghiselli G, Wang JC, Bhatia NN, Hsu WK, Dawson EG. Adjacent segment degeneration in the lumbar spine. *J Bone Joint Surg Am* 2004;86-A(7):1497–1503