



CASE REPORT

Successful management of 3 dogs with colonic pythiosis using itraconazole, terbinafine, and prednisone

Krystle L. Reagan¹  | Stanley L. Marks²  | Patricia A. Pesavento³ |
 Ann Della Maggiore¹ | Bing Y. Zhu¹ | Amy M. Grooters⁴

¹Veterinary Medical Teaching Hospital, University of California Davis, Davis, California

²Department of Medicine and Epidemiology, School of Veterinary Medicine, University of California, Davis, California

³Department of Pathology, Microbiology, and Immunology, School of Veterinary Medicine, University of California, Davis, California

⁴Department of Veterinary Clinical Sciences, School of Veterinary Medicine, Louisiana State University, Baton Rouge, Louisiana

Correspondence

Krystle L. Reagan, University of California Davis, VMTH, 1 Garrod Drive, Davis, CA 95616.
 Email: kreagan@ucdavis.edu

Present addresses

Ann Della Maggiore, MarQueen Pet Emergency and Specialty, Roseville, CA 95661

Bing Y. Zhu, Small Animal Specialist Hospital, North Ryde, New South Wales 2113, Australia

Abstract

Gastrointestinal (GI) pythiosis is a severe and often fatal disease in dogs that traditionally has been poorly responsive to medical treatment. Although aggressive surgical resection with wide margins is the most consistently effective treatment, lesion location and extent often preclude complete resection. Recently, it has been suggested that the addition of anti-inflammatory doses of corticosteroids may improve outcome in dogs with nonresectable GI pythiosis. This report describes 3 dogs with colonic pythiosis in which complete resolution of clinical signs, regression of colonic masses, and progressive decreases in serological titers were observed after treatment with itraconazole, terbinafine, and corticosteroids. This treatment protocol represents a promising treatment for dogs with GI pythiosis in which surgical intervention is not feasible.

KEYWORDS

antifungal, colitis, oomycete, *Pythium insidiosum*

1 | INTRODUCTION

The aquatic oomycete *Pythium insidiosum* is the causative agent of pythiosis, a severe, progressive, and often fatal disease that most often affects the skin or gastrointestinal (GI) tract in dogs.¹ Although historically it has been diagnosed in tropical and subtropical regions,² its geographical distribution in the United States has expanded over the past 15 years to include more arid environments in California and Arizona and less temperate climates in Wisconsin.^{3,4} Gastrointestinal pythiosis typically causes focal or multifocal segmental thickening or expansile granulomatous masses involving the stomach, small intestine, colon, and, less often, the esophagus.^{3,5-8} Areas of the GI tract

that most often are affected include the gastric outflow region and the ileocecolic junction (ICCJ).

Treatment of GI pythiosis traditionally has been unrewarding, likely because ergosterol (the target of most traditional antifungal drugs) generally is lacking in the oomycete cell membrane.⁹ Instead, as sterol auxotrophs, *Pythium*, *Lagenidium*, and related oomycetes incorporate sterols from their environments or hosts rather than producing them.⁹ Nonetheless, improvement or resolution of clinical disease has been described after treatment with ergosterol-targeting drugs (most often itraconazole and terbinafine) in a small number of dogs with pythiosis as well as in a 2-year-old child.^{5,10-12}

Despite these limited successes, the prognosis for dogs with non-resectable GI pythiosis has for the most part remained poor, with a reported median survival time of 26.5 days.^{3,5} Recently, however, it was noted that the addition of anti-inflammatory doses of prednisone to antifungal treatment in an effort to palliate clinical signs may

Abbreviations: BCS, body condition score; BUN, blood urea nitrogen; GI, gastrointestinal; ICCJ, ileocecolic junction; PP, percent positivity.

This is an open access article under the terms of the Creative Commons Attribution-NonCommercial License, which permits use, distribution and reproduction in any medium, provided the original work is properly cited and is not used for commercial purposes.

© 2019 The Authors. *Journal of Veterinary Internal Medicine* published by Wiley Periodicals, Inc. on behalf of the American College of Veterinary Internal Medicine.

increase the likelihood of successful treatment in dogs with non-resectable GI pythiosis, and that complete resolution of disease can occur in dogs treated with corticosteroids alone.^{1,13} Based on this anecdotal information, 3 dogs with nonresectable colonic pythiosis were treated with a combination of itraconazole, terbinafine, and prednisone without surgical intervention. The purpose of our report is to present the clinicopathologic findings, treatment, and outcome in these 3 dogs.

2 | CASE 1

A 1-year-old male neutered Labrador cross breed dog was presented to the University of California, Davis Veterinary Medical Teaching Hospital with a 1-month history of large bowel diarrhea, hematochezia, tenesmus, dyschezia, and weight loss. The dog was adopted 1 month before presentation and the previous medical history was unknown. General physical examination showed a body condition score (BCS) of 2 out of 9 and slight tachycardia. Body weight on presentation was 12.8 kg. Rectal examination elicited a pain response but no other abnormalities were noted. A CBC identified eosinophilia (1855/ μ L; reference range, 0-1500/ μ L) and serum biochemistry disclosed a mild decrease in blood urea nitrogen (BUN) concentration of 8 mg/dL (reference range, 11-33 mg/dL). Abdominal ultrasound examination identified smooth, severe (1 cm), circumferential thickening of the wall of the descending colon over an area >7 cm in length. An additional discrete eccentric mass approximately 1 \times 1 cm was noted in the ileal wall. Both lesions were hypoechoic with decreased definition of wall layering. The mesenteric and sublumbar lymph nodes were enlarged at approximately 1.5 cm in diameter with normal echogenicity, and a small volume of peritoneal effusion was detected. Cytological evaluation of the effusion disclosed a protein concentration of 3.2 g/dL and 181 560 nucleated cells/ μ L comprised 76% neutrophils and 19% eosinophils. Serology for anti-*P. insidiosum* antibodies (Pythium Laboratory, Louisiana State University, Baton Rouge, Louisiana) was positive with a percent positivity (PP) of 104% (values reported to be <15% in healthy dogs and >40% in dogs with pythiosis).¹⁴ Colonoscopy^b identified hyperemic, irregular, and edematous colonic mucosa. No obvious mass effect was noted. Colonic pinch biopsy specimens were consistent with severe eosinophilic and histiocytic necrotizing colitis and intralumenal hyphal structures with nonparallel rarely septate walls. These organisms stained strongly with Gomori methenamine-silver (GMS) and poorly with periodic acid-Schiff (PAS; Figure 1). Ileal pinch biopsy specimens had moderate eosinophilic and histiocytic inflammation but no infectious organisms were noted.

Subtotal colectomy with removal of the ICCJ was recommended to excise the colonic masses and ileal mass with a goal of obtaining 5-cm margins. The owners declined surgery, and treatment with prednisone (0.8 mg/kg PO q24h for 3 days and then 0.4 mg/kg PO q24h), itraconazole (generic non-compounded itraconazole) (8 mg/kg PO q24h), and terbinafine (generic non-compounded terbinafine) (10 mg/kg PO q24h) was implemented. At reevaluation 1 month after initiation of treatment, all clinical signs including diarrhea, hematochezia, and

tenesmus had resolved and the dog had gained 1.9 kg body weight. A repeat CBC identified resolution of the previously noted eosinophilia (194/ μ L), but mild hypercalcemia (12 mg/dL; reference range, 9.6-11.2 mg/dL) was noted on serum biochemistry. A trough itraconazole serum concentration was low at <0.3 μ g/mL (Itraconazole level detection by bioassay, MiraVista, Indianapolis, Indiana). This bioassay detects activity of all antifungals and interpretation is difficult because this patient also was receiving terbinafine. The itraconazole dosage was increased to 13.4 mg/kg PO q24h and the terbinafine and prednisone were continued as described above.

At reevaluation 3 months after initiation of treatment, the dog had gained an additional 1.6 kg body weight and had no clinical signs. Abdominal ultrasound examination identified mild thickening of the ascending colonic wall, cecum, and ileum with resolution of the previously noted masses within the colon and ileum. The previously enlarged mesenteric and sublumbar lymph nodes were ultrasonographically normal. Anti-*P. insidiosum* antibody serology was repeated and had decreased to 27% PP. After 6 months of treatment, serology results had decreased further to 13% PP, and prednisone was tapered to 0.16 mg/kg PO q24h. Itraconazole and terbinafine were continued at the same dosage as initially administered. Abdominal ultrasound examination and serology were repeated every 6 months over the course of 5 years while continuing the same doses of prednisone, itraconazole, and terbinafine, during which the dog remained asymptomatic and had unremarkable abdominal ultrasound assessments. Anti-*P. insidiosum* antibody serology was monitored every 6-12 months and continued to be 13%-26% PP. Two years after diagnosis, serology monitoring became unavailable from the initial laboratory and continued serologic monitoring was performed using an alternative laboratory (Pythium Laboratory, Pathobiology Diagnostic Services, Auburn University, Auburn, Alabama). Five years after diagnosis, the dog's anti-*P. insidiosum* antibody serology was 6% PP and the dog was still receiving itraconazole, terbinafine, and prednisone at the same doses described above.

3 | CASE 2

A 7-year-old male Newfoundland and Labrador cross breed dog presented with a 1-month history of large bowel diarrhea characterized by hematochezia, tenesmus, and dyschezia and weight loss of 2.5 kg over the previous 3 months. The dog was an active hunting dog and had frequent exposure to flooded rice fields, although it had not traveled outside the state of California. Physical examination was unremarkable apart from the rectal examination which identified an enlarged, firm prostate gland with frank blood noted on the glove. Body condition score was 5/9 and body weight was 52.5 kg. A CBC was normal except for a high normal eosinophil count of 1118/ μ L (reference range, 0-1500/ μ L). A serum biochemistry panel disclosed mild hypoalbuminemia of 3.1 g/dL (reference range, 3.4-4.3 g/dL) and low BUN concentration of 7 mg/dL (reference range, 11-33 mg/dL). Abdominal ultrasound examination identified a hypoechoic eccentric 5 \times 2 cm mass associated with the

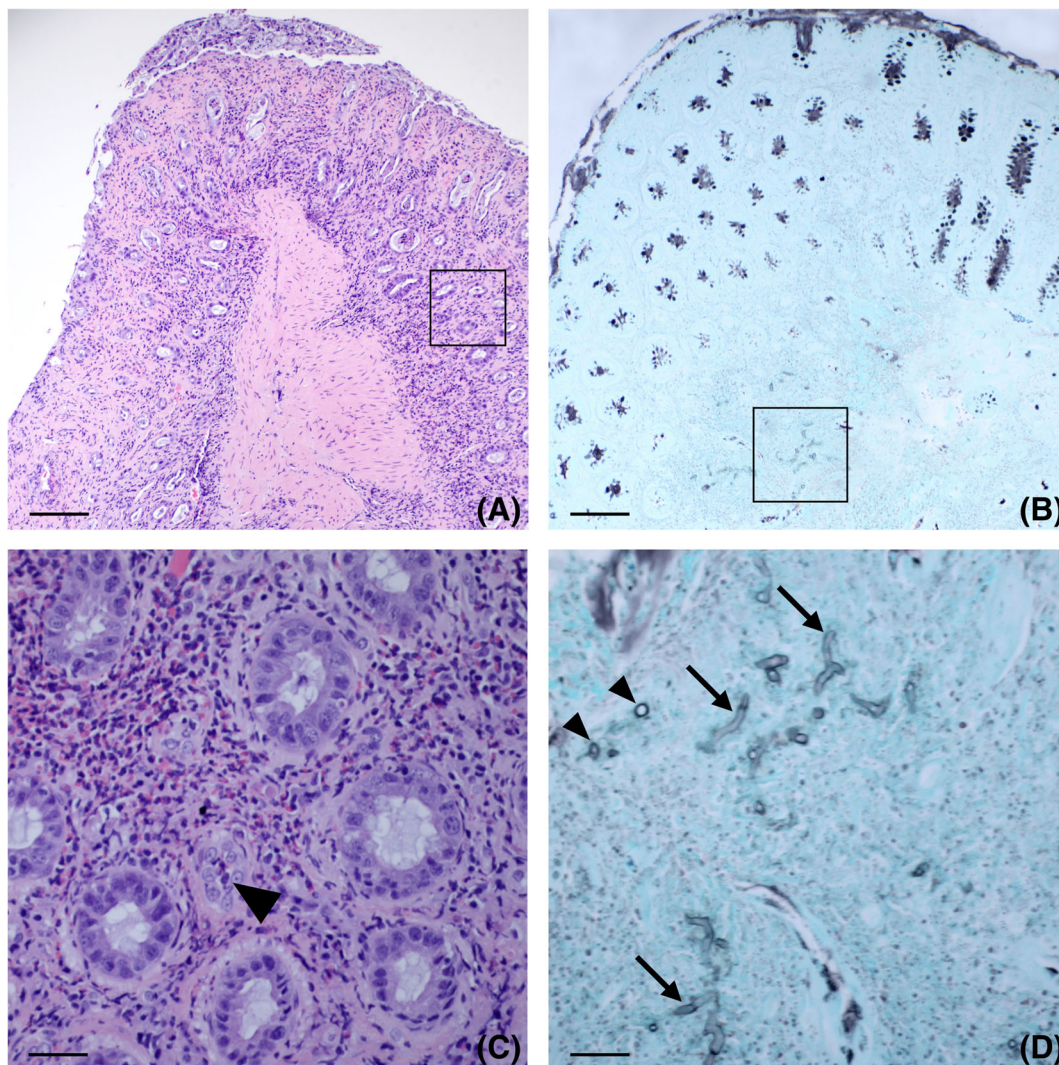


FIGURE 1 A, Photomicrograph from a pinch biopsy of the colon extending to the level of the superficial submucosa obtained from Case 1. There is cellular debris on the surface, and segmental loss of overlying mucosa (ulceration). Glands are separated by inflammation. Hematoxylin and eosin, scale bar = 200 μ m. B, A silver stain (black) demonstrates goblet cells within glands and a region within the submucosa that contains short segments of hyphae. Gomori methenamine-silver stain, scale bar = 200 μ m. C, Boxed region of (A). Within the inflamed lamina propria, there are segmental regions that are dense with eosinophils, which are sometimes present within glandular lumen (arrow). Hematoxylin and eosin, scale bar = 35 μ m. D, Boxed region of (B). A silver stain demonstrates blunt, short segments of fungal hyphae in transverse (arrowheads) and sagittal section (arrows) that are embedded within the submucosal inflammation. Gomori methenamine-silver stain, scale bar = 35 μ m

descending colon with loss of normal wall layering. An additional hypoechoic circumferential mass measuring 1.3 cm in diameter was noted at the ICCJ. The sublumbar and mesenteric lymph nodes were moderately enlarged at 1 cm in diameter and were hypoechoic. Anti-*P. insidiosum* antibody serology was positive at 82% PP (Pythium Lab, Louisiana State University, Baton Rouge, Louisiana). Colonoscopy (Storz colonoscope 60714 NK, Karl Storz Endoskope, Tuttlingen, Germany) identified irregular mucosa and decreased visibility of vasculature in the ascending colon, suggesting colonic wall thickening. The transverse colon had mild granularity on the mucosal surface. The descending colon had multiple nodules with areas of erythema. The ileum appeared normal, but the ICCJ had a granular appearance. Colonic pinch biopsy specimens obtained at colonoscopy

had neutrophilic, eosinophilic, and lymphoplasmacytic colitis with intralumenal fungal hyphae that had nonparallel walls and were rarely septate (Figure 1A). These organisms stained positively with GMS (Figure 1B) and poorly with PAS.

Surgical treatment was recommended but declined by the owners. Medical treatment was initiated with prednisone (0.4 mg/kg PO q12h for 14 days), itraconazole (10 mg/kg PO q24h), and terbinafine (10 mg/kg PO q24h). All clinical signs resolved after 2 weeks of treatment. Anti-*P. insidiosum* antibody serology results were 15% PP and 16% PP after 4 and 6 months of treatment, respectively. Antifungal medications were discontinued without a tapering period after 10 months of administration and the owner reported no recurrence of clinical signs after discontinuing medications. In addition, repeat

abdominal ultrasound examination 3 years after diagnosis showed complete resolution of the previously noted ultrasonographic findings. Anti-*P. insidiosum* antibody serology at that time performed at a different laboratory remained negative at 16% PP (Pythium Laboratory, Pathobiology Diagnostic Services, Auburn University).

4 | CASE 3

A 5-year-old male intact Vizsla was presented with a 1 month history of large bowel diarrhea with hematochezia and tenesmus. The dog had no history of travel outside of California, but was regularly exposed to wetlands during field trial events. General physical examination was normal with a BCS of 4/9 and body weight of 20.2 kg, but rectal examination identified multiple 5-mm, firm nodules circumferentially within the rectum and descending colon. A CBC was normal apart from eosinophilia (1722/ μ L). A serum biochemistry panel disclosed mildly increased alkaline phosphatase activity of 114 IU/L (reference range, 14-91 IU/L). Abdominal ultrasound examination identified enlarged and hypoechoic colic lymph nodes measuring up to 1.3 cm in diameter. The rectum and descending colon within the pelvic canal could not be assessed ultrasonographically. The remainder of the GI tract was unremarkable. Fine needle aspiration of the enlarged lymph nodes was performed and marked lymphoid hyperplasia was observed on cytologic examination. Molecular clonality was assessed and confirmed a polyclonal population of lymphocytes (molecular clonality, UC Davis VMTH Clinical Diagnostic Laboratory Services, Davis, California). Anti-*P. insidiosum* antibody serology was positive at 85 PP (Pythium Laboratory, Pathobiology Diagnostic Services, Auburn University). Proctoscopy (Rigid sigmoidoscope, Welch-Allyn, Skaneateles Falls, New York) identified multifocal to coalescing mucosal ulcerations associated with underlying nodules in the distal descending colon. Pinch biopsy specimens of the affected colon had severe pyogranulomatous inflammation, but no fungal organisms were noted using special stains including GMS, PAS, and McDonald's Gram stains. A presumptive diagnosis of pythiosis was made given the history, clinical signs, supportive serology, and histopathologic findings despite the lack of observable fungal organisms in endoscopic biopsy specimens.

Surgical treatment with excision of the diseased distal colon and rectal pull-through procedure were recommended but declined by the owners, and medical treatment was initiated with prednisone (0.5 mg/kg PO q12h for 2 weeks then decreased to q24h for 2 months), itraconazole (10 mg/kg PO q24h) (generic non-compounded itraconazole), and terbinafine (12 mg/kg PO q24h) (generic noncompounded terbinafine).

At reevaluation 1 month after starting medical treatment, the owners reported complete cessation of clinical signs within 1 week after initiating treatment. Rectal examination indicated complete resolution of the rectal masses, and a repeat CBC was unremarkable. Anti-*P. insidiosum* antibody serology was 65% PP (Pythium Laboratory, Pathobiology Diagnostic Services, Auburn University). A follow-up abdominal ultrasound examination after 2 months of treatment was unremarkable,

with resolution of the previously noted colic lymphadenomegaly. Prednisone was tapered between months 2 and 5 of treatment by 25% once monthly and then discontinued. Anti-*P. insidiosum* antibody serology was reevaluated after 3, 5, 7, and 10 months of treatment with results of 22% PP, 19% PP, 21% PP, and 21% PP, respectively. After 12 months of treatment, the dog remained clinically normal with normal rectal examination and abdominal ultrasonography findings, and antifungal medications were discontinued. One month after discontinuing itraconazole and terbinafine, the dog did not show any clinical signs, abdominal ultrasound examination was unremarkable, and anti-*P. insidiosum* antibody serology was 21% PP (Pythium Laboratory, Pathobiology Diagnostic Services, Auburn University).

5 | DISCUSSION

Few single case reports have documented treatment success with marginal surgical excision and medical treatment using a combination of potassium iodide, itraconazole, and terbinafine,¹⁵ or *Pythium* immunotreatment, itraconazole, and terbinafine.¹¹ Another case report described a positive response to medical treatment without surgical resection in a dog with gastric pythiosis after administration of itraconazole, terbinafine, and mefenoxam.¹⁰ It is difficult to determine whether surgical or medical intervention, or a combination of both, was responsible for the favorable outcomes in these dogs, but these results do indicate that combination treatment could be superior to itraconazole monotherapy.

Triazole and squalene epoxidase inhibitors inhibit fungal ergosterol synthesis, but *Pythium* lacks ergosterol in its cell membrane.^{9,16} One previous in vitro investigation failed to show susceptibility of *P. insidiosum* to itraconazole and showed only weak susceptibility to terbinafine, which may be a consequence of intracellular accumulation of squalene rather than ergosterol inhibition.¹⁷ Another study as well as a single case report in a human patient showed synergism between terbinafine and itraconazole (as was used in the 3 dogs presented here) for some strains of *P. insidiosum*,^{12,18} but other in vitro reports have not noted this synergism.¹⁹

The 3 dogs described here were treated with anti-inflammatory doses of prednisone in addition to the antifungal medications itraconazole and terbinafine. The inclusion of prednisone in combination with antifungal treatment is a novel treatment modality in dogs with GI pythiosis that has been used to palliate severe clinical signs in affected dogs with the observation that some of these dogs had complete resolution of pythiosis.¹ Corticosteroids are an important adjunct treatment for some pulmonary mycotic infections and for histoplasmosis in people and systemic mycoses in dogs.²⁰⁻²⁴ This treatment is counterintuitive, because high dose or long-term corticosteroid treatment is associated with immunosuppression and predisposes patients to opportunistic fungal infections,²⁵ but lower anti-inflammatory dosages appear to improve outcomes. Pythiosis is a highly inflammatory disease as indicated by the dense cellular infiltrates noted on histopathology of colonic biopsy specimens. Eosinophilic inflammation is a hallmark of GI pythiosis and likely contributes to the severe clinical signs noted in

these dogs. Eosinophils are highly sensitive to the effects of corticosteroids including decreased adherence, inhibited chemotaxis and apoptosis, and these effects may explain why corticosteroids lead to clinical improvement in dogs with GI pythiosis.^{26,27}

The degree to which each of the individual treatments used in these 3 patients contributed to the resolution of disease is unknown, especially given that in our previous experience patients have been clinically cured treated with corticosteroids alone or with itraconazole and terbinafine in combination in the absence of corticosteroids. Case 2 was the only dog to undergo measurement of antifungal drug concentrations which were below the limit of detection of the bioassay. This finding may indicate that the prednisone was larger a greater role in the improvement in clinical signs than the anti-fungal medications in the early stages of treatment.

Anti-*P. insidiosum* antibody serology gradually decreased in all 3 dogs and became negative after 3 to 4 months of combination treatment. These results are similar to those previously reported in dogs that have been successfully treated by complete surgical resection.¹⁴ Treatment with corticosteroids could have resulted in serologic titer decrease without disease resolution, but antibody serology continued to decrease after discontinuation of corticosteroids in Cases 2 and 3. During the courses of treatment for Cases 1 and 2, the ELISA that was previously validated with sensitivity and specificity both of 100%¹⁴ became unavailable and samples were submitted to an alternate diagnostic laboratory (Pythium Laboratory, Pathobiology Diagnostic Services, Auburn University). The second assay uses a protocol similar to that developed for the first assay; however, the *P. insidiosum* antigen used in the assay includes both secreted proteins and whole-cell extract in the latter assay, whereas the former assay utilized only whole-cell extract (personal communication, P. Barger). Although published information on sensitivity and specificity for the second assay is not available, sensitivity and specificity are expected to be similar to those of the first assay.

The medical approach presented here offers promise for dogs deemed unsuitable for surgical intervention because of location or extent of lesions or owners' financial constraints. The addition of corticosteroids appears to have provided a benefit over previous reports of anti-fungal medications alone, possibly by decreasing local inflammation. The contribution of each individual treatment in the improvement noted in the 3 dogs presented here cannot be determined from the current results, and further investigation including prospective studies involving a larger cohort of dogs are required to further evaluate the efficacy of this combination treatment and the role of each individual treatment for resolution of disease.

CONFLICT OF INTEREST DECLARATION

Authors declare no conflict of interest.

OFF-LABEL ANTIMICROBIAL DECLARATION

Itraconazole and terbinafine are off label in dogs.

INSTITUTIONAL ANIMAL CARE AND USE COMMITTEE (IACUC) OR OTHER APPROVAL DECLARATION

Authors declare no IACUC or other approval was needed.

HUMAN ETHICS APPROVAL DECLARATION

Authors declare human ethics approval was not needed for this study.

ORCID

Krystle L. Reagan  <https://orcid.org/0000-0003-3426-6352>

Stanley L. Marks  <https://orcid.org/0000-0001-7991-702X>

REFERENCES

- Grooters AM. Pythiosis, lagenidiosis, and zygomycosis. In: Sykes JE, ed. *Greene's Infectious Diseases of the Dog and Cat*. 5th ed. St. Louis, MO: Elsevier; 2020. In Preparation.
- Mendoza L, Newton JC. Immunology and immunotreatment of the infections caused by *Pythium insidiosum*. *Med Mycol*. 2005;43(6):477-486.
- Berryessa NA, Marks SL, Pesavento PA, et al. Gastrointestinal pythiosis in 10 dogs from California. *J Vet Intern Med*. 2008;22(4):1065-1069.
- Oldenhoff W, Grooters A, Pinkerton ME, Knorr J, Trepanier L. Cutaneous pythiosis in two dogs from Wisconsin, USA. *Vet Dermatol*. 2014;25(1):52-e21.
- Fischer JR, Pace LW, Turk JR, Kreeger JM, Miller MA, Gosser HS. Gastrointestinal pythiosis in Missouri dogs: eleven cases. *J Vet Diagn Invest*. 1994;6:380-382.
- Patton CS, Hake R, Newton J, Toal RL. Esophagitis due to *Pythium insidiosum* infection in two dogs. *J Vet Intern Med*. 1996;10(3):139-142.
- Graham JP, Newell SM, Roberts GD, Lester NV. Ultrasonographic features of canine gastrointestinal pythiosis. *Vet Radiol Ultrasound*. 2000;41(3):273-277.
- Miller RI. Gastrointestinal phycomycosis in 63 dogs. *J Am Vet Med Assoc*. 1985;186(5):473-478.
- Grooters AM. Pythiosis, lagenidiosis, and zygomycosis in small animals. *Vet Clin North Am Small Anim Pract*. 2003;33(4):695-720.
- Hummel J, Grooters A, Davidson G, et al. Successful management of gastrointestinal pythiosis in a dog using itraconazole, terbinafine, and mefenoxam. *Med Mycol*. 2010;49(5):1-4.
- Schmiedt CW, Stratton-Phelps M, Torres BT, et al. Treatment of intestinal pythiosis in a dog with a combination of marginal excision, chemotreatment, and immunotreatment. *J Am Vet Med Assoc*. 2012;241(3):358-363.
- Shenep JL, English BK, Kaufman L, et al. Successful medical treatment for deeply invasive facial infection due to *Pythium insidiosum* in a child. *Clin Infect Dis*. 1998;27(6):1388-1393.
- Grooters AM. Pythiosis, lagenidiosis, and zygomycosis. In: Sykes JE, ed. *Canine and Feline Infectious Diseases*. 1st ed. St. Louis, MO: Elsevier; 2013:668-678.
- Grooters AM, Leise BS, Lopez MK, Gee MK, O'Reilly KL. Development and evaluation of an enzyme-linked immunosorbent assay for the serodiagnosis of pythiosis in dogs. *J Vet Intern Med*. 2002;16(2):142-146.
- Fujimori M, Lopes ER, Lima SR, et al. *Pythium insidiosum* colitis in a dog: treatment and clinical outcome. *Ciência Rural*. 2016;46(3):526-529.
- Kerwin JL, Washino RK. Sterol induction of sexual reproduction in *Lagenidium giganteum*. *Exp Mycol*. 1983;7(2):109-115.
- Brown TA, Grooters AM, Hosgood GL. In vitro susceptibility of *Pythium insidiosum* and a *Lagenidium* sp to itraconazole, posaconazole,

- voriconazole, terbinafine, caspofungin, and mefenoxam. *Am J Vet Res*. 2008;69(11):1463-1468.
18. Argenta JS, Santurio JM, Alves SH, et al. In vitro activities of voriconazole, itraconazole, and terbinafine alone or in combination against *Pythium insidiosum* isolates from Brazil. *Antimicrob Agents Chemother*. 2008;52(2):767-769.
 19. Permpalung N, Worasilchai N, Plongla R, et al. Treatment outcomes of surgery, antifungal treatment and immunotreatment in ocular and vascular human pythiosis: a retrospective study of 18 patients. *J Antimicrob Chemother*. 2015;70(6):1885-1892.
 20. Gagnon S, Boota AM, Fischl MA, Baier H, Kirksey OW, la Voie L. Corticosteroids as adjunctive treatment for severe *Pneumocystis carinii* pneumonia in the acquired immunodeficiency syndrome. *N Engl J Med*. 1990;323(21):1444-1450.
 21. Waxman JE, Spector JG, Sale SR, et al. Allergic aspergillus sinusitis: concepts in diagnosis and treatment of a new clinical entity. *Laryngoscope*. 1987;97(3):261-266.
 22. Limper AH, Knox KS, Sarosi GA, et al. An official American Thoracic Society statement: treatment of fungal infections in adult pulmonary and critical care patients. *Am J Respir Crit Care Med*. 2011;183(1):96-128.
 23. Wheat LJ, Freifeld AG, Kleiman MB, et al. Clinical practice guidelines for the management of patients with histoplasmosis: 2007 update by the Infectious Diseases Society of America. *Clin Infect Dis*. 2007;45(7):807-825.
 24. Finn MJ, Stiles J, Krohne SG. Visual outcome in a group of dogs with ocular blastomycosis treated with systemic antifungals and systemic corticosteroids. *Vet Ophthalmol*. 2007;10(5):299-303.
 25. Lionakis MS, Kontoyiannis DP. Glucocorticoids and invasive fungal infections. *Lancet*. 2003;362(9398):1828-1838.
 26. Belvisi MG. Regulation of inflammatory cell function by corticosteroids. *Proc Am Thorac Soc*. 2004;1(3):207-214.
 27. Altman LC, Hill JS, Hairfield WM, Mullarkey MF. Effects of corticosteroids on eosinophil chemotaxis and adherence. *J Clin Invest*. 1981;67(1):28-36.

How to cite this article: Reagan KL, Marks SL, Pesavento PA, Della Maggiore A, Zhu BY, Grooters AM. Successful management of 3 dogs with colonic pythiosis using itraconazole, terbinafine, and prednisone. *J Vet Intern Med*. 2019;33:1434-1439. <https://doi.org/10.1111/jvim.15506>