

[Orthopaedics]

All-Inside Meniscal Repair

Kimberly A. Turman,* MD, David R. Diduch, MD, and Mark D. Miller, MD

All-inside meniscal repair has gained widespread popularity over recent years. The devices and techniques have rapidly evolved, resulting in increased ease of use and reduced surgical times and risk to the neurovascular structures. Despite these advances, inside-out suture repairs remain the current gold standard, with proven long-term results. All-inside techniques must continue to be compared to inside-out meniscal repair.

Keywords: meniscus tear; meniscal repair; knee injury

Meniscal repair has become a commonly performed procedure, particularly with the advent of all-inside meniscal repair devices and techniques. The meniscus contributes many key functions to the knee joint, including joint stability,³⁴ shock absorption and load transmission,¹⁴ proprioception,¹⁷ and articular cartilage nutrition.²¹ The long-term consequences of total meniscectomy include the predictable development of degenerative changes in the joint.^{2,3,15,20} The meniscus should therefore be preserved whenever possible.

The concept of meniscal repair was first described by Annandale in 1885.⁵ Meniscal repair techniques have evolved over time, and they include open, outside-in, inside-out, and all-inside repairs. The gold standard currently remains inside-out vertical mattress suture repairs. Success rates with inside-out techniques average 60% to 80% for isolated meniscal repairs and 90% in the setting of concurrent anterior cruciate ligament (ACL) reconstruction owing to the enhanced healing environment.^{13,47} All-inside techniques have been developed to reduce surgical time, technical difficulty, and risk to neurovascular structures. Despite their popularity, all-inside meniscal repairs must continue to be compared to inside-out repairs.

INDICATIONS FOR MENISCAL REPAIR

Not all meniscus tears are amenable to repair, and several factors must be considered to determine repair suitability and healing potential. Repair suitability is often determined during arthroscopy.

Meniscal tissue is relatively avascular. Only the peripheral 10% to 30% of the meniscus is vascularized, supplied by the

medial and lateral genicular arteries⁶; the remaining meniscus must receive its nutrition through synovial fluid diffusion. The popliteal hiatus also creates a relatively hypovascular area in the posterior horn of the lateral meniscus. DeHaven¹⁶ classified tears in the peripheral 3 mm as *vascular* (also referred to as the red-red zone), tears greater than 5 mm from the meniscocapsular junction as *avascular* (white-white zone), and tears in between as *variable* (red-white zone). Based on the blood supply pattern, tears in the vascular periphery of the meniscus have the best ability to heal, whereas tears in the central white-white zone demonstrate poorer healing rates and are less amenable to repair.^{16,28}

Meniscal tear orientation and complexity must be considered in addition to location. Longitudinal vertical tears, bucket handle tears, and meniscocapsular separations are most amenable to repair. Conversely, complex tears may be better managed with partial meniscectomy. These tears include degenerative tears, radial tears, and tears with horizontal cleavage planes or multiple flaps.⁴³ Oblique, undersurface tears can also be problematic because they often extend from the vascular zone to avascular zone.

It is well known that meniscal repair has a higher success rate when performed in conjunction with ACL reconstruction, an important fact to consider when reviewing the literature. Furthermore, meniscal healing rates are typically lower in an ACL-deficient knee,²⁶ and repair may be contraindicated if the ACL is not also reconstructed.

Older patients with chronic degenerative tears are better served with partial meniscectomy. Meniscal repair also requires a patient to willingly comply with a prolonged rehabilitation course, as opposed to resection.

From the University of Virginia, Charlottesville, Virginia

*Address correspondence to Kimberly A. Turman, MD, University of Virginia, 400 Ray C. Hunt Drive, Suite 330, Charlottesville, VA 22908-0159 (e-mail: turmanka@gmail.com).

No potential conflict of interest declared.

DOI: 10.1177/1941738109334219

© 2009 The Author(s)

ALL-INSIDE MENISCAL REPAIR TECHNIQUES

Standard inside-out suture repairs remain the gold standard against which other techniques are compared. All-inside repairs have, however, benefited from improvements in device and technique since their introduction (in 1991) and, as a result, are growing in popularity (Figure 1). An intact meniscal rim is required as an anchor for repair devices; therefore, meniscocapsular separations are preferentially repaired with an alternate technique. Anterior horn tears are also a relative contraindication due to difficulty in access and may be better managed with outside-in suture techniques.

First-Generation All-Inside Repairs

The first generation of all-inside repairs was described by Morgan³⁸ in 1991 and used curved suture hooks through accessory posterior portals to pass sutures across the tear. Sutures were then retrieved and tied arthroscopically. The technique was technically demanding, and it continued to place the neurovascular structures at risk. It was subsequently abandoned with the development of second-generation repairs.

Second-Generation All-Inside Repairs

The second generation of all-inside meniscal repairs introduced the concept of technique-specific devices placed across the tear and anchored peripherally. The prototype of this generation was the T-Fix (Smith & Nephew, Andover, Massachusetts), which consisted of a polyethylene bar with an attached No. 2-0 braided polyester suture, deployed through a sharp needle or cannula to capture the peripheral meniscus or capsule. Adjacent sutures were then secured with arthroscopic knots pushed onto the meniscal surface. Meniscal repair was now achievable through the standard anterior arthroscopic portals without the need for accessory incisions and with minimal risk to neurovascular structures when performed properly. The device confirmed that it was possible and safe to repair the meniscus by deploying an anchor across the tear and into the periphery of the meniscus and capsule. However, the technical drawbacks of the device were the need for arthroscopic knots with potential chondral abrasion and the inability to tension the knots after placement.

Early results were encouraging, with short-term success rates of 80% to 90%.^{9,19} Despite the early results, the desire for a simpler device with improved compression across the meniscal repair led to the development of third-generation devices.

Third-Generation All-Inside Repairs

The third generation consisted of an explosion of bioabsorbable meniscal repair devices, including arrows, screws, darts, and staples. Most of these devices were composed of the rigid poly-L-lactic-acid (PLLA), which retains its strength for up to 12 months and requires 2 to 3 years or more to completely resorb. The most commonly used device was the Meniscal Arrow

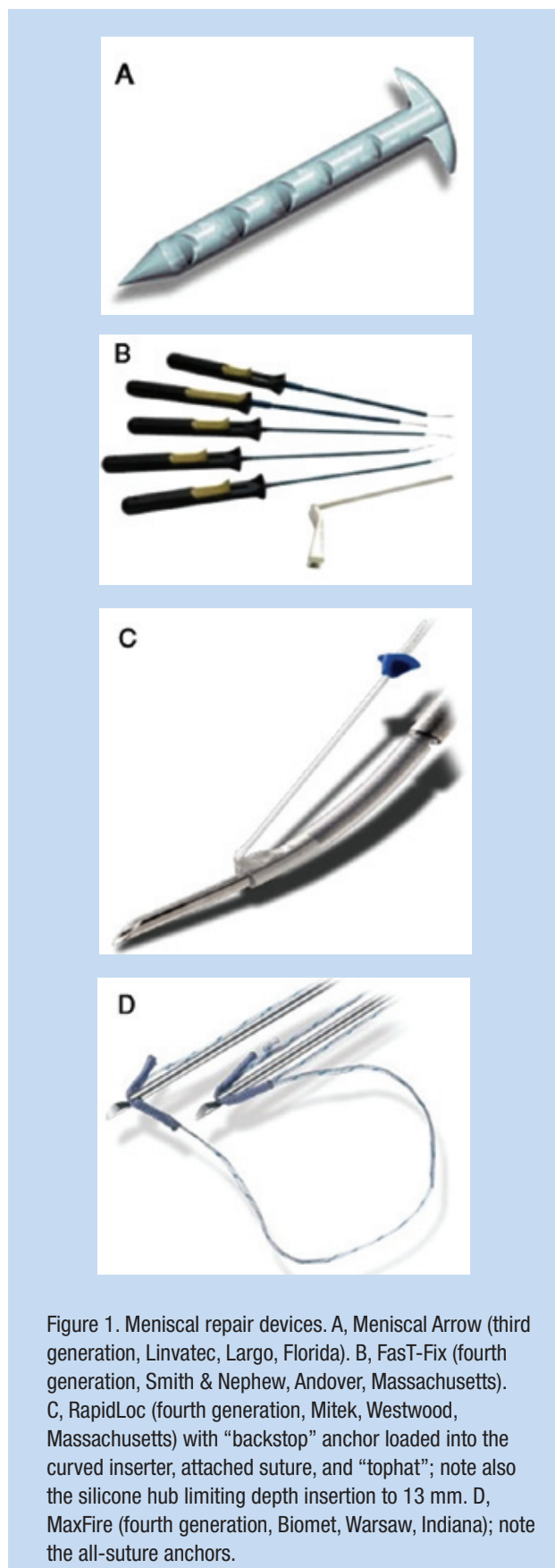


Figure 1. Meniscal repair devices. A, Meniscal Arrow (third generation, Linvatec, Largo, Florida). B, FasT-Fix (fourth generation, Smith & Nephew, Andover, Massachusetts). C, RapidLoc (fourth generation, Mitek, Westwood, Massachusetts) with “backstop” anchor loaded into the curved inserter, attached suture, and “tophat”; note also the silicone hub limiting depth insertion to 13 mm. D, MaxFire (fourth generation, Biomet, Warsaw, Indiana); note the all-suture anchors.

(Linvatec, Largo, Florida) because of its ease of insertion and early success rates. The current version of the meniscal arrow (Contour Meniscus Arrow) has a low-profile head and is barbed along the entire length of the implant shaft to improve fixation strength (Figure 1A). It is composed of a faster-resorbing self-reinforced copolymer 80L/20D,L PLA, which retains its strength for up to 24 weeks and then gradually resorbs. When seating the arrow across the meniscal tear, one must embed the head of the arrow into the meniscus to reduce the risk of chondral damage.

One prospective randomized study used second-look arthroscopy to determine healing rates of 91% (with the arrow) and 75% (with horizontal mattress suture repairs).¹ Our clinical experience with the meniscal arrow revealed a 90.6% success rate at 2 years in patients undergoing concurrent ACL reconstruction.²⁴ However, these results significantly deteriorated at longer-term follow-up, with a success rate of only 71.4% at 6 years in the same group of patients.³³ Other studies have documented similar deterioration of results.^{18,44} Kurzweil and colleagues reported an overall failure rate of 28% with the meniscus arrow, at average follow-up of 54 months.³² Furthermore, in isolated meniscal repairs without concurrent ACL reconstruction, the failure rate was a striking 42%. Yet another study reported a failure rate of 41% at 4.7 years.²³

Numerous device-specific complications have also been reported with the meniscal arrow, including transient synovitis, inflammatory reaction, cyst formation, device failure, device migration, and chondral damage.¹ Chondral damage is a potential complication with any of the rigid third-generation devices (Figure 2). If these devices are placed too proud or if they loosen or migrate before dissolving, significant chondral damage can result, often consisting of grooving of the adjacent femoral condyle.³² Because of the deterioration of results and numerous complications, the rigid third-generation devices have generally fallen out of favor.

Fourth-Generation All-Inside Repairs

The concerns discussed above, combined with the lack of adjustable tensioning, led to the development of the fourth and current generation of all-inside meniscal repair devices. These devices are flexible, suture based, and lower profile, and they allow for variable compression and retensioning across the meniscal tear. The 2 prototypical devices currently available include the FasT-Fix (Smith & Nephew) and the RapidLoc (Mitek, Westwood, Massachusetts).

The FasT-Fix is composed of 2 suture anchors (5 mm) connected by a No. 0 nonabsorbable polyester suture with a pretied slip knot (Figure 1B). A newer version of the FasT-Fix (FasT-Fix AB) is available with absorbable PLLA anchors. A depth-limiting sleeve on the inserter may be precut to any desired length, with 12 to 13 mm generally considered a sufficient length and safe in proximity to the neurovascular structures.³⁷ The curved or straight inserter, with both anchors loaded, is introduced into

¹References 4, 12, 27, 30, 35, 39, 40, 42, 45, 46

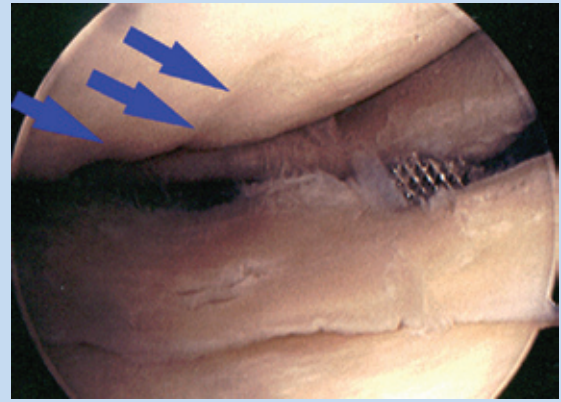


Figure 2. Chondral damage secondary to meniscal arrows. Note the grooving of the femoral condyle and lack of meniscal healing after the arrows were removed.

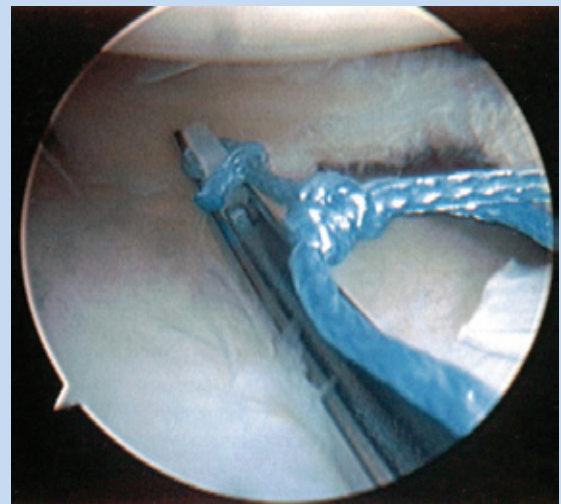


Figure 3. FasT-Fix meniscal repair device. The needle inserter, with both anchors loaded, is in position for the first pass across the meniscus tear.

the joint and advanced across the tear (Figure 3). After deploying the first anchor, the needle inserter is withdrawn from the meniscus but maintained in the joint. The second anchor is advanced to the tip of the inserter, which is then advanced across the meniscus a second time and deployed. The anchors and resultant suture bridge may be placed in a vertical or horizontal mattress configuration, simulating inside-out suture repairs. The pretied slip knot is advanced with a push-pull technique to apply variable compression across the tear. The suture is then cut; alternatively, it may be left in place until all devices are placed to allow for retensioning.

One of the primary advantages of the FasT-Fix is the ability to place a suture-based device in vertical mattress configuration. Unfortunately, the device can be difficult to place posteriorly; it can also misfire, break, and get tangled.³⁷

Compared to the FasT-Fix, the RapidLoc provides even greater ease of insertion. It is composed of a smaller absorbable “backstop” anchor connected to a “tophat” by a No. 2-0 absorbable or nonabsorbable suture (Figure 1C). The tophat was originally composed of PLLA but is now available in polydioxanone (PDS) in efforts to further reduce the risk of chondral damage, given that it resorbs more rapidly (3 to 6 months versus 2 years or greater with PLLA). The device is available with a 0°, 12°, or 27° curved inserter, which is introduced into the joint and across the meniscal tear in a single pass. A silicone hub on the inserter limits the insertion depth to 13 mm. The anchor is deployed and the inserter is removed. The pre-tied slip knot and tophat are advanced into position with a knot pusher to provide variable compression against the backstop anchor. The tophat should dimple the meniscal surface (Figure 4).

Again, sutures may be cut at the time of placement or after all devices have been placed to allow for retensioning if desired. While the RapidLoc is expedient and less technically demanding than the FasT-Fix, it does not allow for vertical mattress–based repair.

Biomechanical studies have demonstrated favorable results with both these devices. Strength and load-to-failure characteristics were reported to be not only comparable to mattress suture constructs, but also significantly better than earlier-generation devices.^{8,11} A more recent study demonstrated improved strength in load to failure with vertical FasT-Fix constructs (125 N), as compared to horizontal FasT-Fix constructs (90 N) and the RapidLoc (87 N); the vertical FasT-Fix also displayed less displacement with cyclic loading (3.2 mm versus 4.4 mm and 4.6 mm, respectively).³¹ Slightly overtightening the construct at the time of insertion is recommended because some displacement or loosening is expected with all these devices and sutures.

CLINICAL RESULTS

A prospective study of 42 meniscal tears repaired with the FasT-Fix with 2-year follow-up revealed success rates of 91% and 80% in patients with and without concurrent ACL reconstruction, respectively.²⁵ No complications were reported. At the time of the second-look arthroscopy in 8 knees, the sutures were noted to be nearly or completely incorporated into the meniscal tissue, and no chondral damage was documented.

A similar clinical study of the PLLA RapidLoc reviewed 54 meniscal repairs in the setting of concurrent ACL reconstruction with mean follow-up of 3 years. Results displayed a 90.7% success rate, similar to that of the equivalent group in the FasT-Fix study, as well as that of inside-out suture repairs.⁴¹ Second-look arthroscopies in this group also revealed healing and incorporation of the tophat into the meniscal tissue, with lack

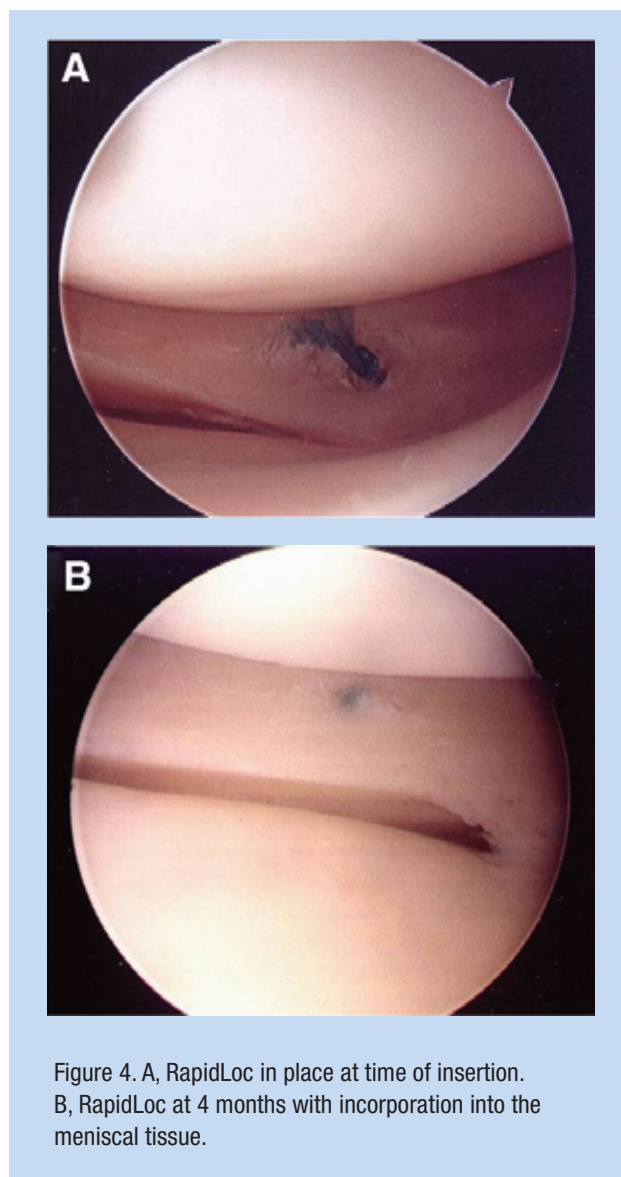


Figure 4. A, RapidLoc in place at time of insertion. B, RapidLoc at 4 months with incorporation into the meniscal tissue.

of chondral abrasion. Predictors for failure included bucket handle tears, tears greater than 2 cm long, multiplanar morphology, and chronic tears >3 months from injury. A subsequent study, with the more rapidly absorbing polydioxanone RapidLoc, revealed a similar clinical success rate (86.8%) in the setting of concurrent ACL reconstruction.¹⁰ Again, no chondral damage was evident in patients undergoing repeat arthroscopy.

Cadaveric studies have been performed to study the potential complications associated with insertion of these devices. In a study of the FasT-Fix, only 27 of 45 experimentally placed anchors were determined to be ideally positioned.³⁷ The preset inserter length of 22 mm resulted in penetration of the collateral ligaments, iliotibial tract, and skin. The recommendation based on these results was to trim the optional depth limiter to no longer than 15 mm to avoid potential entrapments and neurovascular injury.

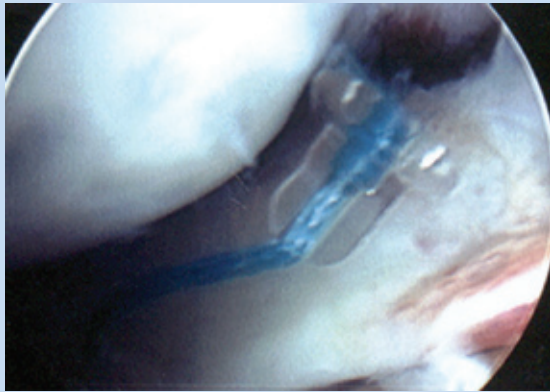


Figure 5. Loose intra-articular RapidLoc anchor.

A similar cadaveric study of the RapidLoc evaluated the placement of 48 devices.³⁶ Greater than 80% of devices were correctly positioned, and no cartilage or vascular injuries were documented. Entrapment of the popliteus tendon and superficial medial collateral ligament by the backstop anchors were the only potential complications encountered. These findings are also common with suture techniques and are of doubtful clinical significance.

The MaxFire meniscal repair device (Biomet, Warsaw, Indiana) has recently been released to the market. This is an all-suture knotless device that also allows tensioning of the repair. Two all-suture anchors are preloaded on needle inserters and may be placed in horizontal or vertical mattress configuration (Figure 1D). Clinical results are lacking.

Despite the advances of these fourth-generation devices, they are not without complications (Figure 5). Device misfires and breakage are possible, as discussed above. Chondral damage as a result of a prominent device (tophat or suture knot) may still occur, although it is much less likely than with the rigid meniscal arrow. Iatrogenic chondral damage is also a potential complication at the time of insertion if precise technique is not used. Soft tissue penetration and entrapments are also possible but less common with the use of the appropriate depth-limiting devices, as mentioned above.

ADJUNCTS TO MENISCAL REPAIR

Regardless of the meniscal repair technique chosen, several adjuncts may be used to enhance meniscal healing. First, meniscal/synovial rasping is routinely used to stimulate enhanced blood supply and so generate a healing response. Less common, trephination may be used to improve short-term vascular access to the red-white zone of the meniscus.²² Last, exogenous fibrin clot may be useful in the setting of isolated meniscal repair.^{7,43} Fibrin clot enhances the local healing environment by placing factors found in the peripheral blood, such as growth factors, fibrin, and platelets, at the site of repair (Figure 6). This produces a healing milieu similar to the

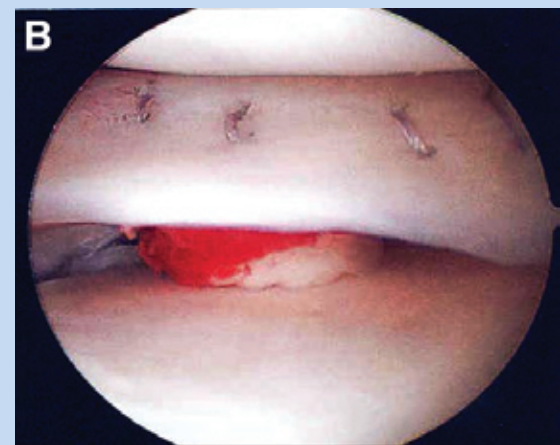
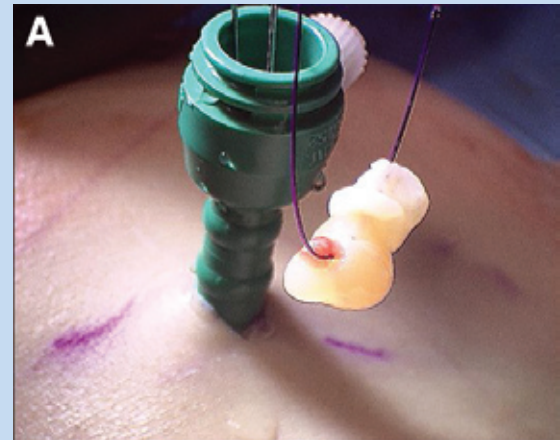


Figure 6. Inside-out meniscal repair supplemented with exogenous fibrin clot. A, the fibrin clot is prepared and delivered into the knee via a cannula. B, fibrin clot in place, inferior to the meniscus, with several vertical mattress sutures in place.

setting of concurrent ACL reconstruction. One study documented a 41% failure rate in isolated meniscal repairs without the addition of exogenous fibrin clot versus an 8% failure rate with its use.²⁹

DISCUSSION

Because preservation of meniscal tissue is the ultimate goal, there is a tremendous need for safe and effective meniscal repair techniques. It is critically important, however, to assess meniscal tears for repair suitability because not all tears can or should be repaired. Characteristics of both the meniscal tear and the patient must be considered. The final determination of partial meniscectomy versus repair and method of repair is frequently made at the time of arthroscopy. The surgeon must therefore be prepared for several options.



Clinical Recommendations

SORT: Strength of Recommendation Taxonomy

A: consistent, good-quality patient-oriented evidence

B: inconsistent or limited-quality patient-oriented evidence

C: consensus, disease-oriented evidence, usual practice, expert opinion, or case series

Clinical Recommendations

SORT Evidence Rating

All-inside meniscal repairs are an effective means to address amenable tears. They may be best suited to meniscal repairs in the setting of concurrent anterior cruciate ligament reconstruction where the healing environment is optimized. Inside-out meniscal repairs remain the gold standard for isolated meniscus tears.

A

For more information about the SORT evidence rating system, see www.aafp.org/afpsort.xml and Ebell MH, Siwek J, Weiss BD, et al. Strength of Recommendation Taxonomy (SORT): a patient-centered approach to grading evidence in the medical literature. *Am Fam Physician.* 2004;69:549-557.

All-inside techniques should be reserved for cases where the healing environment is optimal, such as in the setting of concurrent ACL reconstruction. Hybrid meniscal repairs may be indicated in bucket handle tears, with all-inside devices used in the far posterior aspect of the tear where neurovascular risk is increased and with inside-out sutures used for the body of the tear. This hybrid approach may also be an effective fixation strategy for meniscal transplantation.

Isolated meniscus tears are otherwise best managed with inside-out sutures, given that the current literature has yet to document equivalent success with all-inside repairs in this setting. Potential contraindications to all-inside repairs are meniscocapsular separations (which lack an intact meniscal rim to anchor the device) and anterior horn tears (which are difficult to access). Long-term studies of the fourth-generation all-inside devices and direct comparative studies in the setting of isolated meniscal repairs are needed. In the interim, inside-out vertical mattress sutures remain the gold standard for meniscal repair.

REFERENCES

- Albrecht-Olsen P, Kristensen G, Burgaard P, Joergensen U, Toerholm C. The arrow versus horizontal suture in arthroscopic meniscus repair: a prospective randomized study with arthroscopic evaluation. *Knee Surg Sports Traumatol Arthrosc.* 1999;7:268-273.
- Alford JW, Lewis P, Kang RW, et al. Rapid progression of chondral disease in the lateral compartment of the knee following meniscectomy. *Arthroscopy.* 2005;21:1505-1509.
- Allen PR, Denham RA, Swan AV. Late degenerative changes after meniscectomy: factors affecting the knee after operation. *J Bone Joint Surg Br.* 1984;66:666-671.
- Anderson K, Marx RG, Hannafin J, Warren RF. Chondral injury following meniscal repair with a biodegradable implant. *Arthroscopy.* 2000;16:749-753.
- Annandale T. An operation for displaced semilunar cartilage. *Br Med J.* 1885;1:779.
- Arnoczky SP, Warren RF. The microvasculature of the human meniscus. *Am J Sports Med.* 1982;10:90-95.
- Arnoczky SP, Warren RF, Spivak JM. Meniscal repair using an exogenous fibrin clot: an experimental study in dogs. *J Bone Joint Surg Am.* 1988;70:1209-1217.
- Barber FA, Herbert MA, Richards DP. Load to failure testing of new meniscal repair devices. *Arthroscopy.* 2004;20:45-50.
- Barrett GR, Treacy SH, Ruff CG. Preliminary results of the T-fix endoscopic meniscus repair technique in an anterior cruciate ligament reconstruction population. *Arthroscopy.* 1997;13:218-223.
- Billante MJ, Diduch DR, Lunardini DJ, Treme, GP, Miller MD, Hart JM. Meniscal repair using an all-inside, rapidly absorbing, tensionable device. *Arthroscopy.* 2008;24:779-785.
- Borden P, Nyland J, Caborn DN, Pienkowski D. Biomechanical comparison of the FaST-Fix meniscal repair suture system with vertical mattress sutures and meniscus arrows. *Am J Sports Med.* 2003;31:374-378.
- Calder SJ, Myers PT. Broken arrow: a complication of meniscal repair. *Arthroscopy.* 1999;15:651-652.
- Cannon WJ, Vittori J. The incidence of healing in arthroscopic meniscal repairs in anterior cruciate ligament-reconstructed knees versus stable knees. *Am J Sports Med.* 1992;20:176-181.
- Cole BJ, Carter TR, Rodeo SA. Allograft meniscal transplantation: background, techniques, and results. *J Bone Joint Surg Am.* 2002;84:1236-1250.
- Cox JS, Nye CE, Schaefer WW, et al. The degenerative effects of partial and total resection of the medial meniscus in dog's knees. *Clin Orthop Relat Res.* 1975;109:178-183.
- DeHaven KE. Decision-making factors in the treatment of meniscal lesions. *Clin Orthop Relat Res.* 1990;252:49-54.
- Dye SF, Vaupel GL, Dye CC. Conscious neurosensory mapping of the internal structures of the human knee without intraarticular anesthesia. *Am J Sports Med.* 1998;26:773-777.
- Ellermann A, Siebold R, Buelow JU, Sobau C. Clinical evaluation of meniscus repair with bioabsorbable arrow: a 2- to 3-year follow-up study. *Knee Surg Sports Traumatol Arthrosc.* 2002;10:289-293.
- Escalas F, Quadras J, Caceres E, Benaddi J. T-Fix anchor sutures for arthroscopic meniscal repair. *Knee Surg Sports Traumatol Arthrosc.* 1997;5:72-76.
- Fairbank TJ. Knee joint changes after meniscectomy. *J Bone Joint Surg Br.* 1948;30:664-670.
- Fithian DC, Kelly MA, Mow VC. Material properties and structure-function relationship in the menisci. *Clin Orthop Relat Res.* 1990;25:19-31.
- Fox JM, Rintz KG, Ferrel RD. Trephination of incomplete meniscal tears. *Arthroscopy.* 1993;9:451-455.
- Gifstad T, Grontvedt T, Drogset JO. Meniscal repair with biofix arrows: results after 4.7 years' follow-up. *Am J Sports Med.* 2007;35:71-74.
- Gill SS, Diduch DR. Outcomes after meniscal repair using the meniscus arrow in knees undergoing concurrent anterior cruciate ligament reconstruction. *Arthroscopy.* 2002;18:569-577.
- Haas AL, Schepesis AA, Hornstein J, Edgar CM. Meniscal repair using the FaST-Fix all-inside meniscal repair device. *Arthroscopy.* 2005;21:167-75.
- Hanks GA, Gause TM, Handal JA, Kalenak A. Meniscus repair in the anterior cruciate deficient knee. *Am J Sports Med.* 1990;18:606-611.

27. Hechtman KS, Uribe JW. Cystic hematoma formation following use of a bio-degradable arrow for meniscal repair. *Arthroscopy*. 1999;15:207-210.
28. Henning CE, Lynch MA, Clark JR. Vascularity for healing of meniscus repairs. *Arthroscopy*. 1987;3:13-18.
29. Henning CE, Lynch MA, Yearout KM, et al. Arthroscopic meniscal repair using an exogenous fibrin clot. *Clin Orthop Relat Res*. 1990;252:64-72.
30. Jones HP, Lemos MJ, Wilk RM, Smiley PM, Gutierrez R, Schepsis AA. Two-year follow-up of meniscal repair using a bioabsorbable arrow. *Arthroscopy*. 2002;18:64-69.
31. Kocabey Y, Chang HC, Brand JC, Nawab A, Nyland J, Caborn DNM. A biomechanical comparison of the FasT-Fix meniscal repair suture system and the RapidLoc device in cadaver meniscus. *Arthroscopy*. 2006;22:406-413.
32. Kurzweil PR, Tifford CD, Ignacio EM. Unsatisfactory clinical results of meniscal repair using the meniscus arrow. *Arthroscopy*. 2005;21:905.e1-905.e7.
33. Lee GP, Diduch DR. Deteriorating outcomes after meniscal repair using the meniscus arrow in knees undergoing concurrent anterior cruciate ligament reconstruction: increased failure rate with long-term follow-up. *Am J Sports Med*. 2005;33:1138-1141.
34. Levy IM, Torzilli PA, Gould JUD, et al. The effect of medial meniscectomy on anterior-posterior motion of the knee. *J Bone Joint Surg Am*. 1982;64:883-888.
35. Menche DS, Phillips GI, Pitman MI, Steiner GC. Inflammatory foreign-body reaction to an arthroscopic bioabsorbable meniscal arrow repair. *Arthroscopy*. 1999;15:770-772.
36. Miller MD, Blessey PB, Chhabra A, Kline AJ, Diduch DR. Meniscal repair with the Rapid Loc device: a cadaveric study. *J Knee Surg*. 2003;16:79-82.
37. Miller MD, Kline AJ, Gonzales J, Beach WR. Pitfalls associated with FasT-Fix meniscal repair. *Arthroscopy*. 2002;18:939-943.
38. Morgan CD. The "all-inside" meniscal repair. *Arthroscopy*. 1991;7:120-125.
39. Oliverson TJ, Lintner DM. Biofix arrow appearing as a subcutaneous foreign body. *Arthroscopy*. 2000;16:652-655.
40. Otte S, Klinger HM, Beyer J, Baums MH. Complications after meniscal repair with bioabsorbable arrows: two cases and analysis of literature. *Knee Surg Sports Traumatol Arthrosc*. 2002;10:250-253.
41. Quinby JS, Golish SR, Hart JA, Diduch DR. All-inside meniscal repair using a new flexible, tensionable device. *Am J Sports Med*. 2006;34:1281-1286.
42. Ross G, Grabill J, McDevitt E. Chondral injury after meniscal repair with bioabsorbable arrows. *Arthroscopy*. 2000;16:754-756.
43. Schmitz MA, Rouse LM Jr, DeHaven KE. The management of meniscal tears in the ACL-deficient knee. *Clin Sports Med*. 1996;15:573-593.
44. Siebold R, Dehler C, Boes L, Ellermann A. Arthroscopic all-inside repair using the meniscus arrow: long-term clinical follow-up of 113 patients. *Arthroscopy*. 2007;23:394-399.
45. Song EK, Lee KB, Yoon TR. Aseptic synovitis after meniscal repair using the biodegradable meniscus arrow. *Arthroscopy*. 2001;17:77-80.
46. Tingstad EM, Teitz CC, Simonian PT. Complications associated with the use of meniscal arrows. *Am J Sports Med*. 2001;29:96-98.
47. Warren RF. Meniscectomy and repair in the anterior cruciate ligament-deficient patient. *Clin Orthop Relat Res*. 1990;252:55-63.

For reprints and permissions queries, please visit SAGE's Web site at <http://www.sagepub.com/journalsPermissions.nav>.