

Received: 2016.05.14  
Accepted: 2016.08.04  
Published: 2017.04.25

# Efficacy and Safety of 3 Nasal Packing Materials Used After Functional Endoscopic Sinus Surgery for Chronic Rhinosinusitis: A Comparative Study in China

Authors' Contribution:  
Study Design A  
Data Collection B  
Statistical Analysis C  
Data Interpretation D  
Manuscript Preparation E  
Literature Search F  
Funds Collection G

ACDEF 1,2 **Xi-Ling Zheng**  
ABCDE 3 **Yu-Xiang Zhao**  
ABCDEF 4 **Min Xu**

1 Department of Otorhinolaryngology, Medical School of Xi'an Jiaotong University, Xi'an, Shaanxi, P.R. China  
2 Department of Otorhinolaryngology, The Affiliated Hospital of Yan'an University, Yan'an, Shaanxi, P.R. China  
3 Department of Otorhinolaryngology, Shaanxi Provincial People's Hospital, Xi'an, Shaanxi, P.R. China  
4 Department of Otolaryngology-Head and Neck Surgery, The Second Affiliated Hospital of Xi'an Jiaotong University, Xi'an, Shaanxi, P.R. China

**Corresponding Author:** Min Xu, e-mail: ent551205@163.com  
**Source of support:** Departmental sources

**Background:** This study aimed to investigate the efficacy and safety of 3 nasal packing products (silicone tube, Beschitin-F, and Aquacel1-Ag) after functional endoscopic sinus surgery (FESS) for chronic rhinosinusitis (CRS) patients in China.

**Material/Methods:** Sixty-six CRS patients undergoing FESS surgery were randomly divided into 3 groups (22 patients in each group): the silicone tube group, the Beschitin-F group, and the Aquacel1-Ag group. Postoperative headache, nasal pain, nasal bleeding, and swelling of the nasal mucosa were observed at 1 month after FESS surgery. Bacteriology of chronic rhinosinusitis was conducted by culturing the removed nasal packing.

**Results:** The VAS scores of nasal pain in the silicone tube group were lower than in the Beschitin-F and the Aquacel1-Ag groups. The volume of nasal bleeding in the Beschitin-F group was higher than in the silicone tube and Aquacel1-Ag groups. The adhesion rate of the nasal cavity in the Beschitin-F1 group (2/22, 9.1%) was also higher than in the silicone tube group (0/22, 0%) and the Aquacel1-Ag group (0/22, 0%). The results of bacterial culture from removed nasal packing showed that coagulase-negative staphylococci (CNS) was more frequent in the silicone tube group than in the Beschitin-F and Aquacel1-Ag groups, but *Streptococcus pneumonia*, *Haemophilus influenza*, and Gram-negative rods were more common in the Aquacel1-Ag group than in the silicone tube and Beschitin-F groups.

**Conclusions:** These results indicate that the silicone tube may be more effective and safe than Beschitin-F and Aquacel1-Ag as nasal packing after FES surgery for CRS.

**MeSH Keywords:** Endoscopy • Materials Testing • Silicone Gels

**Full-text PDF:** <http://www.medscimonit.com/abstract/index/idArt/899553>



2565



2



3



23



## Background

Chronic rhinosinusitis (CRS) is a common disease of the nose and usually is caused by purulent sinus infection. According to data from the 2008 National Health Interview Survey, CRS was reported to affect about 1 in 7 adults [1]. Functional endoscopic sinus surgery (FESS) is currently regarded as the most effective surgical treatments for CRS, as it is simple and minimally invasive. However, this procedure is often associated with complications, including nasal bleeding, adhesions, and stenosis, which could be prevented by nasal packing [2]. However, the various nasal packing products are often lacking in efficacy in wound-healing and hemostatic effects. The insertion and removal of the nasal packing is also painful for the patient [3].

As advances in biotechnology have been made, a variety of new biomaterials have been used for FESS nasal packing, such as chitosan scaffolds and dressing with absorbent silver ions [4]. Beschitin-F (chitin-coated gauze) is a chitosan-based material that was developed by the UNITIKA Company in Japan. It has hemostatic effects and promotes the healing of skin wounds [3]. A previous study has shown that Beschitin-F is an excellent nasal filler material for mucous membrane irritation in nasal packing [5]. Aquacel1-Ag, which contains carboxy methyl cellulose (CMC) and silver, is a silver dressing that was developed by the British Convatec Company [6]. It is an excellent material with both antibacterial and wound healing capabilities that can greatly improve the success rate and shorten recovery time [7]. With good elasticity and no irritation, medical silicone tubes can ensure better nasal ventilator capacity and effective mucosal blood flow, as well as a reduction in discomfort for patients [8]. In the present study, we investigated the efficacy and safety of 3 nasal packing materials (silicone tube, Beschitin-F, and Aquacel1-Ag) after FESS for CRS patients.

## Material and Methods

### Study subjects

From August 2014 to February 2015, 66 CRS patients undergoing bilateral FESS surgery were selected from the ENT Department of the Second Affiliated Hospital of Xi'an Jiaotong University. All patients conformed to the diagnostic criteria of CRS [9]. These CRS patients included 36 males and 30 females, with an average age of  $41.6 \pm 4.6$  years (range 22–76 years). All CRS patients were randomly divided into 3 groups (22 patients in each group): the silicone tube group, the Beschitin-F group, and the Aquacel1-Ag group. The enrollment criteria were: 1) no surgical contraindications; and 2) voluntarily agree to participate in the observations and follow-up programs. The exclusion criteria were: 1) teenagers, pregnant women, and lactating mothers; 2) patients who used other nasal packing; 3)

patients with disturbance of blood coagulation, including prothrombin time (PT)/partial thromboplastin time (PTT) prolongation, purpura, and spontaneous bleeding; 4) patients with severe heart, liver, and kidney dysfunction, or uncontrolled hypertension and diabetes; 5) patients with psychosis or language disorders; and 6) patients with incomplete assessments and suspended follow-up. This study was performed with the approval of the Ethics Committee of the Second Affiliated Hospital of Xi'an Jiaotong University. Informed consent was obtained from all patients in this study.

### Treatment regimens

All patients received FESS with local anesthesia combined with intravenous anesthesia. The processus uncinatus were resected under a nasal endoscope combined with monitoring screen, and the nasal polyp-like lesions were removed by electromotion. An arc incision was made in the inferior border of the processus uncinatus, and the processus uncinatus were separated and removed. According to the scope of the lesions, the anterior ethmoid sinus, the anterior and posterior ethmoid sinus, and sellar-type sphenoidal sinus were opened, and the openings of the antrum highmori, frontal sinuses, and sphenoid sinus were enlarged. Preservation of the ethmoid cornua was regarded as the principle goal during surgery, and absorbable hemostatic gauze was then used to cover the wound surface and the nasal packing was replaced.

In the silicone tube group, a silicone catheter, with the length of 2.5–3 cm, internal diameter of 0.6 cm, and external diameter of 0.8 cm, was implanted into the nasal cavity and fix-packed below with Vaseline gauze. In the Beschitin-F group, we used up to 2 layers of either Beschitin-F (Unitika, 30×2 cm) soaked in 100 mg of amikacin sulfate. In the Aquacel1-Ag group, Aquacel1-Ag (Convatec, 2×45 cm) were placed on both sides of the middle nasal meatus after FESS surgery. Cefazolin (2 g) was injected intravenously before the operation, followed by 300 mg of cefditoren pivoxil per day as a prophylactic antibiotic (until 5 days after the operation). The history of allergic rhinitis and asthma, preoperative peripheral blood eosinophil ratio (%), and preoperative CT scoring (Lund and Mackay scores) of CRS patients were recorded.

### Efficacy and safety evaluation

The visual analogue scale method (VAS) was applied to evaluate nasal pain of CRS patients at 1 day after FESS surgery. Nasal pain was assessed by assigning a score from 0 to 10 with 4 levels [6]: a score of 0 for no pain, a score of 1–4 for light pain, a score of 5–6 for moderate pain, and a score of 7 or more for intolerable pain.

**Table 1.** Comparisons of baseline characteristics of patients with chronic rhinosinusitis among the silicone tube, Beschitin-F and Aquacel1-Ag groups.

| Characteristics          | Silicone tube group<br>(n=22) | Beschitin-F1 group<br>(n=22) | Aquacel1-Ag group<br>(n=22) | P     |
|--------------------------|-------------------------------|------------------------------|-----------------------------|-------|
| Age (years)              | 41.9±15.7                     | 42.5±13.6                    | 43.1±14.2                   | 0.963 |
| Gender (female/male)     | 10/12                         | 13/9                         | 11/11                       | 0.654 |
| Nasal polyps (%)         | 6/16                          | 5/17                         | 5/17                        | 0.921 |
| Allergic rhinitis (%)    | 9 (40.9)                      | 9 (40.9)                     | 8 (36.4)                    | 0.938 |
| Asthma (%)               | 6 (27.3)                      | 5 (22.7)                     | 4 (18.2)                    | 0.772 |
| Eosinophil counts        | 5.9±2.6                       | 6.5±3.1                      | 5.8±4.3                     | 0.763 |
| CT-scores                | 14.5±3.9                      | 15.6±4.7                     | 14.2±3.8                    | 0.504 |
| Rhinorrhea (%)           | 18 (81.8)                     | 16 (72.7)                    | 20 (90.9)                   | 0.295 |
| Nasal obstruction (%)    | 20 (90.9)                     | 18 (81.8)                    | 16 (72.7)                   | 0.295 |
| Headache (%)             | 15 (68.2)                     | 13 (59.1)                    | 17 (77.3)                   | 0.432 |
| Hyposmia (%)             | 15 (68.2)                     | 18 (81.8)                    | 14 (63.6)                   | 0.383 |
| Prosopodynia (%)         | 13 (59.1)                     | 14 (63.6)                    | 15 (68.2)                   | 0.822 |
| Posterior nasal dripping | 13 (59.1)                     | 15 (68.2)                    | 16 (72.7)                   | 0.620 |

The nasal bleeding of CRS patients was observed at 4 days after removing nasal packing. Blood volume was calculated using the volume of gauze required for nasal hemostasis (each 10 cm of gauze absorbed approximately 1.5 ml of blood).

Callus formation in the middle nasal meatus and the adhesion of the nasal cavity were observed by nasal endoscopy. Plasma levels of C-reactive protein (CRP) and white blood cell (WBC) counts were measured to observe inflammatory response. Bacteriology of chronic rhinosinusitis was conducted by culturing the removed nasal packing.

The swelling of the nasal mucosa was observed at 1 month after FESS surgery and was divided into 3 grades: 1) mild grade: no obvious cavity reduction, spacious maxillary sinus, and no obvious vesicles and granulation growth; 2) moderate grade: obvious cavity reduction, mucosal edema of maxillary sinus, narrowing of the sinus orifice, with vesicles and granulation growth; and 3) severe grade: the middle turbinate exposed to the lateral wall of the nasal cavity, and a large amount of vesicles and granulation growth in the cavity.

### Statistical analysis

SPSS 19.0 software was used for statistical analysis. Count data are presented as frequency and percentage tables, and comparisons were performed by  $\chi^2$  test. Quantitative data are represented as the mean  $\pm$  standard deviation (SD) ( $\bar{x}\pm SD$ ) and

were analyzed by the independent samples *t* test and one-way analysis of variance (ANOVA). *P*<0.05 was considered statistically significant.

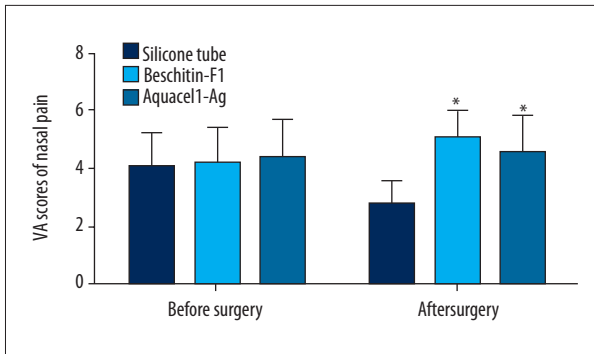
## Results

### Comparisons of baseline characteristics

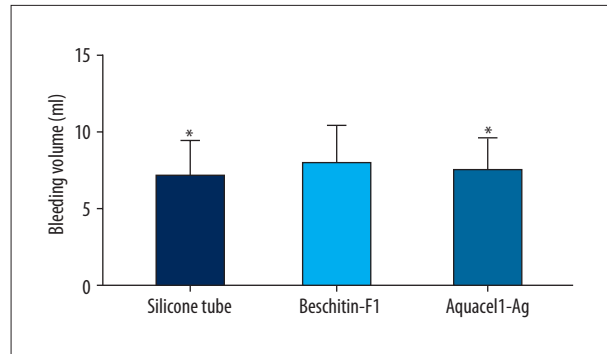
As shown in Table 1, there were no significant differences in age, sex, nasal polyps, history of allergic rhinitis, history of asthma, eosinophil counts, CT scores and clinical symptoms (rhinorrhea, nasal obstruction, headache, hyposmia, prosopodynia, and posterior nasal dripping) among the silicone tube, Beschitin-F, and Aquacel1-Ag groups (all *P*>0.05).

### VAS scores of nasal pain before and after FESS surgery

Before FESS surgery, the VAS scores of nasal pain were not significantly different among the 3 groups (all *P*>0.05) (Figure 1). At 1 day after FESS surgery, the VAS score of nasal pain in the silicone tube group was lower than that in the Beschitin-F and the Aquacel1-Ag groups (all *P*<0.05), but there was no significant difference in the VAS score between the Beschitin-F1 and Aquacel1-Ag groups (*P*>0.05).



**Figure 1.** The VAS scores of nasal pain of patients with chronic rhinosinusitis among the silicone tube, Beschitin-F, and Aquacel1-Ag groups before and after FESS surgery. VAS – visual analogue scale; FESS – functional endoscopic sinus surgery; \*  $P < 0.05$ , compared with the silicone tube group.



**Figure 2.** Postoperative nasal bleeding of patients with chronic rhinosinusitis among the silicone tube, Beschitin-F, and Aquacel1-Ag groups after FESS surgery. FESS – functional endoscopic sinus surgery; \*  $P < 0.05$  compared with the Beschitin-F1 group.

**Table 2.** Inflammatory response and nasal endoscopy examinations of patients with chronic rhinosinusitis among the silicone tube, Beschitin-F and Aquacel1-Ag groups after FESS surgery.

|  | Silicone tube group (n=22) | Beschitin-F1 group (n=22) | Aquacel1-Ag group (n=22) |
|--|----------------------------|---------------------------|--------------------------|
| Plasma CRP levels (mg/dL)                | 1.66±1.03                  | 1.58±0.08                 | 1.59±1.02                |
| WBC counts ( $\times 10^3/\mu\text{L}$ ) | 6.49±1.29                  | 6.41±1.31                 | 6.52±1.52                |
| Callus formation (weeks)                 | 4.2±0.9                    | 4.4±0.8                   | 4.3±0.7                  |
| Adhesion rate (%)                        | 0 (0.0)*                   | 2 (9.1)                   | 0 (0.0)*                 |
| Swelling of the nasal mucosa (%)         |                            |                           |                          |
| Mild grade                               | 11 (50.0)                  | 10 (45.5)                 | 13 (59.1)                |
| Moderate grade                           | 8 (36.4)                   | 10 (45.5)                 | 8 (36.4)                 |
| Severe grade                             | 3 (13.6)                   | 2 (9.1)                   | 1 (4.5)                  |

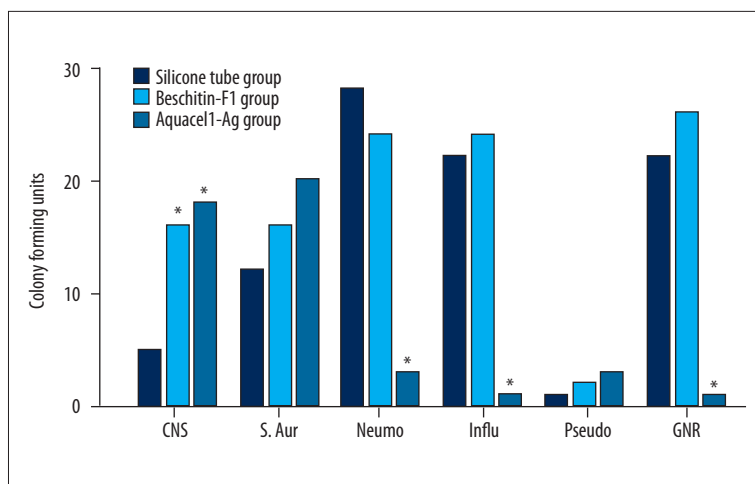
FESS – functional endoscopic sinus surgery; CRP – C-reactive protein; WBC – white blood cell; \*  $P < 0.05$  compared with the Beschitin-F1 group.

### Postoperative nasal bleeding, inflammatory response, and nasal endoscopy examinations after FESS surgery

The volume of nasal bleeding in the Beschitin-F group was higher than that in the silicone tube and Aquacel1-Ag groups (both  $P < 0.05$ ) (Figure 2). As shown in Table 2, there were no differences in plasma levels of CRP and WBC counts and callus formation in the middle nasal meatus among the 3 groups (all  $P > 0.05$ ). The adhesion rate of the nasal cavity in the Beschitin-F1 group (2/22, 9.1%) was also higher than that in the silicone tube group (0/22, 0%) and the Aquacel1-Ag group (0/22, 0%) (both  $P < 0.05$ ). However, no significant difference was observed in the swelling of the nasal mucosa among the 3 groups (all  $P > 0.05$ ).

### Bacterial culture from removed nasal packing

The results of bacterial culture from removed nasal packing showed that coagulase-negative staphylococci (CNS) was more frequent in the silicone tube group than in the Beschitin-F and Aquacel1-Ag groups (both  $P < 0.05$ ), but no difference was found between the Beschitin-F and Aquacel1-Ag groups ( $P > 0.05$ ) (Figure 3). Furthermore, *Streptococcus pneumoniae*, *Haemophilus influenzae*, and Gram-negative rods were more common in the Aquacel1-Ag group than in the silicone tube and Beschitin-F groups (all  $P < 0.05$ ), but the difference between the silicone tube and Beschitin-F1 groups was not statistically significant ( $P > 0.05$ ).



**Figure 3.** Bacterial culture from removed nasal packing of patients with chronic rhinosinusitis among the silicone tube, Beschitin-F, and Aquacel1-Ag groups after FESS surgery. CNS – Coagulase-negative staphylococci; S. Aur – *Staphylococcus aureus*; Neumo – *Streptococcus pneumoniae*; Influ – *Haemophilus influenzae*; Pseudo – *Pseudomonas aeruginosa*; GNR – Gram-negative rods, including *Enterobacter aerogenes*, *Prevotella melaninogenica*, *Escherichia coli*, and *Klebsiella pneumoniae*; \*  $P < 0.05$  compared with the silicone tube group.

## Discussion

The principal aims of postoperative nasal packing include control of postoperative nasal bleeding and promotion of wound healing. Previous studies have reported that postoperative nasal packing exerts a very strong influence on the comfort of the patient [10,11]. Our study focused on comparing the efficacy of 3 nasal packing materials (silicone tubing, Beschitin-F, and Aquacel1-Ag) and evaluating patient comfort, nasal mucosa swelling, nasal bleeding, and bacterial levels.

The results of this study showed that all 3 nasal packing materials had favorable hemostatic effects, and the hemostatic effect in the silicone tube and Aquacel1-Ag was better than in the Beschitin-F with good elasticity. The longer time of wound compression and wound healing might also lead to such a result. In our study, silicone tube, Beschitin-F1, and Aquacel1-Ag were removed at 4 days after FESS surgery, which allowed a longer time for nasal mucosa to heal. This may result in a less painful sensation and a less bleeding volume during the removal of nasal packing materials. Patient comfort was highest and CNS pathogen levels were lowest in the silicone tube group, and the highest patient comfort was confirmed by the fact that the silicone tube group had lower postoperative pain scores after the removal of the nasal packing compared with the Beschitin-F1 and Aquacel1-Ag groups. As mentioned earlier, the patient comfort was evaluated with pain and nasal obstruction, while the nasal obstruction scores for each group were not significantly different before FESS and after the nasal cavity filling material was removed. A previous study suggested that it was effective to implant silicone tubes in treating nasal obstruction and it had the merits of fewer complications, minimal invasion, and quicker recovery [12]. The different results might be caused by the small sample size of patients selected into our study, which might have biased the final results. Additionally, the effect of Vaseline gauze in the nose was not assessed in the silicone tube group because the silicone-filled

cavity after FESS surgery should be filled and fixed by Vaseline gauze due to the poor plasticity of silicone tube and gaps between the tube around and the surface of a wound. Therefore, the main function of Vaseline gauze is to fix the silicone-filled cavity, which has no obvious effect on the patient. However, the Beschitin-F1 group had a higher frequency of adhesions and infections. Medical silicone tubing, with good elasticity and compression capacity, and which is easy to obtain, can be fixed in the middle turbinate meatus after padding to avoid adhesion to the lateral nasal wall [8]. However, the silicone tube itself has poor plasticity, which makes it easy to produce joint space during the padding process. Therefore, the padding process requires the use of Vaseline-coated gauze, which is more difficult to work with [13]. Chitosan, a new natural macromolecule material that is non-toxic, biocompatible, and biodegradable, is used in clinical wound dressing to promote wound healing and prevent postoperative adhesions. Chitosan materials are capable of aggregation and adhesion to red blood cells and platelets. They also activate the coagulation pathway and accelerate the synthesis of fibrin adhesive [14]. Chitosan can induce the production of endothelin, causing vasoconstriction and final wound closure to stop bleeding [15]. The non-toxic and biodegradable characteristics of chitosan have facilitated the development of absorbable materials that require no postoperative removal, which greatly reduces the suffering of patients and simplifies the surgical procedure. Therefore, chitosan has applications for clinical research and development [16].

According to the results of this study, Aquacel1-Ag was more effective at increasing patient comfort and reducing mucosal swelling compared to the other groups. The bacterial levels of the Aquacel1-Ag group were also lower, which indicated that Aquacel1-Ag was effective in preventing postoperative bacterial infection and may be applicable for patients with immune dysfunction. The Aquacel1-Ag silver ion dressing, which has been widely used clinically, particularly for the treatment of intractable wounds, is composed of CMC with open grid services

architecture and has 1.2% silver content [8,17]. CMC's mechanism of action is characterized by wound exudate absorption that facilitates the formation of hydrogel to maintain proper temperature and humidity, while isolating the wound from outside sources of pollution and protecting exposed nerve endings to release pain [18]. The unique open grid services architecture of CMC allows it to impose negative pressure on wounds and thereby promote cell division and regeneration of the wounds. The Aquacel1-Ag wound dressing is capable of providing silver ions with antimicrobial activity to create a clean environment that promotes wound healing [19]. Compared to the other materials, Aquacel1-Ag shortens recovery times and thereby reduces the financial and emotional burdens on patients [7].

Our study also showed that the levels of CNS bacteria were remarkably lower in the silicone tube group than in the Beschitin-F1 and Aquacel1-Ag groups, and the Aquacel1-Ag group had significantly lower levels of *Streptococcus pneumoniae*, *Haemophilus influenzae*, and Gram-negative rods than the silicone tube and Beschitin-F1 groups, indicating that Aquacel1-Ag was the most effective in bacteria suppression in *Streptococcus pneumoniae*, *Haemophilus influenzae*, and Gram-negative rods, but it was the least effective in the suppression of CNS and *Staphylococcus aureus* among the 3 groups. Aquacel hydrofiber is supplemented by 1.2% of silver, which is evenly distributed throughout the entire hydrofiber material [20]. The unique structure and the large surface area are main reasons for the sustained release of silver ions, which have long been reported to possess strong broad-spectrum antibacterial properties. Additionally, this mechanism includes disruption of DNA, binding to the cell wall of bacteria, as well as blocking the respiratory chain, thereby causing bacterial death [21]. Previous studies published by Bowler and Jones revealed that Aquacel1 Ag was effective against many kinds of bacteria, such as *Serratia marcescens*, *Pseudomonas aeruginosa*,

*Aspergillus niger*, *Bacteroides fragilis*, vancomycin-resistant enterococci (VRE), and methicillin-resistant *Staphylococcus aureus* (MRSA) [22,23].

The small number of research subjects in this study may have caused random errors, thus affecting the final results and requiring a further study within a larger sample size. Chewing difficulties during the nasal padding process that required dietary changes, as well as the impact on the sleeping habits, were also likely to affect the results of this study, so future studies should try to control for the interference generated by these factors. In addition, the current study was limited to the use of silicone tubing, Beschitin-F1, and Aquacel1-Ag. Future comparative experiments might incorporate calcium alginate and other nasal packing materials.

## Conclusions

The results of this study indicate that the silicone tube may be more effective and safer than Beschitin-F and Aquacel1-Ag as nasal packing after FES surgery for CRS. Therefore, silicone tubes might be the first choice for CRS after FESS. A limitation of this study is the relatively small sample size. The results of our study should be confirmed by future studies with larger sample sizes.

## Acknowledgments

We would like to acknowledge the helpful comments on this paper that we received from our reviewers.

## Disclosure statement

We declare no conflicts of interest.

## References:

1. Adams PF, Heyman KM, Vickerie JL: Summary health statistics for the U.S. population: National Health Interview Survey, 2008. *Vital Health Stat*, 2009; (243): 1-104
2. Krings JG, Kallogjeri D, Wineland A et al: Complications of primary and revision functional endoscopic sinus surgery for chronic rhinosinusitis. *Laryngoscope*, 2014; 124(4): 838-45
3. Okushi T, Yoshikawa M, Otori N et al: Evaluation of symptoms and QOL with calcium alginate versus chitin-coated gauze for middle meatus packing after endoscopic sinus surgery. *Auris Nasus Larynx*, 2012; 39(1): 31-37
4. Verim A, Seneldir L, Naiboglu B et al: Role of nasal packing in surgical outcome for chronic rhinosinusitis with polyposis. *Laryngoscope*, 2014; 124(7): 1529-35
5. Shikani AH, Chahine KA, Alqudah MA: Endoscopically guided chitosan nasal packing for intractable epistaxis. *Am J Rhinol Allergy*, 2011; 25(1): 61-63
6. Verbelen J, Hoeksema H, Heyneman A et al: Aquacel((R)) Ag dressing versus Acticoat dressing in partial thickness burns: A prospective, randomized, controlled study in 100 patients. Part 1: burn wound healing. *Burns*, 2014; 40(3): 416-27
7. Harding K, Gottrup F, Jawien A et al: A prospective, multi-centre, randomised, open label, parallel, comparative study to evaluate effects of AQUACEL(R) Ag and Urgotul(R) Silver dressing on healing of chronic venous leg ulcers. *Int Wound J*, 2012; 9(3): 285-94
8. Ishii Y: Extraordinary benefits of an ordinary silicone tube. *Respir Investig*, 2015; 53(3): 87
9. Bhattacharyya N, Lee LN: Evaluating the diagnosis of chronic rhinosinusitis based on clinical guidelines and endoscopy. *Otolaryngol Head Neck Surg*, 2010; 143(1): 147-51
10. Kim KS, Won HR, Park CY et al: Analyzing serum eosinophil cationic protein in the clinical assessment of chronic rhinosinusitis. *Am J Rhinol Allergy*, 2013; 27(3): e75-80
11. Chevillard C, Rugina M, Bonfils P et al: Evaluation of calcium alginate nasal packing (Algosteril) versus Polyvinyl acetal (Merocel) for nasal packing after inferior turbinate resection. *Rhinology*, 2006; 44(1): 58-61
12. Lin HT, Day YJ, Sum DC et al: Displaced nasal silicone implant: An unusual cause of nasotracheal tube obstruction. *J Clin Anesth*, 2013; 25(4): 344-45
13. Huang SH, Lin CH, Chang KP et al: Clinical evaluation comparing the efficacy of aquacel Ag with Vaseline gauze versus 1% silver sulfadiazine cream in toxic epidermal necrolysis. *Adv Skin Wound Care*, 2014; 27(5): 210-15

14. Ngoc Ha T, Valentine R, Moratti S et al: A blinded randomized controlled trial evaluating the efficacy of chitosan gel on ostial stenosis following endoscopic sinus surgery. *Int Forum Allergy Rhinol*, 2013; 3(7): 573–80
15. Petrova YS, Pestov AV, Usoltseva MK et al: Selective adsorption of silver(I) ions over copper(II) ions on a sulfoethyl derivative of chitosan. *J Hazard Mater*, 2015; 299: 696–701
16. Orłowska J, Kurczewska U, Derwinska K et al: The use of biodegradable polymers in design of cellular scaffolds. *Postepy Hig Med Dosw (Online)*, 2015; 69: 294–301
17. Yan M, Zheng D, Li Y et al: Biodegradable nasal packings for endoscopic sinonasal surgery: A systematic review and meta-analysis. *PLoS One*, 2014; 9(12): e115458
18. Landrigan PJ, Benbrook C: GMOs, herbicides, and public health. *N Engl J Med*, 2015; 373(8): 693–95
19. Jardim KV, Joanitti GA, Azevedo RB et al: Physico-chemical characterization and cytotoxicity evaluation of curcumin loaded in chitosan/chondroitin sulfate nanoparticles. *Mater Sci Eng C Mater Biol Appl*, 2015; 56: 294–304
20. Caruso DM, Foster KN, Hermans MH et al: Aquacel Ag in the management of partial-thickness burns: results of a clinical trial. *J Burn Care Rehabil*, 2004; 25(1): 89–97
21. Lansdown AB: Silver. I: Its antibacterial properties and mechanism of action. *J Wound Care*, 2002; 11(4): 125–30
22. Bowler PG, Jones SA, Walker M et al: Microbicidal properties of a silver-containing hydrofiber dressing against a variety of burn wound pathogens. *J Burn Care Rehabil*, 2004; 25(2): 192–96
23. Edwards-Jones V: Antimicrobial and barrier effects of silver against methicillin-resistant *Staphylococcus aureus*. *J Wound Care*, 2006; 15(7): 285–90