

A Unique Case of Increased 18F-FDG Metabolic Activity in the Soft Tissues of the Bilateral Upper Thighs Due to Immunizations in a Pediatric Patient

Terrel L. Galloway, Mickaila J. Johnston, Michael D. Starsiak, Eugene D. Silverman

Department of Radiology, Division of Nuclear Medicine, Naval Medical Center San Diego, San Diego, California, USA

Abstract

A case of a 7-month-old white female who was referred for 18F-fluorodeoxyglucose (FDG) Positron emission tomography/computed tomography (PET/CT) initial evaluation of a lytic skull lesion with presumed diagnosis of Langerhans cell histiocytosis is described. Incidentally, she was found to have hypermetabolic nodules in the soft tissues of her anterior thighs.

Keywords: 18F-fluorodeoxyglucose, lytic skull lesion, Positron emission tomography/computed tomography, soft tissue nodule, vaccination

Introduction

A unique case of a 7-month-old white female with a lytic skull lesion who was referred for initial staging 18F-fluorodeoxyglucose (FDG) Positron emission tomography/computed tomography (PET/CT) for presumed Langerhans cell histiocytosis or possible neoplastic process is presented. The 18F-FDG PET/CT did not demonstrate significant FDG avidity in the region of the lytic skull lesion. However, the 18F-FDG PET/CT did demonstrate foci abnormal uptake in the soft tissues of the bilateral anterior thighs.

Case Report

Noncontrast enhanced CT of the head [Figure 1] demonstrates a non-FDG avid lytic lesion in the left frontal skull with a small soft tissue component. Whole body maximum intensity projection (MIP)

image [Figure 2] displays expected physiologic uptake, as well as abnormal focal areas of increased metabolic activity in the bilateral thighs. Select axial 18F-FDG PET/CT images [Figures 3 and 4] display coregistration of abnormal focal hypermetabolic foci within soft tissues of the anterior thighs bilaterally. No activity is evident within the inguinal lymph nodes. At the time of injection, the patient weighed 5.7 kg and had a blood sugar of 57 mg/dL. Imaging was performed approximately 99 min after the radiotracer injection.

Discussion

Increased FDG metabolic activity at sites of vaccination has previously been demonstrated.^[1-3] Both the intramuscular sites of vaccine injection and local lymph nodes can demonstrate increased FDG uptake.^[1-8] This can lead to regions of false positive metabolic activity, when evaluating for other systemic inflammatory or neoplastic processes on PET.

Address for correspondence:

Dr. Terrel L. Galloway,
34800 Bob Wilson Dr, Suite 204,
San Diego, California - 92134 1204, USA.
E-mail: terrelgalloway@yahoo.com

Access this article online

Quick Response Code:



Website:
www.wjnm.org

DOI:
10.4103/1450-1147.176886

This is an open access article distributed under the terms of the Creative Commons Attribution-NonCommercial-ShareAlike 3.0 License, which allows others to remix, tweak, and build upon the work non-commercially, as long as the author is credited and the new creations are licensed under the identical terms.

For reprints contact: reprints@medknow.com

How to cite this article: Galloway TL, Johnston MJ, Starsiak MD, Silverman ED. A unique case of increased 18f-FDG metabolic activity in the soft tissues of the bilateral upper thighs due to immunizations in a pediatric patient. World J Nucl Med 2017;16:59-61.

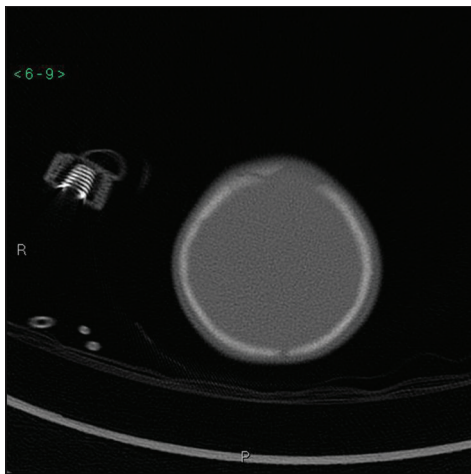


Figure 1: Noncontrast enhanced head CT

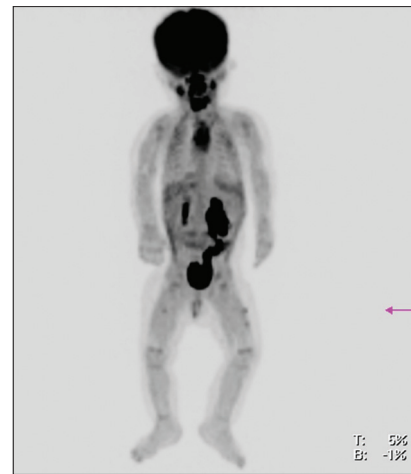

Figure 2: Whole-body maximum intensity projection



Figure 3: Select attenuation corrected axial 18F-fluorodeoxyglucose (18-F-FDG) positron emission tomography images of the bilateral thighs

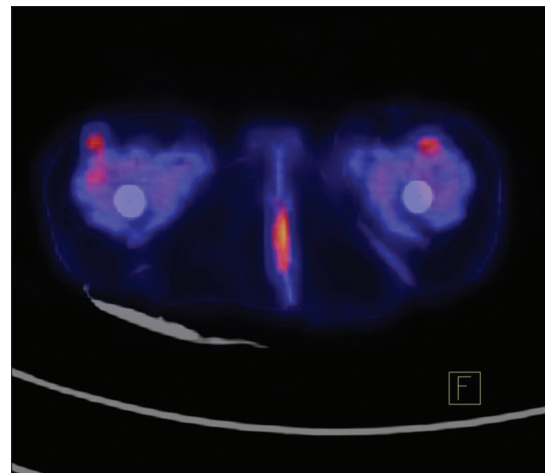


Figure 4: Select fused computed tomography and attenuation corrected axial 18F-fluorodeoxyglucose (18-F-FDG) positron emission tomography images of the bilateral thighs

On initial workup for the lytic skull lesion, differential diagnoses of Langerhans cell histiocytosis or a neoplastic process were initially considered. The patient then received an 18F-FDG PET/CT that demonstrated that the lytic frontal skull lesion did not have FDG avidity. However, multiple PET avid nodules in the soft tissues of the bilateral anterior thighs were present. Skull biopsy eventually characterized the skull lesion as an epidermoid cyst. Review of the patient's medical record did reveal that the patient had received both the 4-month-old and 6-month-old immunizations intramuscularly (IM) in the bilateral thighs. The 4-month-old immunizations consisted of combined diphtheria-tetanus-pertussis with hepatitis B and inactivated polio virus vaccines (DTaP-HepB-IPV) IM in the right thigh along with *Haemophilus influenzae* type b (Hib) and pneumococcal conjugate vaccine (PCV) IM in the left thigh approximately 114 days before the PET/CT. The 6-month-old immunizations also consisted of DTaP-HepB-IPV IM in the right thigh along with Hib and PCV IM in the left thigh approximately 51 days before the PET/CT.

A singular case report describes similar activity in one thigh of an infant who received vaccination 5 days prior to the 18F-FDG PET/CT.¹ However, such activity has not been seen in the bilateral thighs nor in an infant who received vaccinations over 50 days prior to the scan, thus invoking the question as to how long such activity can last following immunizations in infants. This also again emphasizes the importance of acquiring the vaccination history in infants and children to avoid attributing these false positive findings as pathologic activity.

Financial support and sponsorship

Nil.

Conflicts of interest

There are no conflicts of interest.

References

1. Sheehy N, Drubach L. (18) F-FDG uptake at vaccination site.

- Pediatr Radiol 2008;38:246.
2. Prosch H, Mirzaei S, Oschatz E, Strasser G, Huber M, Mostbeck G. Gluteal injection site granulomas: False positive finding on FDG-PET in patients with non-small cell lung cancer. *Br J Radiol* 2005;78:758-61.
 3. Burger IA, Husmann L, Hany TF, Schmid DT, Schaefer NG. Incidence and intensity of F-18 FDG uptake after vaccination with H1N1 vaccine. *Clin Nucl Med* 2011;36:848-53.
 4. Williams G, Joyce RM, Parker JA. False-positive axillary lymph node on FDG-PET/CT scan resulting from immunization. *Clin Nucl Med* 2006;31:731-2.
 5. Thomassen A, Lerberg Nielsen A, Gerke O, Johansen A, Petersen H. Duration of 18F-FDG avidity in lymph nodes after pandemic H1N1v and seasonal influenza vaccination. *Eur J Nucl Med Mol Imaging* 2011;38:894-8.
 6. Focosi D, Caracciolo F, Galimberti S, Papineschi F, Petrini M. False positive PET scanning caused by inactivated influenza virus vaccination during complete remission from anaplastic T-cell lymphoma. *Ann Hematol* 2008;87:343-4.
 7. Panagiotidis E, Exarhos D, Housianakou I, Bournazos A, Datsiris I. FDG uptake in axillary lymph nodes after vaccination against pandemic (H1N1). *Eur Radiol* 2010;20:1251-3.
 8. Kim JE, Kim EK, Lee DH, Kim SW, Suh C, Lee JS. False-positive hypermetabolic lesions on post-treatment PET-CT after influenza vaccination. *Korean J Intern Med* 2011;26:210-2.