

Double-balloon Trapping for Coil Embolization of Ruptured Internal Carotid Artery Aneurysm: A Novel Technique

Abstract

Introduction: Endovascular treatment of complex ruptured aneurysms in the internal carotid (IC) artery is extremely challenging. Navigation of double-balloon catheters becomes all the more difficult in tortuous vessels. **Patients and Methods:** A 57-year-old female with more than three times previously ruptured left IC artery aneurysm with subarachnoid hemorrhage had a left IC small aneurysm with a neck of 3.2 mm. Proximal and distal balloons were inflated in left IC artery in respect to the aneurysm, to prevent further rupture during navigation of the microcatheter and first coil. **Discussion:** The technique uses two balloons placed proximal and distal to the ruptured aneurysm, to reduce further bleeding, just as the application of temporary clips, followed by inertion of coils rapidly to obliterate the aneurysm. **Conclusion:** It is a novel technique of double-balloon trapping of proximal and distal segment of IC artery with aneurysm coiling technique as an alternative to balloon-assisted coiling and stent-assisted coiling in patients with ruptured aneurysm.

Keywords: Double-balloon, ruptured aneurysm, trapping

Introduction

Endovascular techniques for the treatment of intracranial aneurysm have evolved significantly since the introduction of Guglielmi detachable coils in the early 1990s.^[1] Complex wide-necked intracranial aneurysms are, however, extremely challenging to treat by endovascular techniques.

Balloon-assisted coiling (BAC) has been accepted as an adjunctive technique for the endovascular treatment of complex wide-necked intracranial aneurysms.^[2-10] When the anatomy is unfavorable, BAC alone may not be sufficient to prevent coil protrusion into the parent vessel, and an intracranial stent may be needed as a supporting scaffold. This can potentially add to the complexity of the case, especially in situations with aneurysmal subarachnoid hemorrhage where antiplatelet treatment before stent deployment may not be advisable.

Many modifications to BAC^[11-14] have been described to address concerns regarding coil prolapse, prolonged ischemic times during temporary occlusion, and lack of durability of coiling. In balloon-assisted rapid intermittent sequential coiling technique,

predetermined number of coils (usually between three and five coils per balloon inflation cycle) was deployed in the wide-necked aneurysm within a maximum balloon inflation time of 5 min. This allows multiple coils to brace with each other and form stable scaffolding for the deployment of further coils.

We describe our experience with a double-balloon trapping technique of proximal and distal segment of internal carotid (IC) artery with aneurysm coiling technique as an alternative to BAC and stent-assisted coiling in patients with ruptured aneurysm and in relative contraindications for stent-assisted coiling such as unfavorable tortuous vascular anatomy or parent artery too small for stent deployment.

Patients and Methods

A 57-year-old female with more than three times previously ruptured after her admission with left IC artery aneurysm with subarachnoid hemorrhage presented in World Federation of Neurosurgical Societies Grade 5 [Figure 1]. She had a left IC small aneurysm with a neck of 3.2 mm [Figure 2]. We planned an emergency endovascular coil embolization under general anesthesia. Proximal and distal balloons were inflated in left IC

**Ahmed Ansari,
Tomotaka
Ohshima¹,
Shunsaku Goto¹,
Taiki Yamamoto¹,
Kojiro Ishikawa¹,
Yoko Kato**

*Department of Neurosurgery,
Fujita Health University,
Banbuntane Hotokukai
Hospital, ¹Department of
Neurosurgery and Stroke,
Kariya Toyota General Hospital,
Nagoya, Japan*

Address for correspondence:

*Dr. Tomotaka Ohshima,
Department of Neurosurgery
and Stroke, Kariya Toyota
General Hospital, Nagoya,
Japan.
E-mail: tomotaka.oshima@
toyota-kai.or.jp*

Access this article online

Website: www.asianjns.org

DOI: 10.4103/ajns.AJNS_134_17

Quick Response Code:



How to cite this article: Ansari A, Ohshima T, Goto S, Yamamoto T, Ishikawa K, Kato Y. Double-balloon trapping for coil embolization of ruptured internal carotid artery aneurysm: A novel technique. *Asian J Neurosurg* 2019;14:873-7.

This is an open access journal, and articles are distributed under the terms of the Creative Commons Attribution-NonCommercial-ShareAlike 4.0 License, which allows others to remix, tweak, and build upon the work non-commercially, as long as appropriate credit is given and the new creations are licensed under the identical terms.

For reprints contact: reprints@medknow.com

artery in respect to the aneurysm, to prevent further rupture during navigation of the microcatheter and first coil.

Technique

The procedure was performed in a dedicated biplane neuroangiography suite (GE, United States) under general anesthesia.

Our procedure for double-balloon trapping included unilateral femoral arterial access and placement of an 8F access sheath. An 8F balloon guiding Optimo 90 cm (Tokai Medical Products, Aichi, Japan), catheter with 5F JB-2 125 cm (Medikit co. Ltd., Tokyo, Japan), and Radifocus 0.035 wire 150 cm (Terumo, Tokyo, Japan) were used.

A TransForm 4 × 10 (Stryker Neurovascular, Kalamazoo, MI, USA) balloon was navigated into the distal IC beyond the aneurysm. After a Headway preshaped 90° microcatheter (Terumo) with a CHIKAI 14 microguidewire (Asahi Intecc, Aichi, Japan) was navigated just front of the aneurysmal neck, the balloon of Optimo was inflated. Next, the TransForm balloon was inflated at just distal of the aneurysmal neck. Then, temporary double-balloon trapping was built. Under the double-balloon trapping, the microcatheter was navigated and a Target 360 Ultra 3.5 × 8 coil (Stryker) was deployed into the aneurysm as a frame. Next, the TransForm balloon was deflated and the Optimo balloon was subsequently deflated with manual aspiration of the congestive blood between two balloons. The occlusion time was 150 s. After checking angiogram, systemic heparinization was induced.

The patient was treated with Target 360 Ultra 3.5 × 8, Target nano 360 2.5 × 4, and Target nano helical 1.5 × 3, 1.5 × 2, 1 × 2 (Stryker) coils with a rapid detachment system. A total of five coils were used. Hemostasis was achieved using 7F ExoSeal (Cordis Corporation, a Johnson and Johnson Company; Bridgewater, NJ).

TransForm 4 × 10 balloons were inserted just distal to the ruptured aneurysm in the vessel to stop further bleeding and guidance to navigate a microcatheter into an aneurysm as a wall. As this positioning of the balloon is dangerous to increase blood flow into the aneurysm, the proximal balloon of the guiding catheter should be inflated former. Unlike the traditional approach, in this technique, we place a predetermined number of coils (usually between three and five coils per balloon inflation cycle) during a maximum balloon inflation time of 5 min. The balloon is then deflated to allow cerebral reperfusion and to evaluate if any coil loops are prolapsing into the parent artery. Balloon inflation is never carried out for longer than 5 min to reduce ischemic time [Figure 3].

On postoperative day 2, a check magnetic resonance imaging diffusion-weighted imaging was performed, which showed no infarcts [Figure 4]. The patient was discharged on a postoperative day 22 with no deficits [Figure 5].

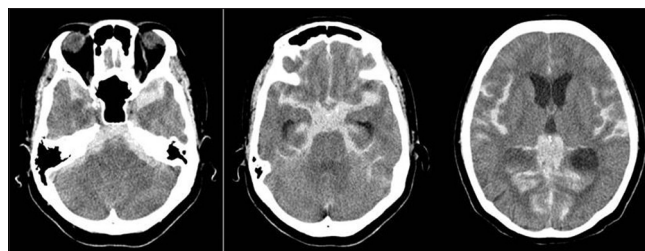


Figure 1: Computed tomography scan with diffuse subarachnoid bleed

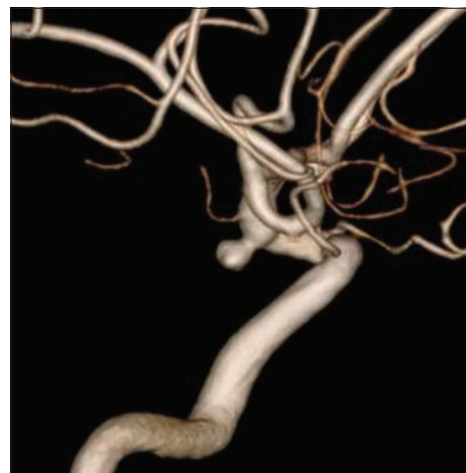

Figure 2: Left internal carotid aneurysm of 3.2 mm size on angiography

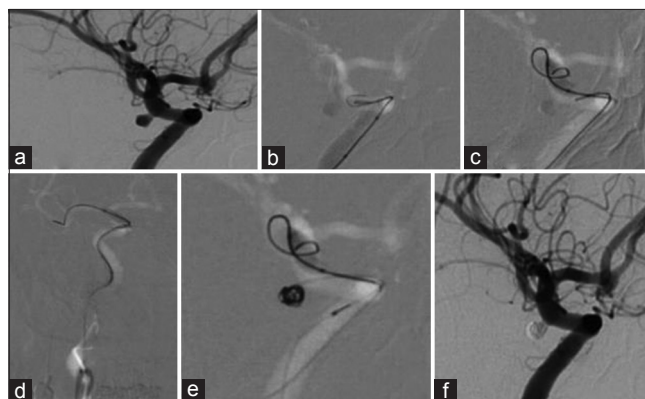


Figure 3: Digital subtraction angiography showing – (a) left internal carotid artery aneurysm; (b-d) proximal and distal balloons being inserted in relation to internal carotid aneurysm and inflated; (e) coiling of the aneurysm being done after proximal and distal-balloon trapping of left internal carotid artery; (f) postcoiling angiogram showing complete aneurysm obliteration

Discussion

Initially, the balloon-remodeling technique had permitted the endovascular treatment of intracranial aneurysms with an unfavorable dome-to-neck ratio.^[15] In several cases, two balloon catheters were used proximal to the circle of Willis to prevent the encroachment of coils onto the parent artery.^[16] Despite mastery of remodeling technique in many interventional neuroradiology clinics, endovascular treatment of complex aneurysms in small arteries is still challenging.^[7]

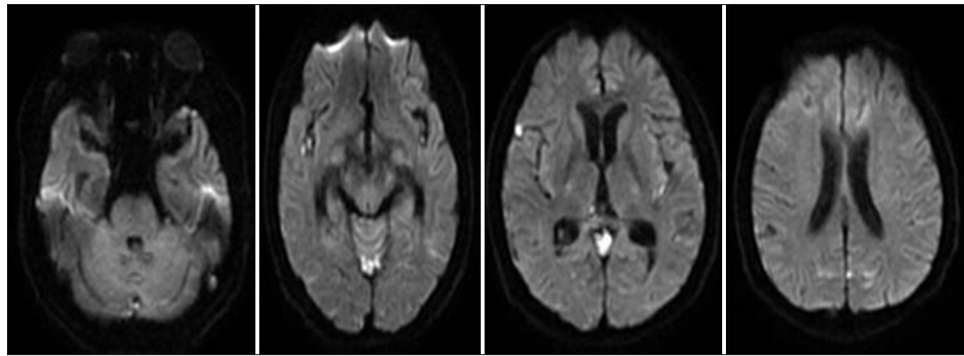


Figure 4: Postoperative day 2 magnetic resonance imaging diffusion-weighted imaging – no infarct

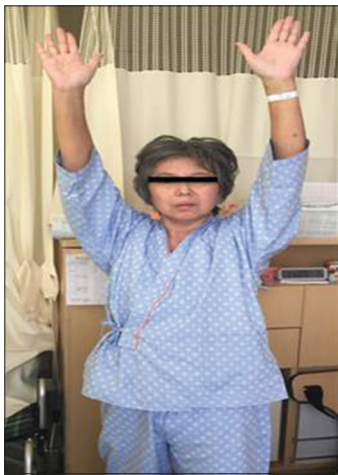

Figure 5: Postoperative day 22: No deficits

The requirement for dual antiplatelet medication, however, represents one significant potential drawback of the application of intracranial balloons and stents for aneurysm treatment. This is an important issue in the setting of acute subarachnoid hemorrhage, in which platelet inhibition could potentially result in a significant risk of bleeding complications,^[17] especially if a ventricular drain is required.

Many modifications such as “double-balloon”^[11-13] and double-microcatheter technique^[18,19] have been described for treating complex wide-necked aneurysms. Simultaneously, navigating two balloon catheters, however, may be difficult in tortuous vascular anatomy. The presence of multiple catheters may be difficult in small vessel diameter and may cause catheter-induced vasospasm.^[11] These techniques also pose a high risk of the parent artery rupture^[7] and thromboembolic events.^[11] Importantly, they do not solve the problem of framing coil prolapse after the balloon(s) is/are deflated.

Kelly *et al.*^[12] described placing multiple coils during each balloon inflation cycle (typically lasting 5–10 min) using a double-balloon trapping technique in a large wide-necked superior cerebellar artery aneurysm. The technique was primarily aimed at protecting the superior cerebellar artery arising from the neck of the aneurysm. Fiorella and

Woo^[14] described a technique of placing multiple coils during each balloon inflation cycle, which they named the “conglomerate mass technique.” The technique was aimed at reducing ischemic time and coil prolapse and at enhancing coil mass stability.

Our technique uses two balloons placed proximal and distal to the ruptured aneurysm, to reduce further bleeding, just as the application of temporary clips. Finally, coils are inserted rapidly to obliterate the aneurysm. The time for which the balloons remain inside the vessel should be reduced to a maximum of 5 min. Alternatively, the balloons can be deflated for the passage of blood. We completed the coiling in a time frame of <5 min.

The advantage of double-balloon trapping method with compliant balloons is that it permits the treatment of wide-necked aneurysms. Although the simultaneous use of multiple catheters is a potential risk factor for thromboembolic events during coiling,^[20] the risk may be at least partly offset because the two balloons prevent the encroachment of coils into the parent artery.

The present case was critical condition with repeated aneurysmal re-rupture after her arrival. Therefore, we thought that the small aneurysm was extremely fragile. The double-balloon trapping method is concepted from aneurysmal clipping. In the operation of clipping, we try to confirm both of proximal and distal parent arteries before exposure of aneurysms. Our balloon guiding catheter is used to be a proximal temporary clip. The proximal balloon should be inflated before the distal balloon to avoid increasing blood flow into the aneurysm. This proximal flow control also makes the distal balloon place easily at the precise point [Figure 6]. Furthermore, under the double balloon trapping, we can control a microcatheter absolute free. A neck-bridging stent also can be deployed if need especially in case of a blister-like aneurysm.

The double-balloon trapping technique has some disadvantages. First, the risk of thromboembolic complication is higher than the conventional procedure. We use systemic heparinization just after the deployment of the first coil. After the distal balloon is deflated, the proximal

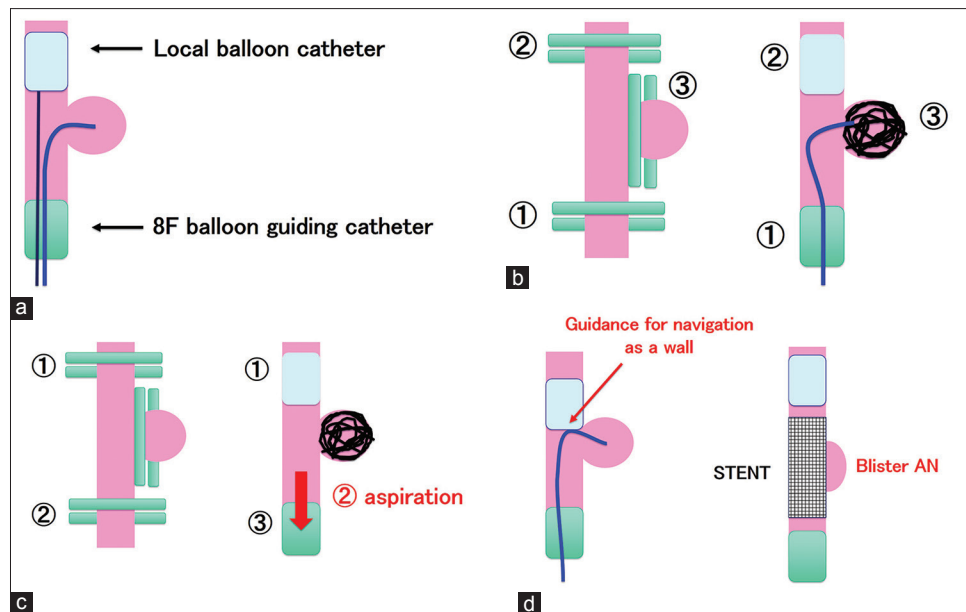


Figure 6: Pictorial diagram (a) showing balloon dilatation proximal and distal to the aneurysm, (b) showing usage of balloons in the same fashion as temporary clips, (c) showing coiled aneurysm, (d) showing usage of balloon as a navigation in inserting coils

guiding balloon is subsequently deflated with manual aspiration of the congestive blood between two balloons to avoid debris migrating. Potential complications such as complete prolapse of entire mass of multiple coils after balloon deflation can occur, although it was not found in this patient. This could be due to multiple coils bracing each other within the aneurysm and forming stable scaffold for deployment of further coils. As with any novel technique, there is a learning curve to gain technical expertise. Future larger series with long-term digital subtraction angiographic follow-up is required to confirm these preliminary results.

Conclusion

Double-balloon trapping technique allows good packing and affords a stable configuration across a ruptured aneurysm. This technique may provide an alternative to stent-assisted coiling or balloon-assisted rapid intermittent sequential coiling in patients with acutely ruptured small and blistered aneurysm.

Declaration of patient consent

The authors certify that they have obtained all appropriate patient consent forms. In the form the patient(s) has/have given his/her/their consent for his/her/their images and other clinical information to be reported in the journal. The patients understand that their names and initials will not be published and due efforts will be made to conceal their identity, but anonymity cannot be guaranteed.

Financial support and sponsorship

Nil.

Conflicts of interest

There are no conflicts of interest.

References

- Guglielmi G, Viñuela F, Duckwiler G, Dion J, Lylyk P, Berenstein A, et al. Endovascular treatment of posterior circulation aneurysms by electrothrombosis using electrically detachable coils. *J Neurosurg* 1992;77:515-24.
- Moret J, Cognard C, Weill A, Castaings L, Rey A. The "Remodelling technique" in the treatment of wide neck intracranial aneurysms. *Angiographic results and clinical follow-up in 56 cases. Interv Neuroradiol* 1997;3:21-35.
- Lefkowitz MA, Gobin YP, Akiba Y, Duckwiler GR, Murayama Y, Guglielmi G, et al. Balloon-assisted Guglielmi detachable coiling of wide-necked aneurysms: Part II – Clinical results. *Neurosurgery* 1999;45:531-7.
- Aletich VA, Debrun GM, Misra M, Charbel F, Ausman JI. The remodeling technique of balloon-assisted Guglielmi detachable coil placement in wide-necked aneurysms: Experience at the university of Illinois at Chicago. *J Neurosurg* 2000;93:388-96.
- Nelson PK, Levy DI. Balloon-assisted coil embolization of wide-necked aneurysms of the internal carotid artery: Medium-term angiographic and clinical follow-up in 22 patients. *AJNR Am J Neuroradiol* 2001;22:19-26.
- Cottier JP, Pasco A, Gallas S, Gabrillargues J, Cognard C, Drouineau J, et al. Utility of balloon-assisted Guglielmi detachable coiling in the treatment of 49 cerebral aneurysms: A retrospective, multicenter study. *AJNR Am J Neuroradiol* 2001;22:345-51.
- Lubicz B, Leclerc X, Gauthier JY, Lejeune JP, Pruvot JP. HyperForm remodeling-balloon for endovascular treatment of wide-neck intracranial aneurysms. *AJNR Am J Neuroradiol* 2004;25:1381-3.
- White JB, Layton KF, Kallmes DF, Cloft HJ. Balloon-assisted coiling through a 5-French system. *Neuroradiology* 2007;49:157-9.
- Ross IB, Dhillon GS. Balloon assistance as a routine adjunct to the endovascular treatment of cerebral aneurysms. *Surg Neurol* 2006;66:593-601.
- Layton KF, Cloft HJ, Gray LA, Lewis DA, Kallmes DF. Balloon-assisted coiling of intracranial aneurysms: Evaluation of local thrombus formation and symptomatic thromboembolic

- complications. *AJNR Am J Neuroradiol* 2007;28:1172-5.
11. Arat A, Cil B. Double-balloon remodeling of wide-necked aneurysms distal to the circle of Willis. *AJNR Am J Neuroradiol* 2005;26:1768-71.
 12. Kelly ME, Gonugunta V, Woo HH, Turner R 4th, Fiorella D. Double-balloon trapping technique for embolization of a large wide-necked superior cerebellar artery aneurysm: Case report. *Neurosurgery* 2008;63:291-2.
 13. Shima H, Nomura M, Muramatsu N, Sugihara T, Fukui I, Kitamura Y, *et al.* Embolization of a wide-necked basilar bifurcation aneurysm by double-balloon remodeling using HyperForm compliant balloon catheters. *J Clin Neurosci* 2009;16:560-2.
 14. Fiorella D, Woo HH. Balloon assisted treatment of intracranial aneurysms: The conglomerate coil mass technique. *J Neurointerv Surg* 2009;1:121-31.
 15. Moret J, Pierot L, Boulin A, Castaings L. "Remodelling" of the arterial wall of the parent vessel in the endovascular treatment of intracranial aneurysms. *Neuroradiology* 1994;36 (Suppl 1):83.
 16. Takahashi A. Letter to the editor. Neck plastic intra-aneurysmal GDC embolisation with double protective balloons. Method of multiple guiding catheter introduction. *Interv Neuroradiol* 1998;4:177-9.
 17. Tumialán LM, Zhang YJ, Cawley CM, Dion JE, Tong FC, Barrow DL, *et al.* Intracranial hemorrhage associated with stent-assisted coil embolization of cerebral aneurysms: A cautionary report. *J Neurosurg* 2008;108:1122-9.
 18. Baxter BW, Rosso D, Lownie SP. Double microcatheter technique for detachable coil treatment of large, wide-necked intracranial aneurysms. *AJNR Am J Neuroradiol* 1998;19:1176-8.
 19. Kai Y, Hamada J, Morioka M, Yano S, Mizuno T, Kuratsu J, *et al.* Double microcatheter technique for endovascular coiling of wide-neck aneurysms using a new guiding device for the transcarotid approach: Technical note. *Neuroradiology* 2005;47:73-7.
 20. Albayram S, Selcuk H, Kara B, Bozdag E, Uzma O, Kocer N, *et al.* Thromboembolic events associated with balloon-assisted coil embolization: Evaluation with diffusion-weighted MR imaging. *AJNR Am J Neuroradiol* 2004;25:1768-77.