



Since January 2020 Elsevier has created a COVID-19 resource centre with free information in English and Mandarin on the novel coronavirus COVID-19. The COVID-19 resource centre is hosted on Elsevier Connect, the company's public news and information website.

Elsevier hereby grants permission to make all its COVID-19-related research that is available on the COVID-19 resource centre - including this research content - immediately available in PubMed Central and other publicly funded repositories, such as the WHO COVID database with rights for unrestricted research re-use and analyses in any form or by any means with acknowledgement of the original source. These permissions are granted for free by Elsevier for as long as the COVID-19 resource centre remains active.

In conclusion, COVID-19 complications challenge our diagnostic skills. As long as we are able to broaden our knowledge of the physiopathology of this disease we can improve our ability to reduce its associated mortality.

Ana-Maria Ioan,^a Alejandro Durante-López,^b Juan Martínez-Milla,^b César Pérez-Calvo,^a and Arnaldo Santos^{a,c,*}

^aIntensive Care Medicine Department, Hospital Fundación Jiménez Díaz, Madrid, Spain

^bDepartment of Cardiology, Hospital Fundación Jiménez Díaz, Madrid, Spain

^cCIBER de Enfermedades Respiratorias (CIBERES), Madrid, Spain

* Corresponding author:

E-mail address: asantosoviedo@yahoo.com (A. Santos).

Available online 27 April 2020

REFERENCES

1. Mekontso Dessap A, Boissier F, Charron C, et al. Acute Cor Pulmonale During Protective Ventilation for Acute Respiratory Distress Syndrome: Prevalence, Predictors and Clinical Impact. *Intensive Care Med.* May 2016;42:862–870. <http://dx.doi.org/10.1007/s00134-015-4141-2>.
2. Driggin E, Madhavan MV, Bikdeli B, et al. Cardiovascular Considerations for Patients, Health Care Workers and Health Systems During the Coronavirus Disease 2019 (COVID-19) Pandemic. *J Am Coll Cardiol.* 2020. <http://dx.doi.org/10.1016/j.jacc.2020.03.031>.
3. Gattinoni L, Coppola S, Cressoni M, Busana M, Rossi S, Chiumello D. Covid-19 Does Not Lead to a "Typical" Acute Respiratory Distress Syndrome. *Am J Respir Crit Care Med.* 2020. <http://dx.doi.org/10.1164/rccm.202003-0817LE>.
4. Zhang Y, Xiao M, Zhang S, et al. Coagulopathy and Antiphospholipid Antibodies in Patients with Covid-19. *N Engl J Med.* 2020. <http://dx.doi.org/10.1056/NEJMc2007575>.
5. Falterman TJ, Martinez JA, Daberkow D, Weiss LD. Pulmonary embolism with ST segment elevation in leads V1 to V4: case report and review of the literature regarding electrocardiographic changes in acute pulmonary embolism. *J Emerg Med.* 2001;21:255–261.
6. Halpern EJ. Triple-Rule-Out CT Angiography for Evaluation of Acute Chest Pain and Possible Acute Coronary Syndrome. *Radiology.* 2009;252:332–345.

<https://doi.org/10.1016/j.rec.2020.04.010>

1885-5857/

© 2020 Sociedad Española de Cardiología. Published by Elsevier España, S.L.U. All rights reserved.

Fatal outcome of COVID-19 disease in a 5-month infant with comorbidities



Evolución mortal de la enfermedad COVID-19 en un lactante de 5 meses con comorbilidad

To the Editor,

SARS-CoV-2 infection in children has been described in around 1% of cases in China.¹ Although data are still limited, most series report mostly mild cases, even in infants. Critically-ill patients represent 0.6% of children and 50% of them are younger than 1 year old.² There have been very few reports of deaths. In a Wuhan series, a 10-month-old infant with intussusception developed multiorgan failure and died, while 3 patients had underlying diseases, representing 1.7% of children.³

Spain is currently in a situation of intense community transmission with more than 100 000 reported cases.

Between 11 and 18 March 2020, 12 children with confirmed SARS-CoV-2 infection were admitted to a large university hospital, 5 (41.6%) of whom had underlying disease (1 liver transplant, 1 vasculitis with hemodialysis, 2 congenital heart disease, and 1 Hurler syndrome with associated dilated cardiomyopathy).

One of the 12 children was a 5-month-old boy who had been diagnosed with heart failure and mucopolysaccharidosis type I-Hurler syndrome at age 1 month. He had moderate dilatation of the left ventricle assessed by echocardiography and computed tomography (figure 1), left ventricular end diastolic diameter 30 mm Z + 3.8, and moderate left ventricular dysfunction (ejection fraction 48%). Enzyme replacement therapy (ERT) with human recombinant α L-iduronidase was started on a weekly basis after neurologist and hematologist consultation as a bridge to bone marrow transplant. After 7 weeks, his function deteriorated, with increased left ventricular volume (left ventricular end diastolic diameter 48 mm Z + 8.5) lower ejection fraction (EF; < 30%) moderate mitral regurgitation, and left atrium enlargement. The patient required admission to intensive care with adrenaline and milrinone drips. A computed tomography scan was performed to rule out coronary artery lesions. The possibility of heart transplant listing was excluded. After intense heart failure therapy, iv drips

were discontinued and the patient was switched to oral therapy with captopril, diuretics, carvedilol and digoxin with a mild improvement, which allowed discharge after 8 weeks. ERT was continued to allow bone marrow transplant if cardiac function improved.

When the patient was 5 months old, he was hospitalized after a 24-hour course of irritability, low-grade fever (below 38 C), cough, runny nose, and vomiting. He showed pallor, slight respiratory distress, and bibasal pulmonary subcrackles. Chest X-ray showed cardiomegaly without consolidations (figure 2A). An electrocardiogram showed sinus rhythm at 160 bpm and biventricular hypertrophy. The last echocardiogram performed 2 weeks before admission showed left ventricular dilation with left ventricular end diastolic diameter 39 mm Z + 7.3 EF 30%, and longitudinal global strain – 10%. Leukocyte count was 21 400/mm³ with 12 890/mm³ neutrophils, and C-reactive protein 36 mg/L. Treatment was started with fluid restriction and conventional oxygen therapy (1–2 LPM).

COVID-19 disease was suspected and SARS-CoV-2 polymerase chain reaction was positive. Captopril was withdrawn in the

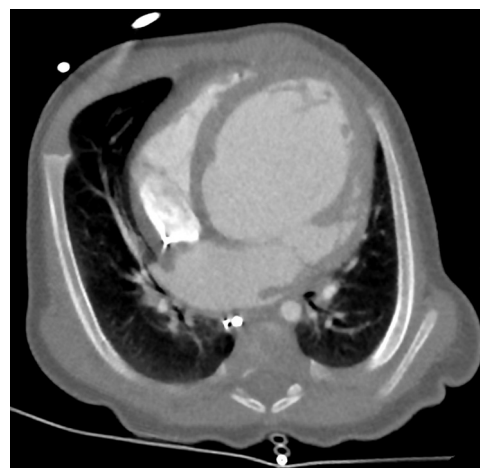

Figure 1. Retrospective electrocardiogram-triggered 320-multidetector cardiac computed tomography angiography image showing marked dilation of the left ventricle.

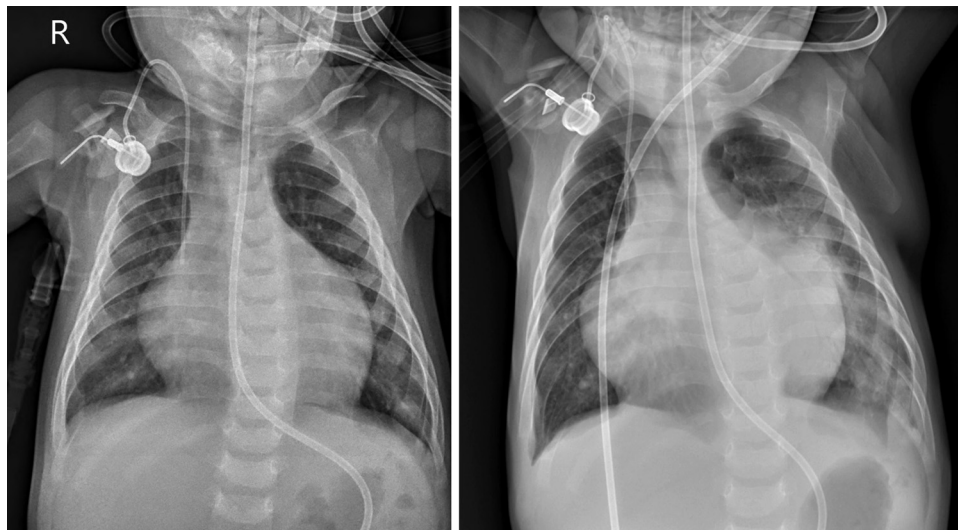


Figure 2. A: Chest film taken on hospital admission showing an abnormal (wide) cardiothoracic ratio, without visible lung abnormalities. R, right. B: follow-up radiograph obtained at day 3 after admission showing bilateral perihilar consolidation with air bronchograms, extending to left lung base, even in retrocardiac space.

emergency room prior to confirmation of the diagnosis. At 24 hours after admission, the patient was stable without oxygen therapy. After 48 hours, there was an increase in bilateral pulmonary crackles and palpebral edema. He had low-grade fever without analytical impairment, so it was interpreted as worsening heart failure with good response to diuretic treatment. However, 72 hours after admission, he had high fever (39.6 C) and respiratory distress, and chest X-ray revealed extensive symmetric parahilar consolidations that extended to the paracardiac region and pulmonary base on the left side (figure 2B). Blood testing showed no lymphopenia (2540/ μ L), C-reactive protein 244 mg/L, and D-dimer 973 ng/mL. Blood culture was negative. Hydroxychloroquine and ceftriaxone were prescribed, and remdesivir requested, but 2 hours later the patient had a cardiac arrest, requiring intubation. After admission to the pediatric intensive care unit, he had a second cardiac arrest, which proved fatal.

This report emphasizes the fatal clinical course of an infant admitted with SARS-CoV-2 infection associated with significant comorbidity. In the current COVID-19 outbreak, most deaths occur in elderly patients with or without comorbidities.¹ Cardiac injury is a common condition among hospitalized adult patients with COVID-19 in Wuhan, China, and has been associated with a higher risk of in-hospital mortality.⁴ The outcomes of infants with severe heart disease associated with SARS-CoV-2 infections have not been reported.

Mucopolysaccharidosis type I-Hurler syndrome is a lysosomal storage disease caused by a deficiency of the lysosomal enzyme α -L-iduronidase. The clinical course is characterized by progressive multisystem morbidity with cardiovascular deterioration and death in infancy. Current treatment includes ERT and bone marrow transplant.⁵ Severe cardiomyopathy in early infancy may complicate the clinical situation and affect survival but ERT has been reported to improve cardiac function.⁵

SARS-CoV-2 infection is proposed to evolve in 3 phases, causing mortality in the third phase after about 2 weeks or more.⁶ In the early phase, SARS-CoV-2 multiplies in the host, primarily focusing on the respiratory system with mild symptoms. SARS-CoV-2 binds to its target using the angiotensin-converting enzyme 2 receptor on human cells, abundantly present in the human lung. During the second phase, lung involvement is established, and lymphopenia appears. A minority of patients will reach the third phase of

systemic hyperinflammation with an increase in inflammatory cytokines, interleukins, C-reactive protein, ferritin, D-dimer, and others. Troponin and N-terminal pro B-type natriuretic peptide can also be elevated.

The clinical course of our patient was very short, reaching the hyperinflammation phase in just 3 to 4 days from the onset of symptoms. The situation of previous heart failure could undoubtedly contribute to a low reserve that led to cardiac arrest. The role of previous treatment with an angiotensin-converting enzyme inhibitor may have contributed to his rapid deterioration but the role of angiotensin-converting enzyme inhibitors remains to be elucidated.

There is scarce information about SARS-CoV-2 infection in children with underlying disease. It is noteworthy that in the first week of the pandemic in our center, 5 of the 12 admitted children had significant comorbidities. Patients with heart failure due to cardiomyopathies or congenital heart disease may constitute a group of special concern.

Acknowledgments

We wish to thank Dr Samuel Ignacio Pascual for his advice (Pediatric Neurology Department).

Francisco José Climent,^a Cristina Calvo,^{b,*} Luis García-Guereta,^c Diego Rodríguez-Álvarez,^d Nelson Mauricio Buitrago,^e and Antonio Pérez-Martínez^f

^aUnidad de Niños con Patología Crónica Compleja, Hospital Universitario La Paz, Madrid, Spain

^bServicio de Pediatría y Enfermedades Infecciosas, Hospital Universitario La Paz, Madrid, Spain

^cServicio de Cardiología Pediátrica, Hospital Universitario La Paz, Madrid, Spain

^dServicio de Cuidados Intensivos Pediátricos, Hospital Universitario La Paz, Madrid, Spain

^eServicio de Radiología Pediátrica, Hospital Universitario La Paz, Madrid, Spain

[†]Servicio de Hemato-Oncología Pediátrica, Hospital Universitario La Paz, Madrid, Spain

* Corresponding author:

E-mail address: ccalvorey@gmail.com (C. Calvo).

Available online 27 April 2020

REFERENCES

1. Wu Z, McGoogan JM. Characteristics of and important lessons from the coronavirus disease 2019 (COVID-19) outbreak in China: summary of a report of 72 314 cases from the Chinese Center for Disease Control and Prevention. *JAMA*. 2020. <http://dx.doi.org/10.1001/jama.2020.2648>.
2. Dong Y, Mo X, Hu Y, et al. Epidemiological Characteristics of 2143 Pediatric Patients With 2019 Coronavirus Disease in China. *Pediatrics*. 2020. <https://doi.org/10.1542/peds.2020-0702>

3. Chen Z, Xiong H, Li JX, et al. COVID-19 With Post-Chemotherapy Agranulocytosis in Childhood Acute Leukemia: A Case Report. *Zhonghua Xue Ye Xue Za Zhi*. 2020;41:E004 <https://doi.org/10.3760/cma.j.issn.0253-2727.2020.0004>
4. Shi S, Qin MM, Shen BB, et al. Association of Cardiac Injury With Mortality in Hospitalized Patients With COVID-19 in Wuhan. *China JAMA Cardiol*. 2020;e200950.
5. Wiseman DH, Mercer J, Tylee K, et al. Management of mucopolysaccharidosis type IH (Hurler's syndrome) presenting in infancy with severe dilated cardiomyopathy: a single institution's experience. *J Inherit Metab Dis*. 2013;36:263–270.
6. Siddiqi HK, Mehra MR. COVID-19 Illness in Native and Immunosuppressed States: A Clinical-Therapeutic Staging Proposal. *J Heart Lung Transplant*. 2020. <http://dx.doi.org/10.1016/j.healun.2020.03.012>.

<https://doi.org/10.1016/j.rec.2020.04.011>
1885-5857/

© 2020 Sociedad Española de Cardiología. Published by Elsevier España, S.L.U. All rights reserved.

COVID-19 and cardiogenic shock. Different cardiovascular presentations with high mortality



COVID-19 y shock cardiogénico: diferentes formas de presentación cardiovascular con alta mortalidad

To the Editor,

Coronavirus disease 2019 (COVID-19) is the clinical manifestation of infection by severe acute respiratory syndrome-related coronavirus 2 (SARS-CoV-2). Patients with this condition usually present with respiratory symptoms that can progress to pneumonia, and severe cases may develop acute respiratory distress syndrome and cardiogenic shock. Information on the etiology and mortality of cardiogenic shock in COVID-19 is currently limited and is the objective of the present study.

Between 1 March and 15 April, 2020, urgent cardiac catheterization was carried out in 23 patients with a suspected ST-elevation acute coronary syndrome or cardiorespiratory arrest. Seven of them (30%) tested positive for COVID-19 by polymerase chain reaction (PCR) in nasopharyngeal exudate. All patients testing negative for COVID-19 were ultimately discharged without complications. Of the 7 testing positive for COVID-19, 2 were discharged, 1 died due to respiratory failure secondary to severe pneumonia, and 4 developed cardiogenic shock immediately after arrival at the hospital. Three of these 4 patients died, yielding a mortality rate of 75% in the context of cardiogenic shock. The clinical, analytical, and imaging features of these patients, the treatment they received, and their clinical courses are summarized in [table 1](#).

The first case was a 42-year-old woman, with no cardiovascular risk factors or comorbidities, who attended the emergency room with symptoms of dyspnea and cough. Minutes later she developed cardiorespiratory arrest in a defibrillation-amenable rhythm, which led to an arrhythmic storm refractory to antiarrhythmic therapy. Echocardiography showed severe biventricular dysfunction. During cardiopulmonary resuscitation in the cardiac catheterization laboratory, a venoarterial extracorporeal membrane oxygenation (VA-ECMO) support system was implanted by peripheral cannulation. Aortography depicted a normal aorta and coronary arteries, and pulmonary angiography ruled out pulmonary thromboembolism ([figure 1A,B](#)). At completion of the procedure, an intra-aortic counterpulsation balloon was implanted to attempt left ventricular unloading, as well as a temporary pacemaker, but the patient died within hours in refractory shock. As the patient tested PCR-positive for COVID-19, the most likely diagnosis was acute fulminant myocarditis.

The second case was a 50-year-old man with no cardiovascular risk factors or comorbid conditions, who was hospitalized for severe bilateral pneumonia due to COVID-19 with a need for mechanical ventilation. A few hours after he was admitted, he suddenly developed severe hypotension (systolic blood pressure, 60 mmHg) with lateral wall ST-segment elevation. Urgent cardiac catheterization showed lesion-free coronary arteries and severe left ventricular dysfunction with contractility changes consistent with stress cardiomyopathy (inverted tako-tsubo), with akinesis of the basal and mid segments, and apical hypercontractility ([figure 1C,D](#)). Left ventricular end-diastolic pressure was 22 mmHg. The patient progressed gradually to distributive shock, requiring ventilation. After 11 days of hospitalization under treatment with hydroxychloroquine, antiretroviral agents, antibiotics, and corticosteroids, he was discharged with normal cardiac contractility.

The third case was a 75 year-old man, with no cardiovascular risk factors or notable comorbidities, who attended the emergency room for symptoms of dyspnea and chest pain. Electrocardiography showed inferior wall ST-segment elevation and complete atrioventricular block. He experienced several episodes of primary ventricular fibrillation requiring electrical cardioversion, as well as orotracheal intubation and mechanical ventilation. Norepinephrine perfusion was started, and primary angioplasty was performed with implantation of a stent in the right coronary artery ([figure 1E,F](#)). The echocardiogram showed biventricular dysfunction with right-sided predominance, and the chest radiograph, bilateral pneumonia. Within a few hours the patient died in electromechanical dissociation, with a diagnosis of right coronary artery thrombosis and bilateral SARS-CoV-2 pneumonia.

Finally, the fourth case was a 37 year-old woman, obese and with a history of deep venous thrombosis, who attended the emergency room for symptoms of dyspnea and chest pain. Troponin I was found to be elevated, and because of her medical history, urgent CT angiography of the pulmonary arteries was performed, which showed bilateral pulmonary thromboembolism with right ventricular dilation, in addition to patchy peripheral opacities compatible with SARS-CoV-2 pneumonia, which was confirmed by PCR ([figure 1G,H](#)). Suddenly, she experienced severe, persistent hypotension and severe oxygen desaturation (peripheral saturation < 80%). Despite administration of systemic thrombolysis, the patient died due to cardiogenic shock without reaching the cardiac catheterization laboratory for possible percutaneous treatment.

As illustrated by these 4 cases, cardiogenic shock can develop suddenly in COVID-19 patients and can have different causes. It is essential to perform a differential diagnosis with a view toward